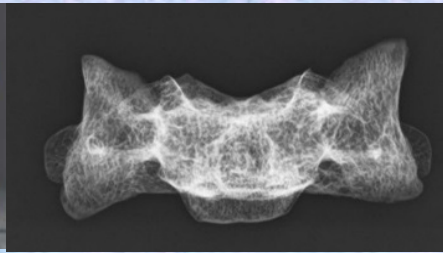
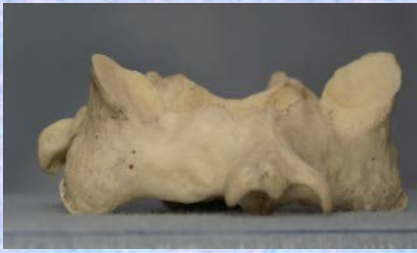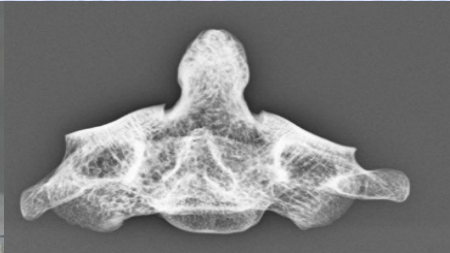

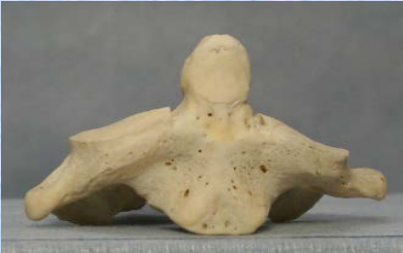
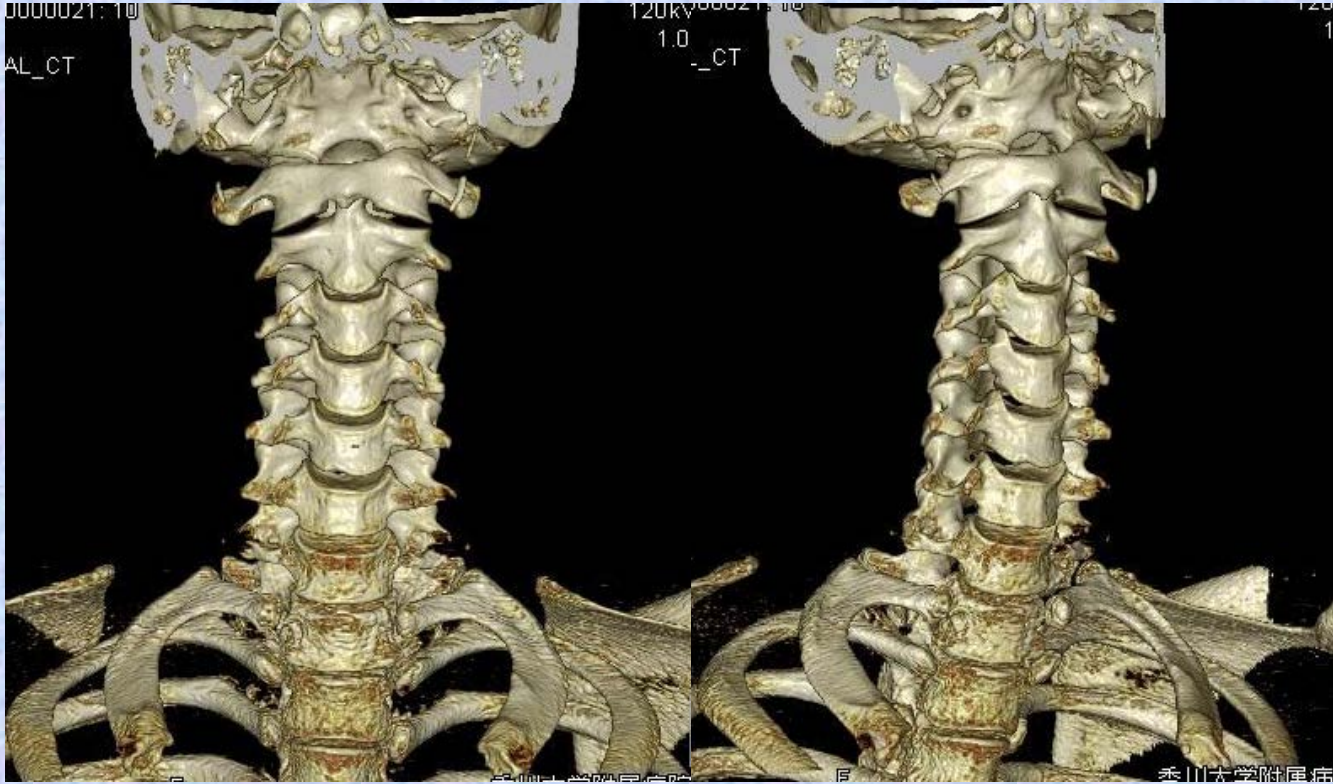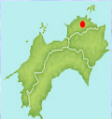骨標本X線ステレオ解剖図

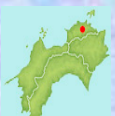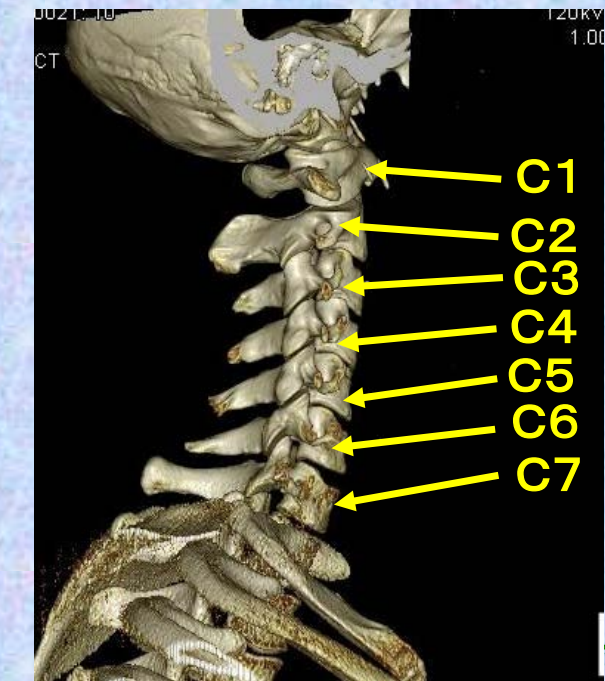
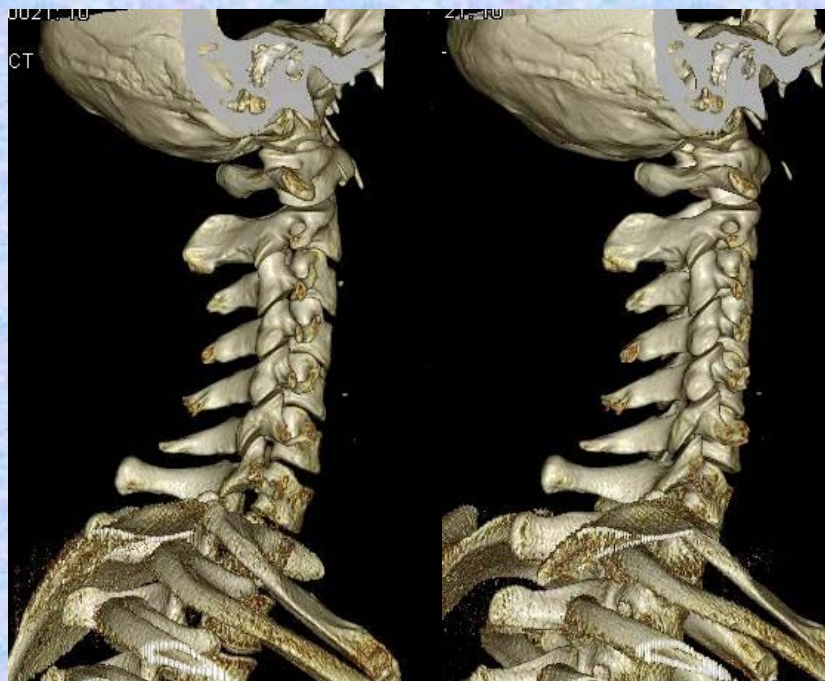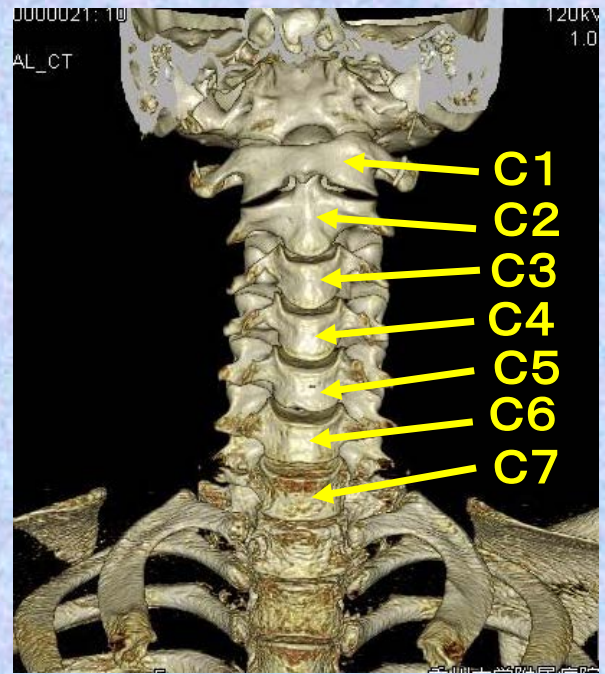
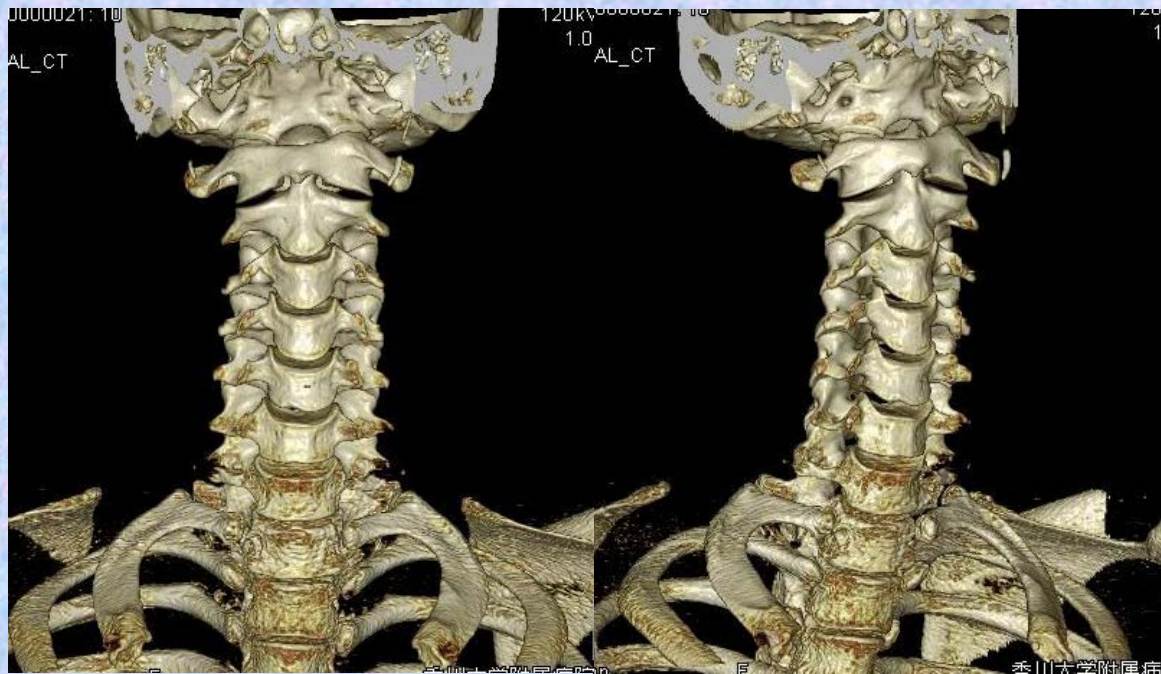頸椎

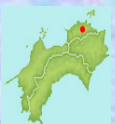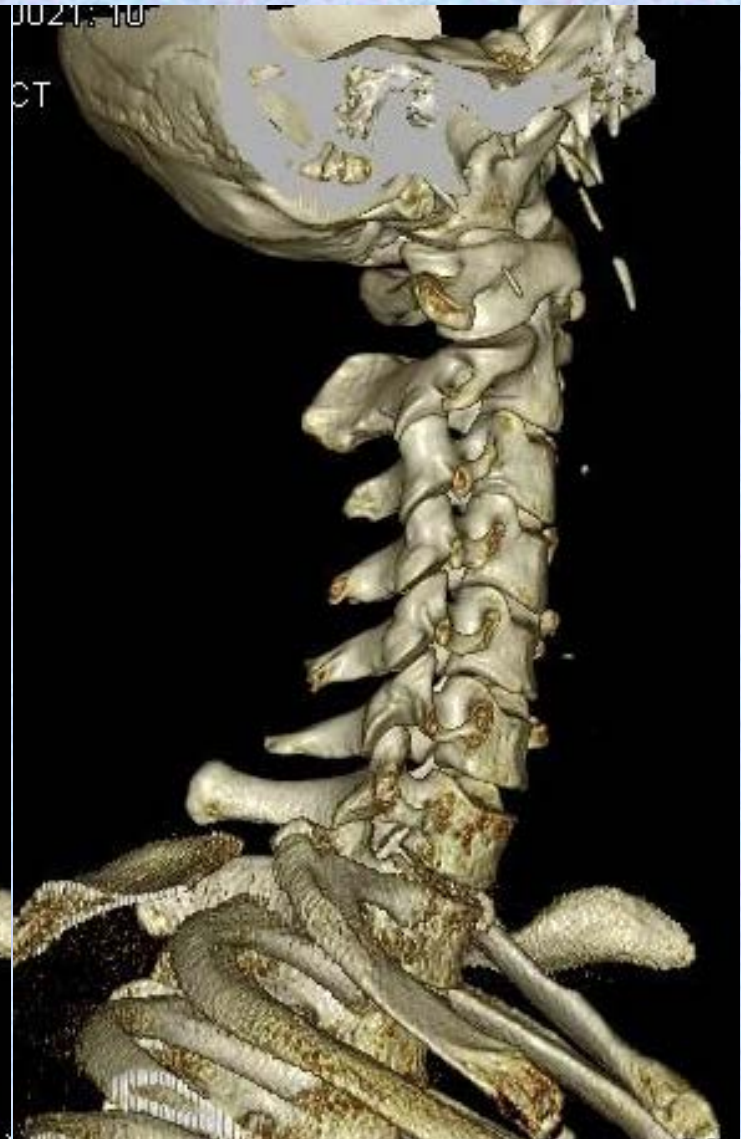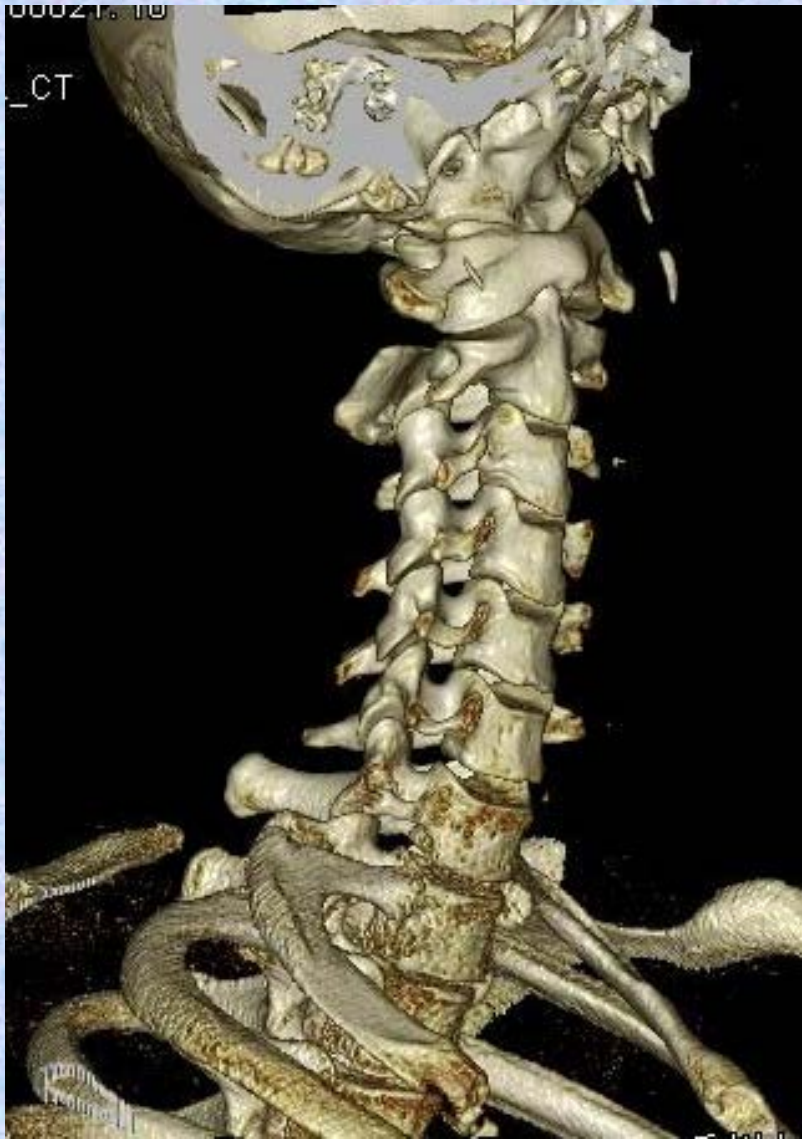頸椎



監修 香川大学医学部 組織細胞生物学 教授 荒木 伸一
 作成 香川大学医学部附属病院 放射線部 勢川 博雄 2014.9







頸椎

Cervical vertebrae (複)

Cervical vertebra (単)



第1頸椎

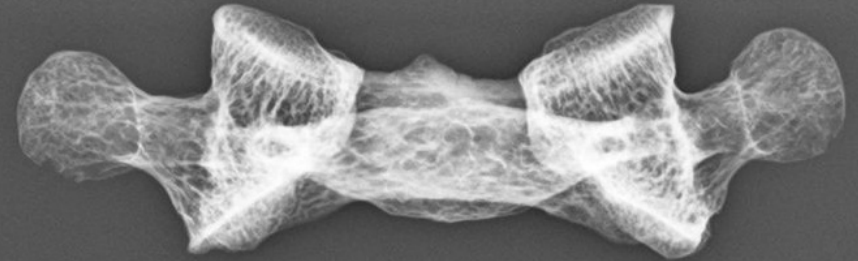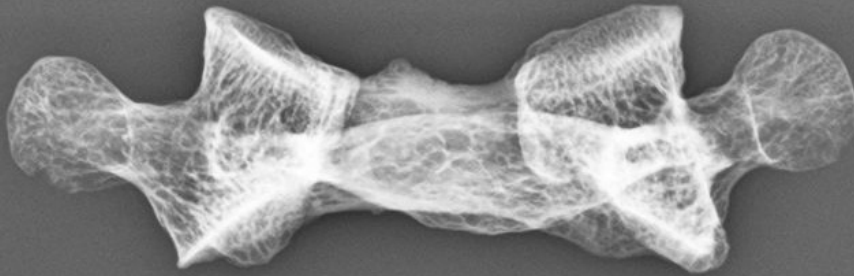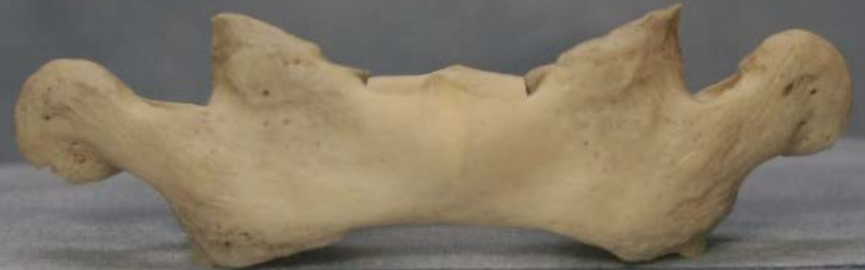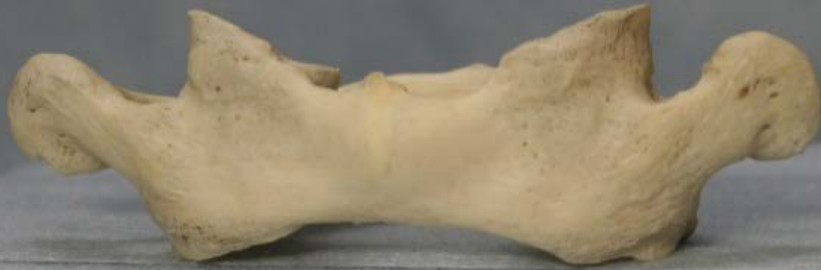Cervical vertebra 1

C 1

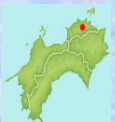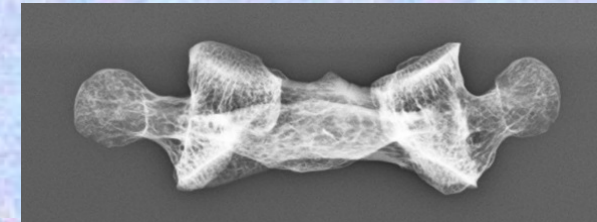



頸椎 C1 前面

第1頸椎 環椎 前面 (Cervical vertebra 1 Atlas anterior surface)

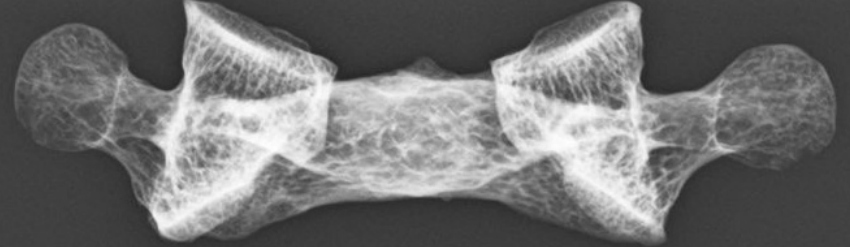
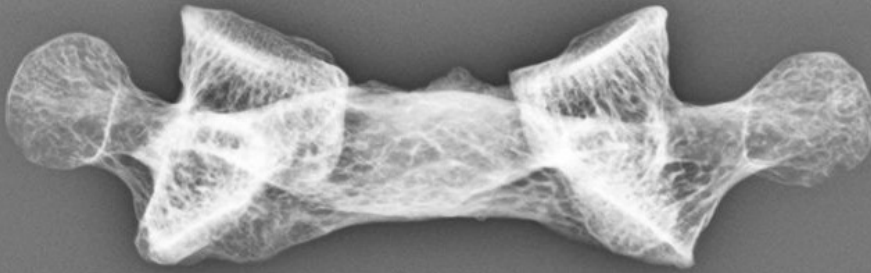
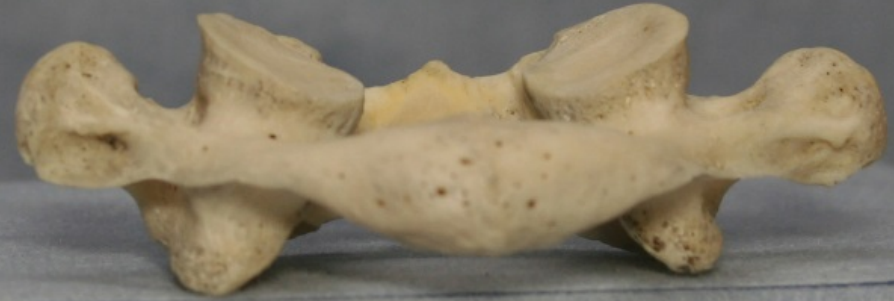
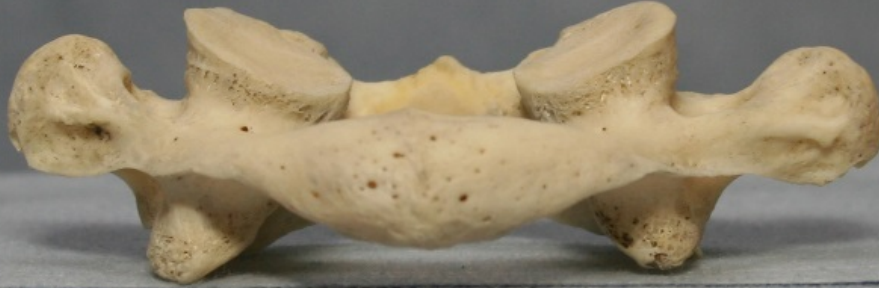- ①前弓 anterior arch
- ②横突起 transverse process
- ③上関節窩 superior articular facet
- ④下関節窩 inferior articular facet
- ⑤後弓 posterior arch

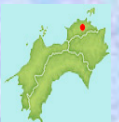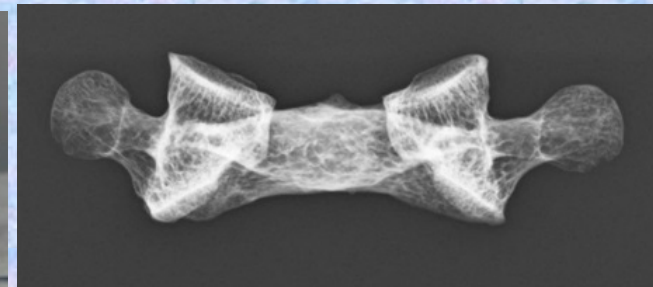
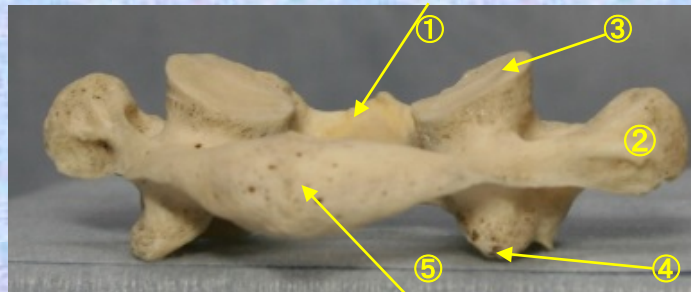


頸椎 C1 後面

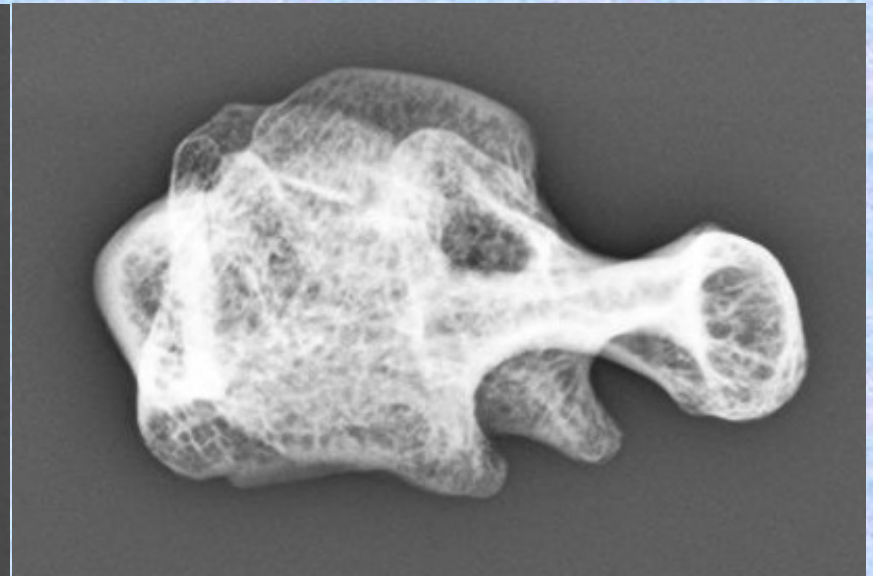
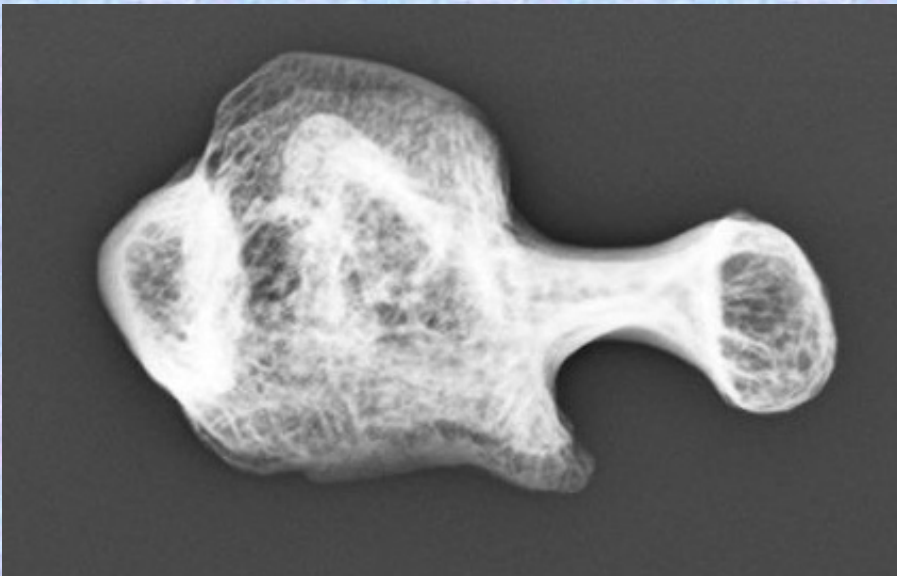
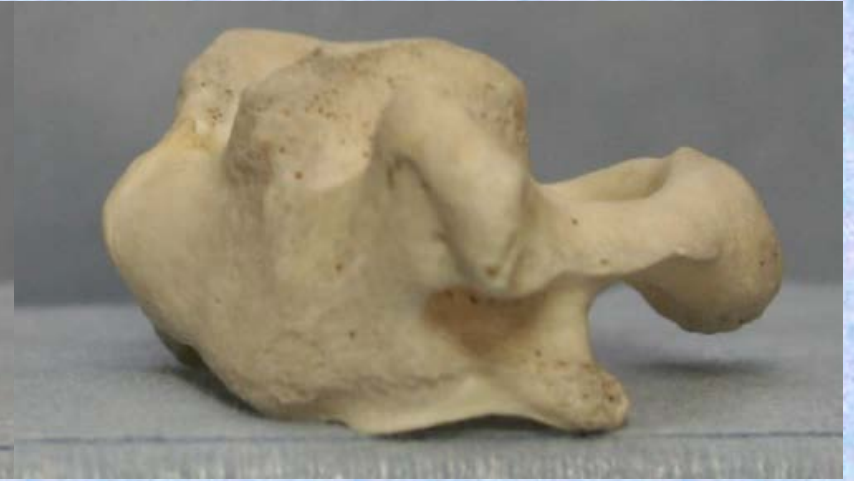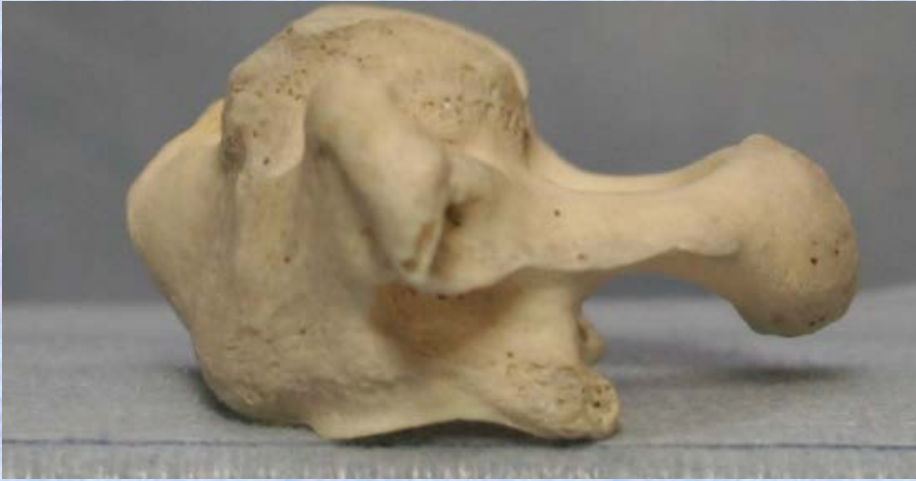第1頸椎 環椎 後面 (Cervical vertebra 1 Atlas posterior surface)



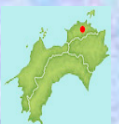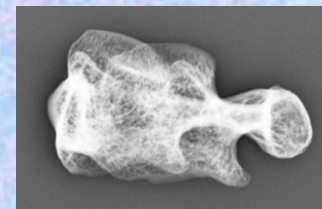
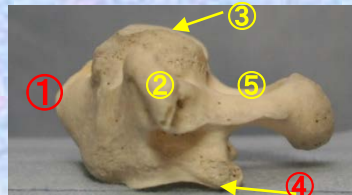
- ①前弓 anterior arch
- ②横突起 transverse process
- ③上関節窩 superior articular facet
- ④下関節窩 inferior articular facet
- ⑤後弓 posterior arch



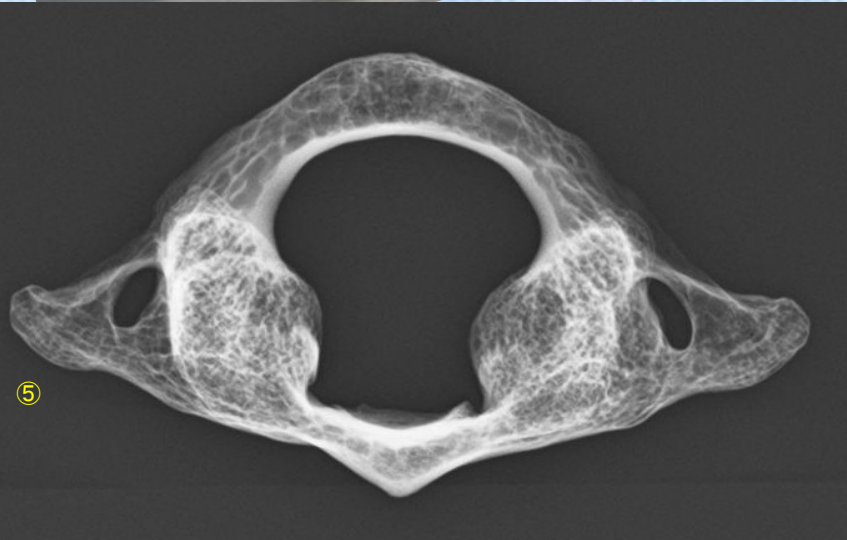
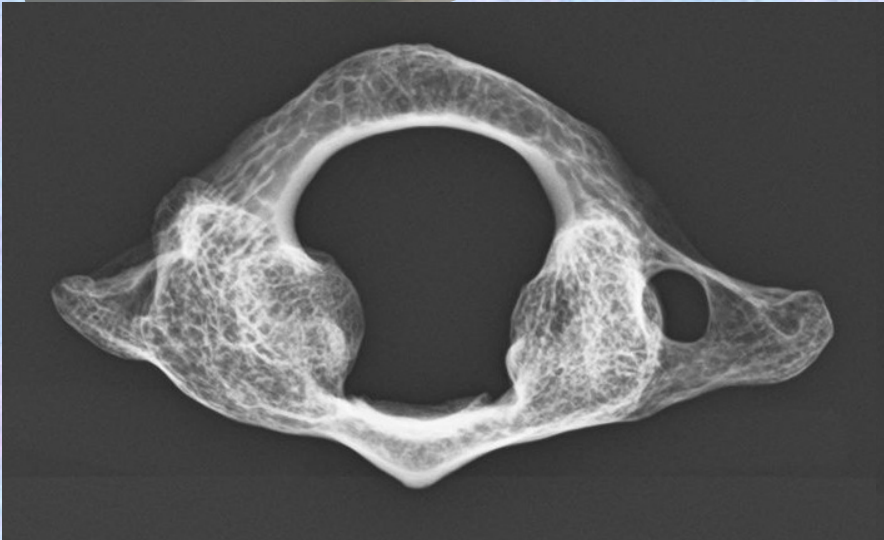
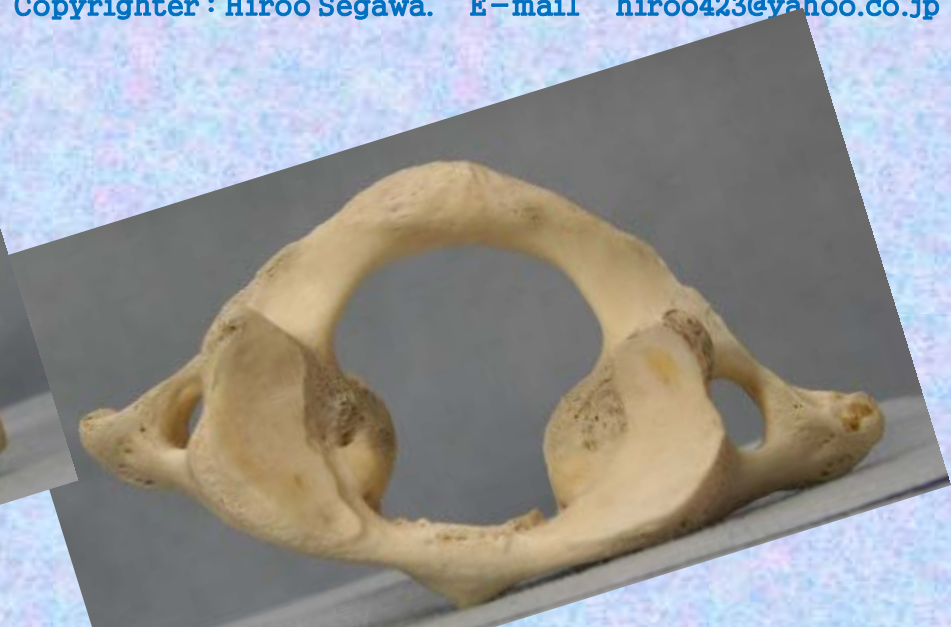

頸椎 C1 側面



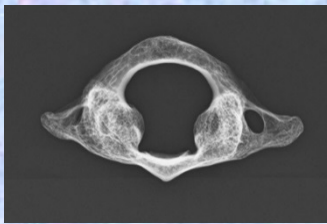
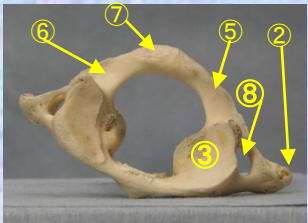
- ① 前弓 anterior arch
- ② 横突起 transverse process
- ③ 上関節窩 superior articular facet
- ④ 下関節窩 inferior articular facet
- ⑤ 後弓 posterior arch



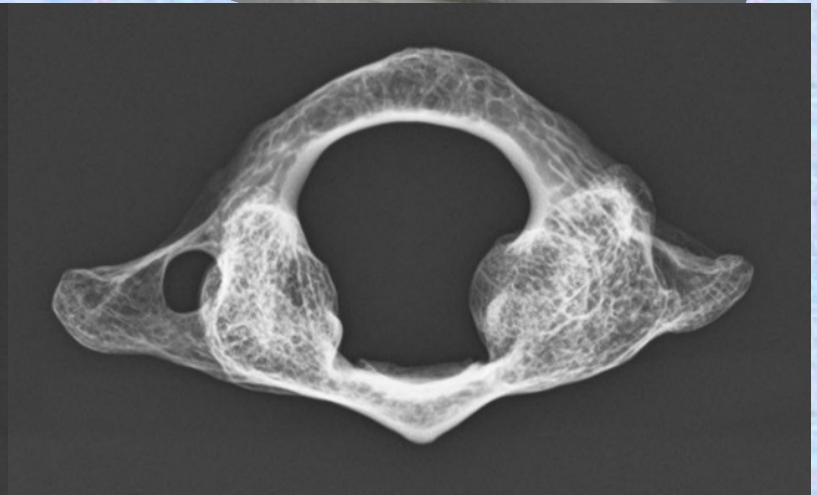
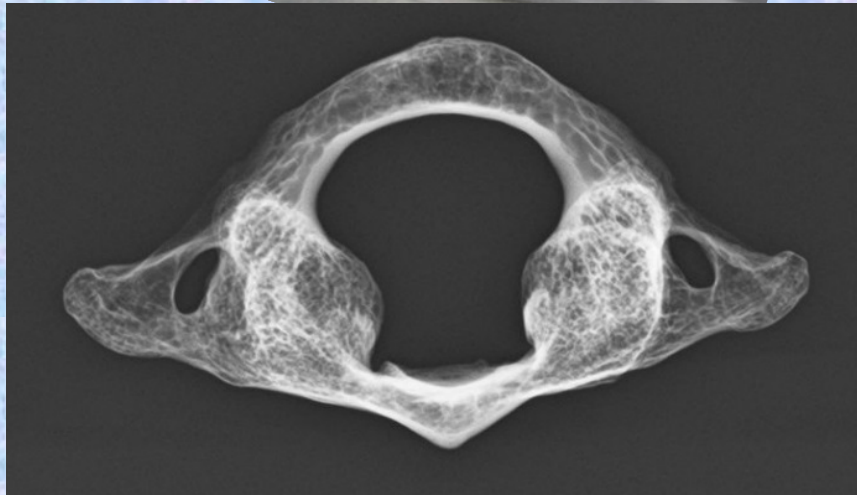
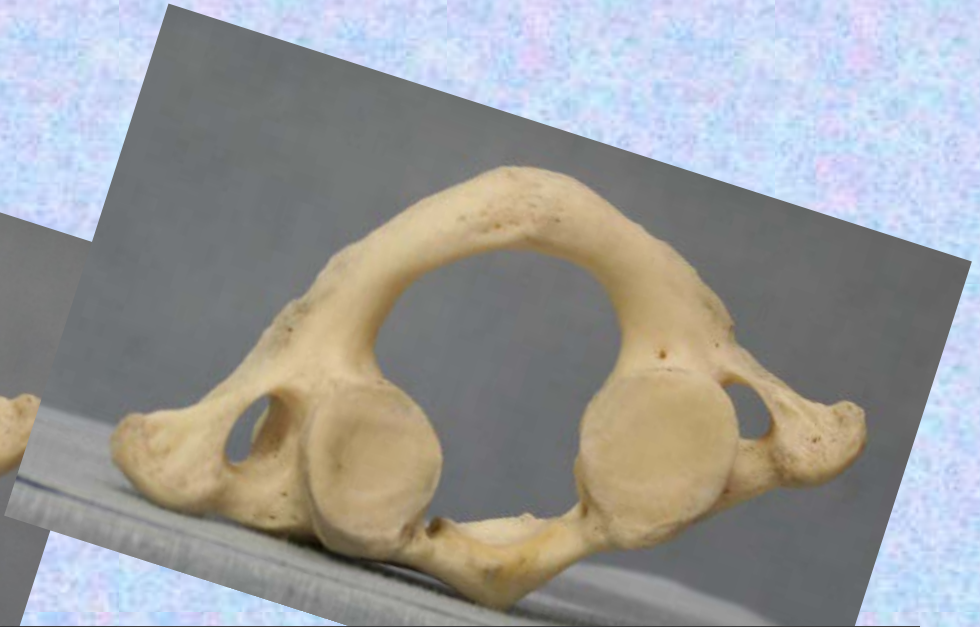
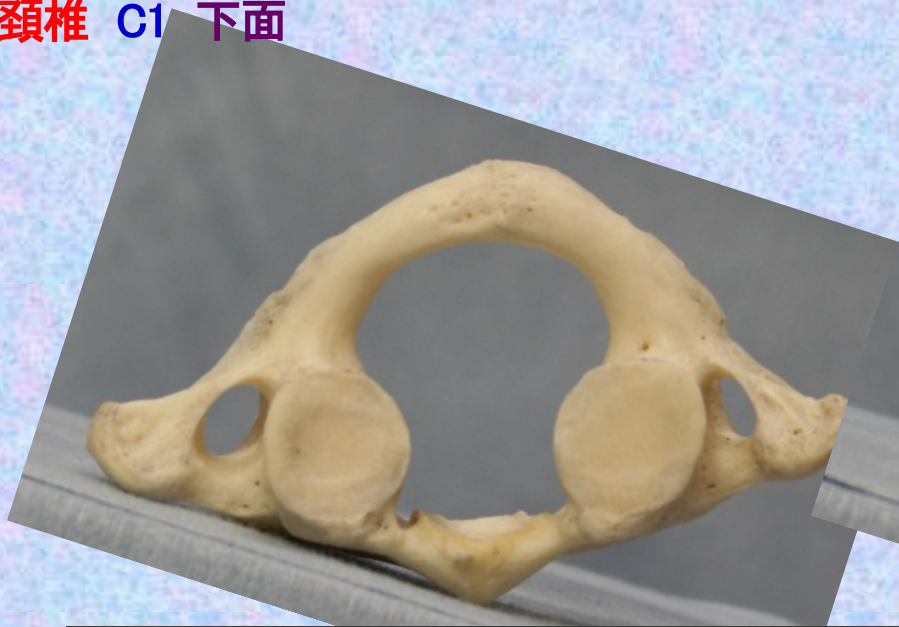
頸椎 C1 上面



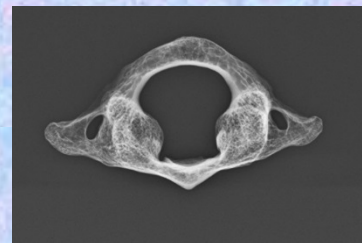
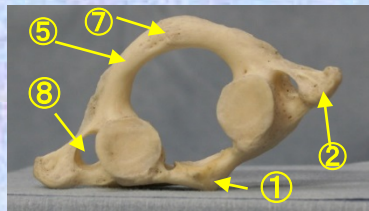
- 前弓 anterior arch
- 横突起 transverse process
- 上関節窩 superior articular facet
- 下関節窩 inferior articular facet
- 後弓 posterior arch
- 椎骨動脈溝 groove for vertebral artery
- 後結節 posterior tubercle
- 横突孔 foramen of transverse process



頸椎 C1 下面



- ① 前弓 anterior arch
- ② 横突起 transverse process
- ③ 上関節窩 superior articular facet
- ④ 下関節窩 inferior articular facet
- ⑤ 後弓 posterior arch
- ⑥ 椎骨動脈溝 vertebral artery groove
- ⑦ 後結節 posterior tubercle
- ⑧ 横突孔 transverse foramen



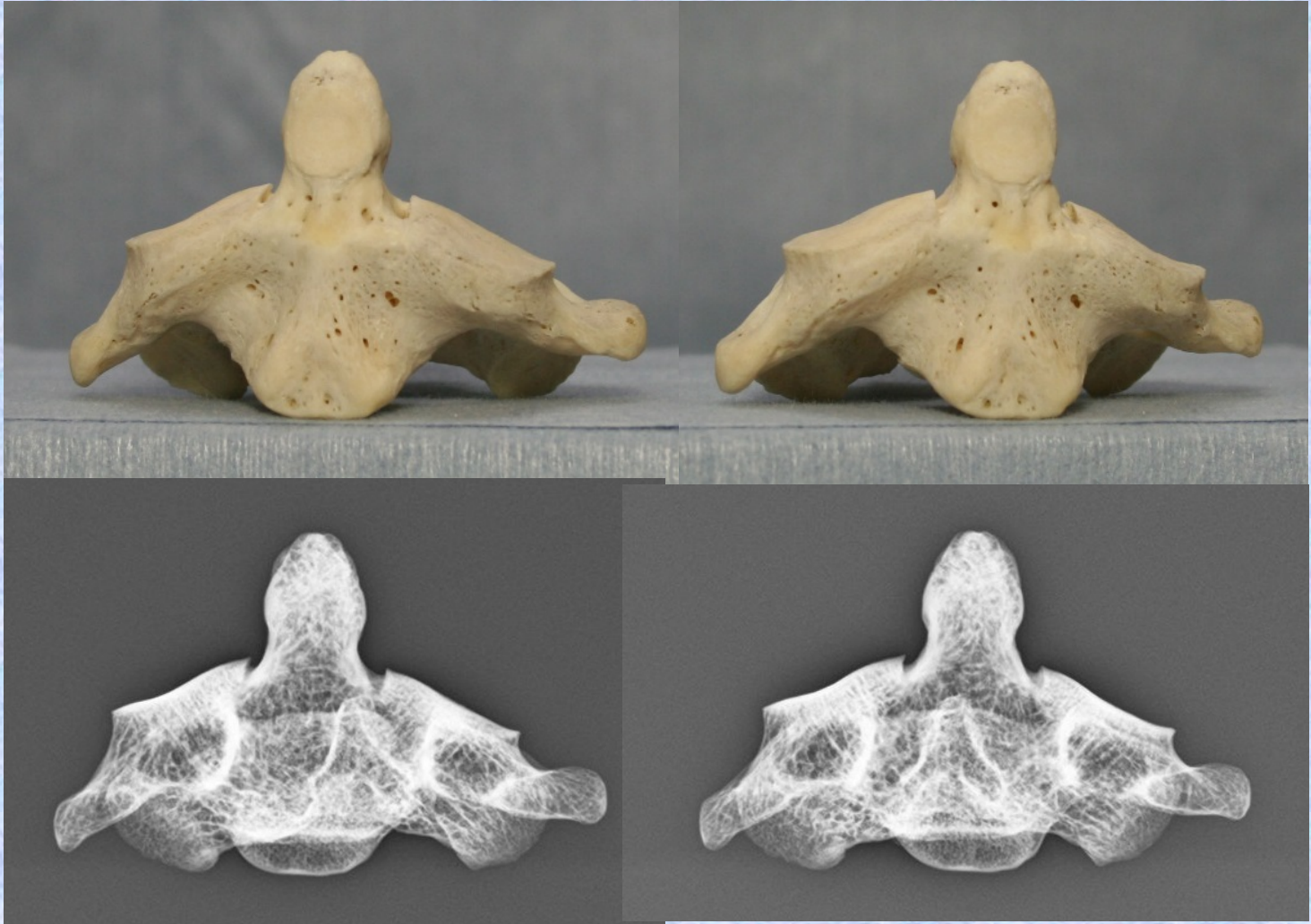
第2頸椎

Cervical vertebra 2

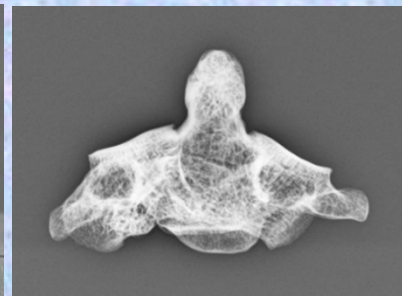
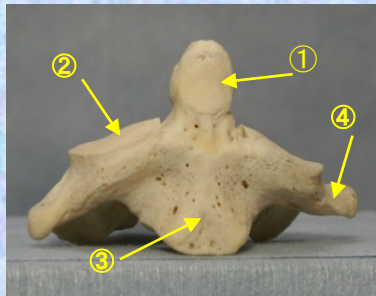
C 2



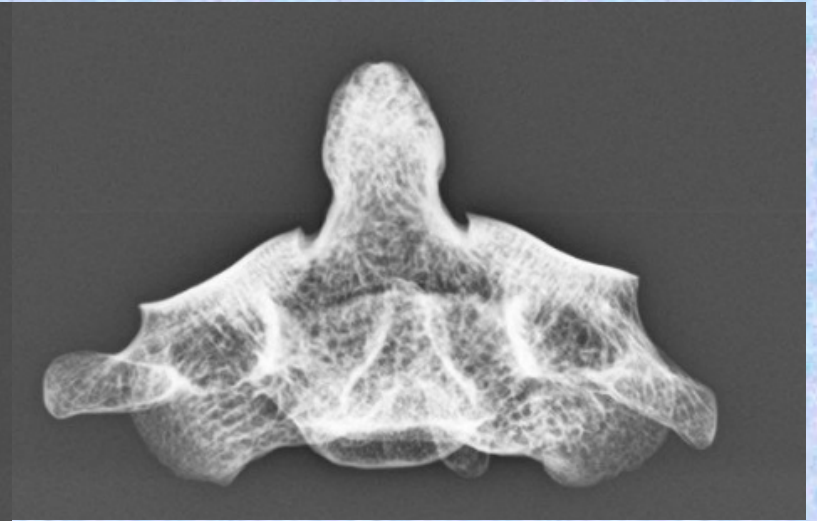
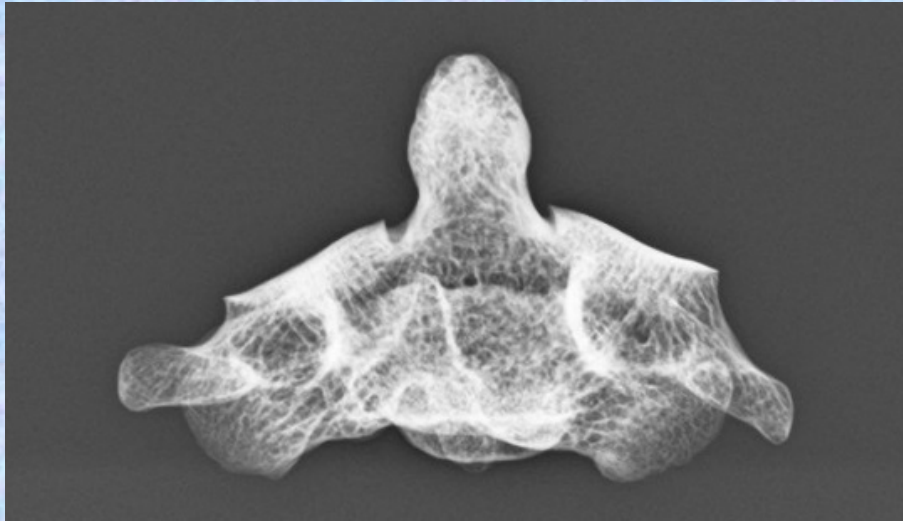
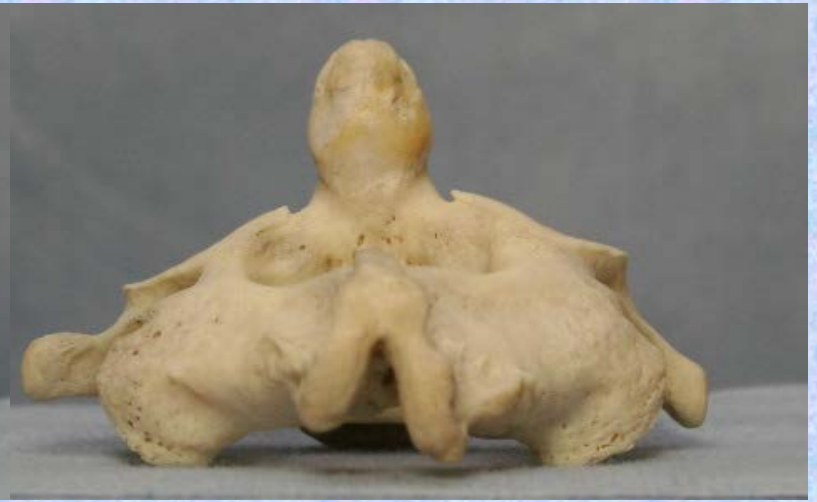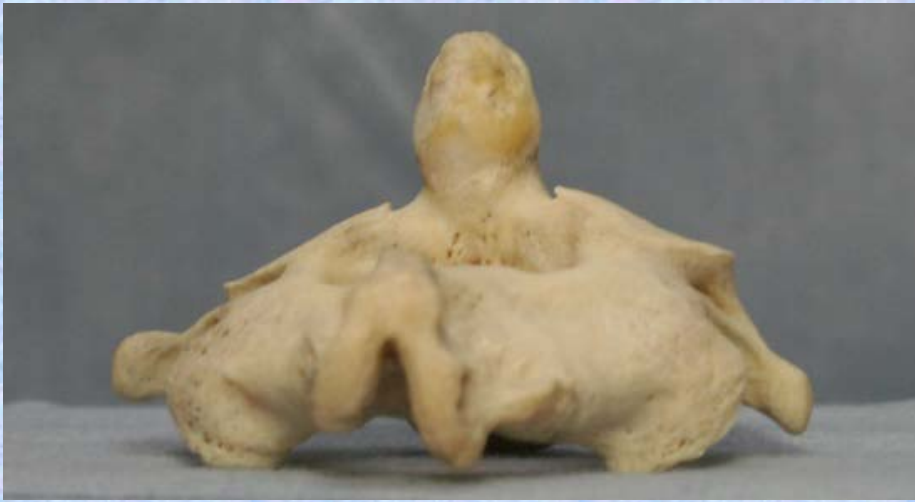頸椎 C2 前面



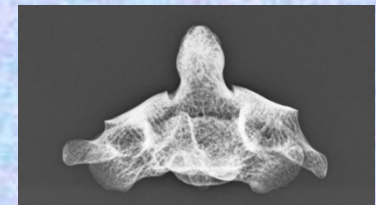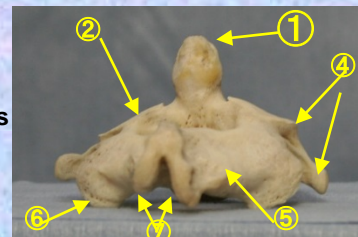
- ① 齒突起 dens
- ② 上關節面(上關節突起關節面)
superior articular surface
- ③ 椎體 transverse process
- ④ 橫突起と横突孔 transverse process
and foramen



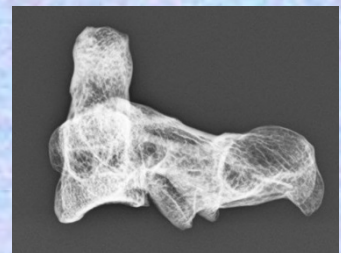
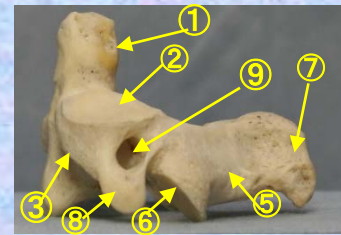
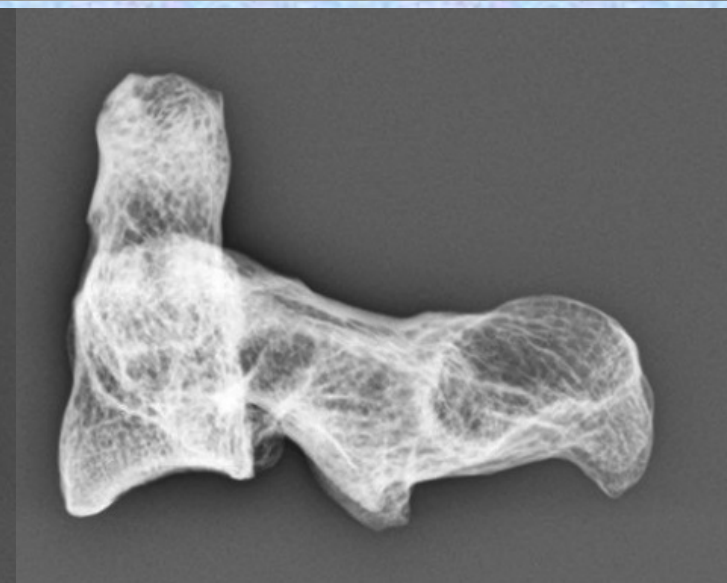
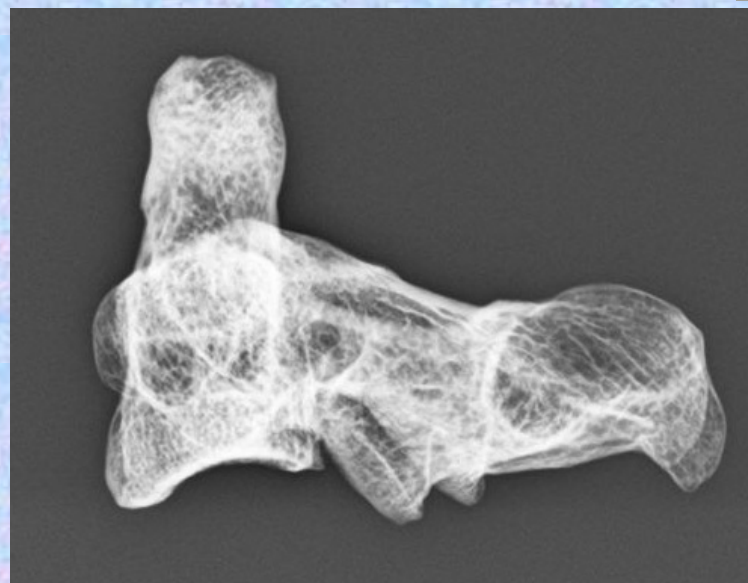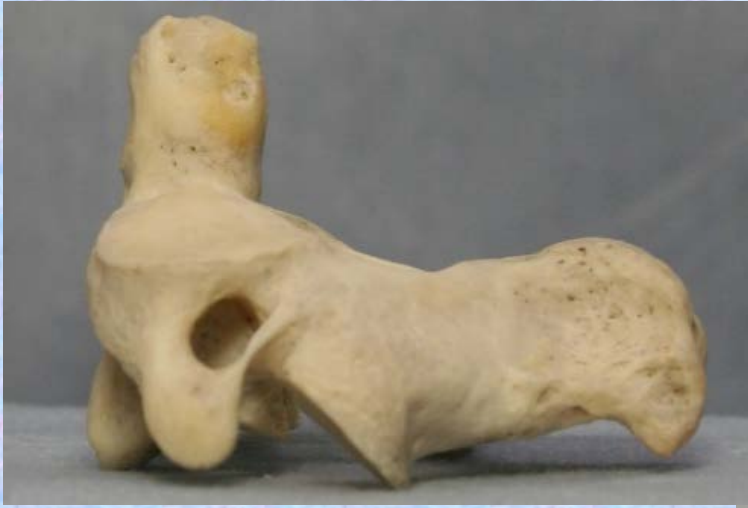頸椎 C2 後面



- ① 齒突起 dens
- ② 上關節面(上關節突起關節面) superior articular surface
- ③ 椎体 transverse process
- ④ 橫突起と横突孔 transverse process and foramen
- ⑤ 椎弓 vertebral arch
- ⑥ 下關節突起 inferior articular process
- ⑦ 棘突起(2分岐性) spinous process
- ⑧ 橫突起 transverse process
- ⑨ 横突孔 transverse foramen
- ⑩ 椎孔 vertebral foramen



頸椎 C2 側面

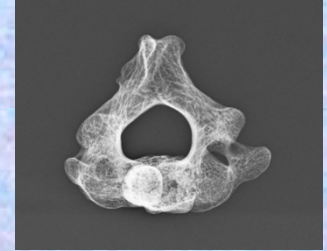
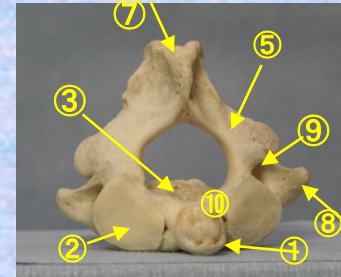
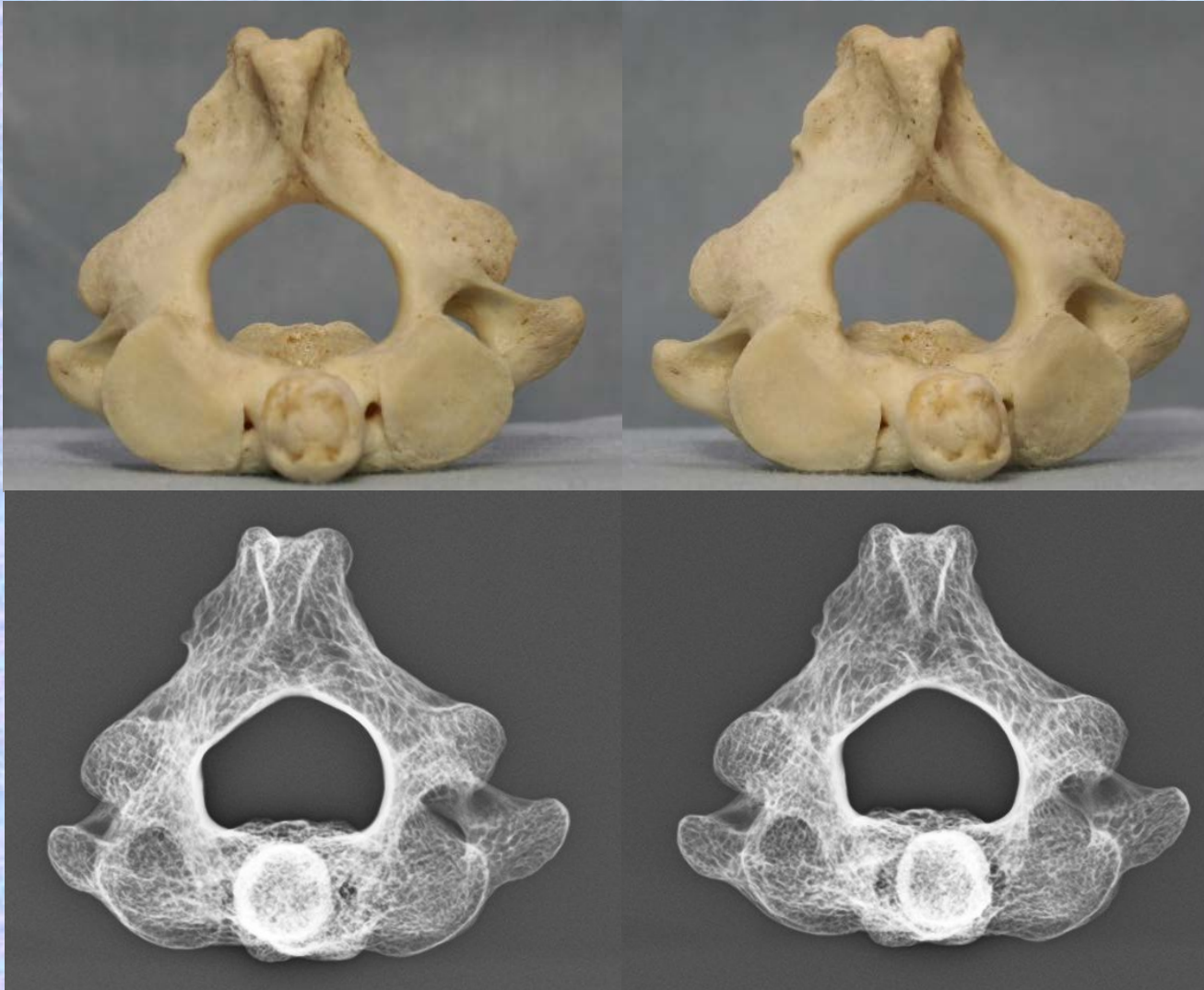


- ① 齒突起 dens
- ② 上關節面(上關節突起關節面) superior articular surface
- ③ 椎体 transverse process
- ④ 横突起と横突孔 transverse process and foramen

- ⑤ 椎弓 vertebral arch
- ⑥ 下關節突起 inferior articular process
- ⑦ 棘突起(2分岐性) spinous process
- ⑧ 横突起 transverse process
- ⑨ 横突孔 transverse foramen
- ⑩ 椎孔 vertebral foramen



頸椎 C2 上面

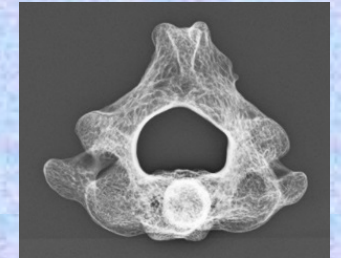
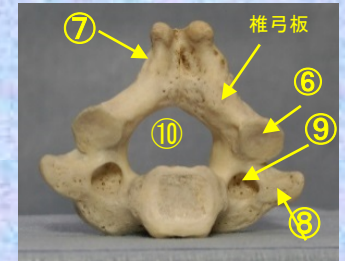
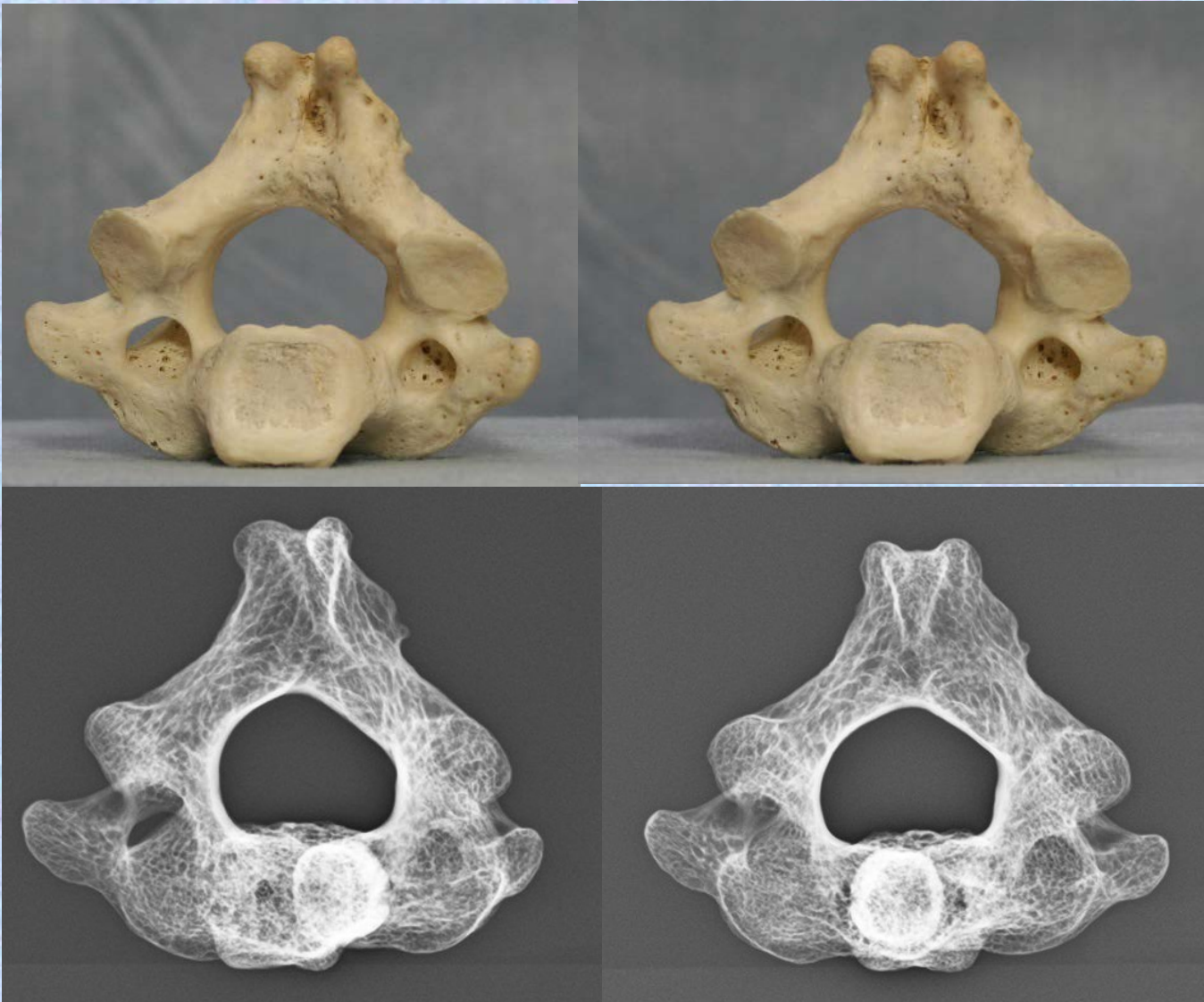


- ① 齒突起 dens
- ② 上關節面(上關節突起關節面)
superior articular surface
- ③ 椎体 transverse process
- ④ 横突起と横突孔 transverse process
and foramen

- ⑤ 椎弓 vertebral arch
- ⑥ 下關節突起 inferior articular process
- ⑦ 棘突起(2分岐性) spinous process
- ⑧ 横突起 transverse process
- ⑨ 横突孔 transverse foramen
- ⑩ 椎孔 vertebral foramen



頸椎 C2 下面



- ① 齒突起 dens
- ② 上關節面(上關節突起關節面)
superior articular surface
- ③ 椎体 transverse process
- ④ 横突起と横突孔 transverse process
and foramen

- ⑤ 椎弓 vertebral arch
- ⑥ 下關節突起 inferior articular process
- ⑦ 棘突起(2分岐性) spinous process
- ⑧ 横突起 transverse process
- ⑨ 横突孔 transverse foramen
- ⑩ 椎孔 vertebral foramen

第3頸椎

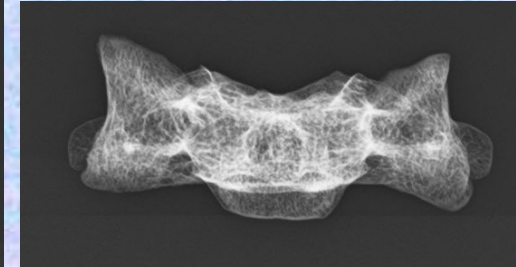
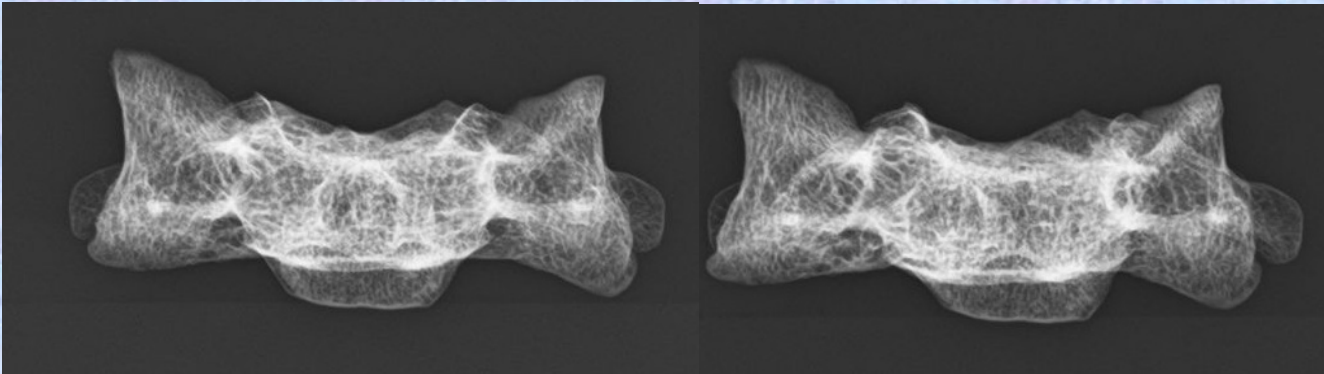
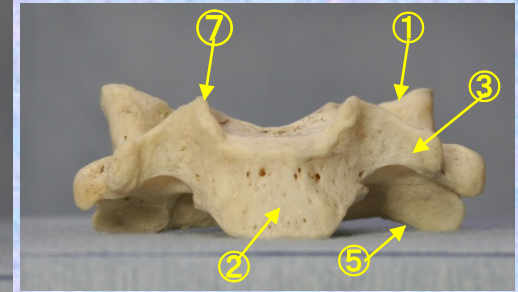
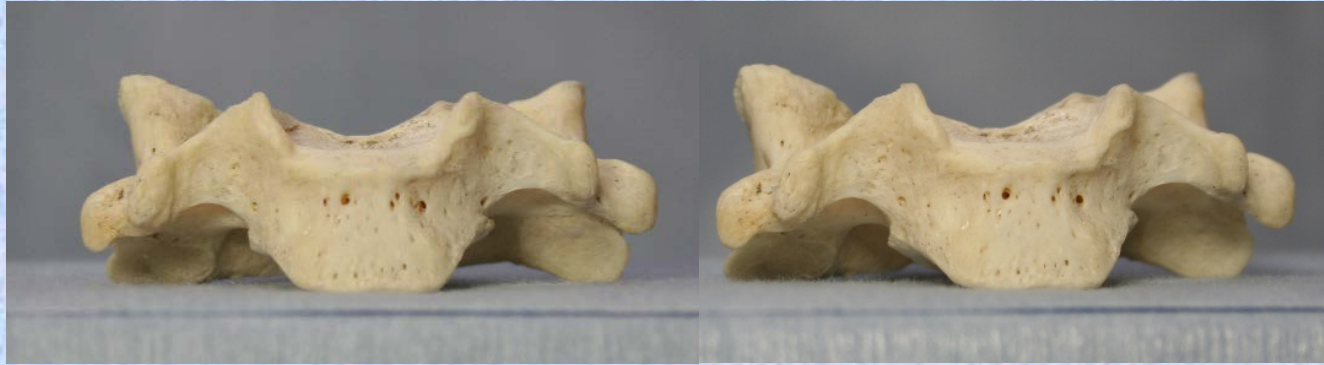Cervical vertebra 3

C 3



頸椎 C3 前面

前面

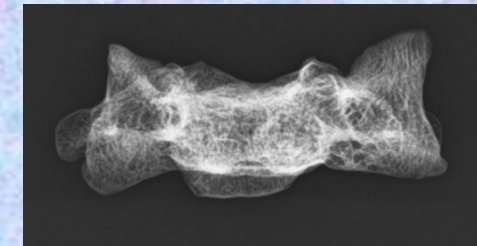
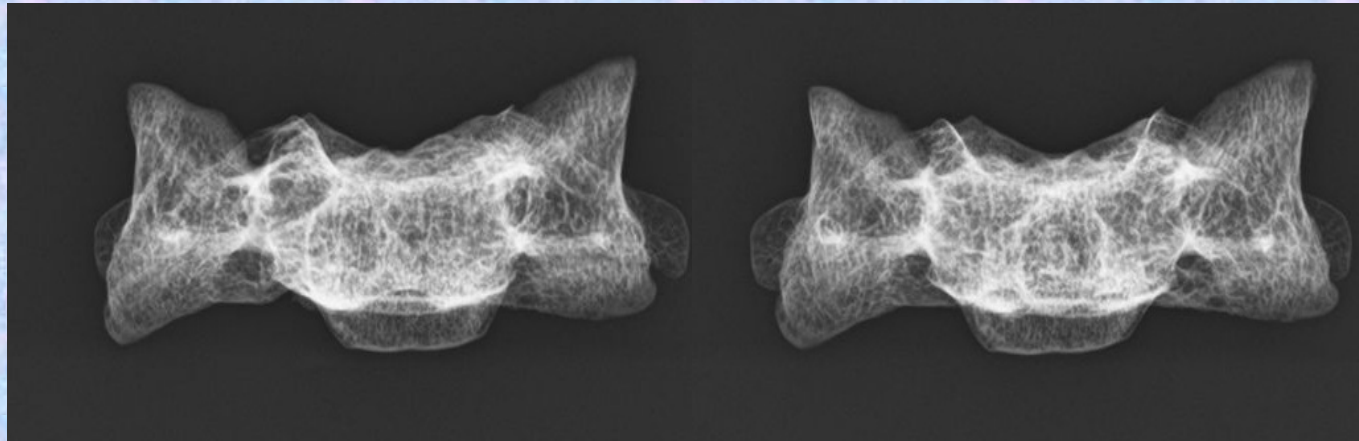
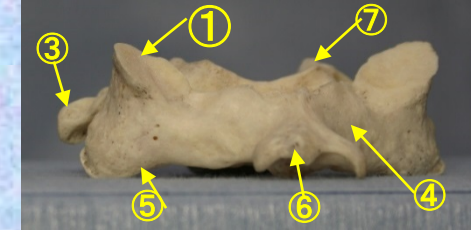
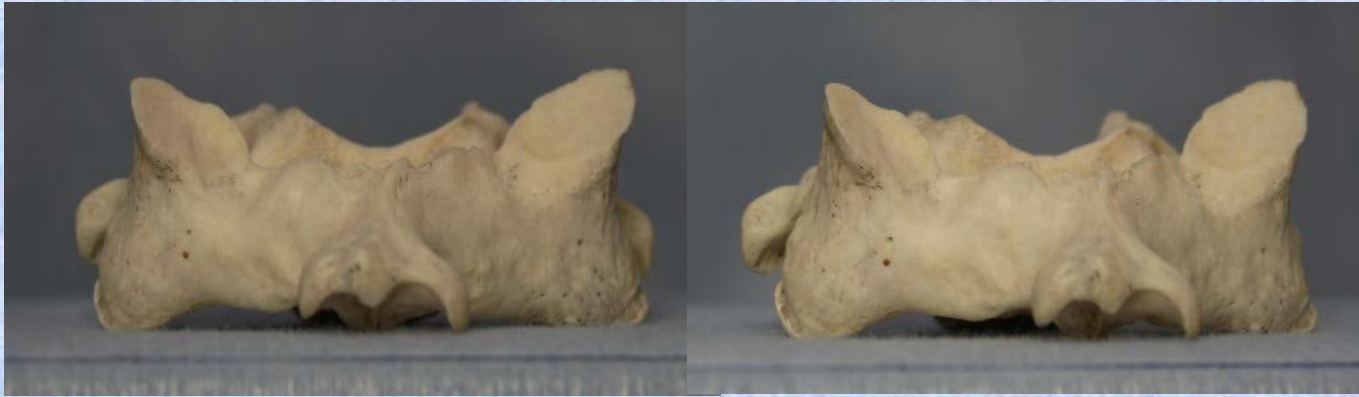

- ①上関節面(上関節突起関節面) superior articular surface
- ②椎体 transverse process
- ③横突起と横突孔 transverse process and foramen
- ④椎弓板 lamina
- ⑤下関節突起 inferior articular process
- ⑥棘突起 spinous process

- ⑦後外側唇 posteriolateral lip
- ⑧横突起 transverse process
- ⑨横突孔 transverse foramen
- ⑩上関節突起 superior articular process
- ⑪横突起の前結節 anterior tubercle of transverse process
- ⑫突起の後結節 posterior tubercle of transverse process
- ⑬椎孔 vertebral foramen
- ⑭椎弓根 pedicle



頸椎 C3 後面

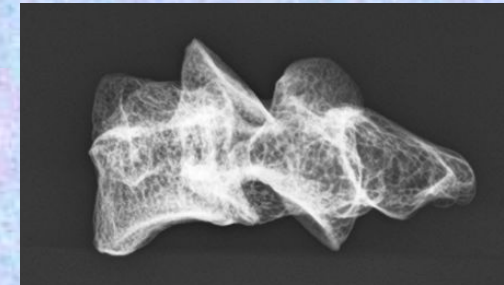
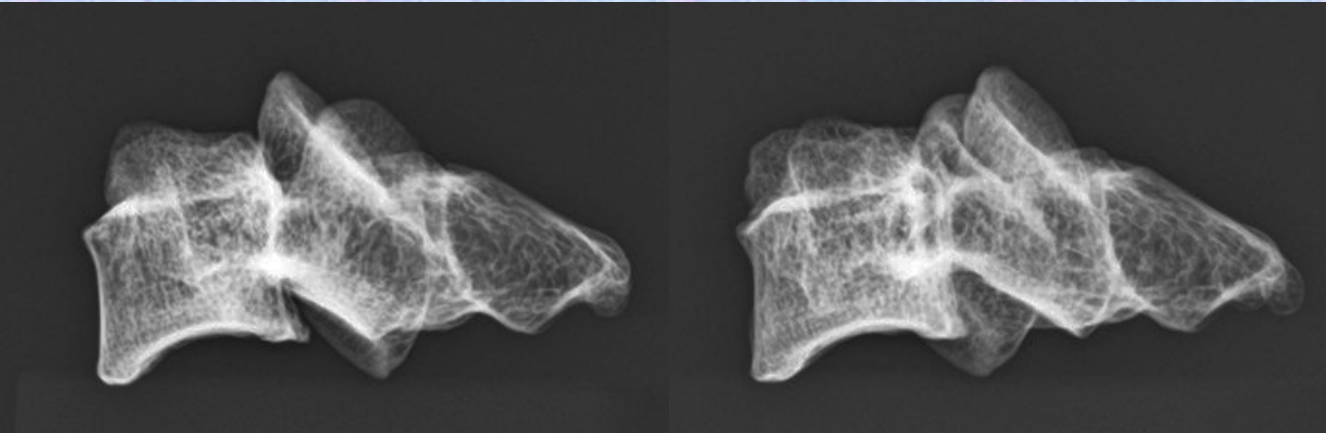
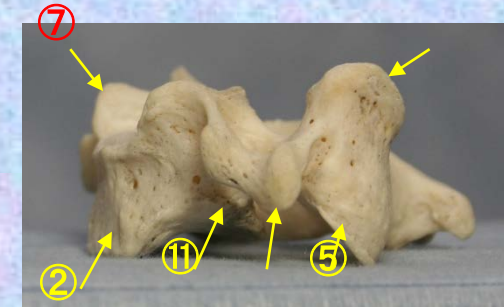
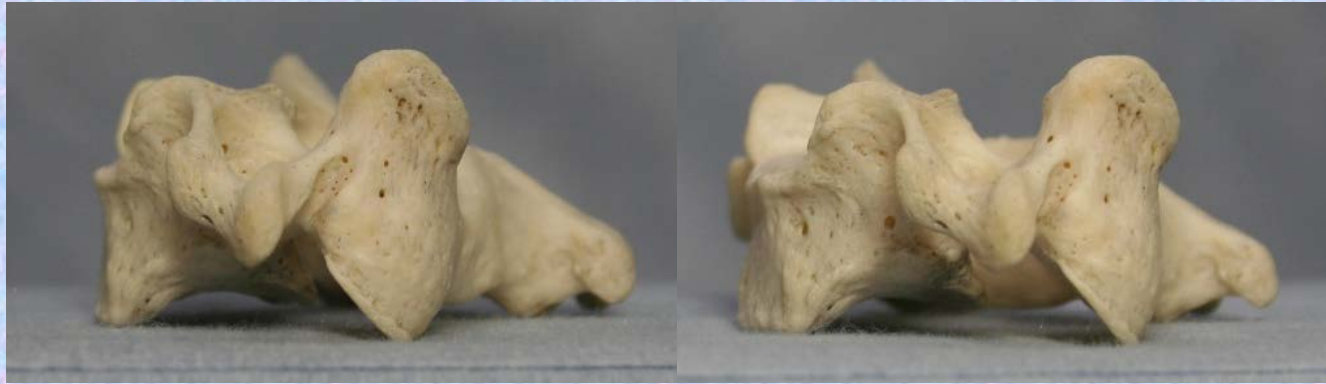

- ①上関節面(上関節突起関節面) superior articular surface
- ②椎体 transverse process
- ③横突起と横突孔 transverse process and foramen
- ④椎弓板 lamina
- ⑤下関節突起 inferior articular process
- ⑥棘突起 spinous process

- ⑦後外側唇 posteriolateral lip
- ⑧横突起 transverse process
- ⑨横突孔 transverse foramen
- ⑩上関節突起 superior articular process
- ⑪横突起の前結節 anterior tubercle of transverse process
- ⑫横突起の後結節 posterior tubercle of transverse process
- ⑬椎孔 vertebral foramen
- ⑭椎弓根 pedicle



頸椎 C3 側面

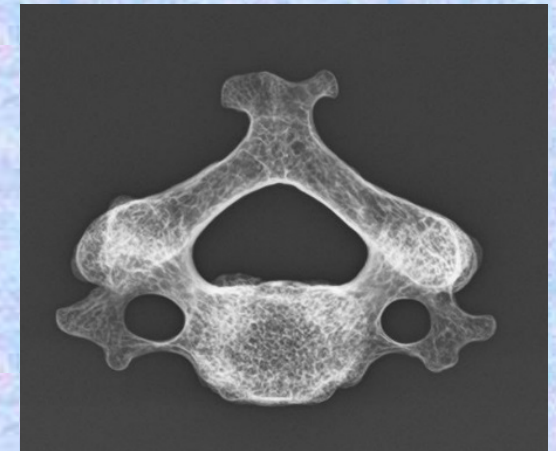
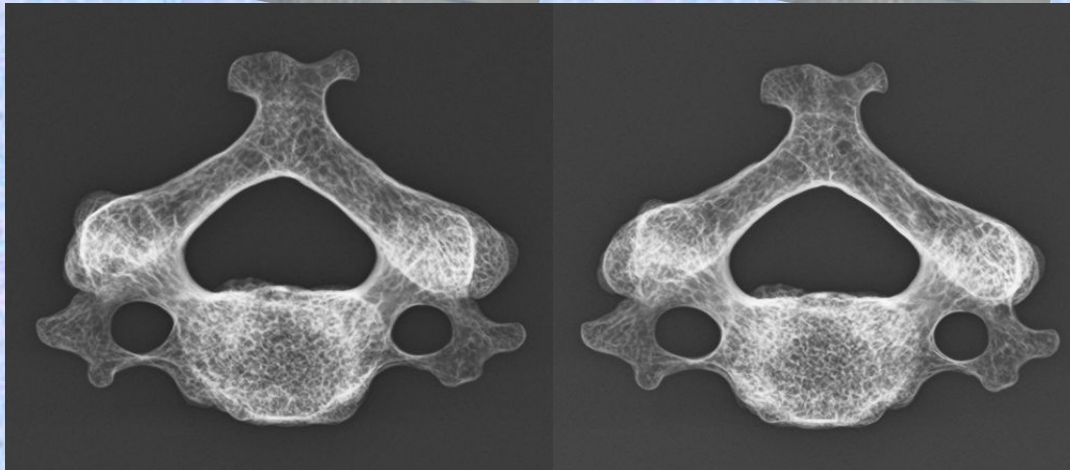
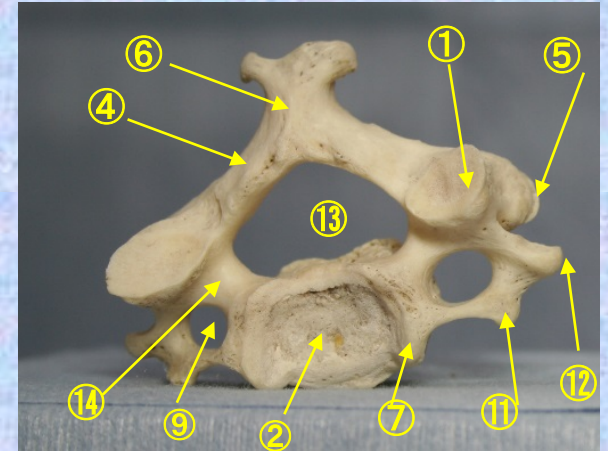
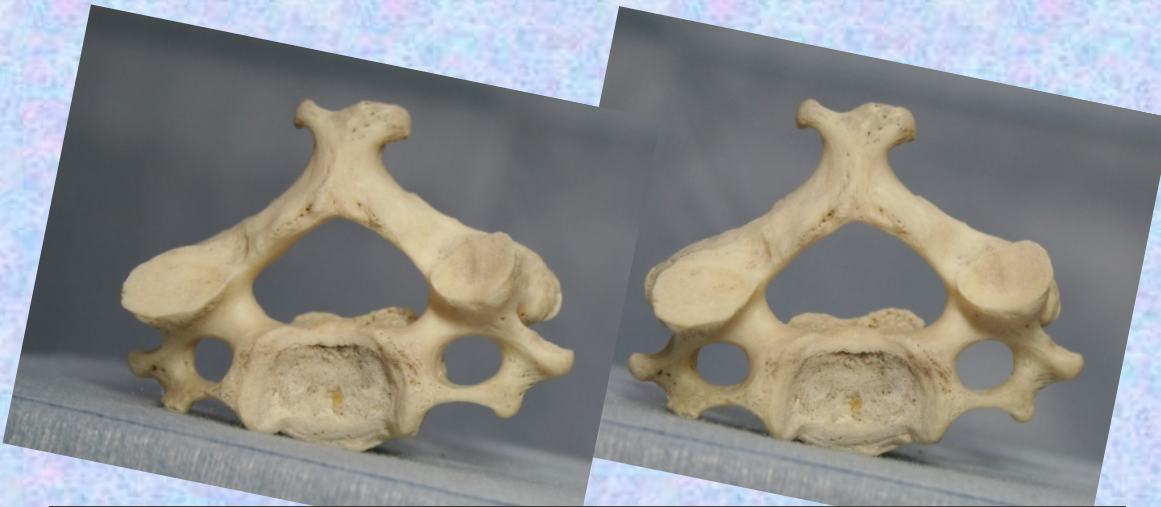


- ①上関節面(上関節突起関節面) superior articular surface
- ②椎体 transverse process
- ③横突起と横突孔 transverse process and foramen
- ④椎弓板 lamina
- ⑤下関節突起 inferior articular process
- ⑥棘突起 spinous process

- ⑦後外側唇 posteriolateral lip
- ⑧横突起 transverse process
- ⑨横突孔 transverse foramen
- ⑩上関節突起 superior articular process
- ⑪横突起の前結節 anterior tubercle of transverse process
- ⑫突起の後結節 posterior tubercle of transverse process
- ⑬椎孔 vertebral foramen
- ⑭椎弓根 pedicle



頸椎 C3 上面

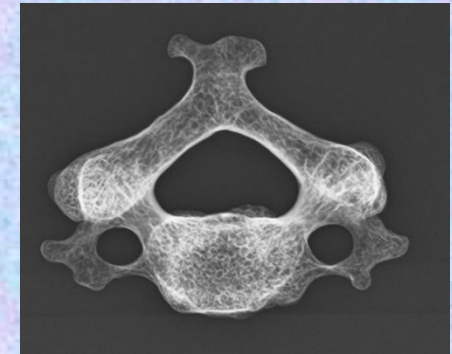
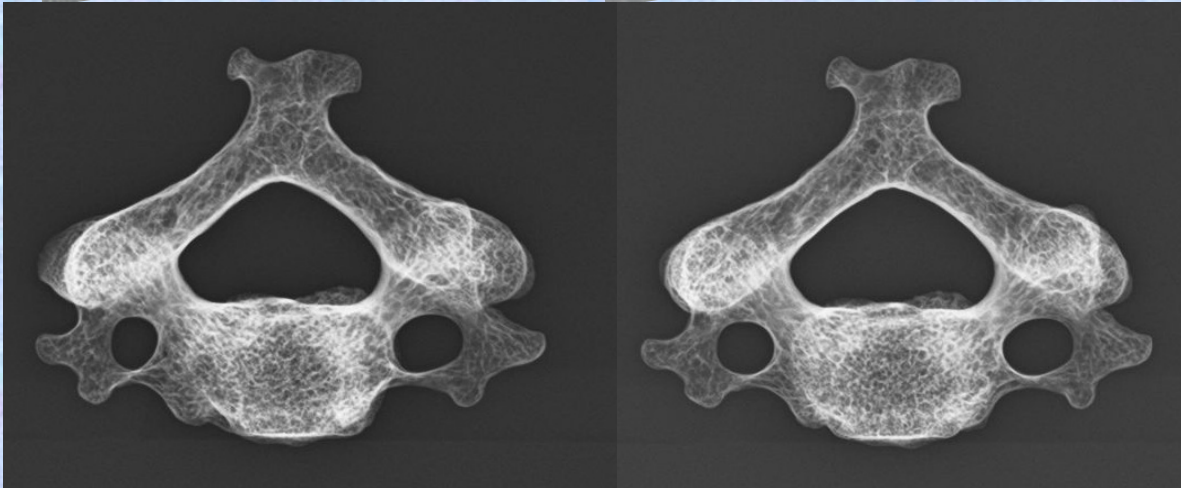
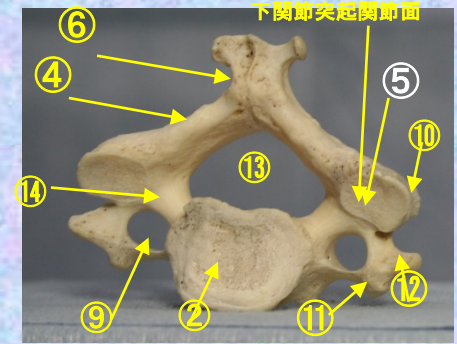
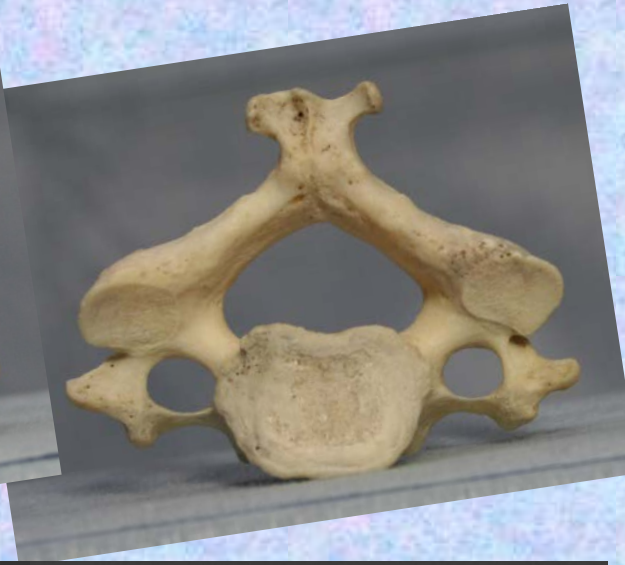
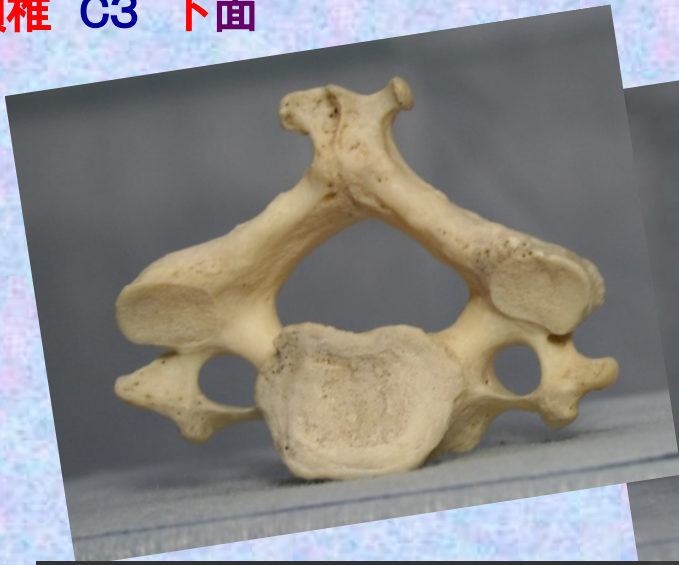
- ①上関節面(上関節突起関節面) superior articular surface
- ②椎体 transverse process
- ③横突起と横突孔 transverse process and foramen
- ④椎弓板 lamina
- ⑤下関節突起 inferior articular process
- ⑥棘突起 spinous process

- ⑦後外側唇 posteriolateral lip
- ⑧横突起 transverse process
- ⑨横突孔 transverse foramen
- ⑩上関節突起 superior articular process
- ⑪横突起の前結節 anterior tubercle of transverse process
- ⑫横突起の後結節 posterior tubercle of transverse process
- ⑬椎孔 vertebral foramen
- ⑭椎弓根 pedicle



頸椎 C3 下面



- ①上関節面(上関節突起関節面) superior articular surface
- ②椎体 transverse process
- ③横突起と横突孔 transverse process and foramen
- ④椎弓板 lamina
- ⑤下関節突起 inferior articular process
- ⑥棘突起 spinous process

- ⑦後外側唇 posteriolateral lip
- ⑧横突起 transverse process
- ⑨横突孔 transverse foramen
- ⑩上関節突起 superior articular process
- ⑪横突起の前結節 anterior tubercle of transverse process
- ⑫横突起の後結節 posterior tubercle of transverse process
- ⑬椎孔 vertebral foramen
- ⑭椎弓根 pedicle



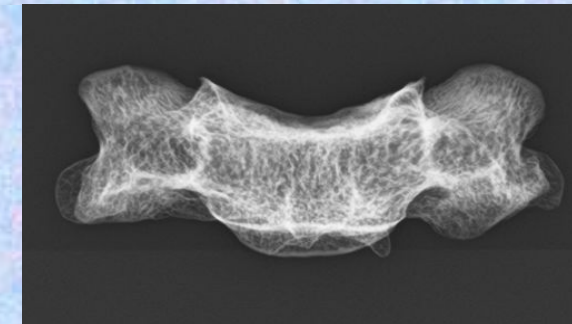
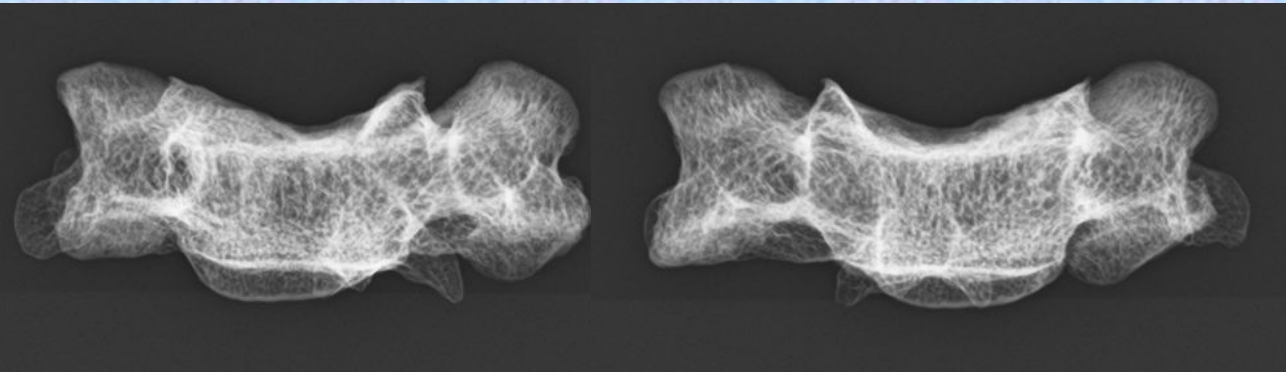
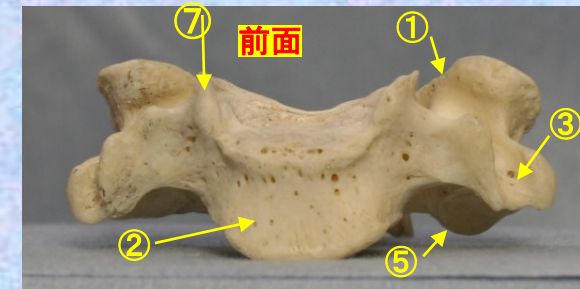
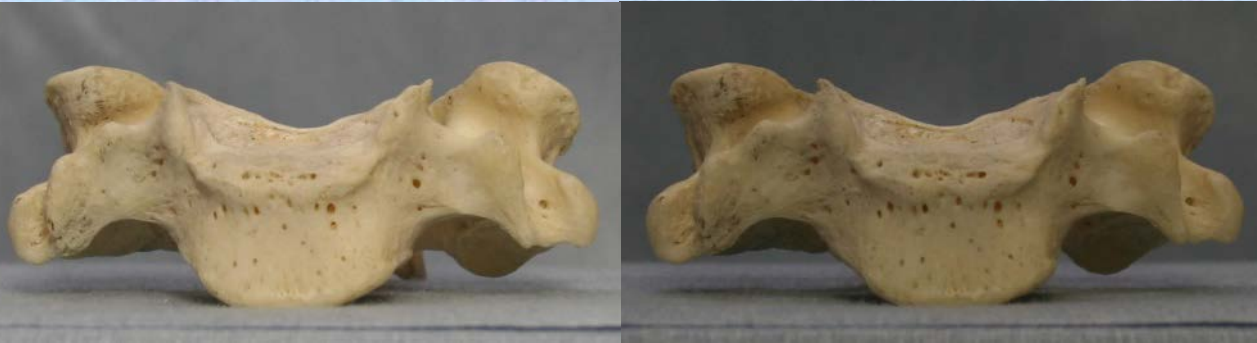第4頸椎

Cervical vertebra 4

C 4

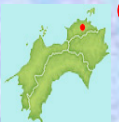

頸椎 C4 前面

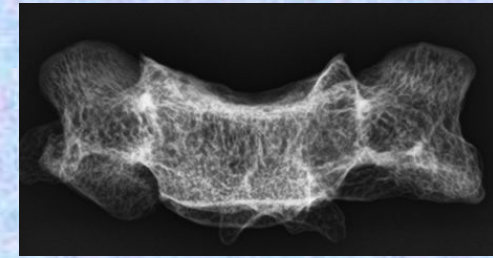
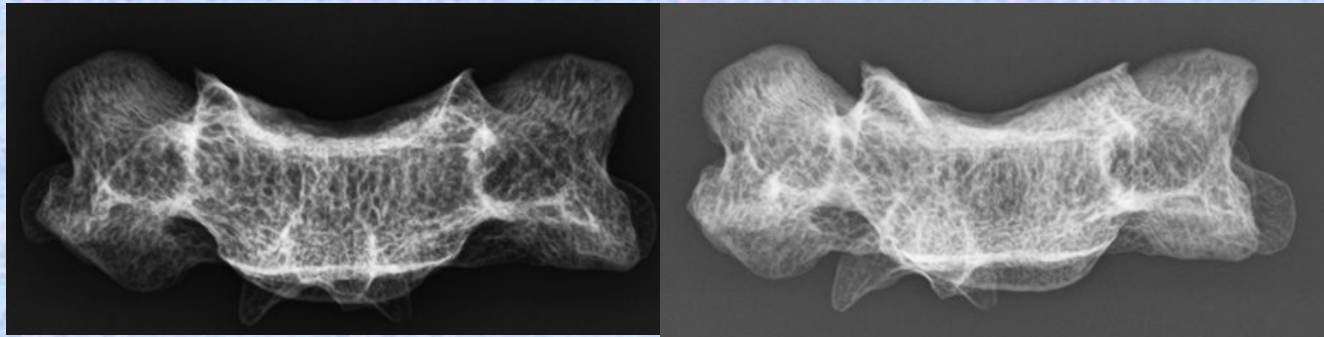
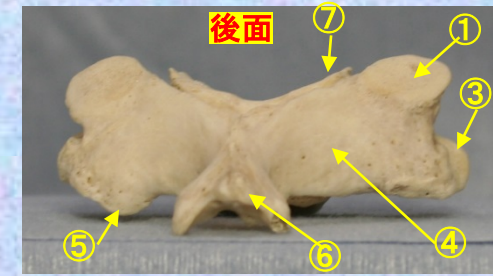


- ①上関節面(上関節突起関節面) superior articular surface
- ②椎体 transverse process
- ③横突起と横突孔 transverse process and foramen
- ④椎弓板 lamina
- ⑤下関節突起 inferior articular process
- ⑥棘突起 spinous process

- ⑦後外側唇 posteriolateral lip
- ⑧横突起 transverse process
- ⑨横突孔 transverse foramen
- ⑩上関節突起 superior articular process
- ⑪横突起の前結節 anterior tubercle of transverse process
- ⑫横突起の後結節 posterior tubercle of transverse process
- ⑬椎孔 vertebral foramen
- ⑭椎弓根 pedicle



頸椎 C4 後面

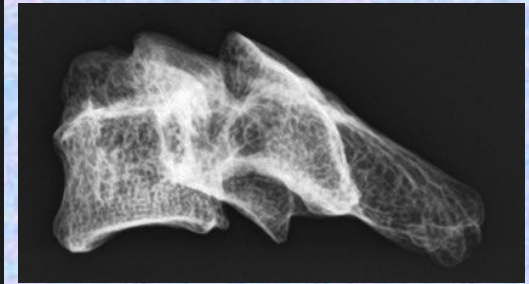
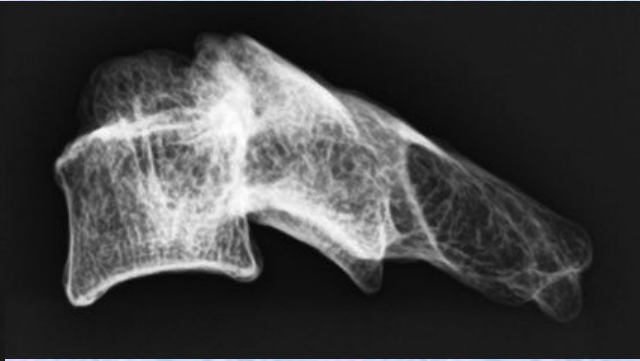
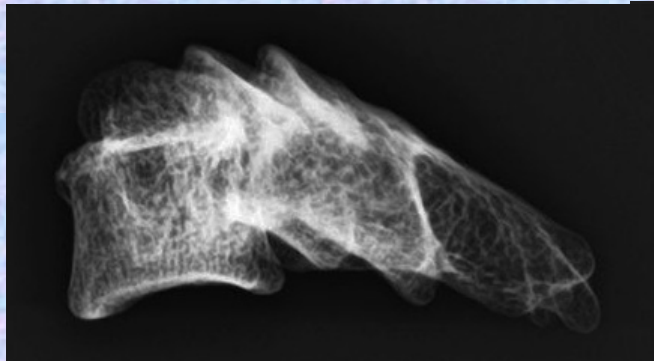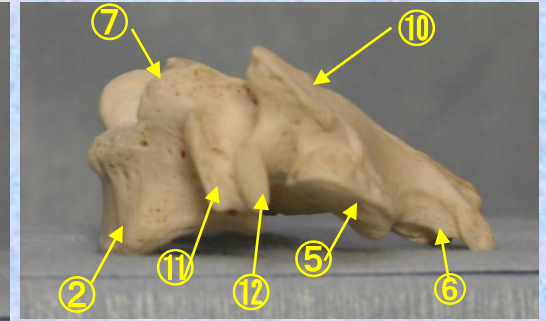

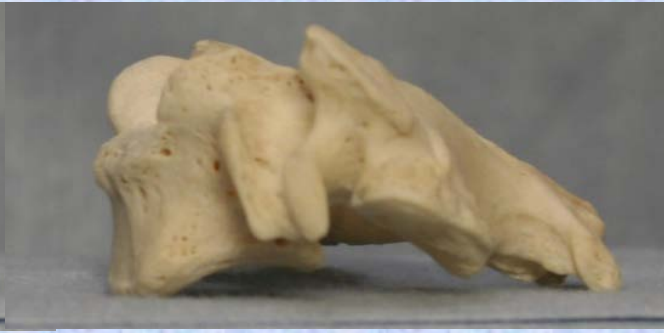
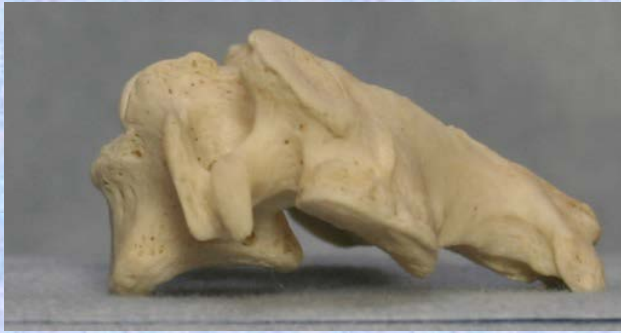- ①上関節面(上関節突起関節面) superior articular surface
- ②椎体 transverse process
- ③横突起と横突孔 transverse process and foramen
- ④椎弓板 lamina
- ⑤下関節突起 inferior articular process
- ⑥棘突起 spinous process

- ⑦後外側唇 posteriolateral lip
- ⑧横突起 transverse process
- ⑨横突孔 transverse foramen
- ⑩上関節突起 superior articular process
- ⑪横突起の前結節 anterior tubercle of transverse process
- ⑫横突起の後結節 posterior tubercle of transverse process
- ⑬椎孔 vertebral foramen
- ⑭椎弓根 pedicle



頸椎 C4 側面

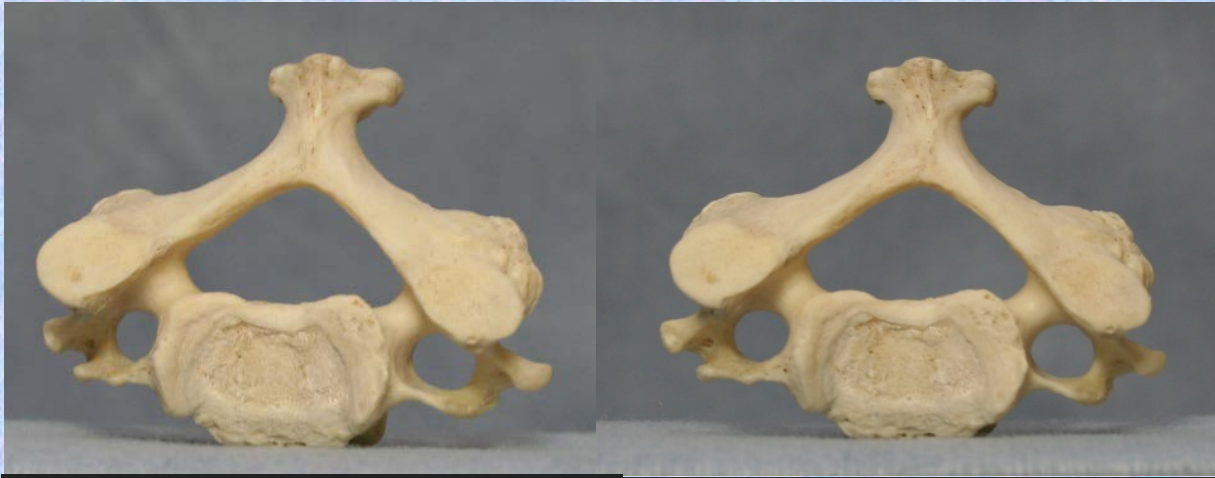


- ①上関節面(上関節突起関節面) superior articular surface
- ②椎体 transverse process
- ③横突起と横突孔 transverse process and foramen
- ④椎弓板 lamina
- ⑤下関節突起 inferior articular process
- ⑥棘突起 spinous process

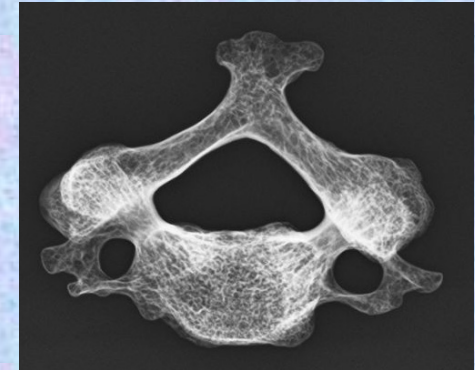
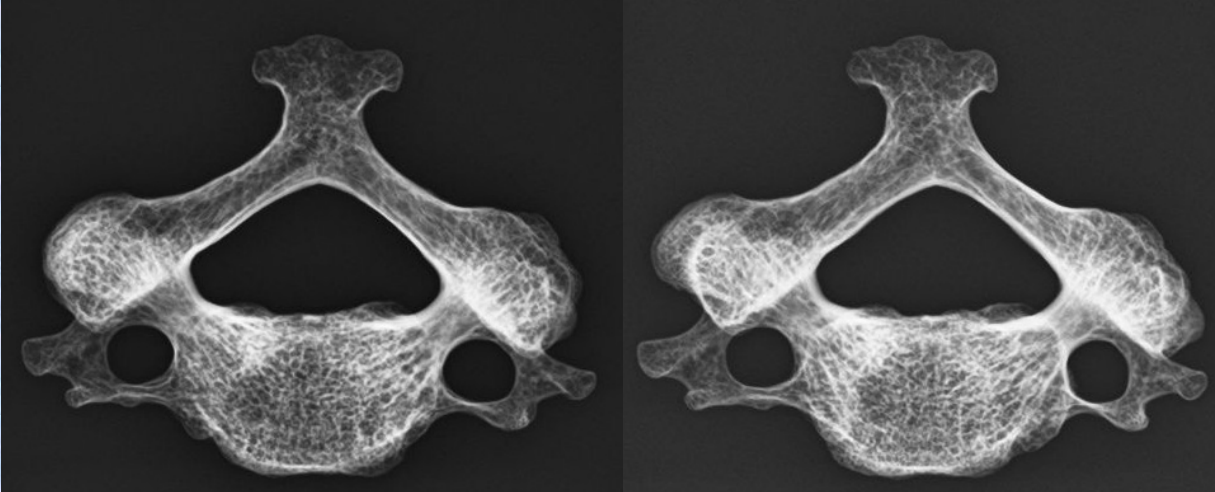
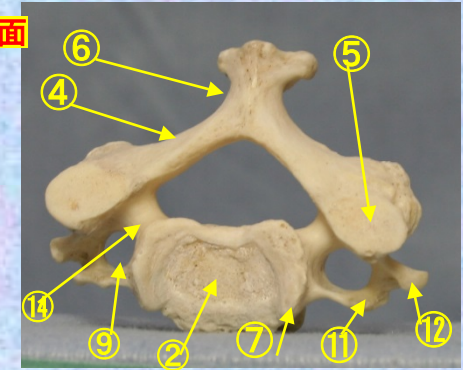
- ⑦後外側唇 posteriolateral lip
- ⑧横突起 transverse process
- ⑨横突孔 transverse foramen
- ⑩上関節突起 superior articular process
- ⑪横突起の前結節 anterior tubercle of transverse process
- ⑫横突起の後結節 posterior tubercle of transverse process
- ⑬椎孔 vertebral foramen
- ⑭椎弓根 pedicle



頸椎 C4 上面

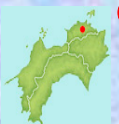

上面

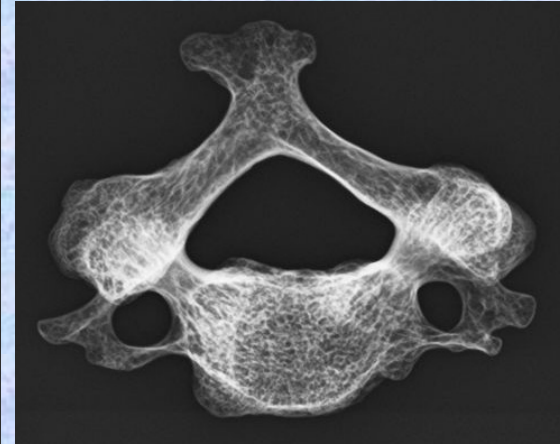
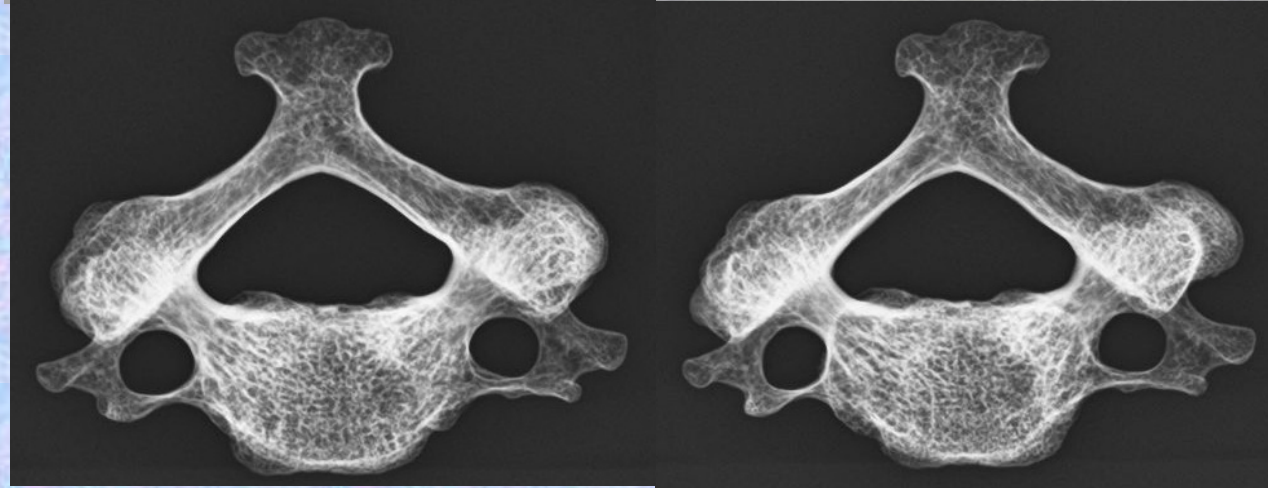
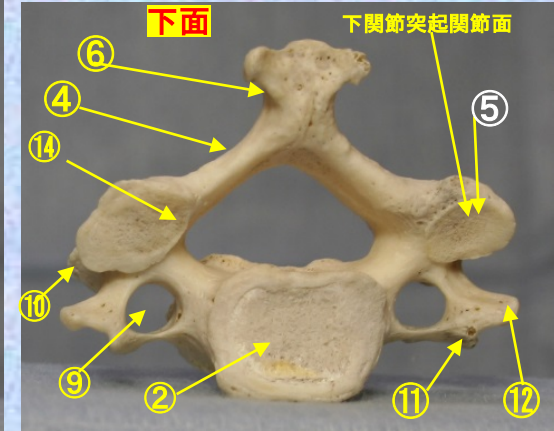
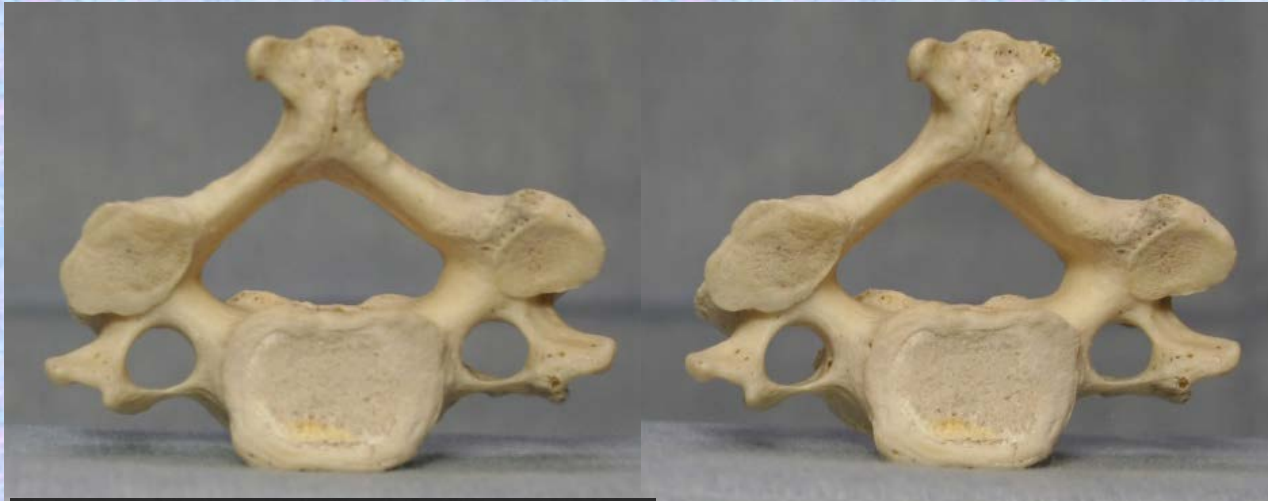

- ①上関節面(上関節突起関節面) superior articular surface
- ②椎体 transverse process
- ③横突起と横突孔 transverse process and foramen
- ④椎弓板 lamina
- ⑤下関節突起 inferior articular process
- ⑥棘突起 spinous process

- ⑦後外側唇 posteriolateral lip
- ⑧横突起 transverse process
- ⑨横突孔 transverse foramen
- ⑩上関節突起 superior articular process
- ⑪横突起の前結節 anterior tubercle of transverse process
- ⑫横突起の後結節 posterior tubercle of transverse process
- ⑬椎孔 vertebral foramen
- ⑭椎弓根 pedicle



頸椎 C4 下面



- ①上関節面(上関節突起関節面) superior articular surface
- ②椎体 transverse process
- ③横突起と横突孔 transverse process and foramen
- ④椎弓板 lamina
- ⑤下関節突起 inferior articular process
- ⑥棘突起 spinous process

- ⑦後外側唇 posteriolateral lip
- ⑧横突起 transverse process
- ⑨横突孔 transverse foramen
- ⑩上関節突起 superior articular process
- ⑪横突起の前結節 anterior tubercle of transverse process
- ⑫横突起の後結節 posterior tubercle of transverse process
- ⑬椎孔 vertebral foramen
- ⑭椎弓根 pedicle



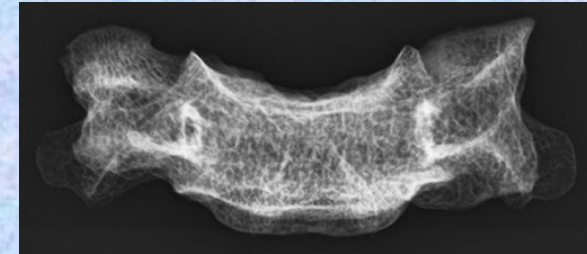
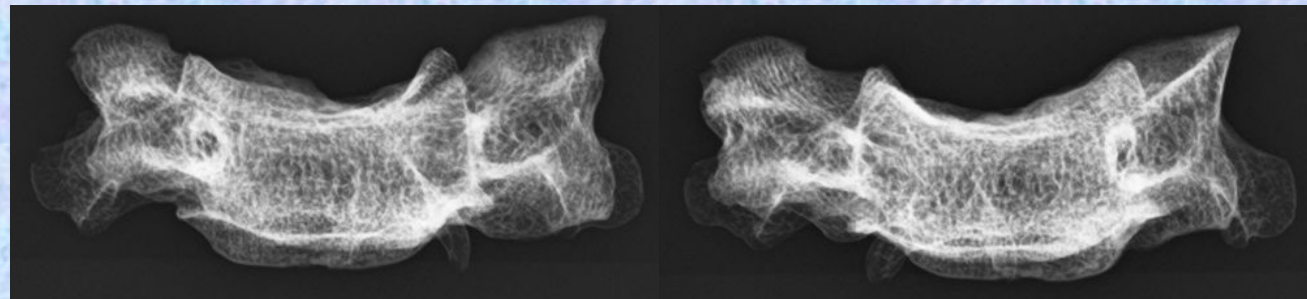
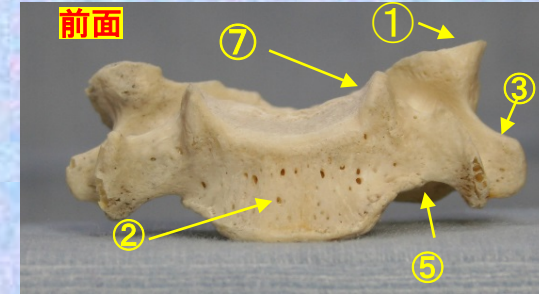
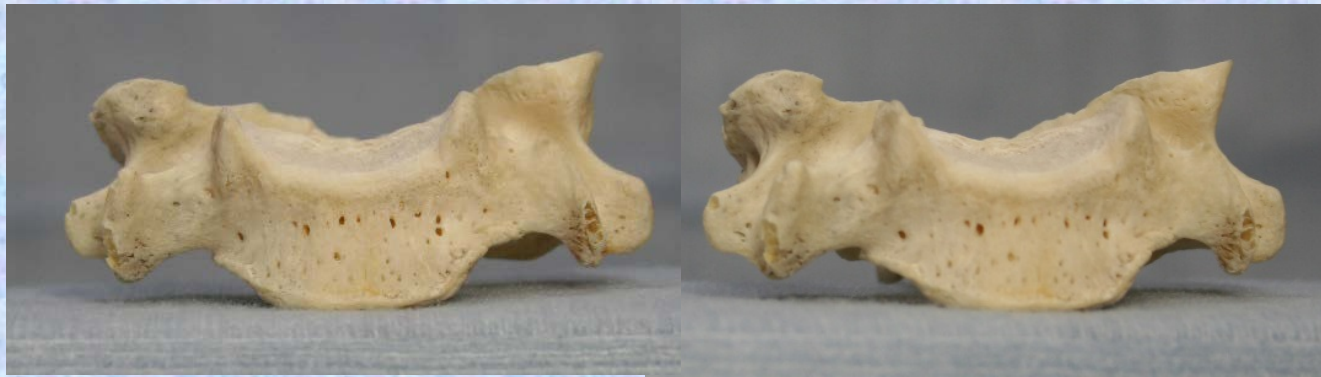
第5頸椎

Cervical vertebra 5

C5



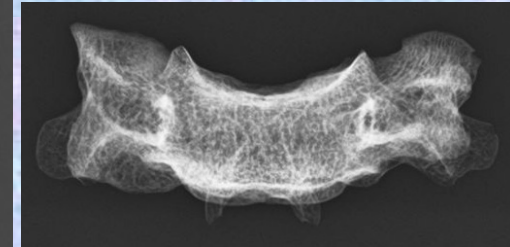
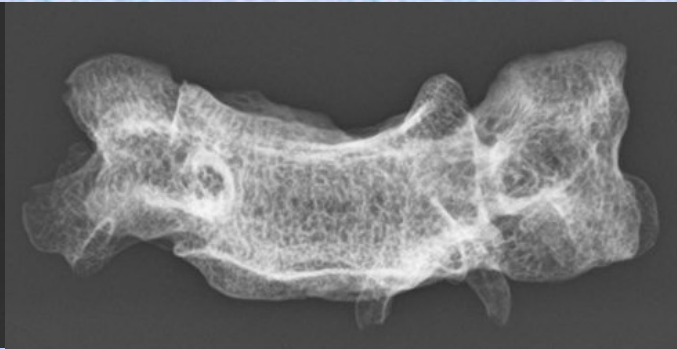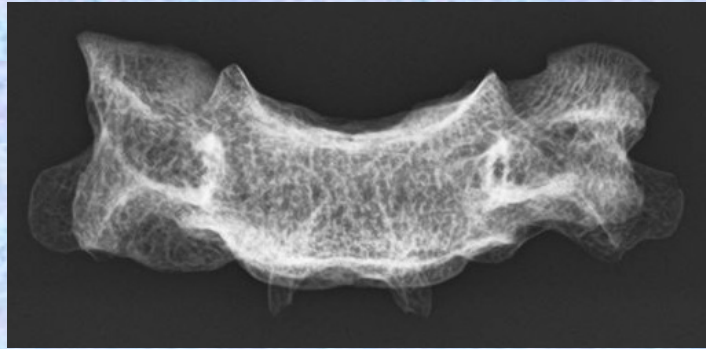
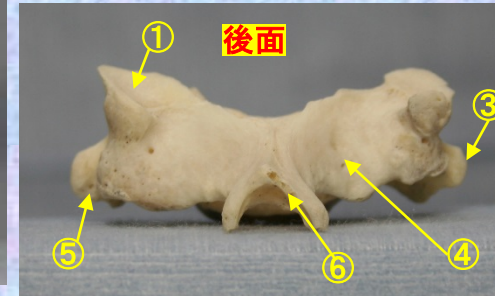
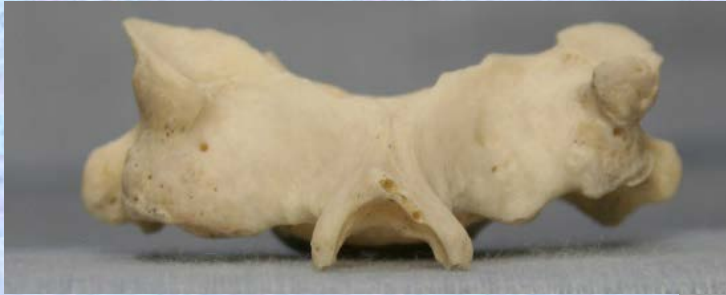頸椎 C5 正面



- ①上関節面(上関節突起関節面) superior articular surface
- ②椎体 transverse process
- ③横突起と横突孔 transverse process and foramen
- ④椎弓板 lamina
- ⑤下関節突起 inferior articular process
- ⑥棘突起 spinous process

- ⑦後外側唇 posteriolateral lip
- ⑧横突起 transverse process
- ⑨横突孔 transverse foramen
- ⑩上関節突起 superior articular process
- ⑪横突起の前結節 anterior tubercle of transverse process
- ⑫横突起の後結節 posterior tubercle of transverse process
- ⑬椎孔 vertebral foramen
- ⑭椎弓根 pedicle



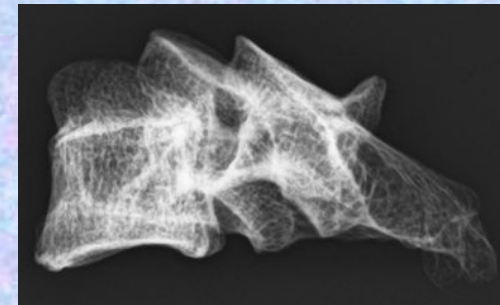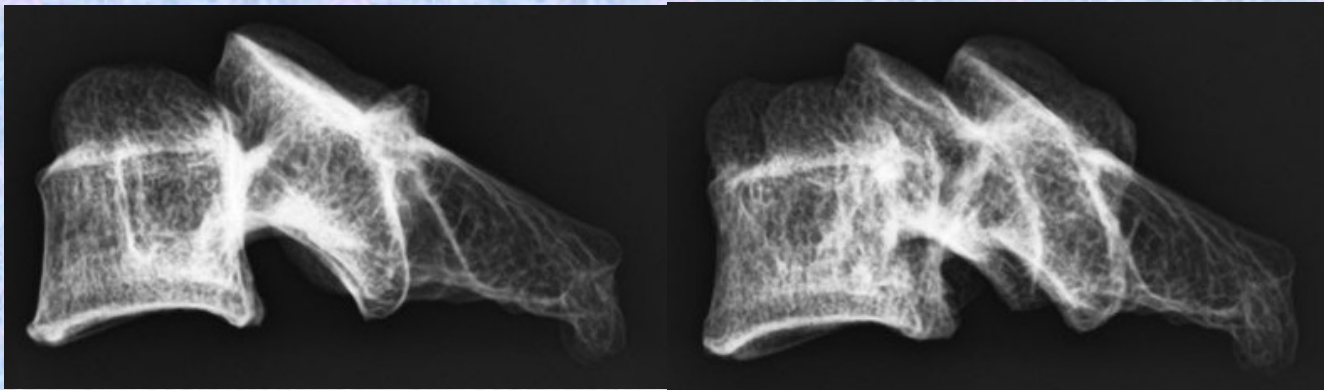
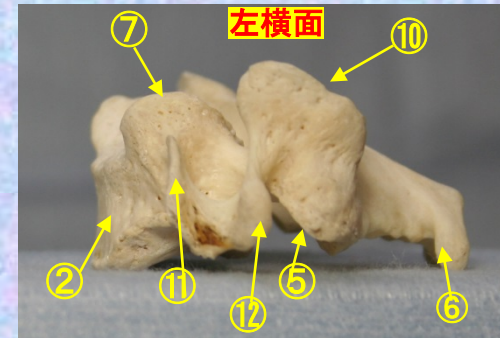

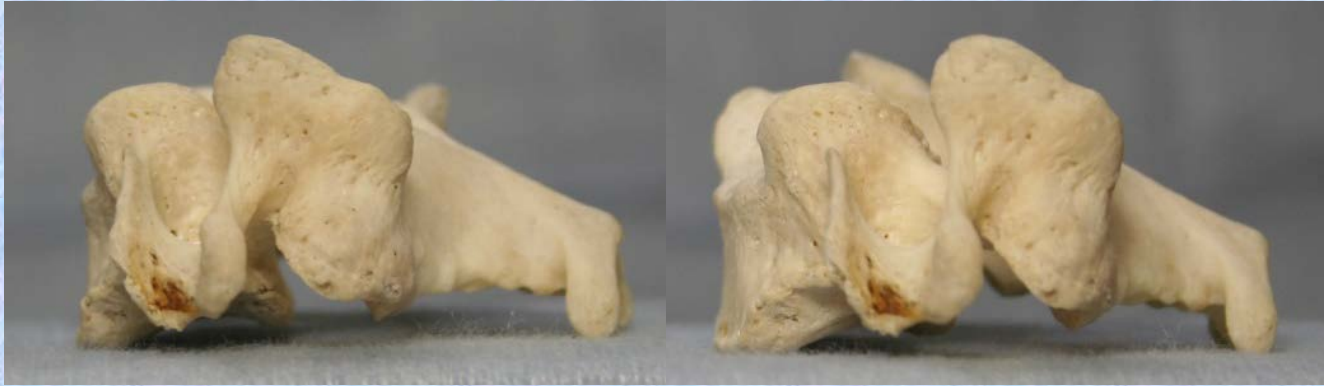
- ①上関節面(上関節突起関節面) superior articular surface
- ②椎体 transverse process
- ③横突起と横突孔 transverse process and foramen
- ④椎弓板 lamina
- ⑤下関節突起 inferior articular process
- ⑥棘突起 spinous process

- ⑦後外側唇 posteriolateral lip
- ⑧横突起 transverse process
- ⑨横突孔 transverse foramen
- ⑩上関節突起 superior articular process
- ⑪横突起の前結節 anterior tubercle of transverse process
- ⑫横突起の後結節 posterior tubercle of transverse process
- ⑬椎孔 vertebral foramen
- ⑭椎弓根 pedicle



頸椎 C5 側面

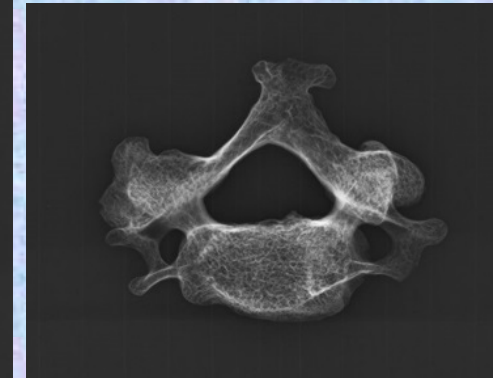
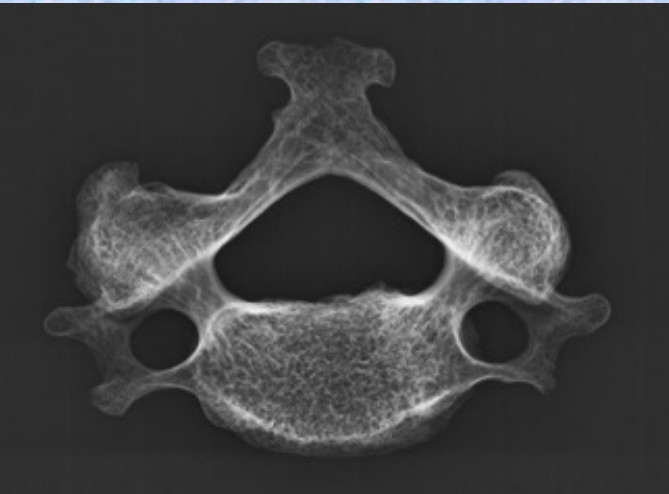
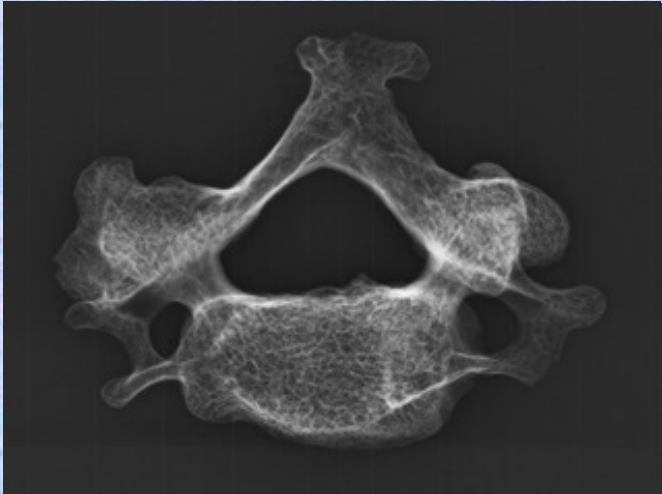
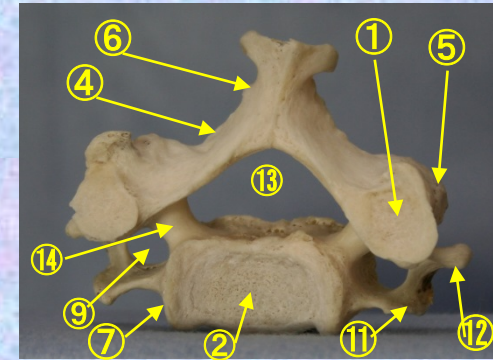
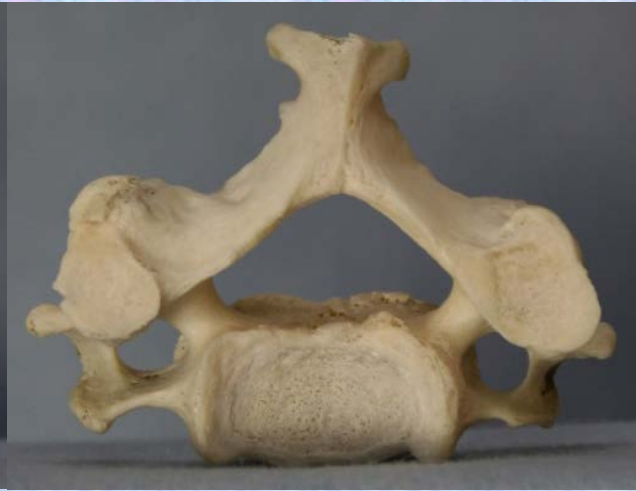
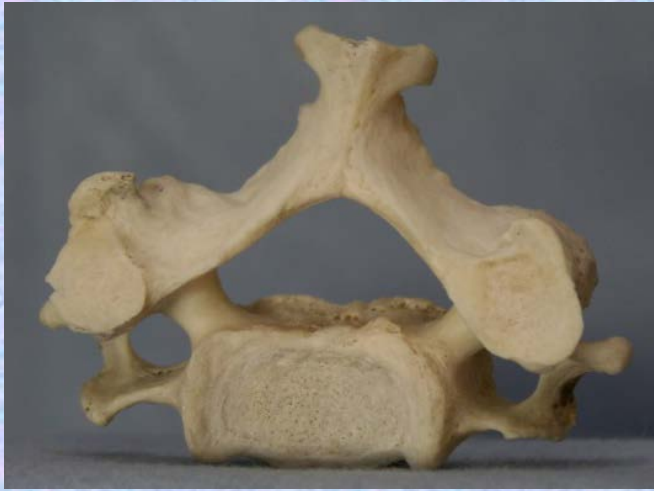
- ①上関節面(上関節突起関節面) superior articular surface
- ②椎体 transverse process
- ③横突起と横突孔 transverse process and foramen
- ④椎弓板 lamina
- ⑤下関節突起 inferior articular process
- ⑥棘突起 spinous process

- ⑦後外側唇 posteriolateral lip
- ⑧横突起 transverse process
- ⑨横突孔 transverse foramen
- ⑩上関節突起 superior articular process
- ⑪横突起の前結節 anterior tubercle of transverse process
- ⑫横突起の後結節 posterior tubercle of transverse process
- ⑬椎孔 vertebral foramen
- ⑭椎弓根 pedicle



頸椎 C5 上面

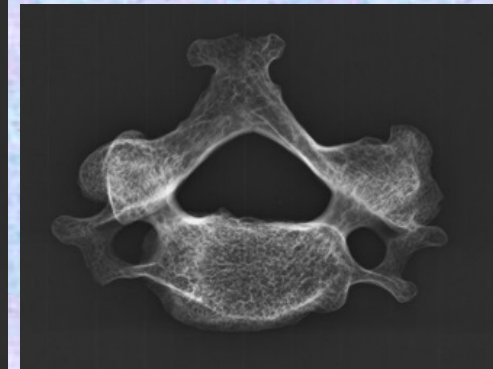
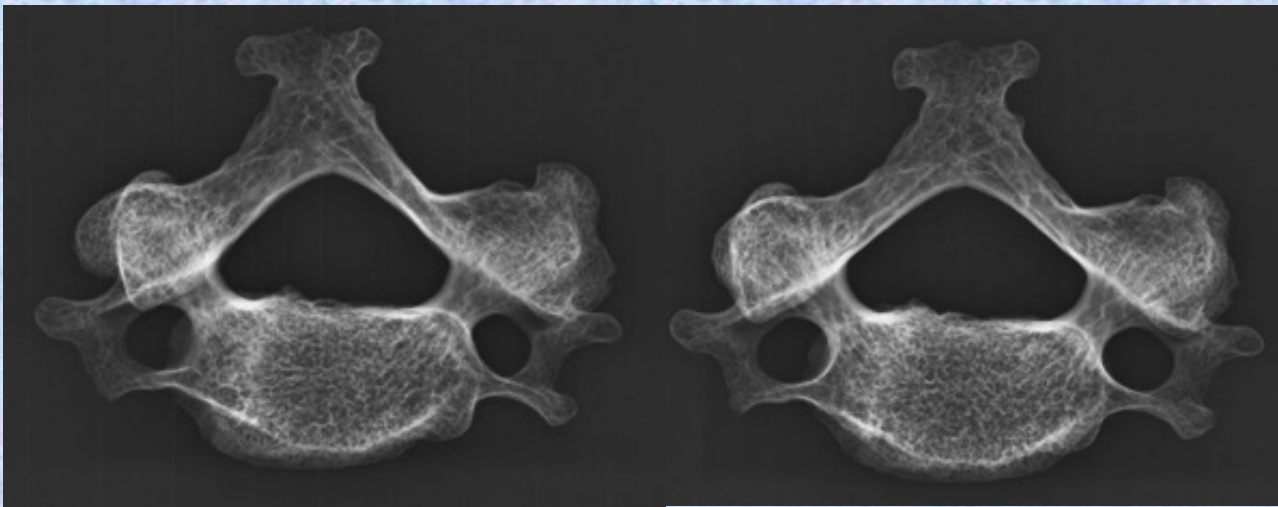
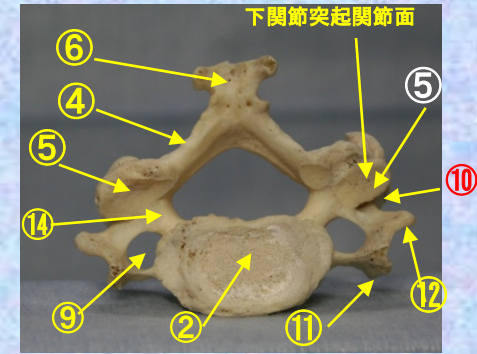
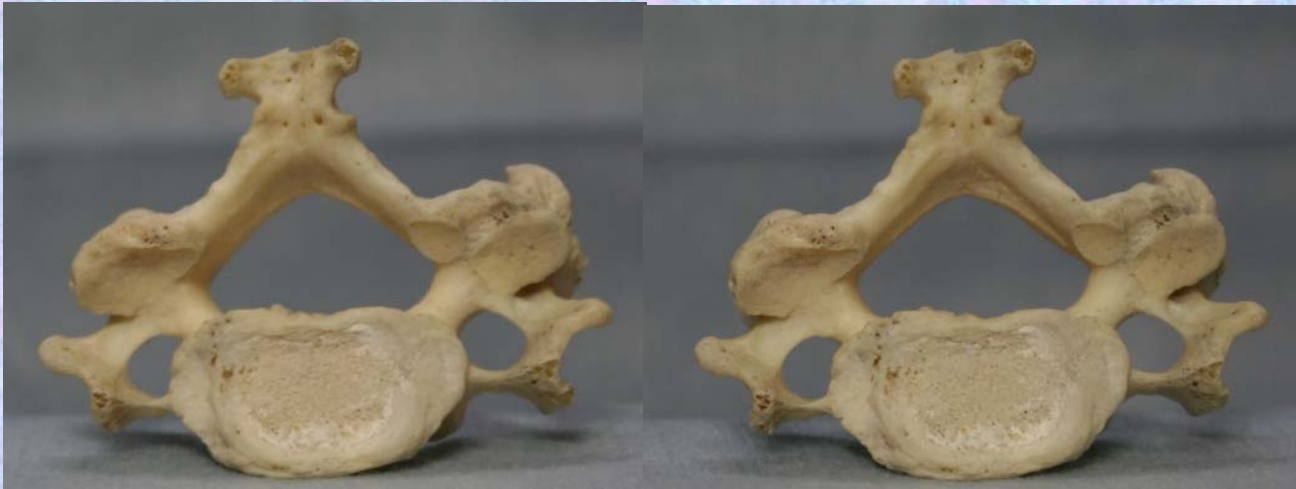

- ①上関節面(上関節突起関節面) superior articular surface
- ②椎体 transverse process
- ③横突起と横突孔 transverse process and foramen
- ④椎弓板 lamina
- ⑤下関節突起 inferior articular process
- ⑥棘突起 spinous process

- ⑦後外側唇 posteriolateral lip
- ⑧横突起 transverse process
- ⑨横突孔 transverse foramen
- ⑩上関節突起 superior articular process
- ⑪横突起の前結節 anterior tubercle of transverse process
- ⑫横突起の後結節 posterior tubercle of transverse process
- ⑬椎孔 vertebral foramen
- ⑭椎弓根 pedicle



頸椎 C5 下面



- ①上関節面(上関節突起関節面) superior articular surface
- ②椎体 transverse process
- ③横突起と横突孔 transverse process and foramen
- ④椎弓板 lamina
- ⑤下関節突起 inferior articular process
- ⑥棘突起 spinous process

- ⑦後外側唇 posteriolateral lip
- ⑧横突起 transverse process
- ⑨横突孔 transverse foramen
- ⑩上関節突起 superior articular process
- ⑪横突起の前結節 anterior tubercle of transverse process
- ⑫横突起の後結節 posterior tubercle of transverse process
- ⑬椎孔 vertebral foramen
- ⑭椎弓根 pedicle



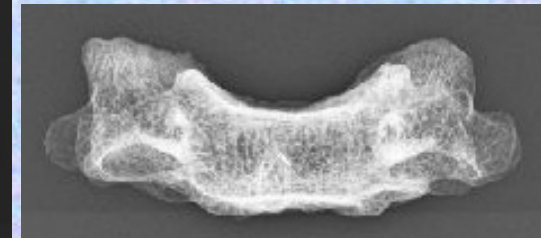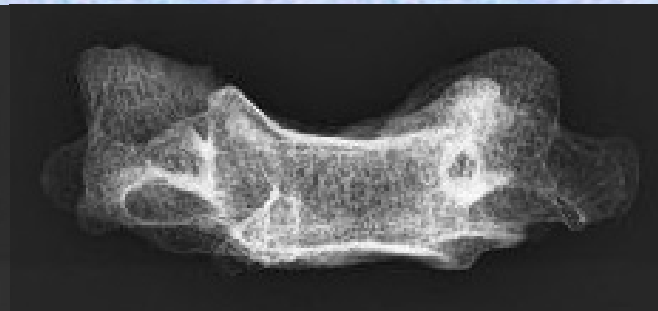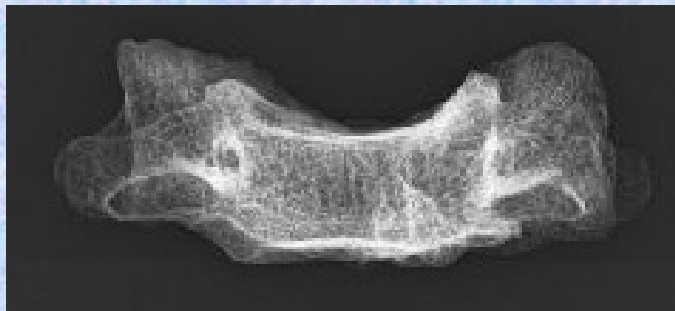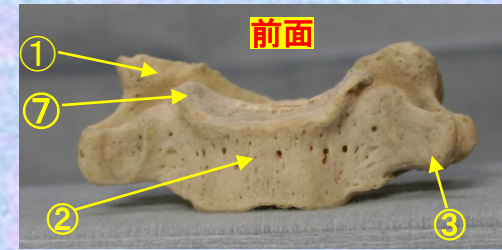
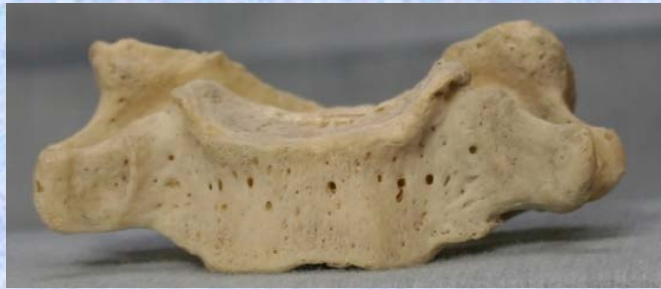第6頸椎

Cervical vertebra 6

C 6



頸椎 C6 正面

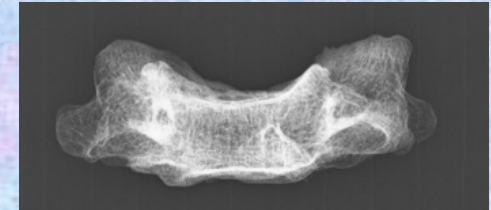
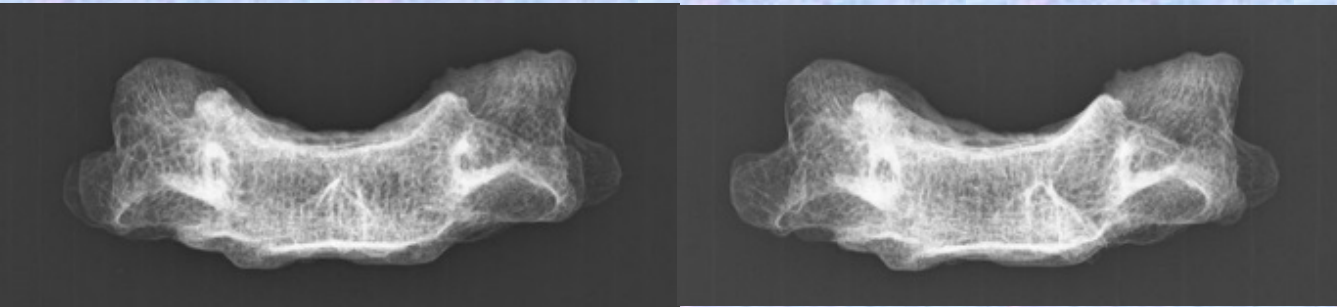
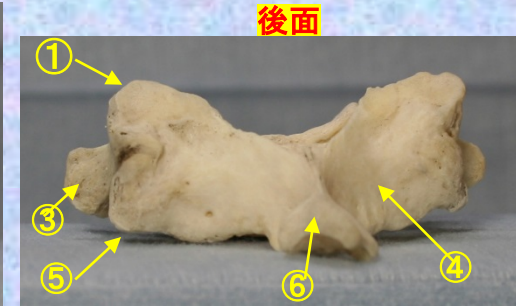
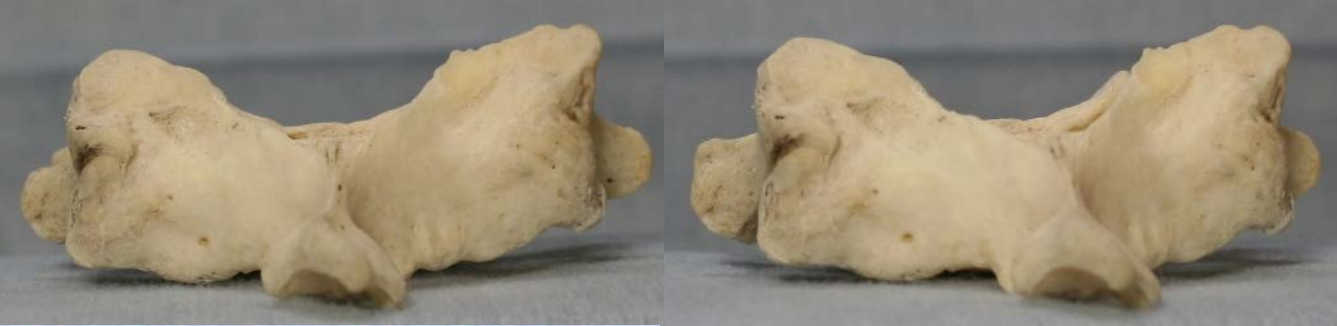

- ①上関節面(上関節突起関節面) superior articular surface
- ②椎体 transverse process
- ③横突起と横突孔 transverse process and foramen
- ④椎弓板 lamina
- ⑤下関節突起 inferior articular process
- ⑥棘突起(2分岐性) spinous process

- ⑦後外側唇 posteriolateral lip
- ⑧横突起 transverse process
- ⑨横突孔 transverse foramen
- ⑩上関節突起 superior articular process
- ⑪横突起の前結節 anterior tubercle of transverse process
- ⑫横突起の後結節 posterior tubercle of transverse process
- ⑬椎孔 vertebral foramen
- ⑭椎弓根 pedicle



頸椎 C6 後面

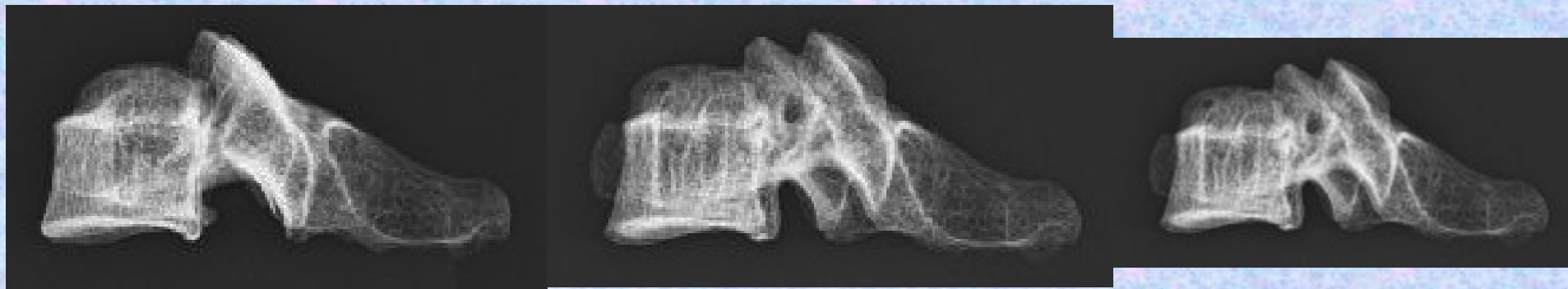
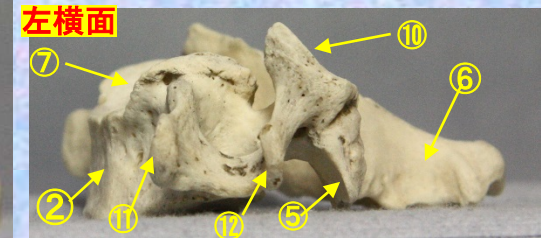
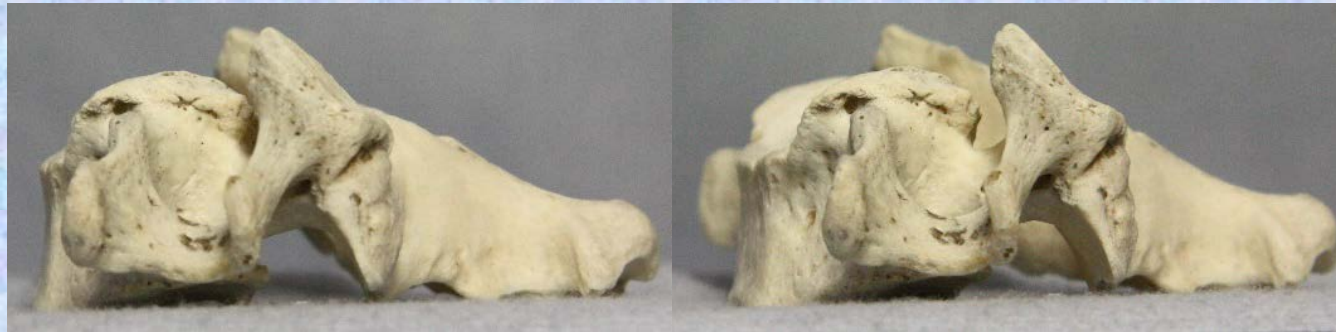

- ①上関節面(上関節突起関節面) superior articular surface
- ②椎体 transverse process
- ③横突起と横突孔 transverse process and foramen
- ④椎弓板 lamina
- ⑤下関節突起 inferior articular process
- ⑥棘突起(2分岐性) spinous process

- ⑦後外側唇 posteriolateral lip
- ⑧横突起 transverse process
- ⑨横突孔 transverse foramen
- ⑩上関節突起 superior articular process
- ⑪横突起の前結節 anterior tubercle of transverse process
- ⑫横突起の後結節 posterior tubercle of transverse process
- ⑬椎孔 vertebral foramen
- ⑭椎弓根 pedicle



頸椎 C6 側面

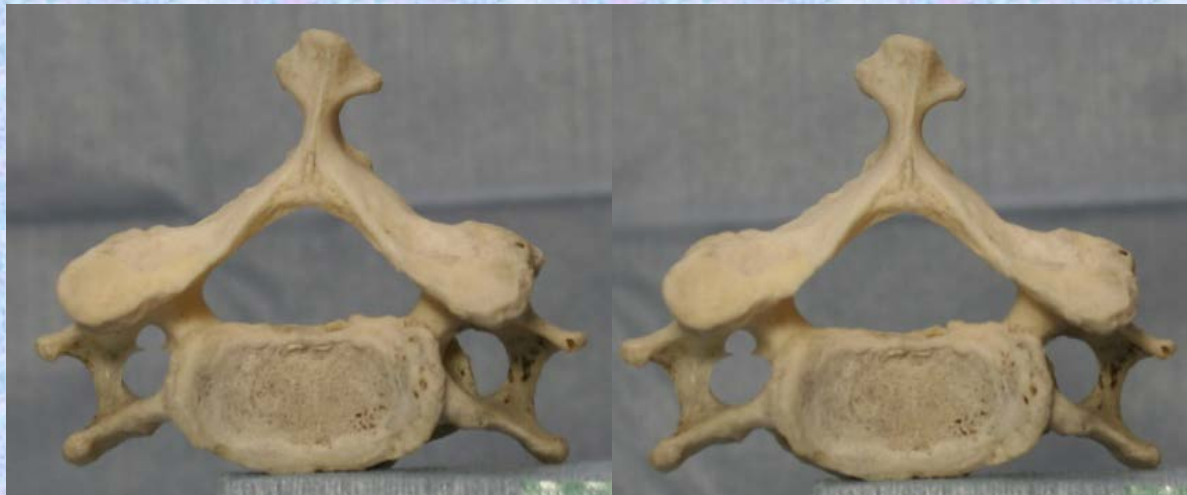

- ①上関節面(上関節突起関節面) superior articular surface
- ②椎体 transverse process
- ③横突起と横突孔 transverse process and foramen
- ④椎弓板 lamina
- ⑤下関節突起 inferior articular process
- ⑥棘突起(2分岐性) spinous process

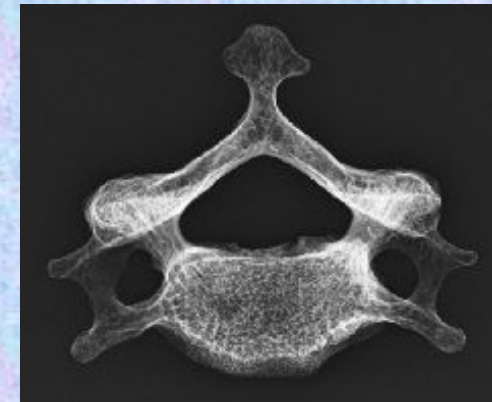
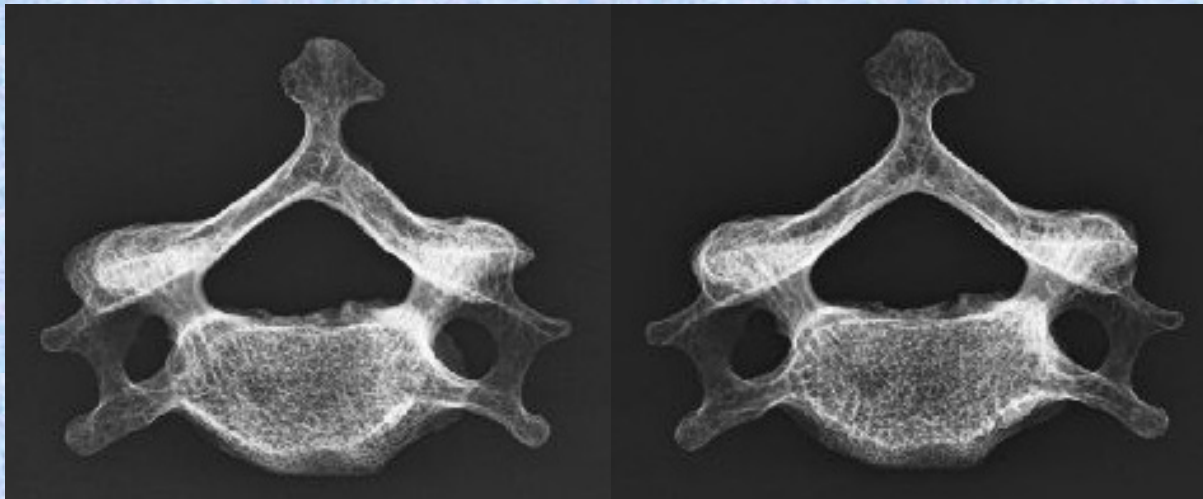
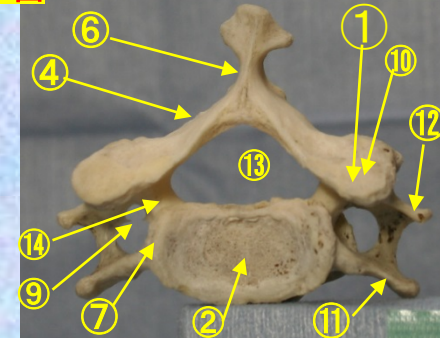
- ⑦後外側唇 posteriolateral lip
- ⑧横突起 transverse process
- ⑨横突孔 transverse foramen
- ⑩上関節突起 superior articular process
- ⑪横突起の前結節 anterior tubercle of transverse process
- ⑫横突起の後結節 posterior tubercle of transverse process
- ⑬椎孔 vertebral foramen
- ⑭椎弓根 pedicle



頸椎 C6 上面



上面

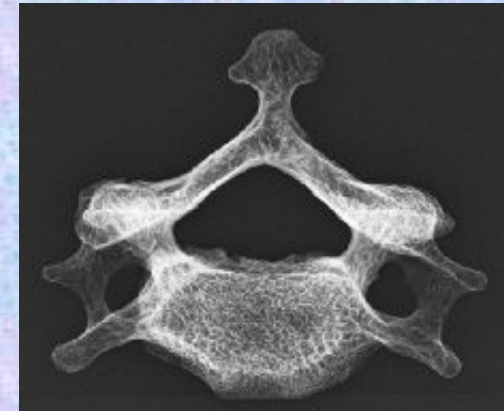
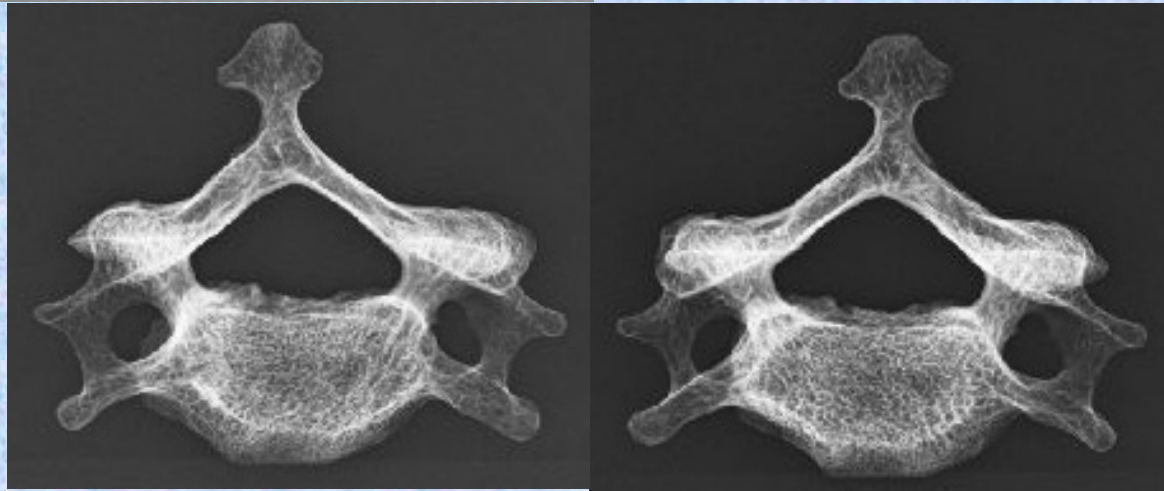
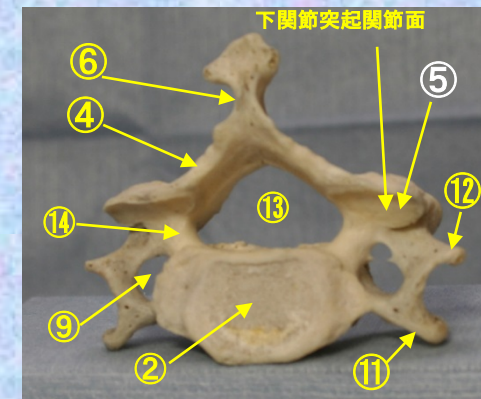
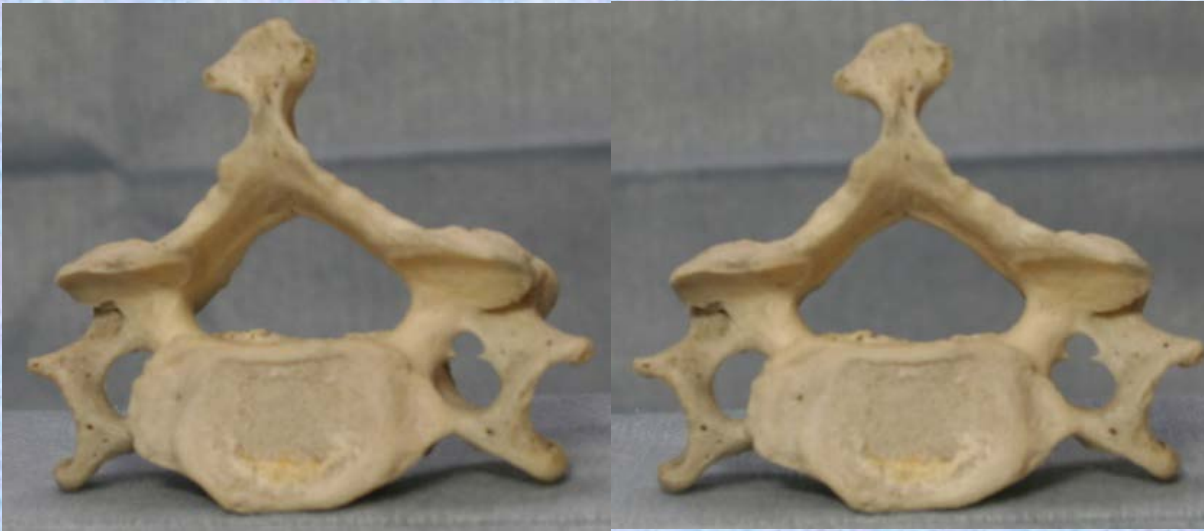

- ①上関節面(上関節突起関節面) superior articular surface
- ②椎体 transverse process
- ③横突起と横突孔 transverse process and foramen
- ④椎弓板 lamina
- ⑤下関節突起 inferior articular process
- ⑥棘突起(2分岐性) spinous process

- ⑦後外側唇 posteriolateral lip
- ⑧横突起 transverse process
- ⑨横突孔 transverse foramen
- ⑩上関節突起 superior articular process
- ⑪横突起の前結節 anterior tubercle of transverse process
- ⑫横突起の後結節 posterior tubercle of transverse process
- ⑬椎孔 vertebral foramen
- ⑭椎弓根 pedicle



頸椎 C6 下面



- ①上関節面(上関節突起関節面) superior articular surface
- ②椎体 transverse process
- ③横突起と横突孔 transverse process and foramen
- ④椎弓板 lamina
- ⑤下関節突起 inferior articular process
- ⑥棘突起(2分岐性) spinous process

- ⑦後外側唇 posteriolateral lip
- ⑧横突起 transverse process
- ⑨横突孔 transverse foramen
- ⑩上関節突起 superior articular process
- ⑪横突起の前結節 anterior tubercle of transverse process
- ⑫横突起の後結節 posterior tubercle of transverse process
- ⑬椎孔 vertebral foramen
- ⑭椎弓根 pedicle



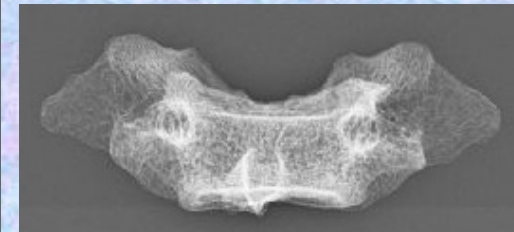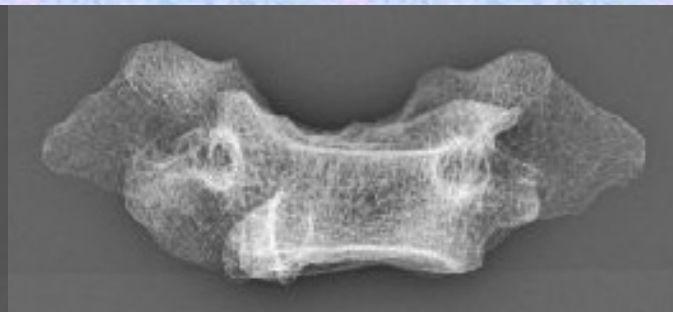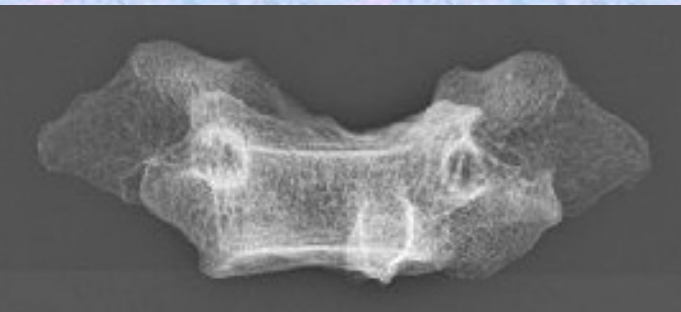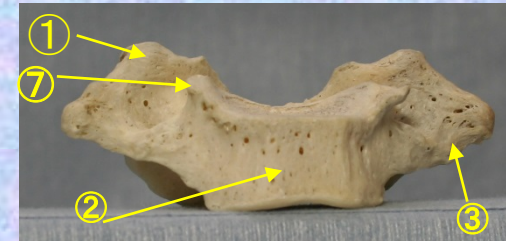
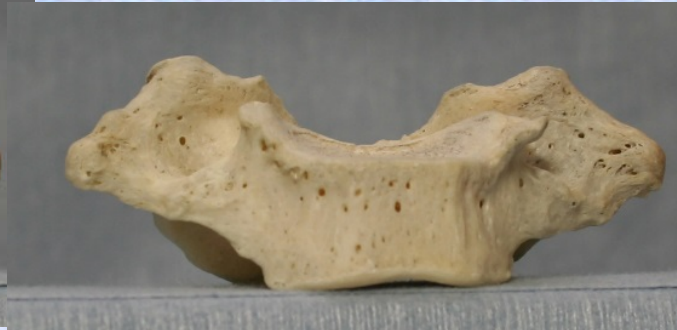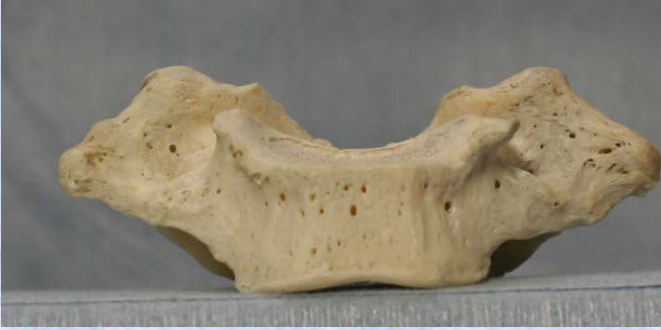第7頸椎

Cervical vertebra 7

C 7



頸椎 C7 前面

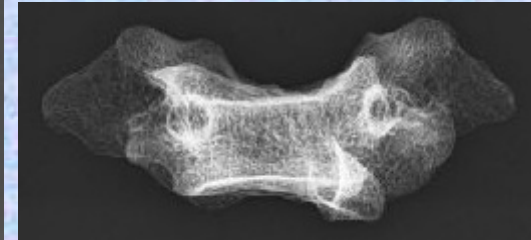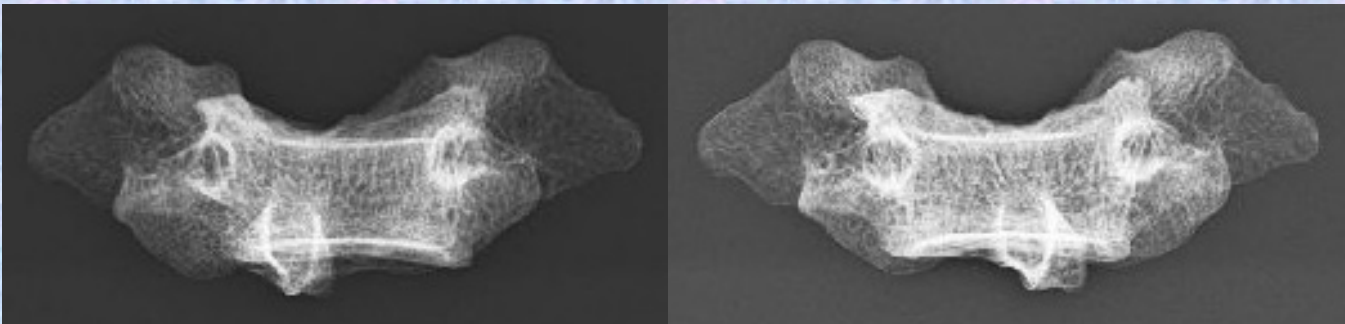
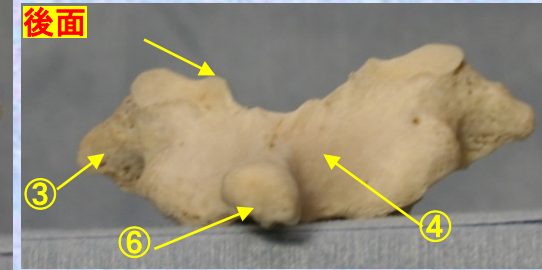


- ①上関節面(上関節突起関節面) superior articular surface
- ②椎体 transverse process
- ③横突起と横突孔 transverse process and foramen
- ④椎弓板 lamina
- ⑤下関節突起 inferior articular process
- ⑥棘突起 spinous process

- ⑦後外側唇 posteriolateral lip
- ⑧横突起 transverse process
- ⑨横突孔 transverse foramen
- ⑩上関節突起 superior articular process
- ⑪横突起の前結節 anterior tubercle of transverse process
- ⑫横突起の後結節 posterior tubercle of transverse process
- ⑬椎孔 vertebral foramen
- ⑭椎弓根 pedicle



頸椎 C7 後面

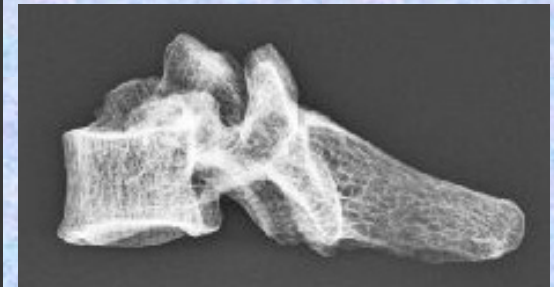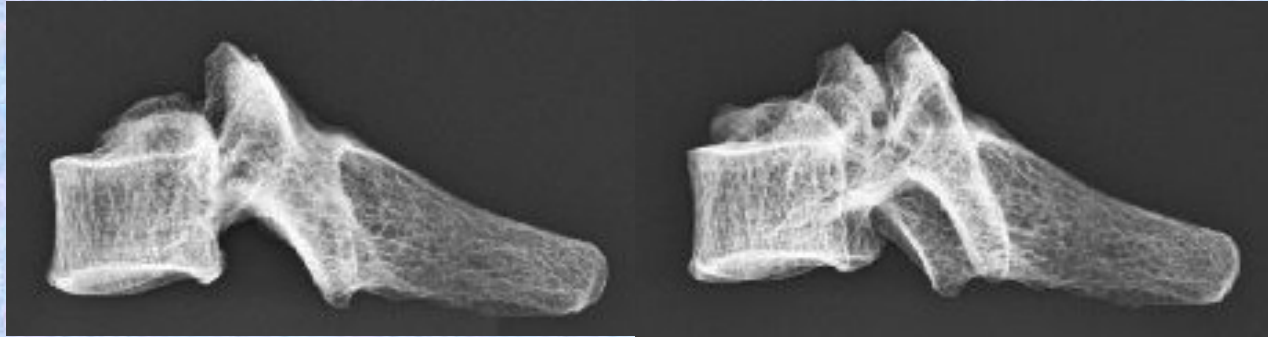

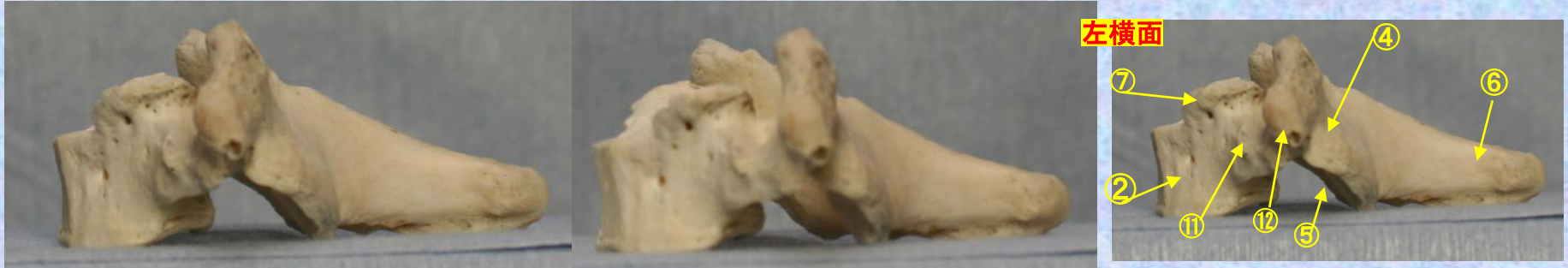
- ①上関節面(上関節突起関節面) superior articular surface
- ②椎体 transverse process
- ③横突起と横突孔 transverse process and foramen
- ④椎弓板 lamina
- ⑤下関節突起 inferior articular process
- ⑥棘突起 spinous process

- ⑦後外側唇 posteriolateral lip
- ⑧横突起 transverse process
- ⑨横突孔 transverse foramen
- ⑩上関節突起 superior articular process
- ⑪横突起の前結節 anterior tubercle of transverse process
- ⑫横突起の後結節 posterior tubercle of transverse process
- ⑬椎孔 vertebral foramen
- ⑭椎弓根 pedicle



頸椎 C7 側面

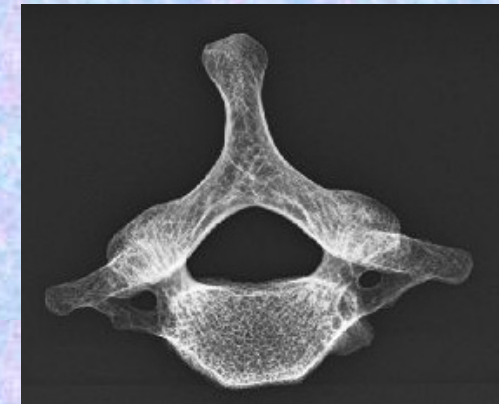
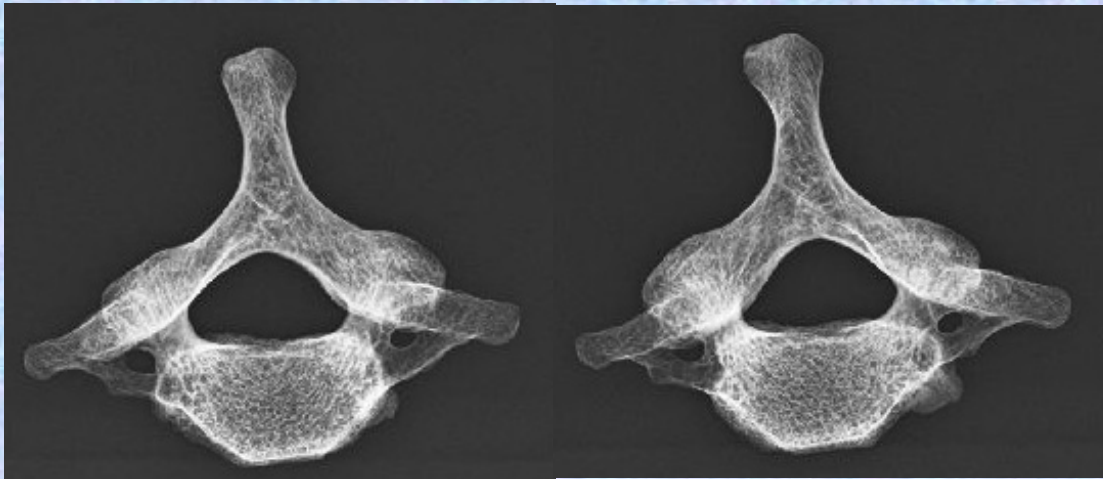
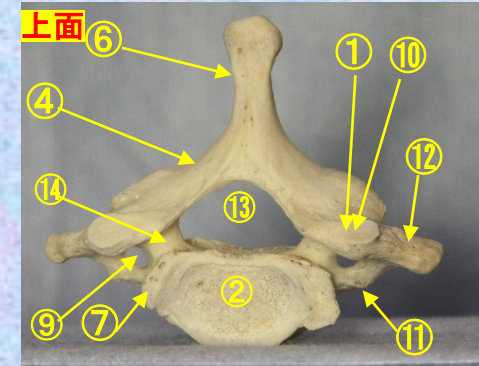
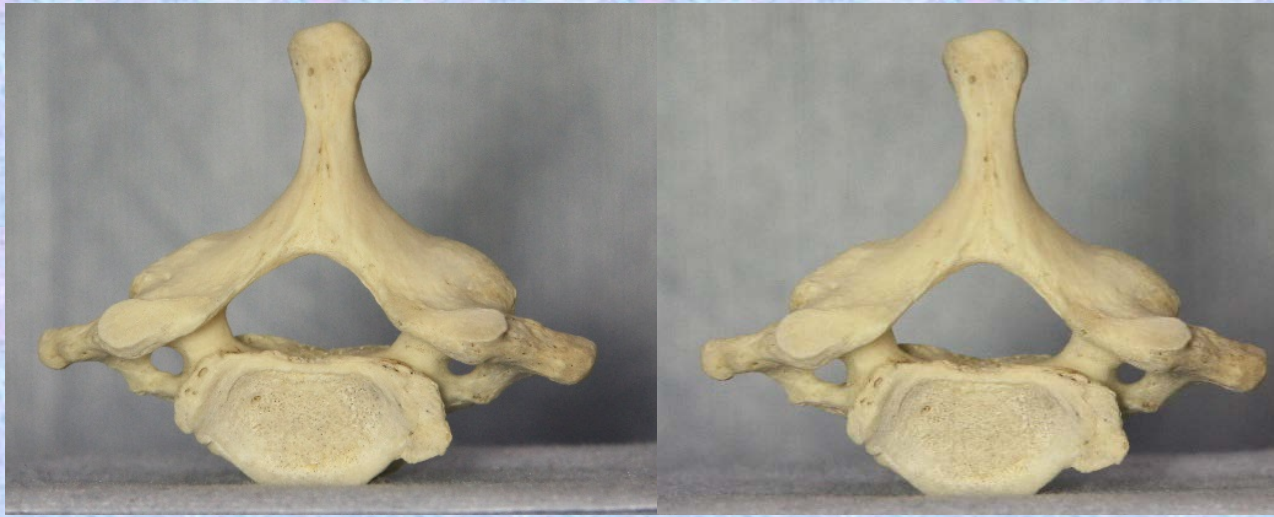

- ①上関節面(上関節突起関節面) superior articular surface
- ②椎体 transverse process
- ③横突起と横突孔 transverse process and foramen
- ④椎弓板 lamina
- ⑤下関節突起 inferior articular process
- ⑥棘突起 spinous process

- ⑦後外側唇 posteriolateral lip
- ⑧横突起 transverse process
- ⑨横突孔 transverse foramen
- ⑩上関節突起 superior articular process
- ⑪横突起の前結節 anterior tubercle of transverse process
- ⑫横突起の後結節 posterior tubercle of transverse process
- ⑬椎孔 vertebral foramen
- ⑭椎弓根 pedicle



頸椎 C7 上面

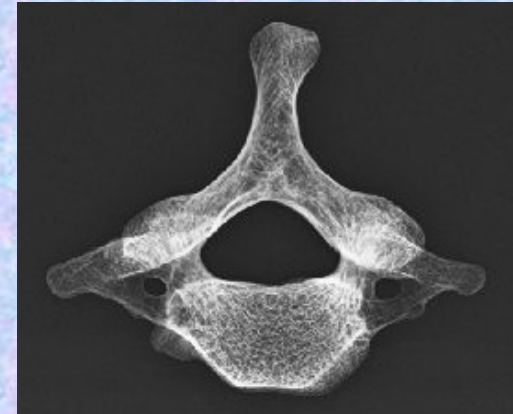
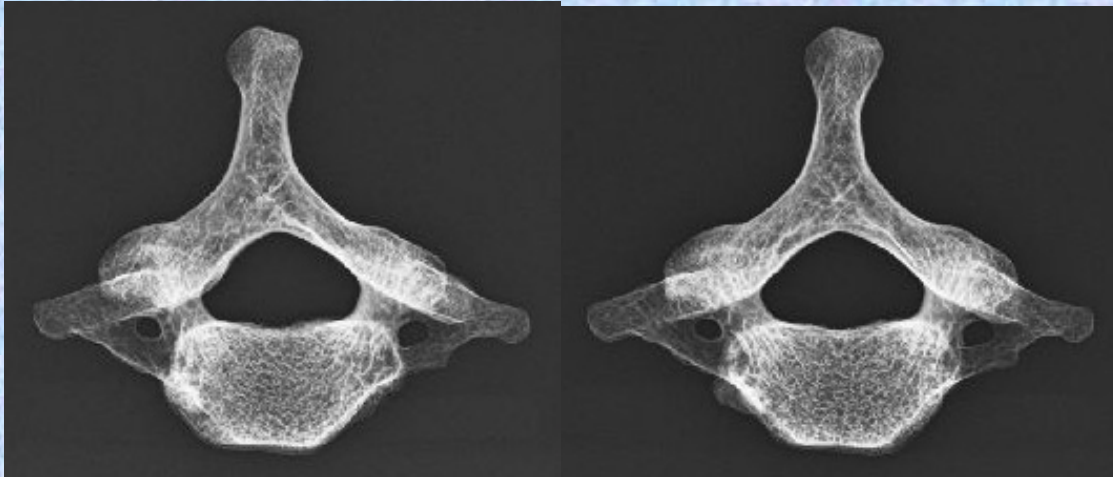
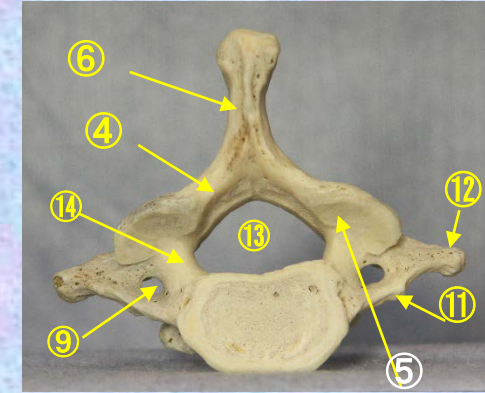
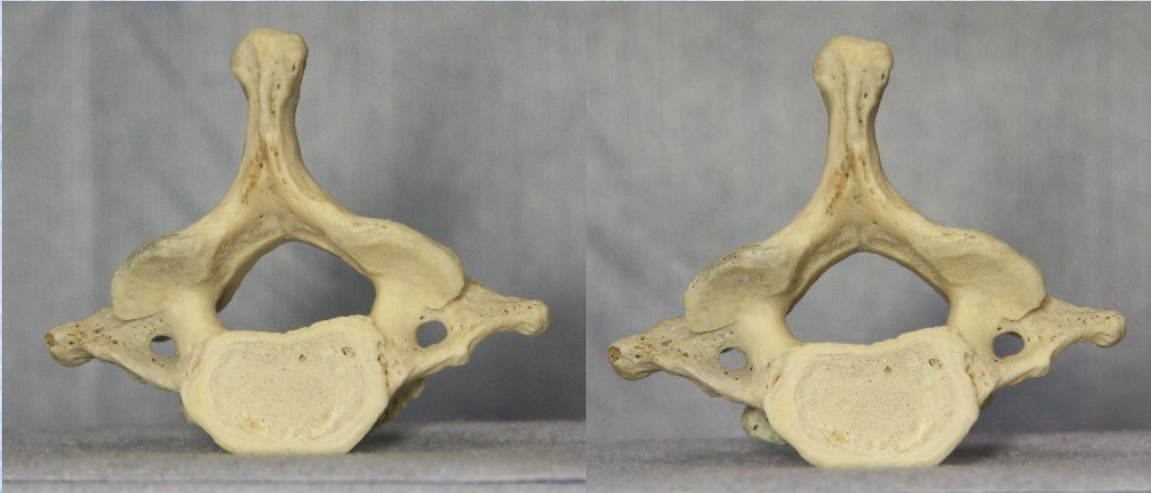


- ①上関節面(上関節突起関節面) superior articular surface
- ②椎体 transverse process
- ③横突起と横突孔 transverse process and foramen
- ④椎弓板 lamina
- ⑤下関節突起 inferior articular process
- ⑥棘突起 spinous process

- ⑦後外側唇 posteriolateral lip
- ⑧横突起 transverse process
- ⑨横突孔 transverse foramen
- ⑩上関節突起 superior articular process
- ⑪横突起の前結節 anterior tubercle of transverse process
- ⑫横突起の後結節 posterior tubercle of transverse process
- ⑬椎孔 vertebral foramen
- ⑭椎弓根 pedicle



頸椎 C7 下面



- ①上関節面(上関節突起関節面) superior articular surface
- ②椎体 transverse process
- ③横突起と横突孔 transverse process and foramen
- ④椎弓板 lamina
- ⑤下関節突起 inferior articular process
- ⑥棘突起 spinous process

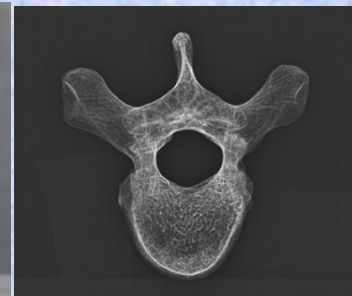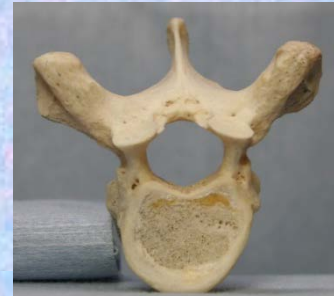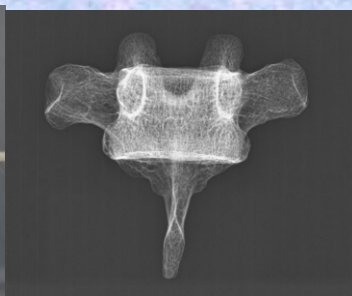
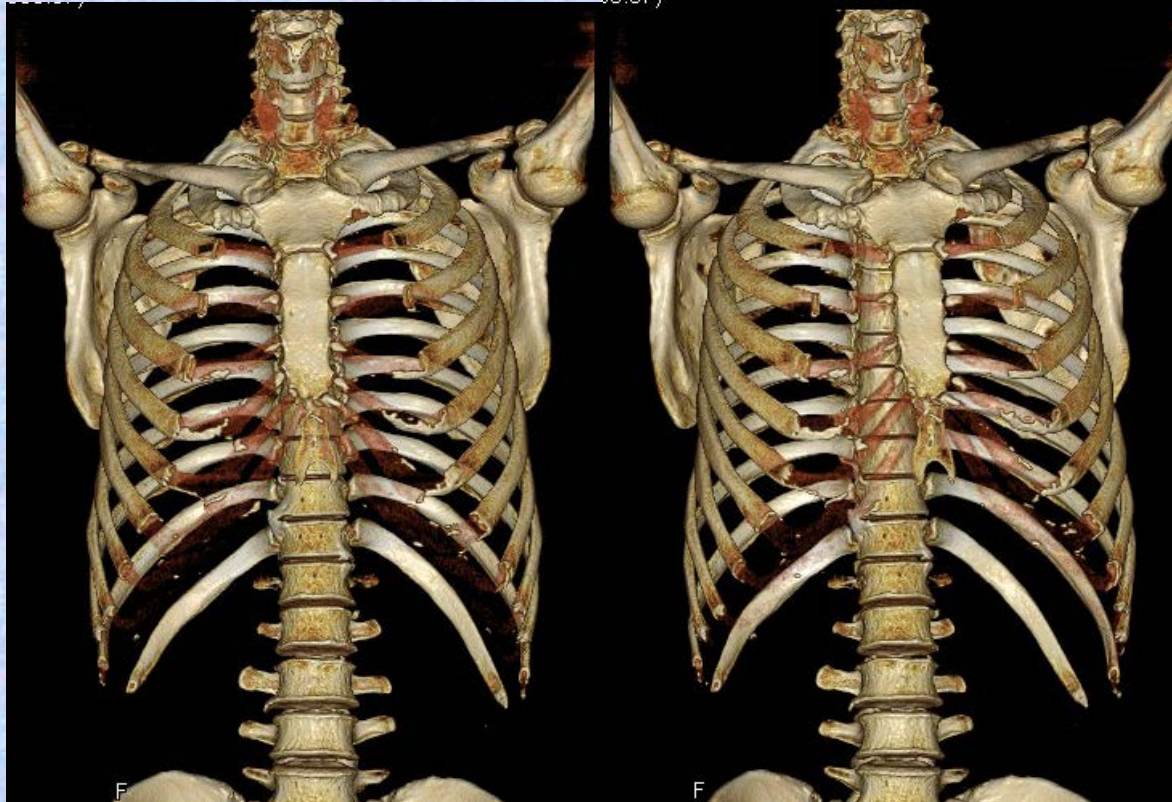
- ⑦後外側唇 posteriolateral lip
- ⑧横突起 transverse process
- ⑨横突孔 transverse foramen
- ⑩上関節突起 superior articular process
- ⑪横突起の前結節 anterior tubercle of transverse process
- ⑫横突起の後結節 posterior tubercle of transverse process
- ⑬椎孔 vertebral foramen
- ⑭椎弓根 pedicle



骨標本X線ステレオ解剖図

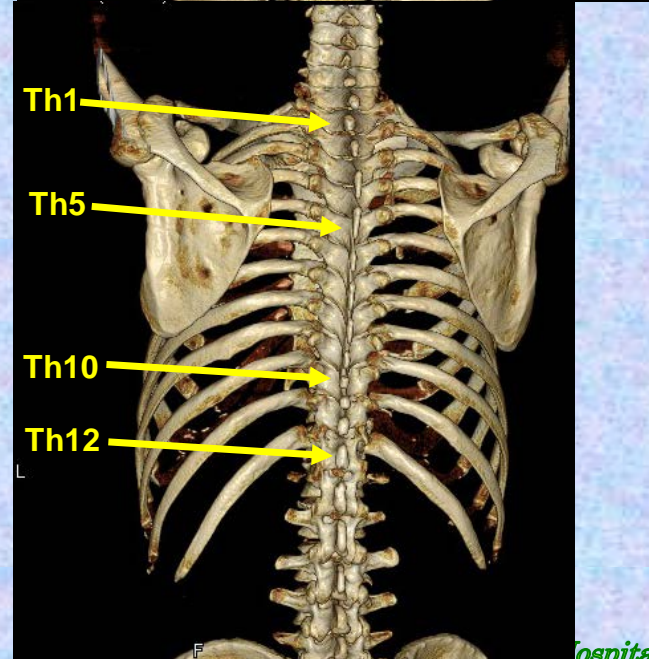
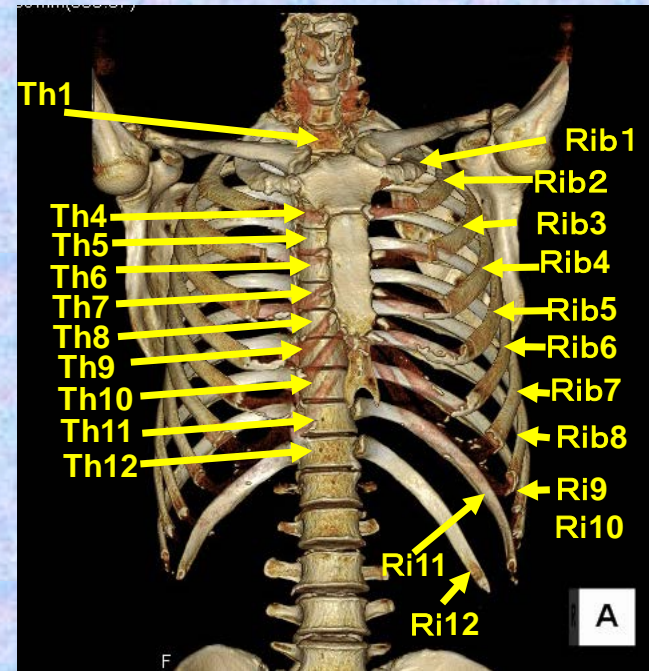
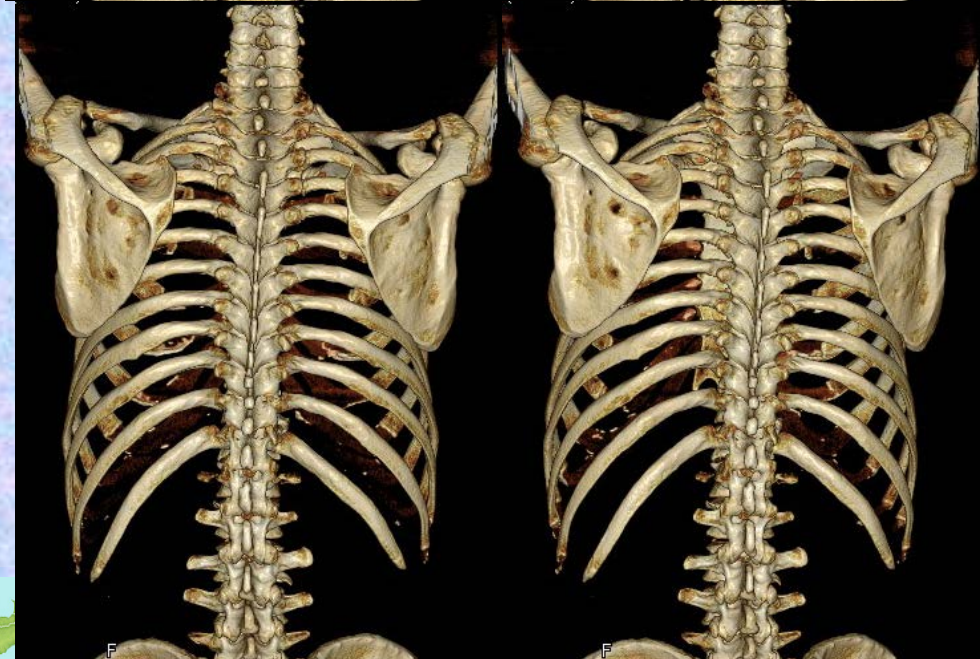
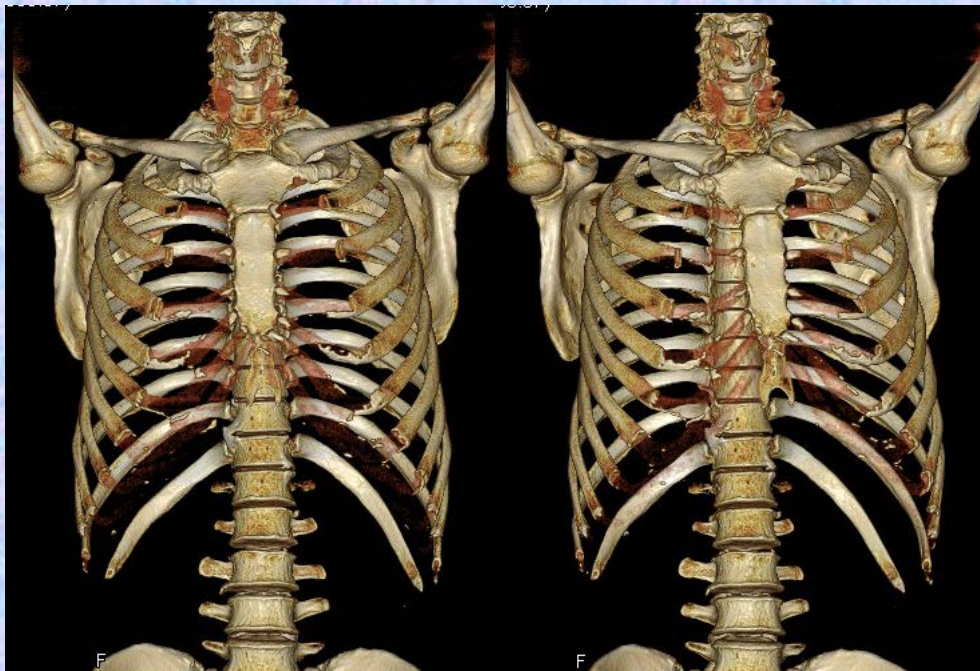
胸椎

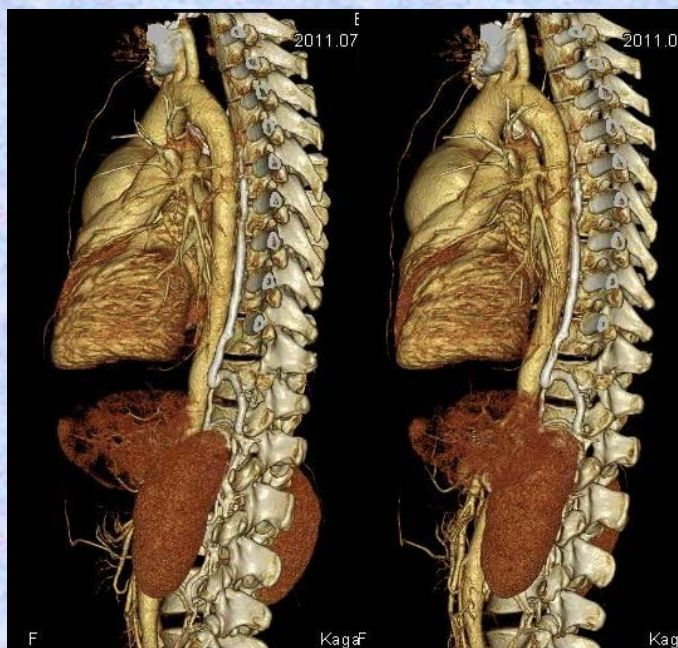
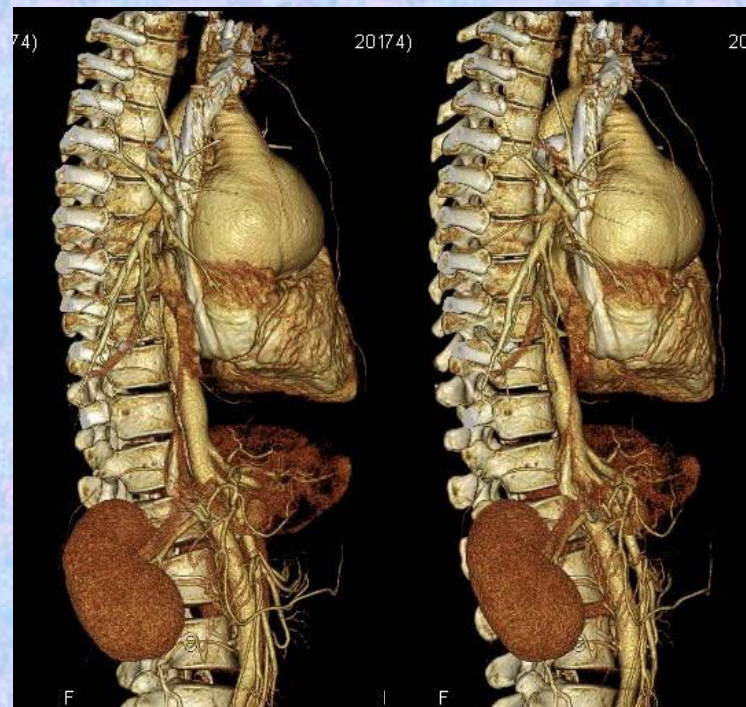
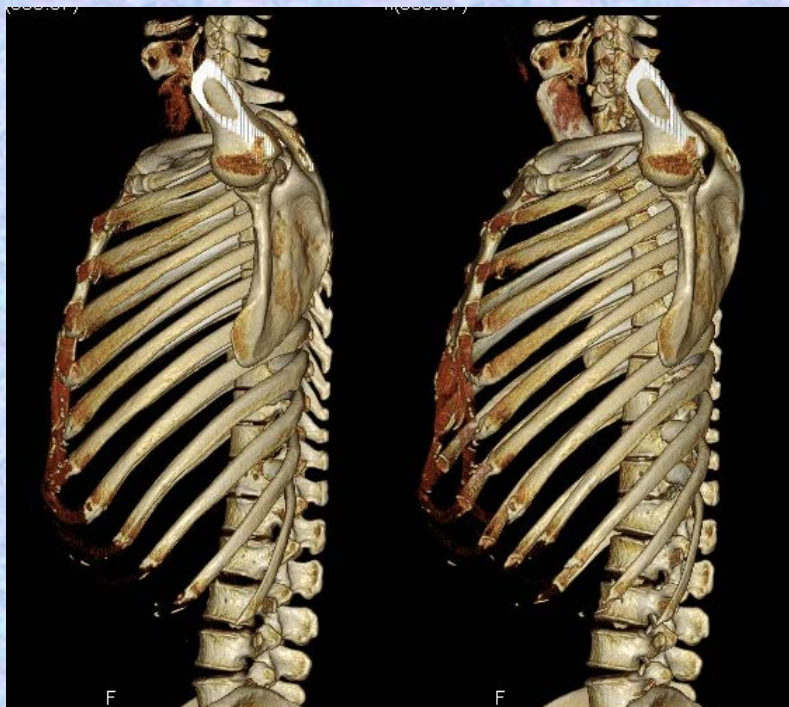
胸椎

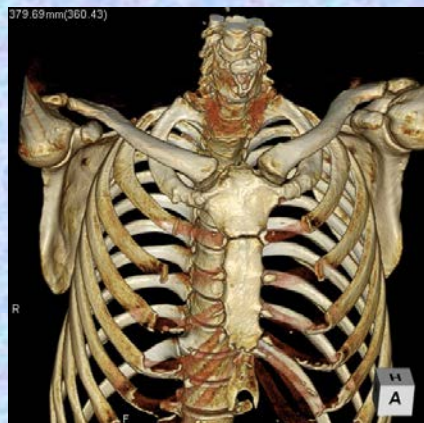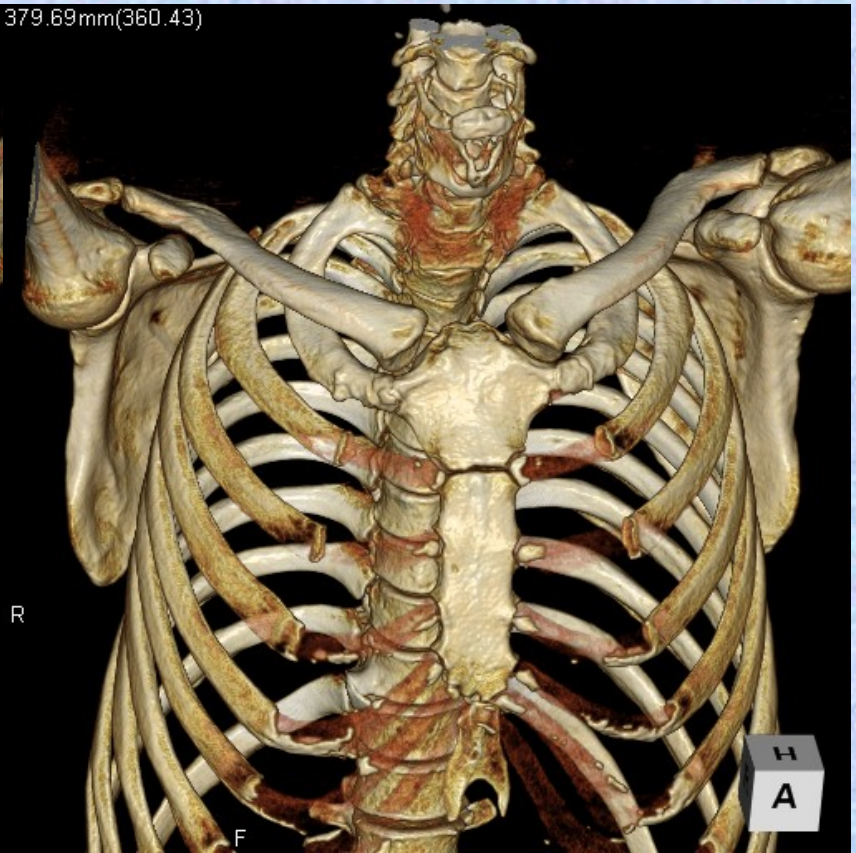
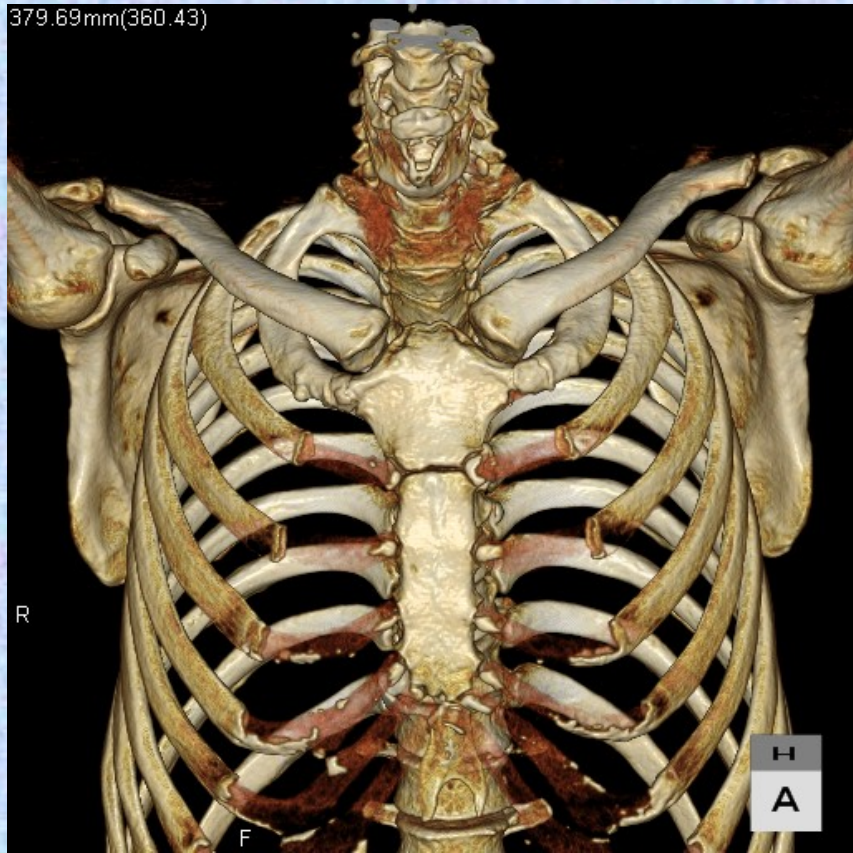


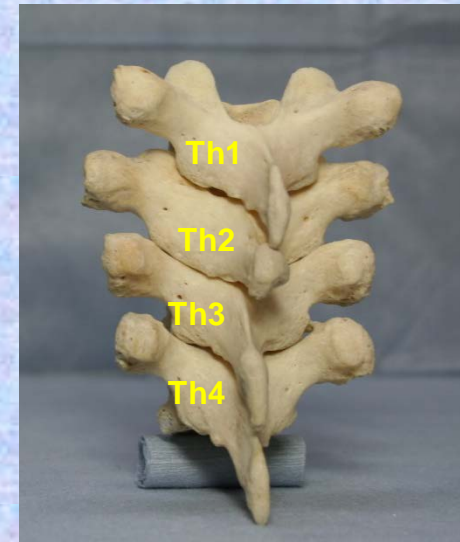
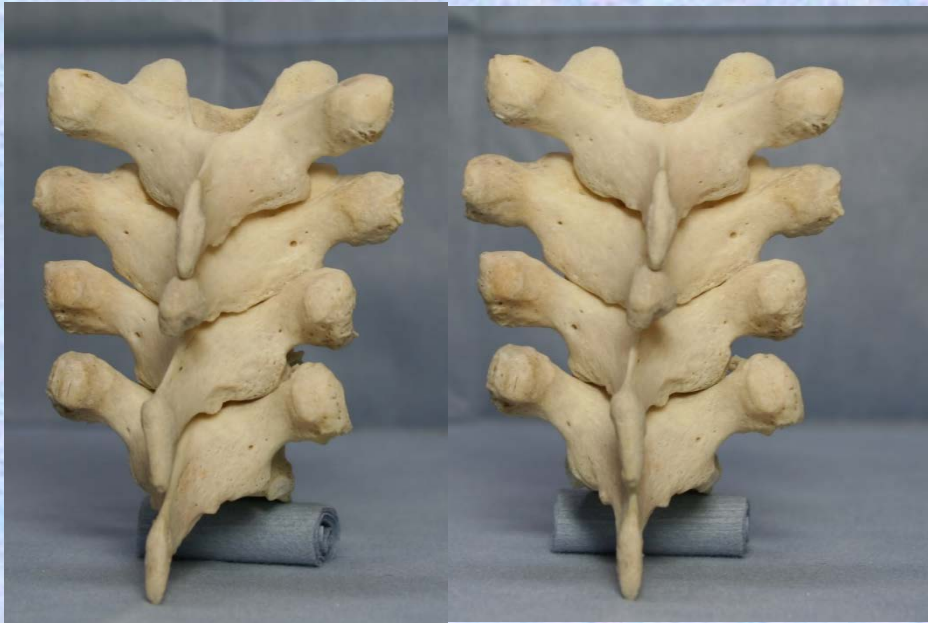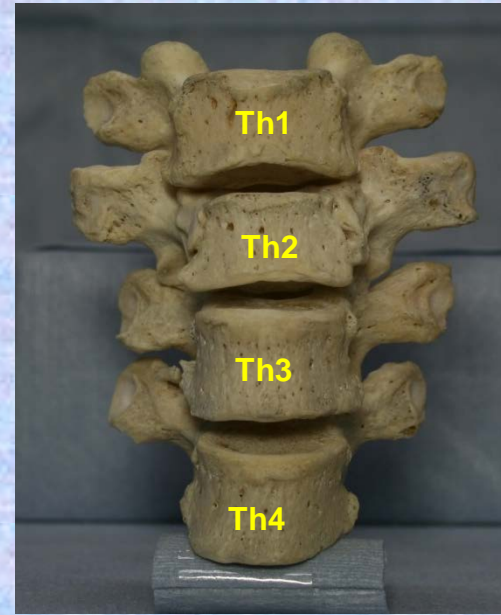
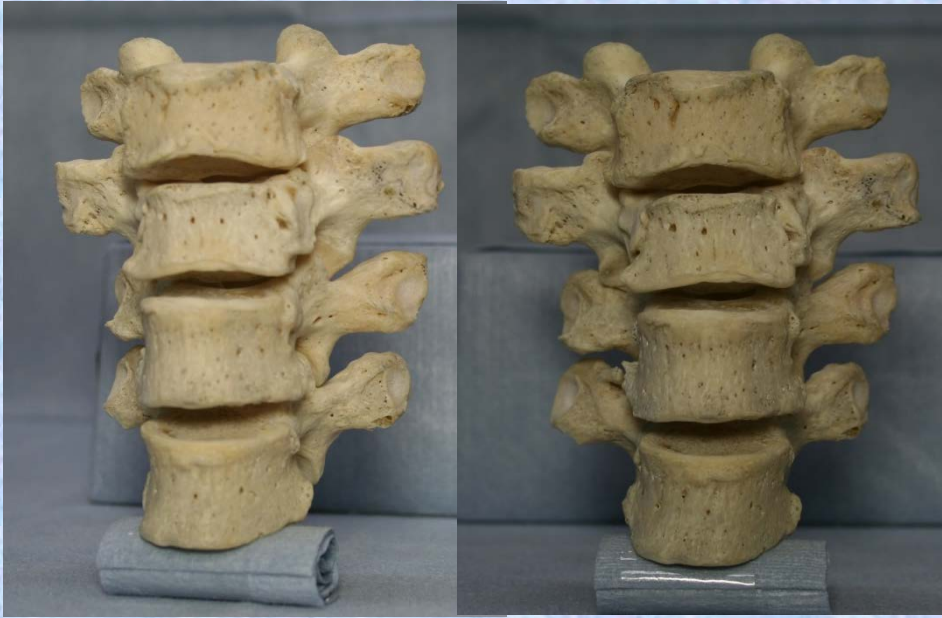監修 香川大学医学部 組織細胞生物学 教授 荒木 伸一
作成 香川大学医学部附属病院 放射線部 勢川 博雄 2014.9











胸椎

Thoracic vertebrae (複)

Thoracic vertebra (単)

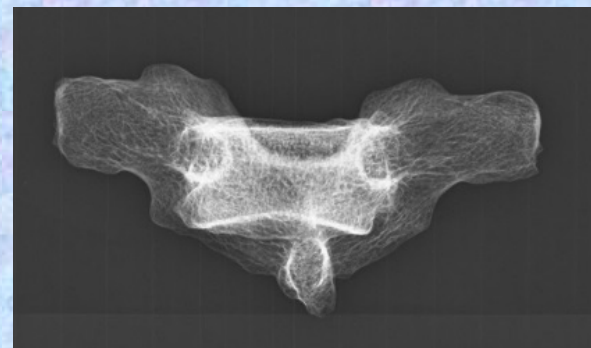
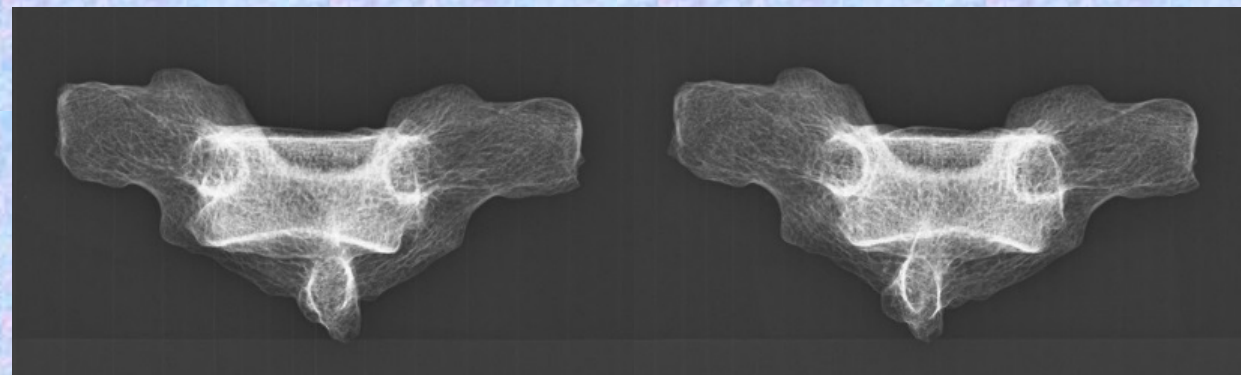
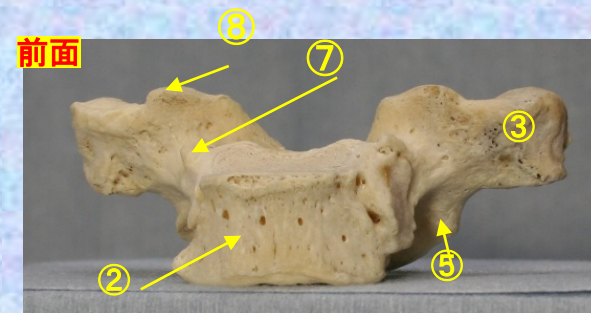
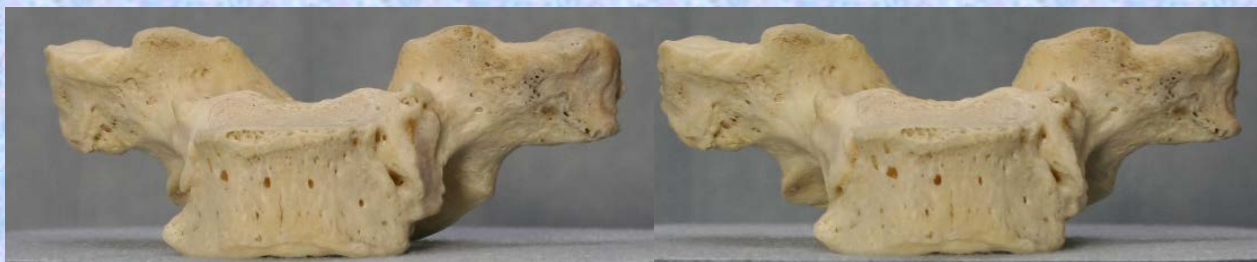

第1胸椎

Thoracic vertebra 1

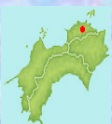Th1

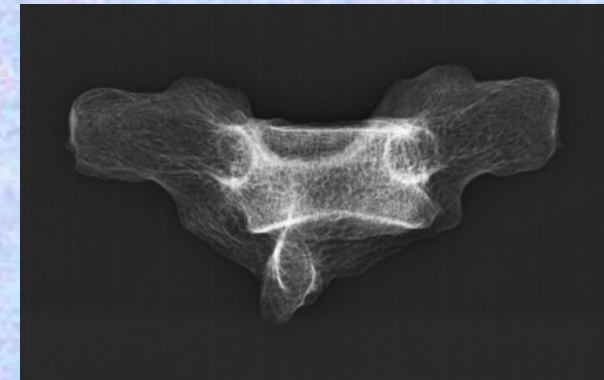
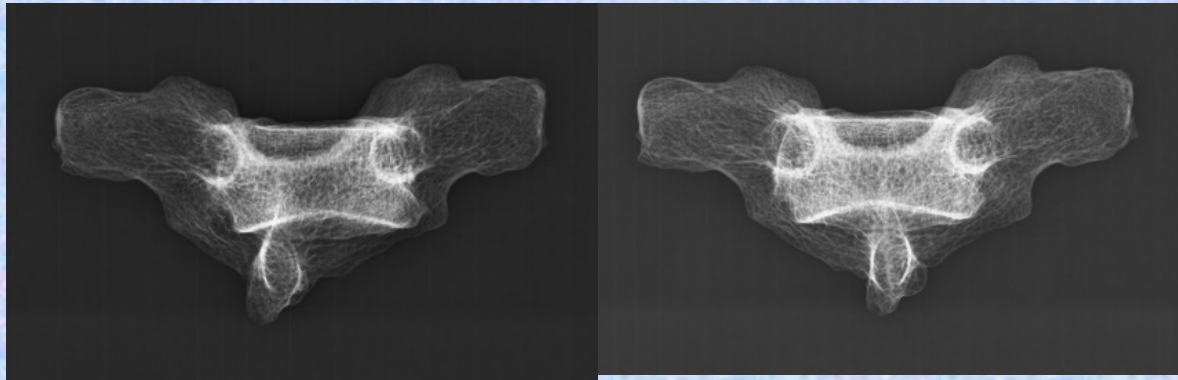
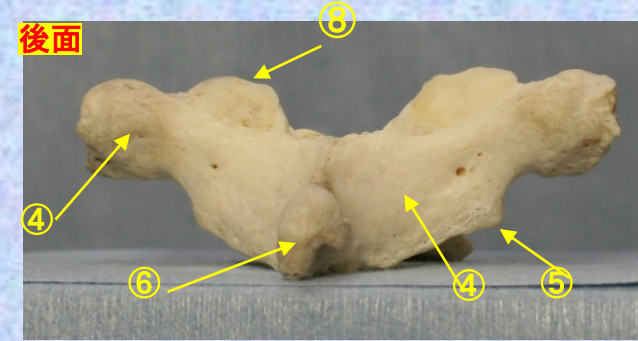
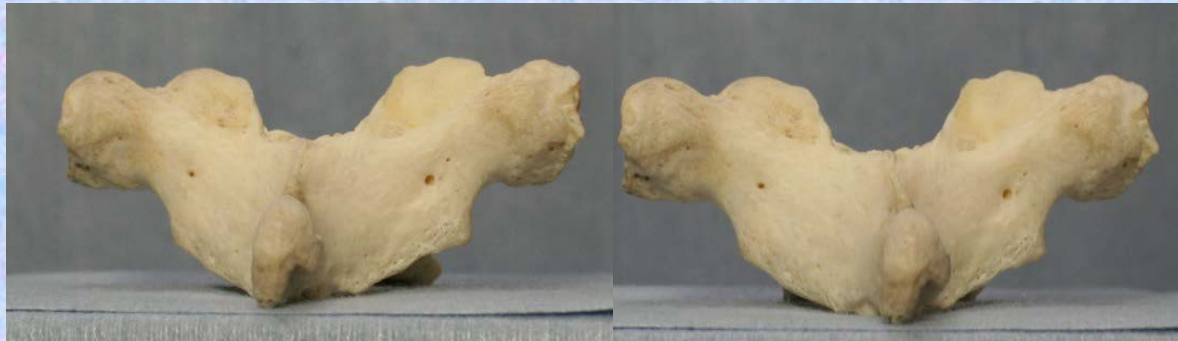



- ①下関節面(下関節突起関節面) inferior articular surface
- ②椎体 transverse process
- ③横突起 transverse process
- ④椎弓板 lamina
- ⑤下関節突起 inferior articular process
- ⑥棘突起 spinous process

- ⑦後外側唇 posteriolateral lip
- ⑧上関節突起 superior articular process
- ⑨椎孔 vertebral foramen
- ⑩椎弓根 pedicle
- ⑪上肋骨窩 superior costal facet
- ⑫横突肋骨窩 costal facet of transverse process
- ⑬下肋骨窩 inferior costal facet (TH1にはなし。)





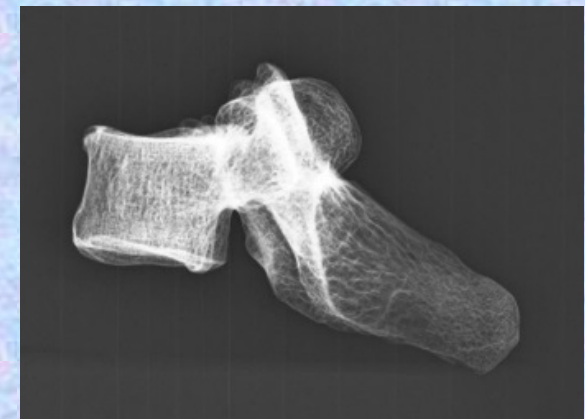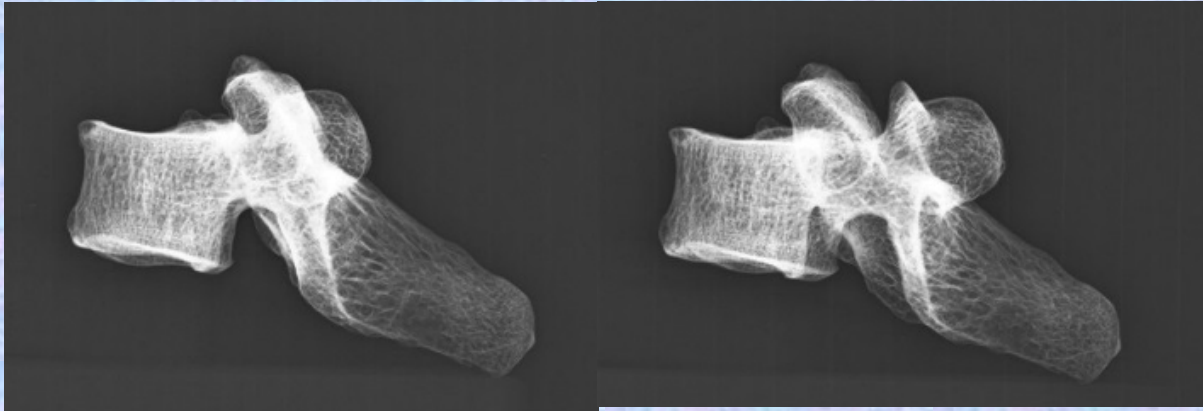
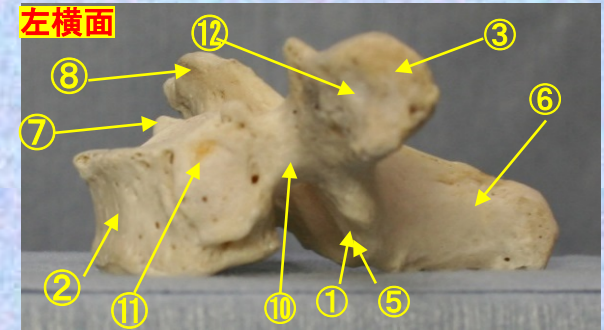
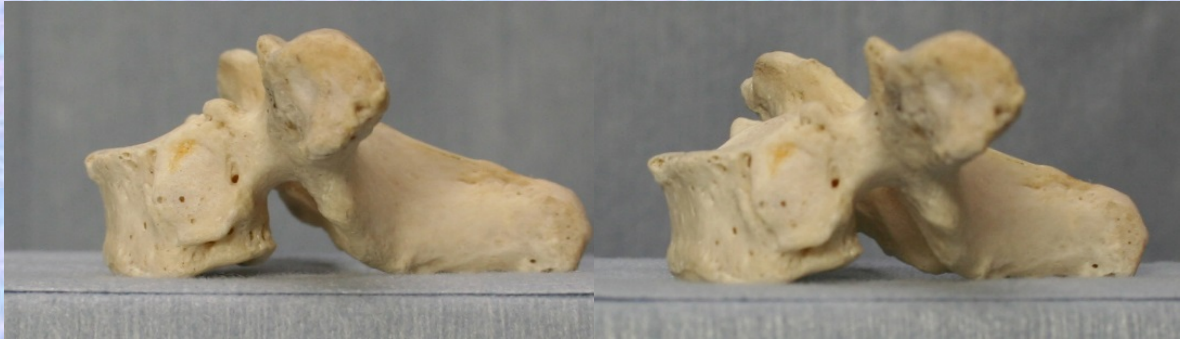- ① 下関節面(下関節突起関節面) inferior articular surface
- ② 椎体 transverse process
- ③ 横突起 transverse process
- ④ 椎弓板 lamina
- ⑤ 下関節突起 inferior articular process
- ⑥ 棘突起 spinous process

- ⑦ 後外側唇 posteriolateral lip
- ⑧ 上関節突起 superior articular process
- ⑨ 椎孔 vertebral foramen
- ⑩ 椎弓根 pedicle
- ⑪ 上肋骨窩 superior costal facet
- ⑫ 横突肋骨窩 costal facet of transverse process
- ⑬ 下肋骨窩 inferior costal facet(TH1にはなし。)



胸椎 Th1 側面

Th1



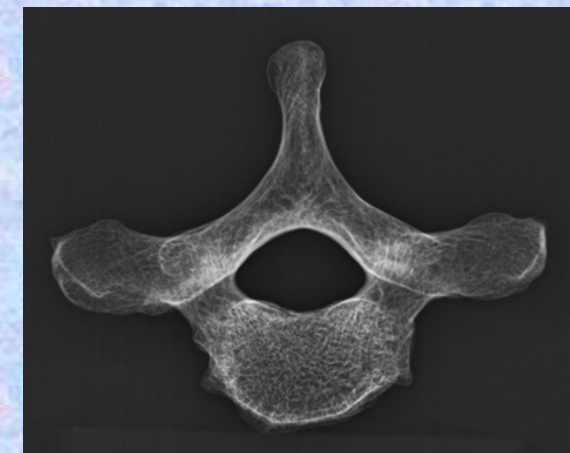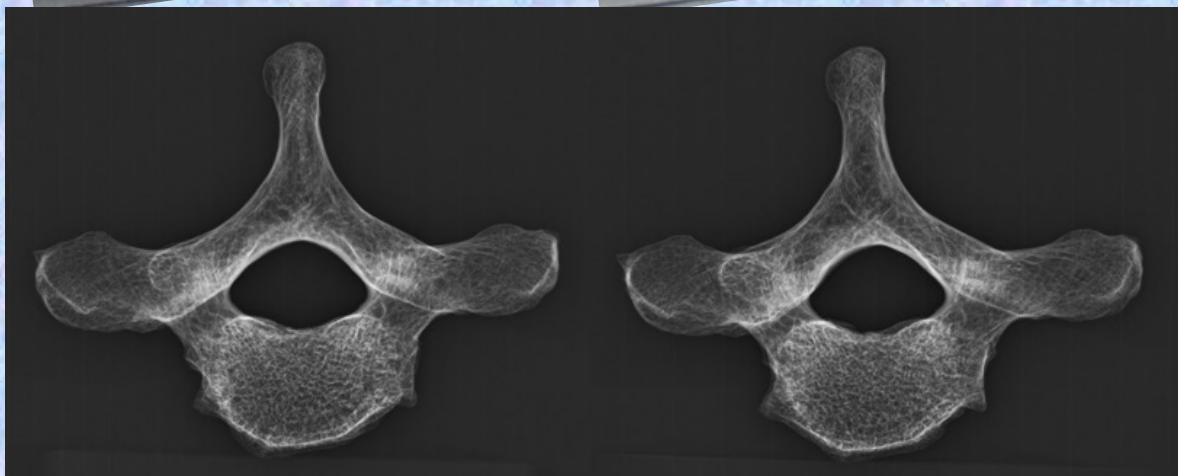
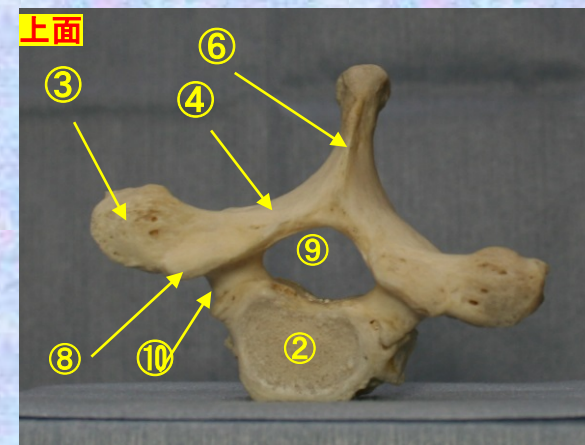
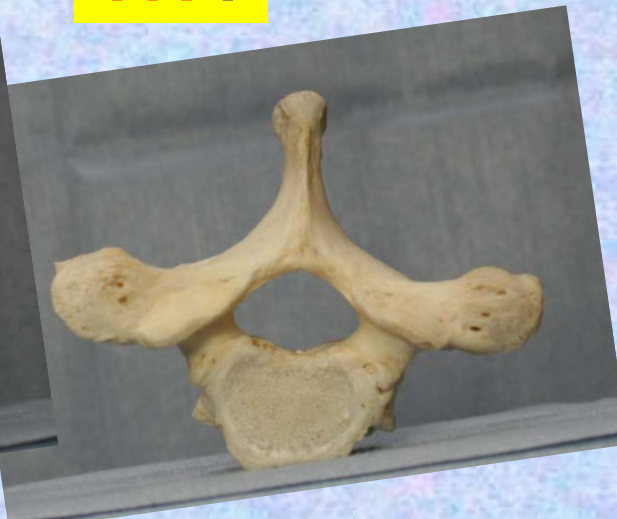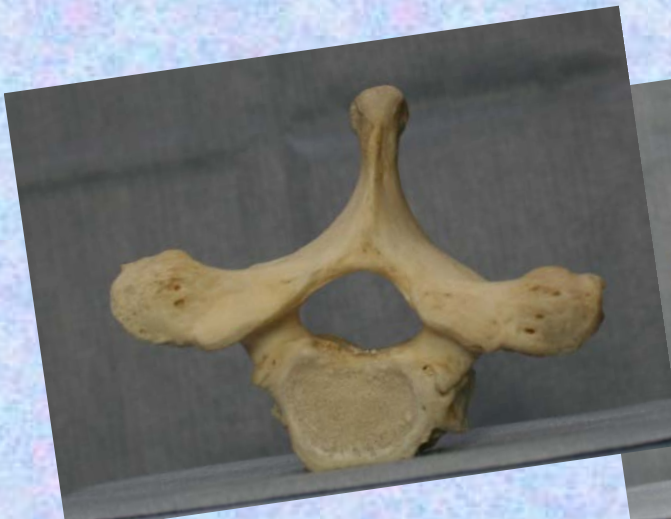- ①下関節面(下関節突起関節面) inferior articular surface
- ②椎体 transverse process
- ③横突起 transverse process
- ④椎弓板 lamina
- ⑤下関節突起 inferior articular process
- ⑥棘突起 spinous process

- ⑦後外側唇 posteriolateral lip
- ⑧上関節突起 superior articular process
- ⑨椎孔 vertebral foramen
- ⑩椎弓根 pedicle
- ⑪上肋骨窩 superior costal facet
- ⑫横突肋骨窩 costal facet of transverse process
- ⑬下肋骨窩 inferior costal facet (TH1にはなし。)



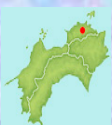胸椎 Th1 上面

Th1



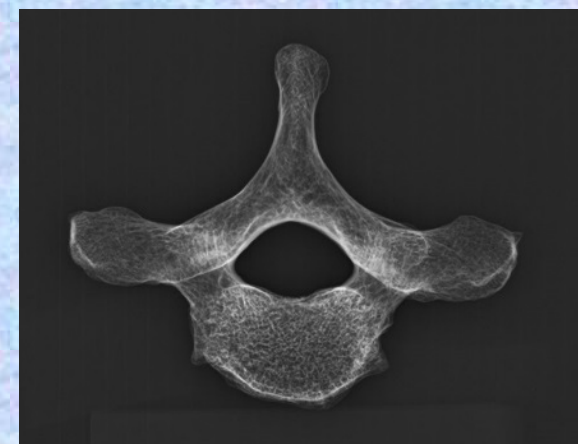
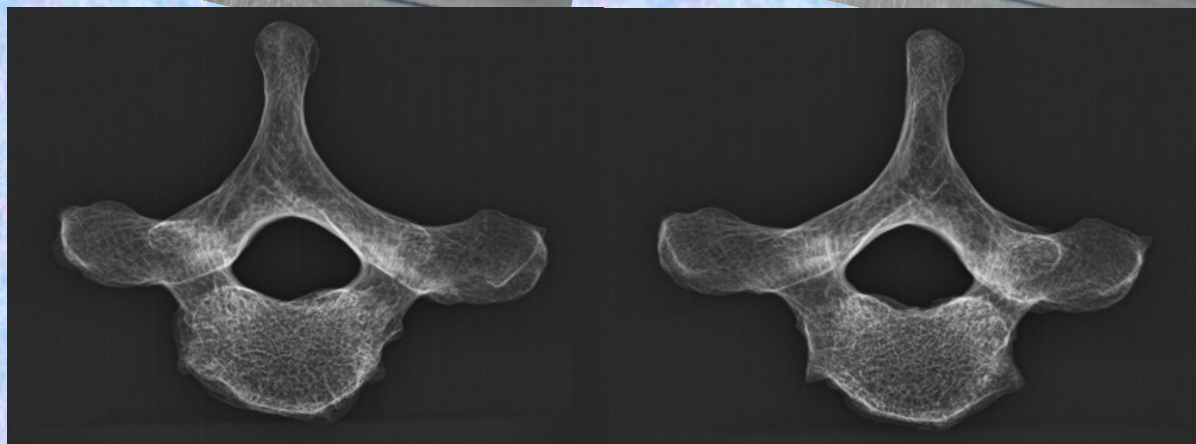
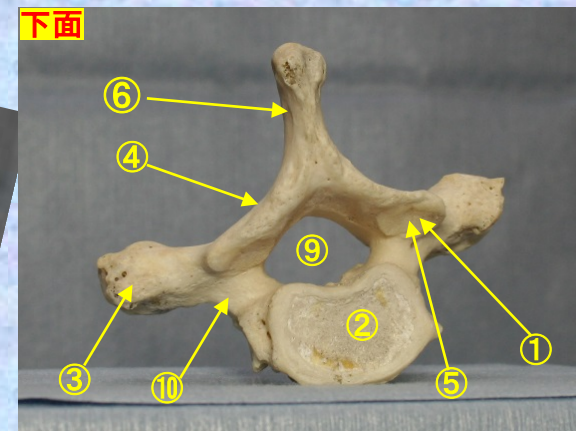
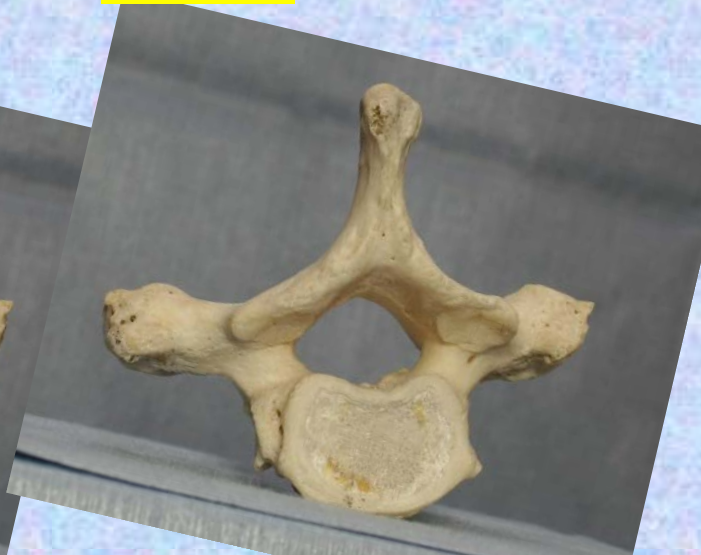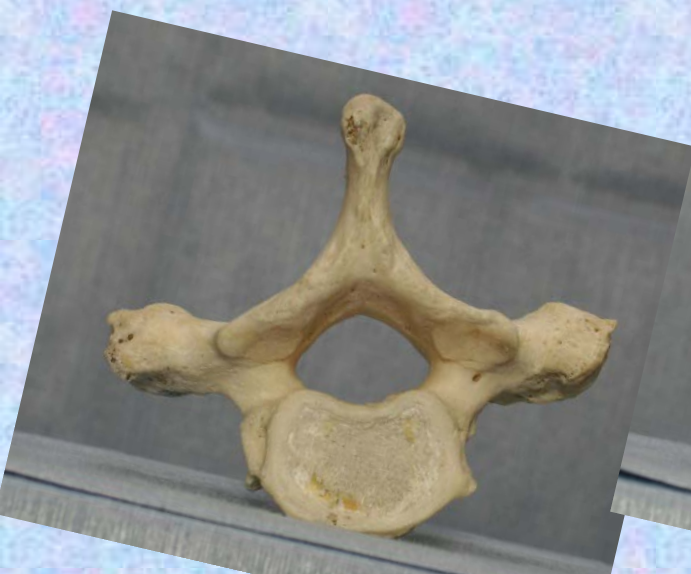
- ①下関節面(下関節突起関節面) inferior articular surface
- ②椎体 transverse process
- ③横突起 transverse process
- ④椎弓板 lamina
- ⑤下関節突起 inferior articular process
- ⑥棘突起 spinous process

- ⑦後外側唇 posteriolateral lip
- ⑧上関節突起 superior articular process
- ⑨椎孔 vertebral foramen
- ⑩椎弓根 pedicle
- ⑪上肋骨窩 superior costal facet
- ⑫横突肋骨窩 costal facet of transverse process
- ⑬下肋骨窩 inferior costal facet (TH1にはなし。)



胸椎 Th1 下面

Th1



- ①下関節面(下関節突起関節面) inferior articular surface
- ②椎体 transverse process
- ③横突起 transverse process
- ④椎弓板 lamina
- ⑤下関節突起 inferior articular process
- ⑥棘突起 spinous process

- ⑦後外側唇 posteriolateral lip
- ⑧上関節突起 superior articular process
- ⑨椎孔 vertebral foramen
- ⑩椎弓根 pedicle
- ⑪上肋骨窩 superior costal facet
- ⑫横突肋骨窩 costal facet of transverse process
- ⑬下肋骨窩 inferior costal facet (TH1にはなし。)

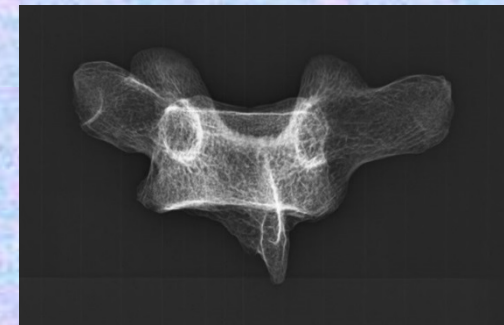
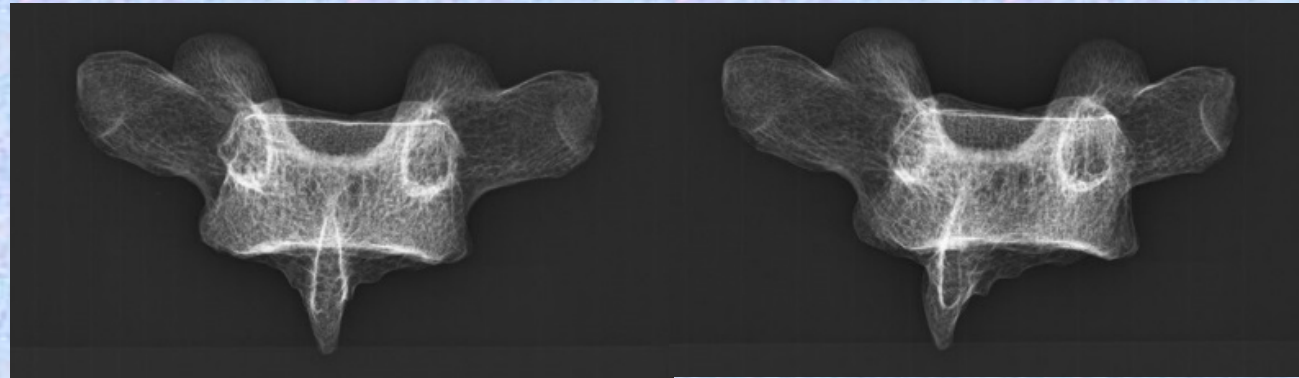
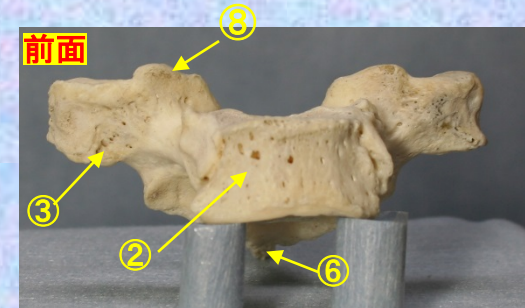
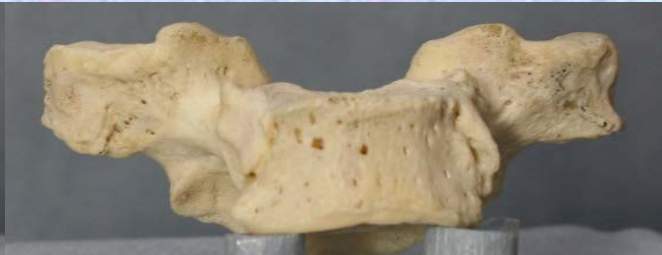
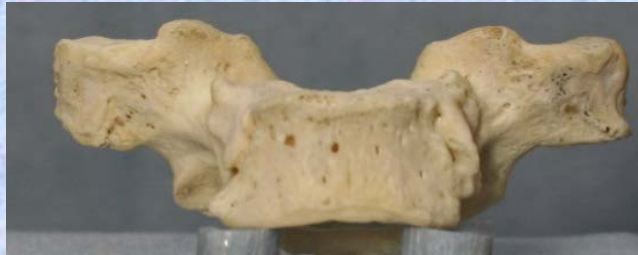
第2胸椎

Thoracic vertebra 2

Th2





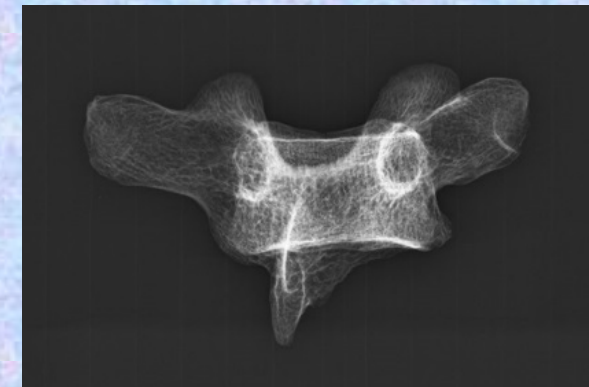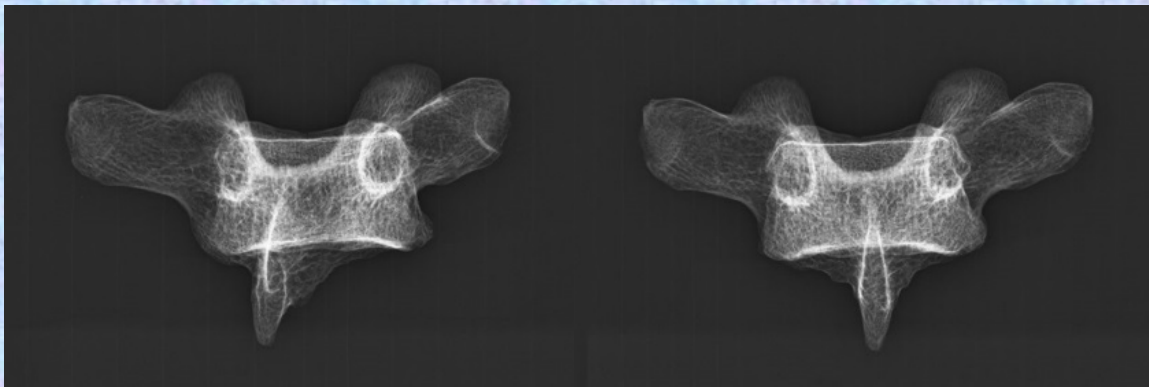
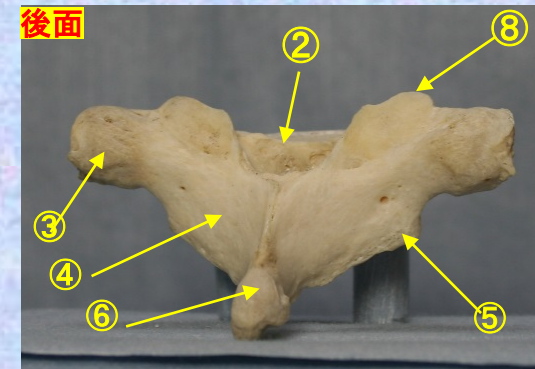
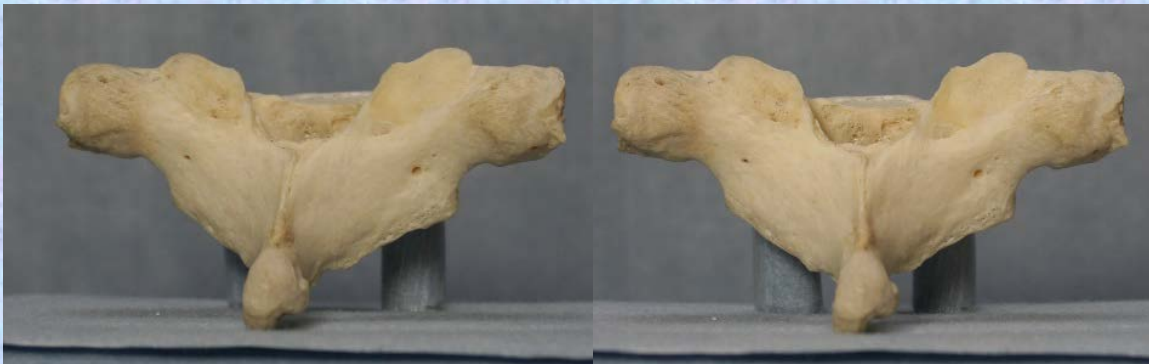- ① 下関節面(下関節突起関節面) inferior articular surface
- ② 椎体 transverse process
- ③ 横突起 transverse process
- ④ 椎弓板 lamina
- ⑤ 下関節突起 inferior articular process
- ⑥ 棘突起 spinous process

- ⑦ 後外側唇 posteriolateral lip
- ⑧ 上関節突起 superior articular process
- ⑨ 椎孔 vertebral foramen
- ⑩ 椎弓根 pedicle
- ⑪ 上肋骨窩 superior costal facet
- ⑫ 横突肋骨窩 costal facet of transverse process
- ⑬ 下肋骨窩 inferior costal facet(TH1にはなし。)



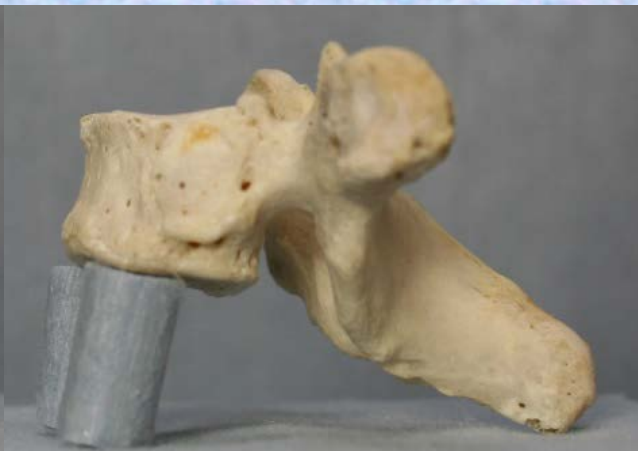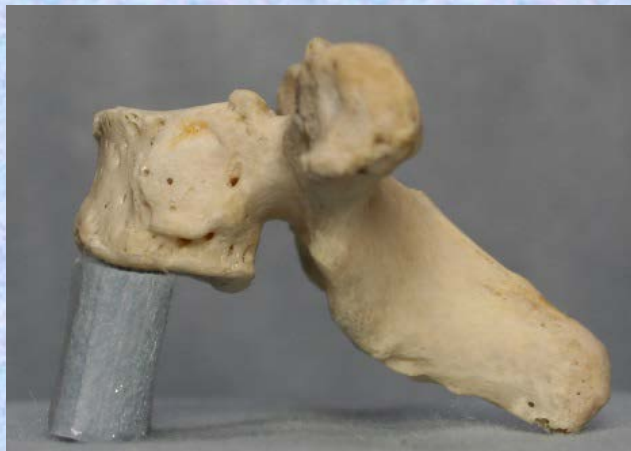胸椎 Th2 後面

Th2

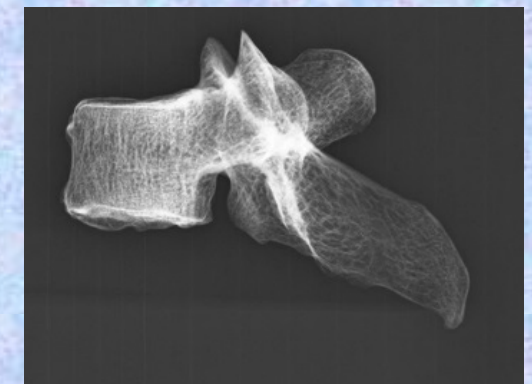
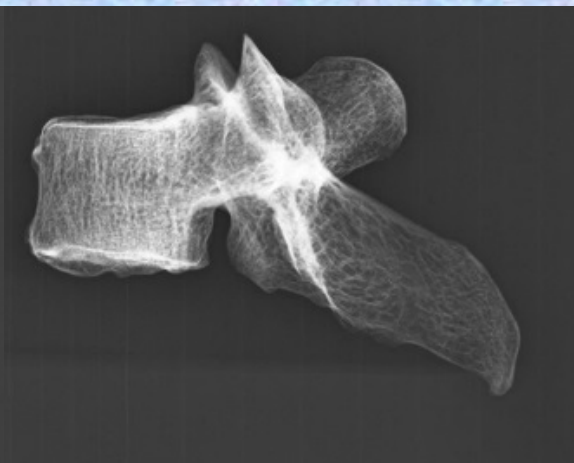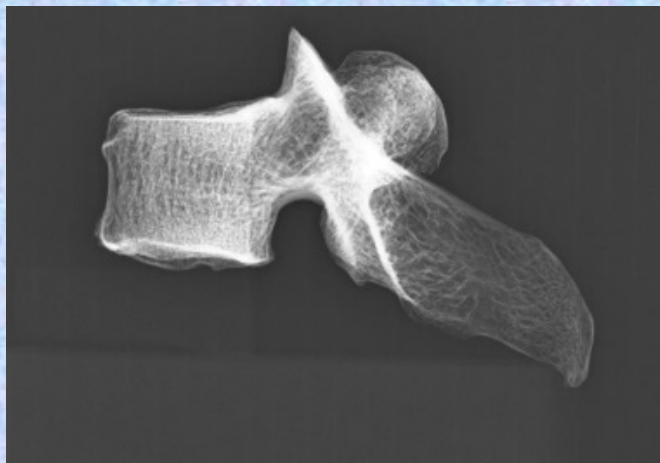
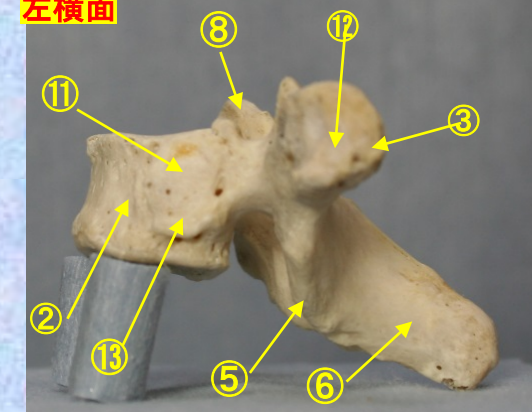


- ① 下関節面(下関節突起関節面) inferior articular surface
- ② 椎体 transverse process
- ③ 横突起 transverse process
- ④ 椎弓板 lamina
- ⑤ 下関節突起 inferior articular process
- ⑥ 棘突起 spinous process

- ⑦ 後外側唇 posteriolateral lip
- ⑧ 上関節突起 superior articular process
- ⑨ 椎孔 vertebral foramen
- ⑩ 椎弓根 pedicle
- ⑪ 上肋骨窩 superior costal facet
- ⑫ 横突肋骨窩 costal facet of transverse process
- ⑬ 下肋骨窩 inferior costal facet (TH1にはなし。)



左横面



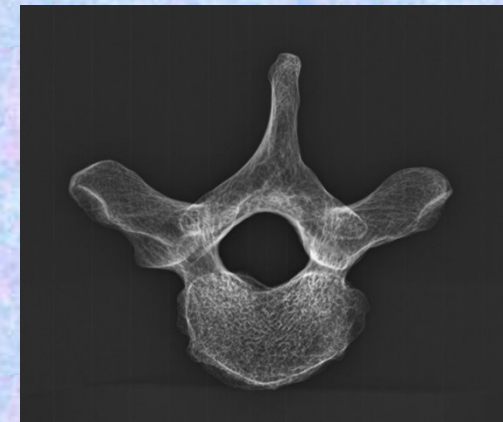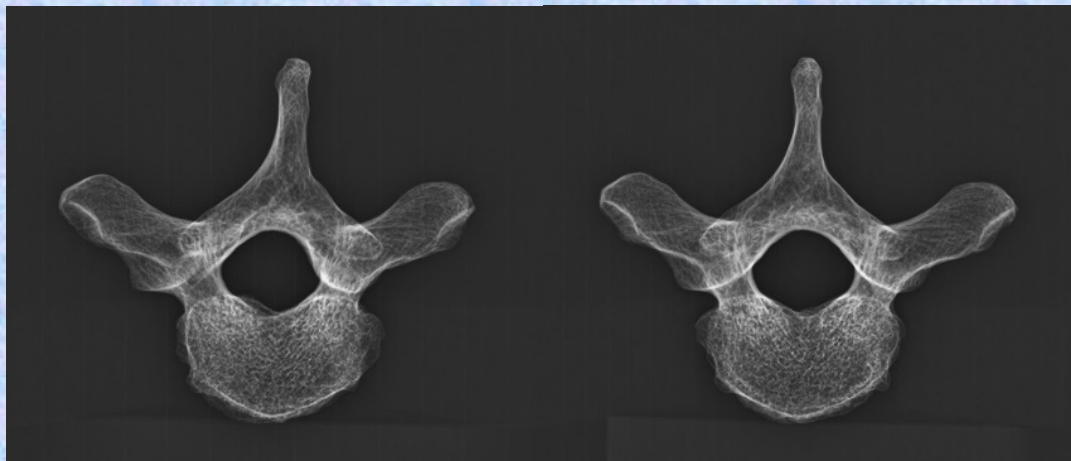
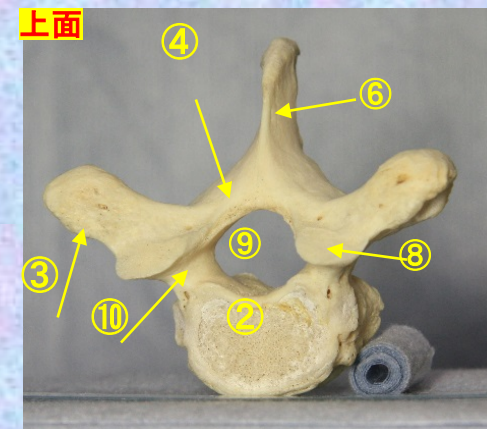
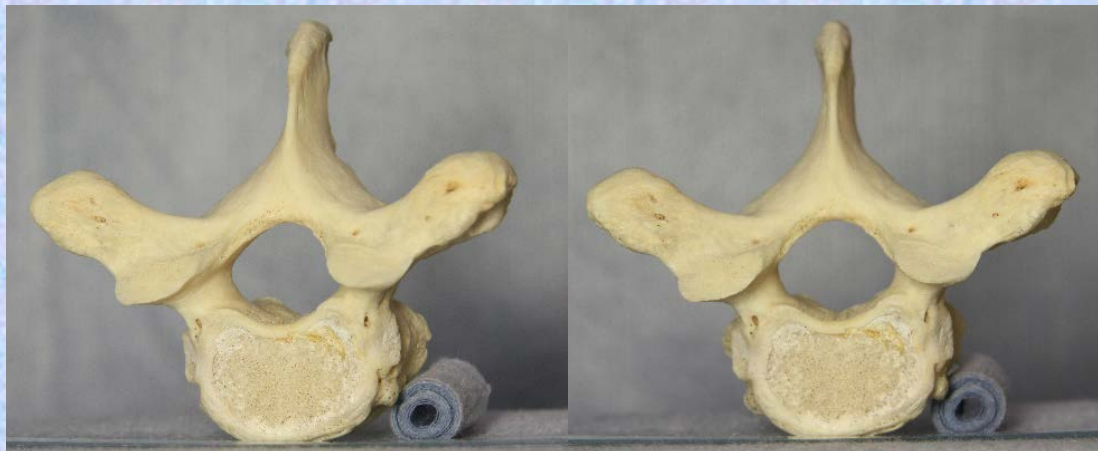- ①下関節面(下関節突起関節面) inferior articular surface
- ②椎体 transverse process
- ③横突起 transverse process
- ④椎弓板 lamina
- ⑤下関節突起 inferior articular process
- ⑥棘突起 spinous process

- ⑦後外側唇 posteriolateral lip
- ⑧上関節突起 superior articular process
- ⑨椎孔 vertebral foramen
- ⑩椎弓根 pedicle
- ⑪上肋骨窩 superior costal facet
- ⑫横突肋骨窩 costal facet of transverse process
- ⑬下肋骨窩 inferior costal facet (TH1にはなし。)



胸椎 Th2 上面

Th2

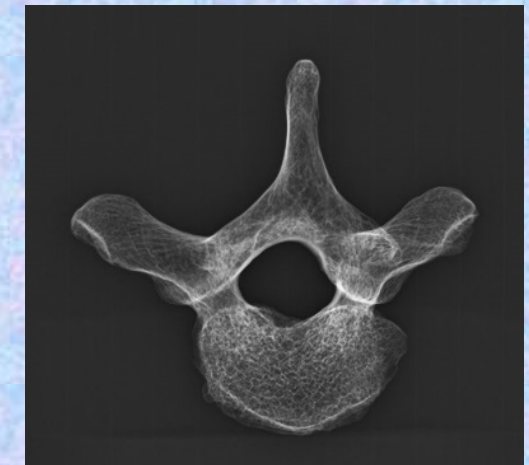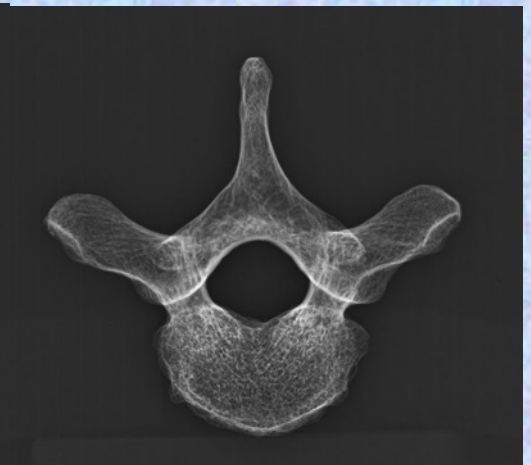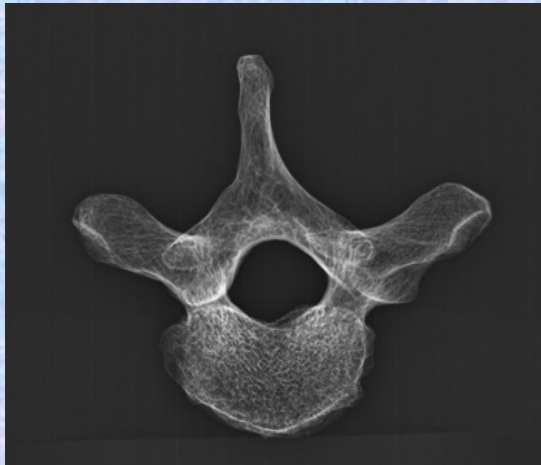
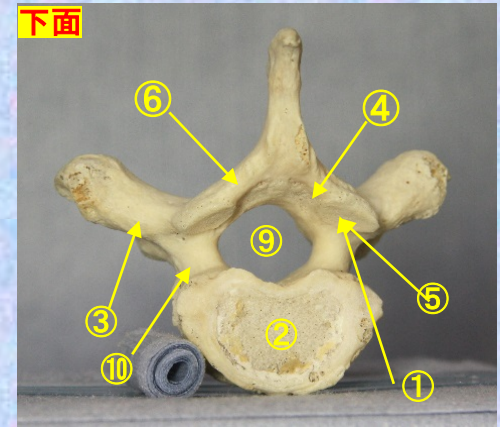


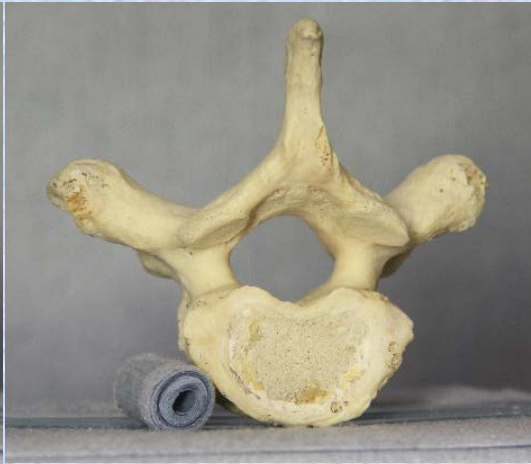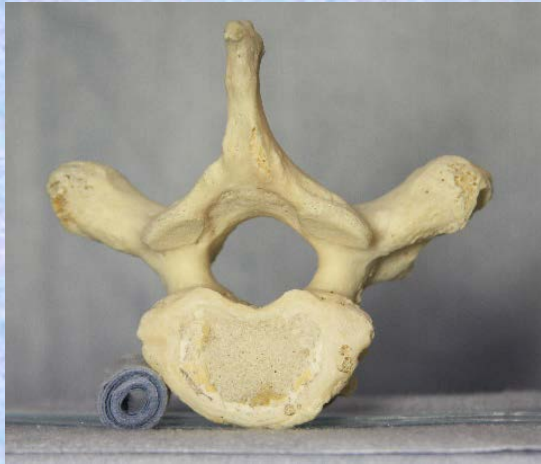- ① 下関節面(下関節突起関節面) inferior articular surface
- ② 椎体 transverse process
- ③ 横突起 transverse process
- ④ 椎弓板 lamina
- ⑤ 下関節突起 inferior articular process
- ⑥ 棘突起 spinous process

- ⑦ 後外側唇 posteriolateral lip
- ⑧ 上関節突起 superior articular process
- ⑨ 椎孔 vertebral foramen
- ⑩ 椎弓根 pedicle
- ⑪ 上肋骨窩 superior costal facet
- ⑫ 横突肋骨窩 costal facet of transverse process
- ⑬ 下肋骨窩 inferior costal facet (TH1にはなし。)

胸椎 Th2 下面

Th2



- ① 下関節面(下関節突起関節面) inferior articular surface
- ② 椎体 transverse process
- ③ 横突起 transverse process
- ④ 椎弓板 lamina
- ⑤ 下関節突起 inferior articular process
- ⑥ 棘突起 spinous process

- ⑦ 後外側唇 posteriolateral lip
- ⑧ 上関節突起 superior articular process
- ⑨ 椎孔 vertebral foramen
- ⑩ 椎弓根 pedicle
- ⑪ 上肋骨窩 superior costal facet
- ⑫ 横突肋骨窩 costal facet of transverse process
- ⑬ 下肋骨窩 inferior costal facet (TH1にはなし。)

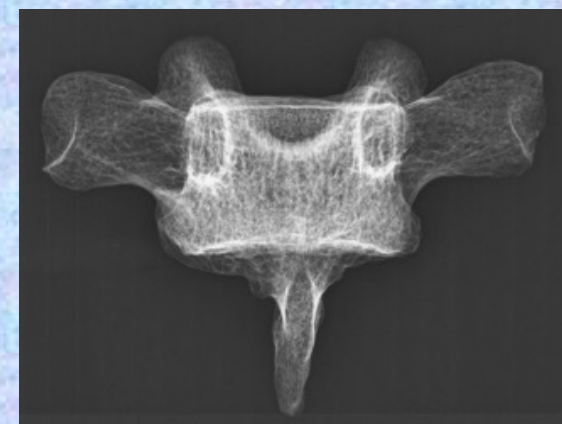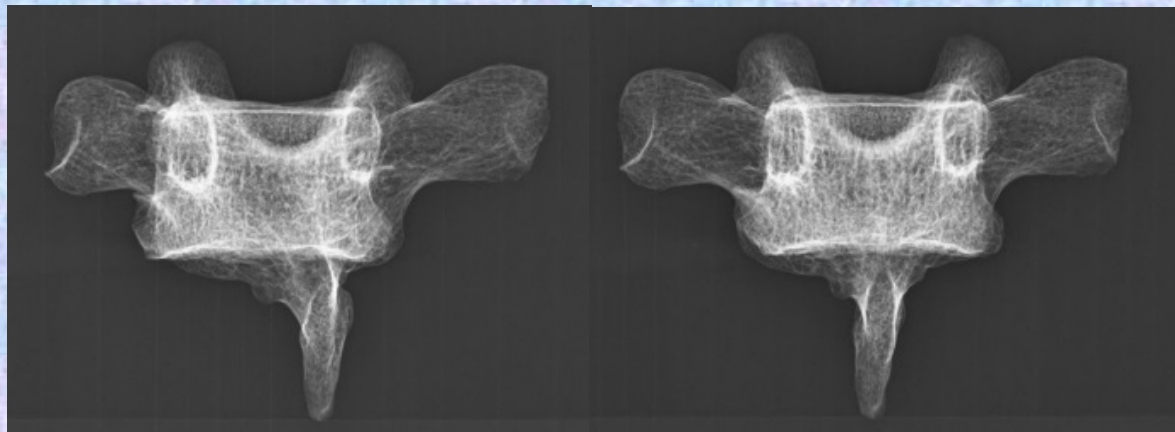
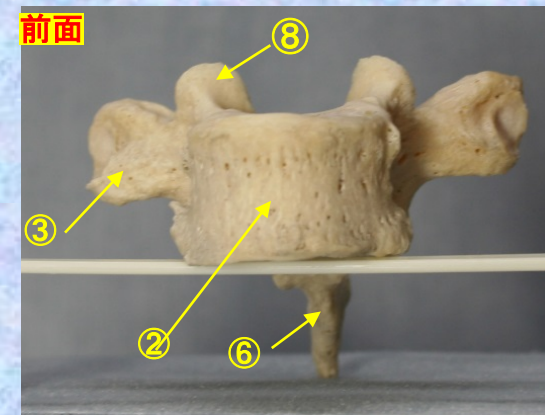

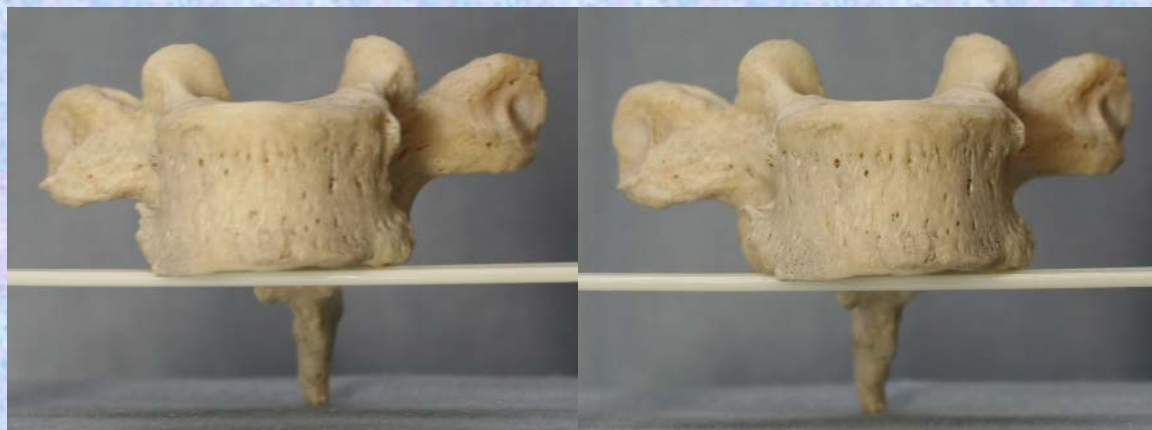
第3胸椎

Thoracic vertebra 3

Th3





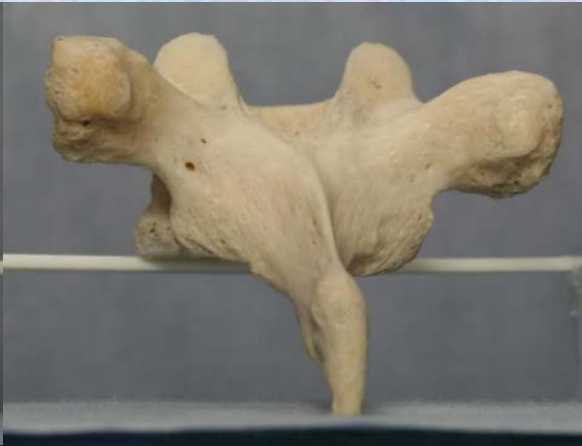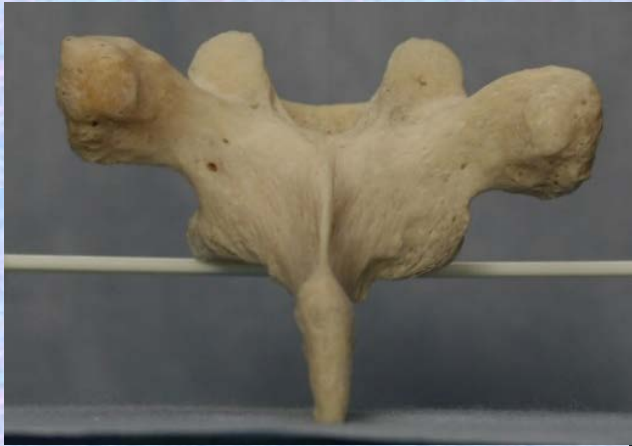- ① 下関節面(下関節突起関節面) inferior articular surface
- ② 椎体 transverse process
- ③ 横突起 transverse process
- ④ 椎弓板 lamina
- ⑤ 下関節突起 inferior articular process
- ⑥ 棘突起 spinous process

- ⑦ 後外側唇 posteriolateral lip
- ⑧ 上関節突起 superior articular process
- ⑨ 椎孔 vertebral foramen
- ⑩ 椎弓根 pedicle
- ⑪ 上肋骨窩 superior costal facet
- ⑫ 横突肋骨窩 costal facet of transverse process
- ⑬ 下肋骨窩 inferior costal facet (TH1にはなし。)

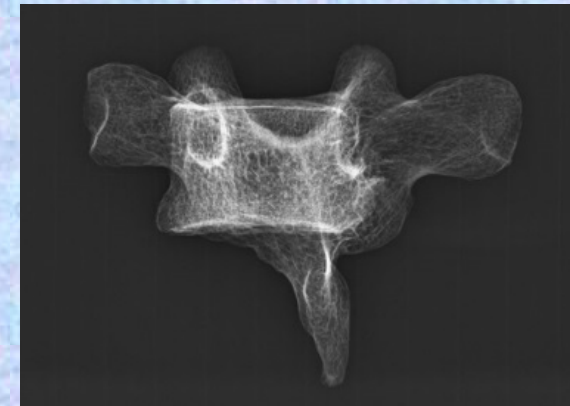
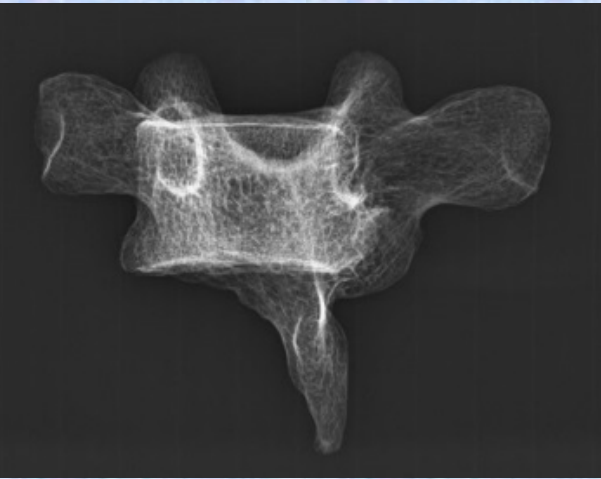
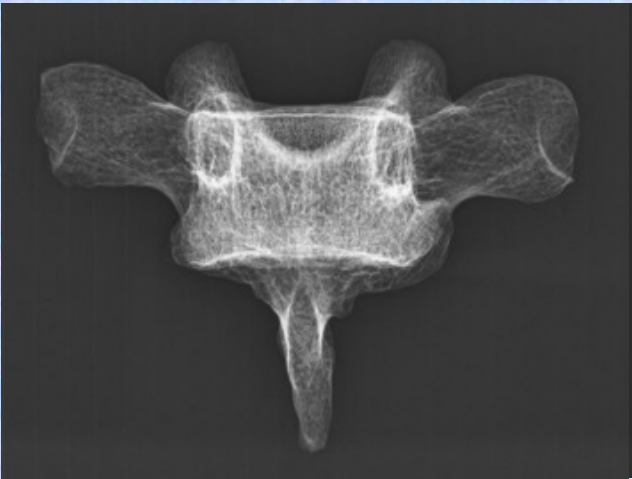
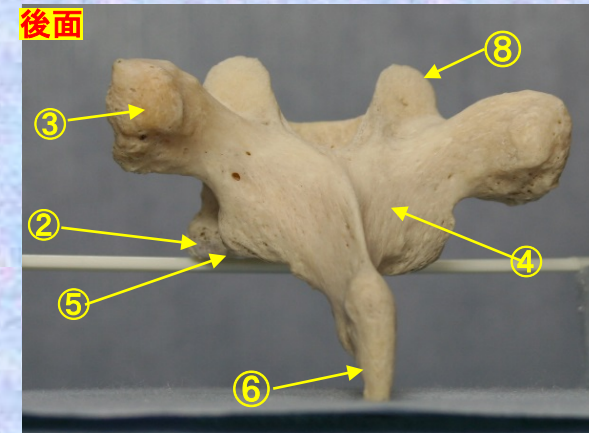


胸椎 Th3 後面

Th3



後面



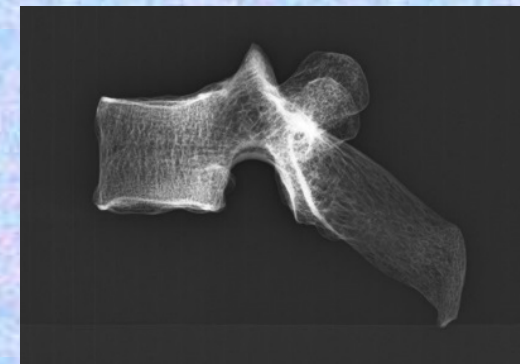
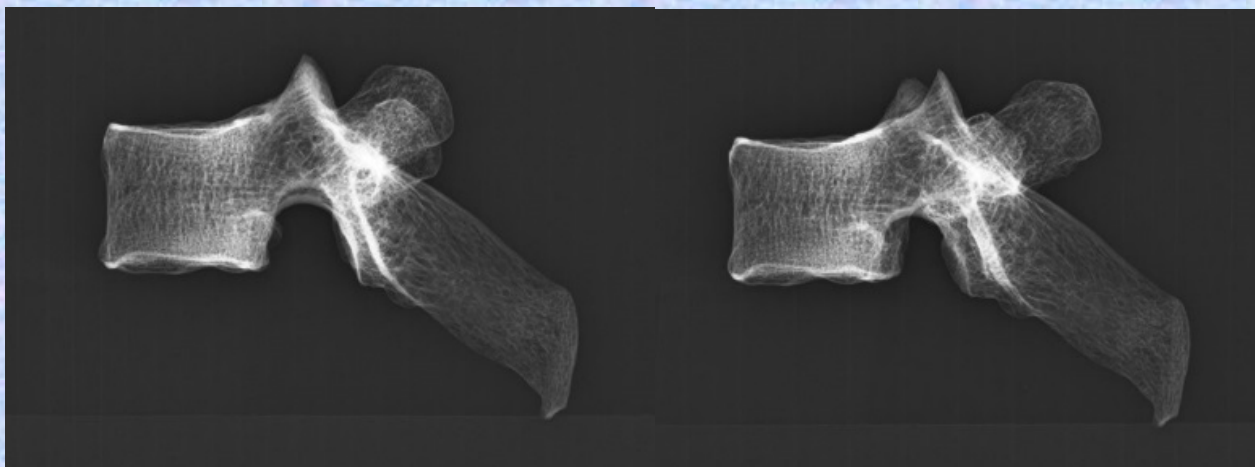
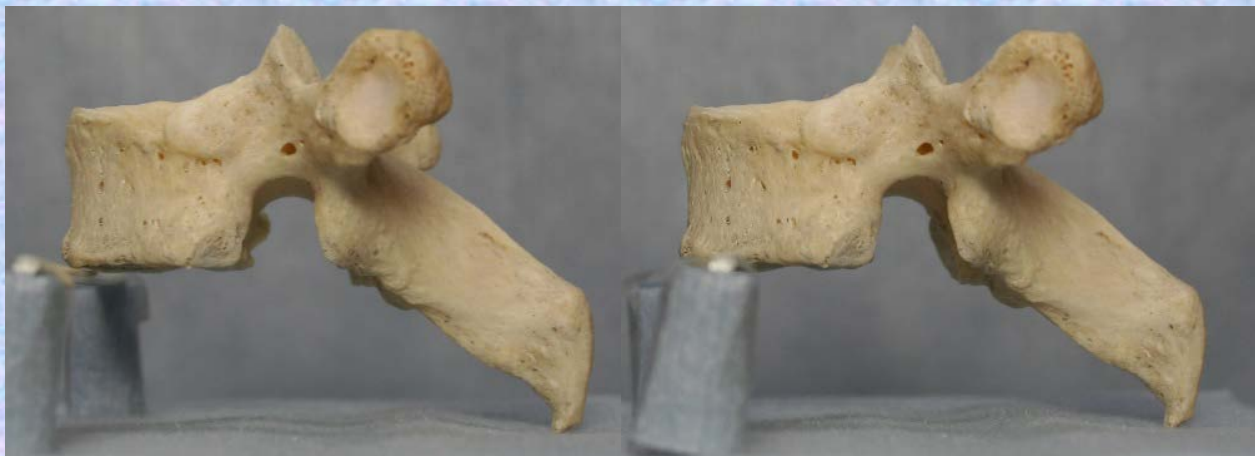
- ①下関節面(下関節突起関節面) inferior articular surface
- ②椎体 transverse process
- ③横突起 transverse process
- ④椎弓板 lamina
- ⑤下関節突起 inferior articular process
- ⑥棘突起 spinous process

- ⑦後外側唇 posteriolateral lip
- ⑧上関節突起 superior articular process
- ⑨椎孔 vertebral foramen
- ⑩椎弓根 pedicle
- ⑪上肋骨窩 superior costal facet
- ⑫横突肋骨窩 costal facet of transverse process
- ⑬下肋骨窩 inferior costal facet (TH1にはなし。)



胸椎 Th3 側面

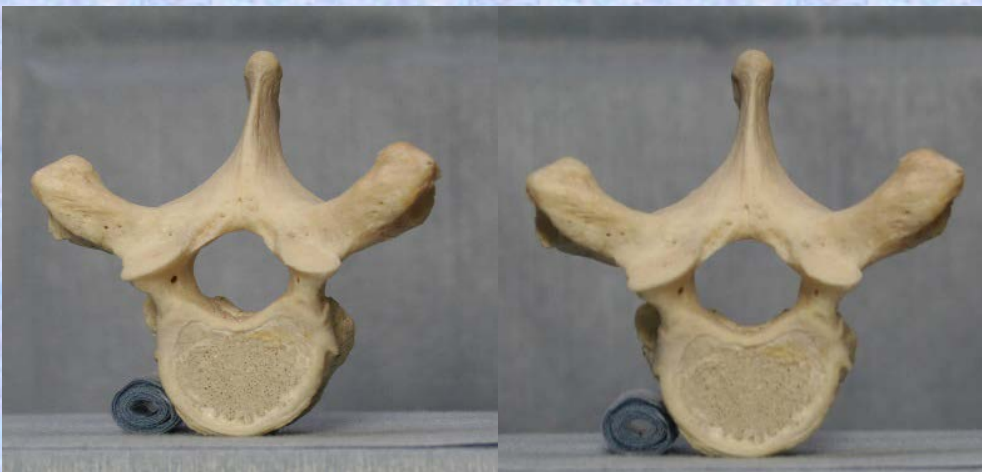Th3



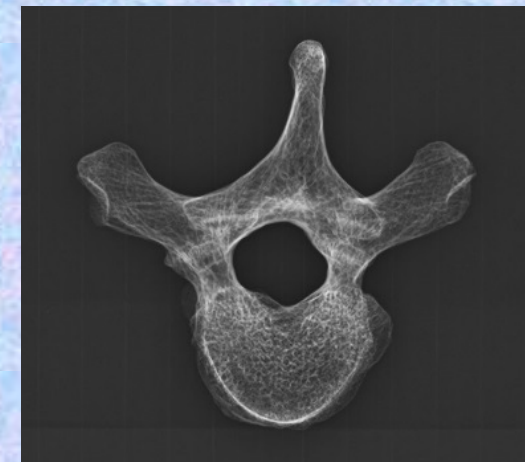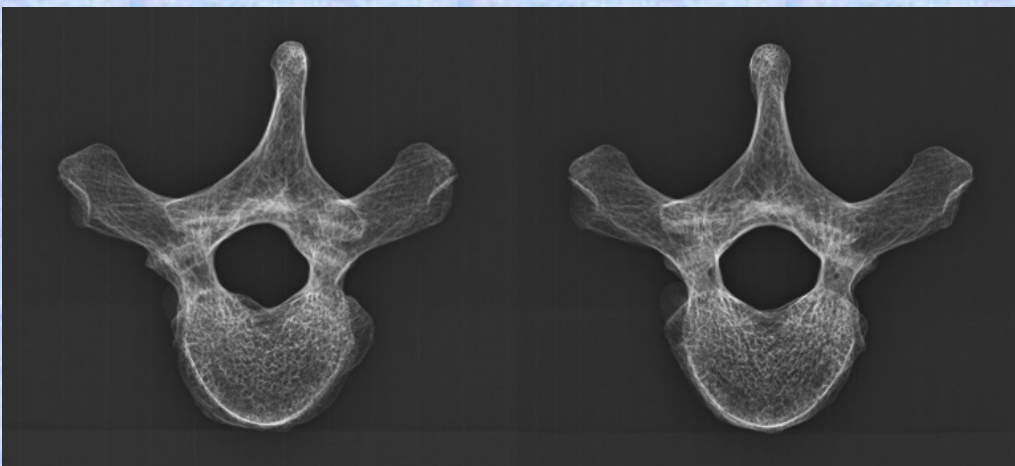
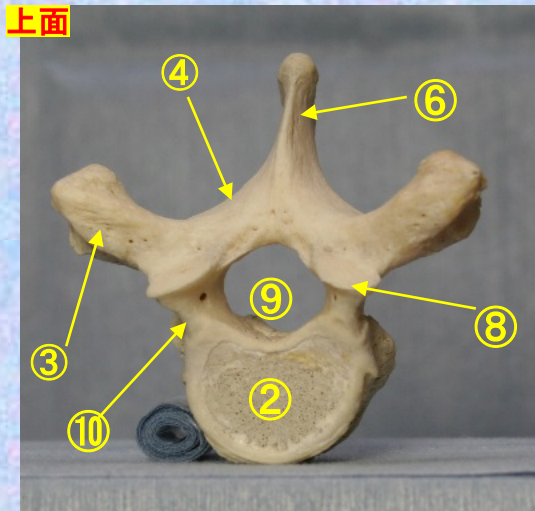
- ①下関節面(下関節突起関節面) inferior articular surface
- ②椎体 transverse process
- ③横突起 transverse process
- ④椎弓板 lamina
- ⑤下関節突起 inferior articular process
- ⑥棘突起 spinous process

- ⑦後外側唇 posteriolateral lip
- ⑧上関節突起 superior articular process
- ⑨椎孔 vertebral foramen
- ⑩椎弓根 pedicle
- ⑪上肋骨窩 superior costal facet
- ⑫横突肋骨窩 costal facet of transverse process
- ⑬下肋骨窩 inferior costal facet(TH1にはなし。)





上面

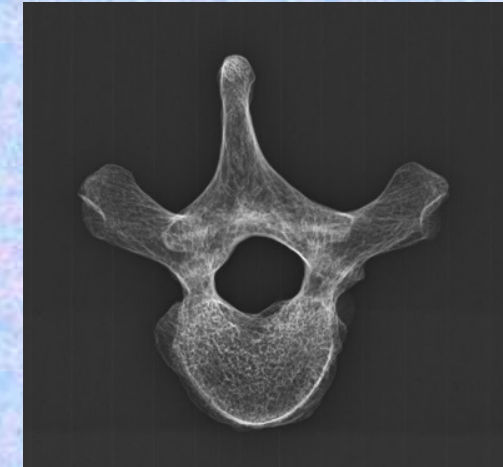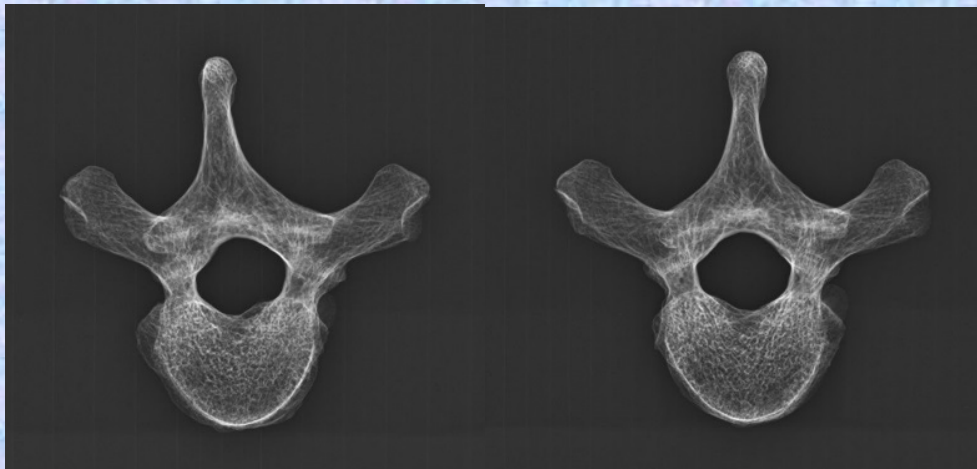
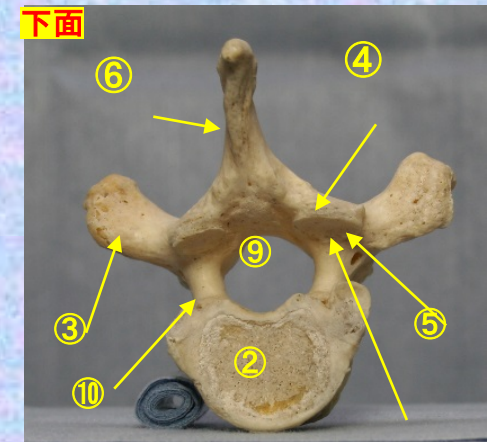

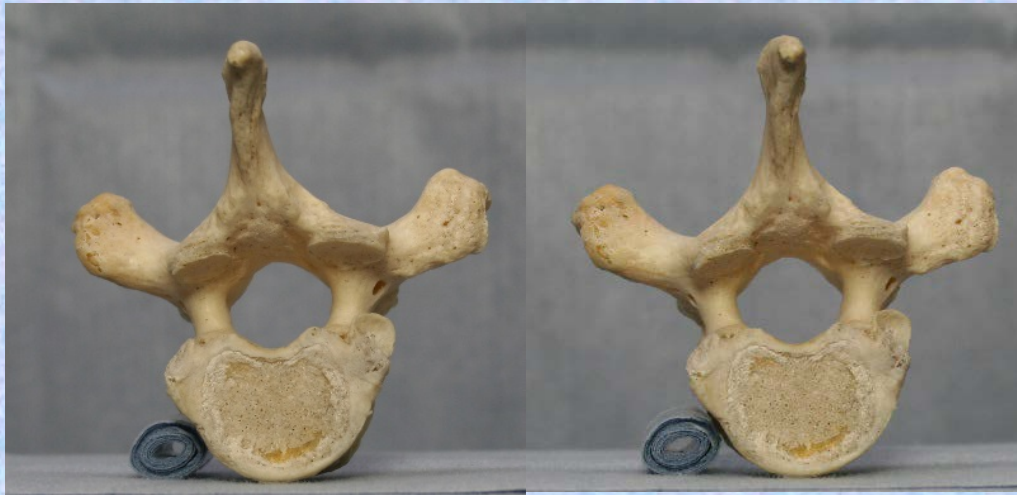
- ① 下関節面(下関節突起関節面) inferior articular surface
- ② 椎体 transverse process
- ③ 横突起 transverse process
- ④ 椎弓板 lamina
- ⑤ 下関節突起 inferior articular process
- ⑥ 棘突起 spinous process

- ⑦ 後外側唇 posteriolateral lip
- ⑧ 上関節突起 superior articular process
- ⑨ 椎孔 vertebral foramen
- ⑩ 椎弓根 pedicle
- ⑪ 上肋骨窩 superior costal facet
- ⑫ 横突肋骨窩 costal facet of transverse process
- ⑬ 下肋骨窩 inferior costal facet (TH1にはなし。)

胸椎 Th3 下面

Th3



- ① 下関節面(下関節突起関節面) inferior articular surface
- ② 椎体 transverse process
- ③ 横突起 transverse process
- ④ 椎弓板 lamina
- ⑤ 下関節突起 inferior articular process
- ⑥ 棘突起 spinous process

- ⑦ 後外側唇 posteriolateral lip
- ⑧ 上関節突起 superior articular process
- ⑨ 椎孔 vertebral foramen
- ⑩ 椎弓根 pedicle
- ⑪ 上肋骨窩 superior costal facet
- ⑫ 横突肋骨窩 costal facet of transverse process
- ⑬ 下肋骨窩 inferior costal facet (TH1にはなし。)

第4胸椎

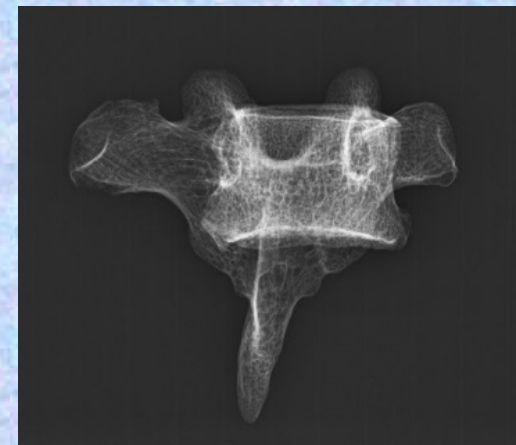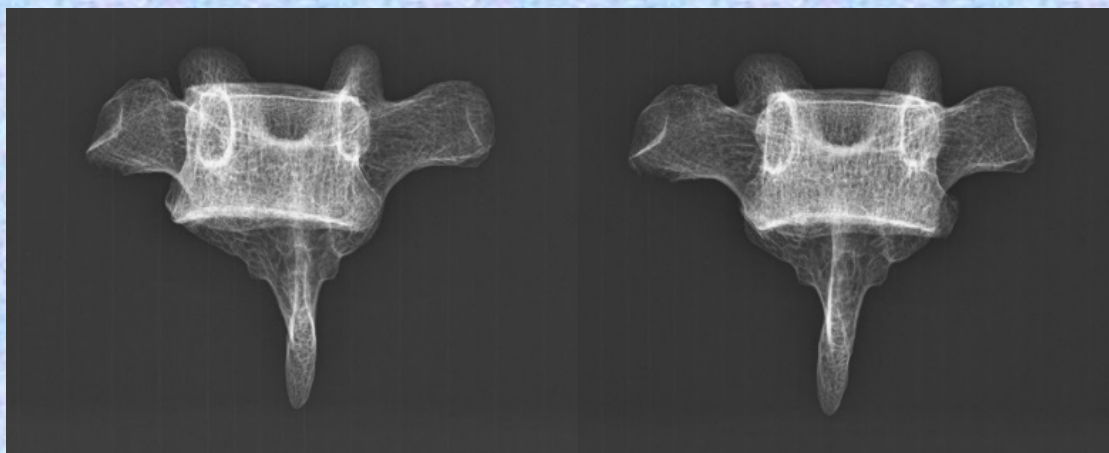

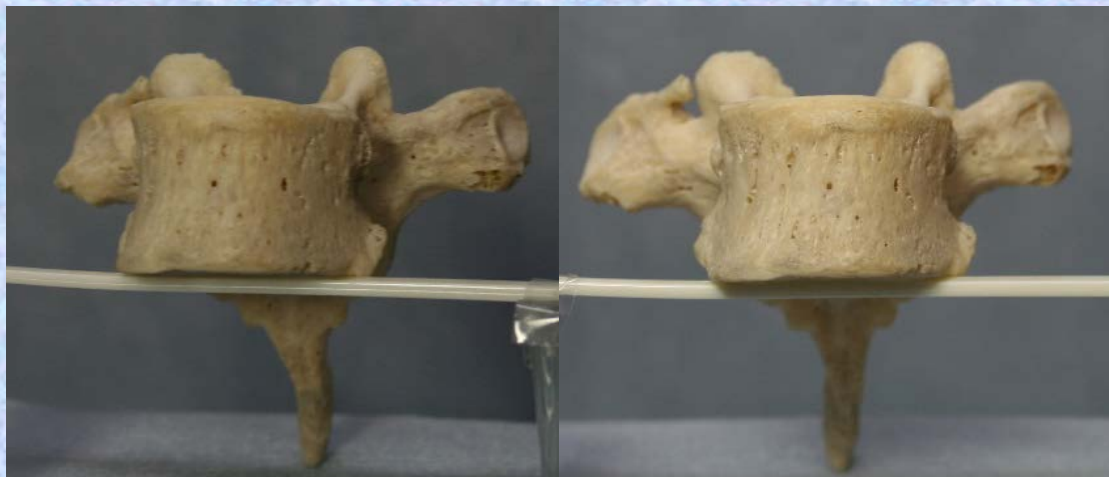Thoracic vertebra 4

Th4



胸椎 Th4 前面

Th4



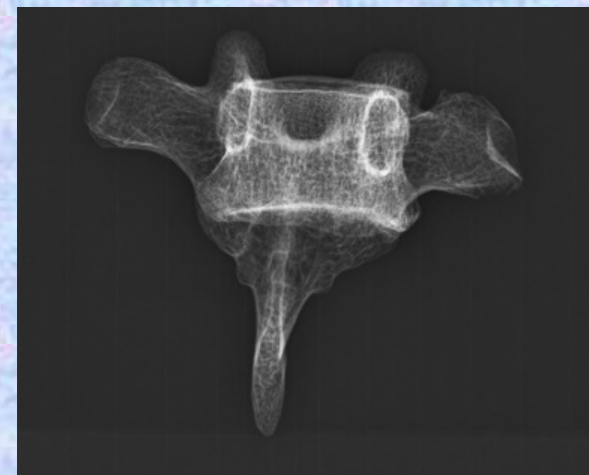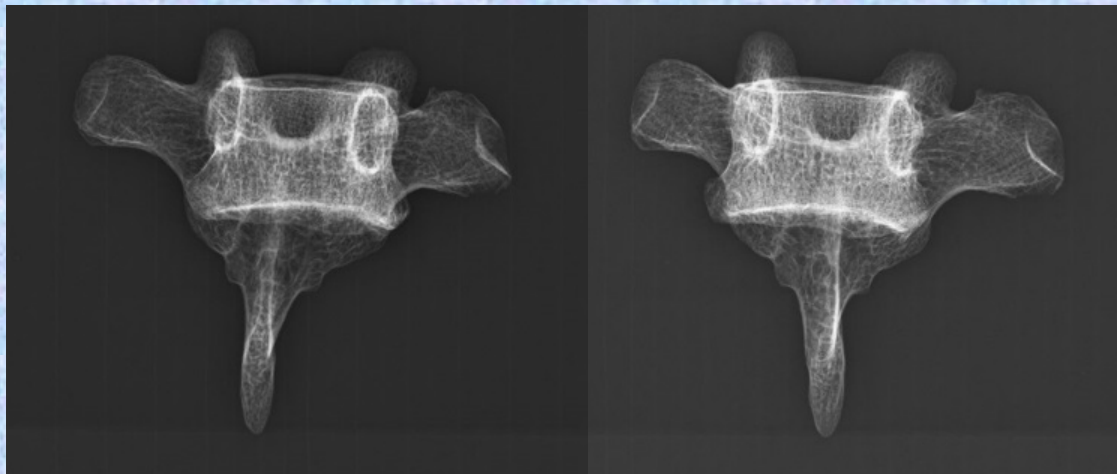
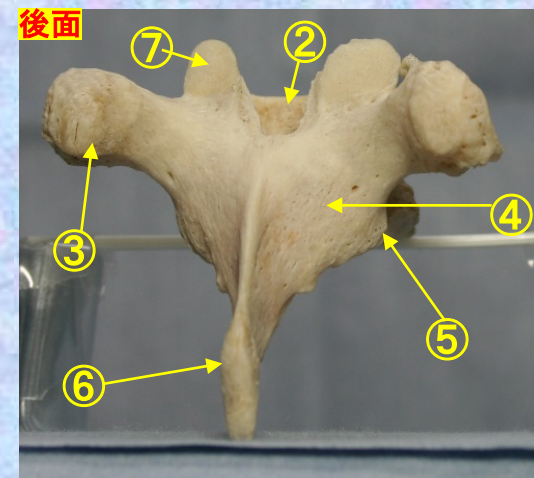
- ① 下関節面(下関節突起関節面) inferior articular surface
- ② 椎体 transverse process
- ③ 横突起 transverse process
- ④ 椎弓板 lamina
- ⑤ 下関節突起 inferior articular process
- ⑥ 棘突起 spinous process

- ⑦ 上関節突起 superior articular process
- ⑧ 椎孔 vertebral foramen
- ⑨ 椎弓根 pedicle
- ⑩ 上肋骨窩 superior costal facet
- ⑪ 横突肋骨窩 costal facet of transverse process
- ⑫ 下肋骨窩 inferior costal facet



胸椎 Th4 後面

Th4



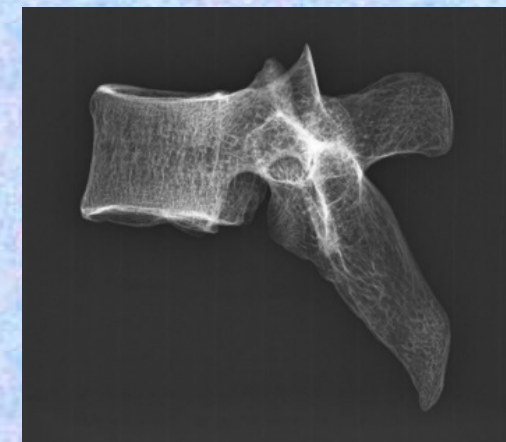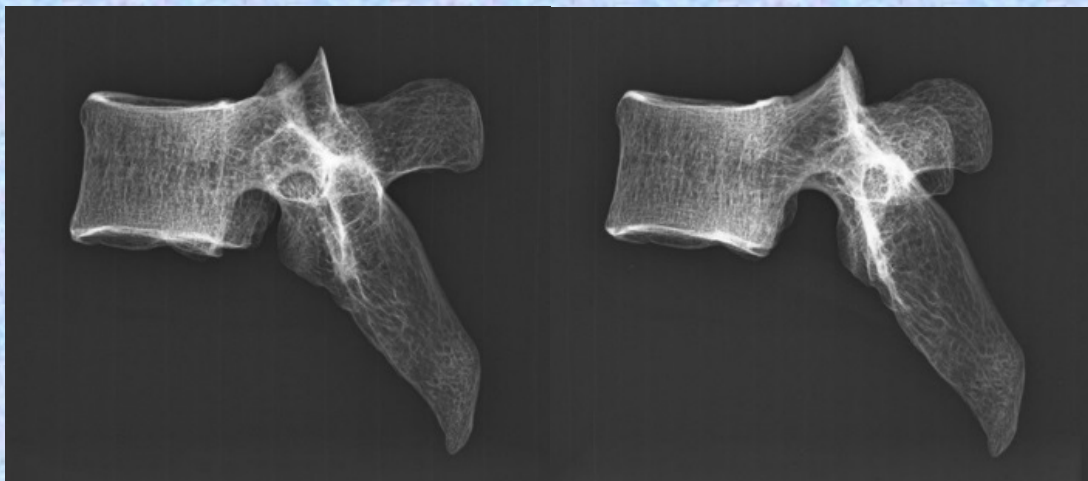
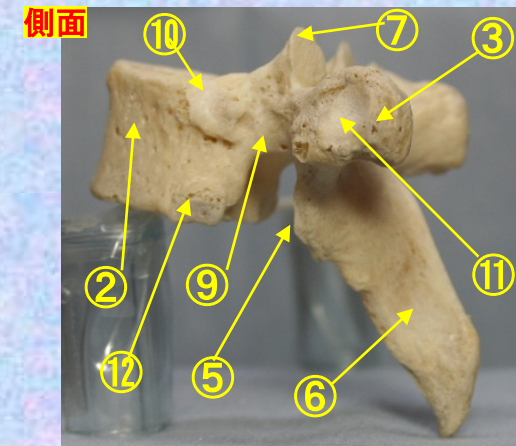
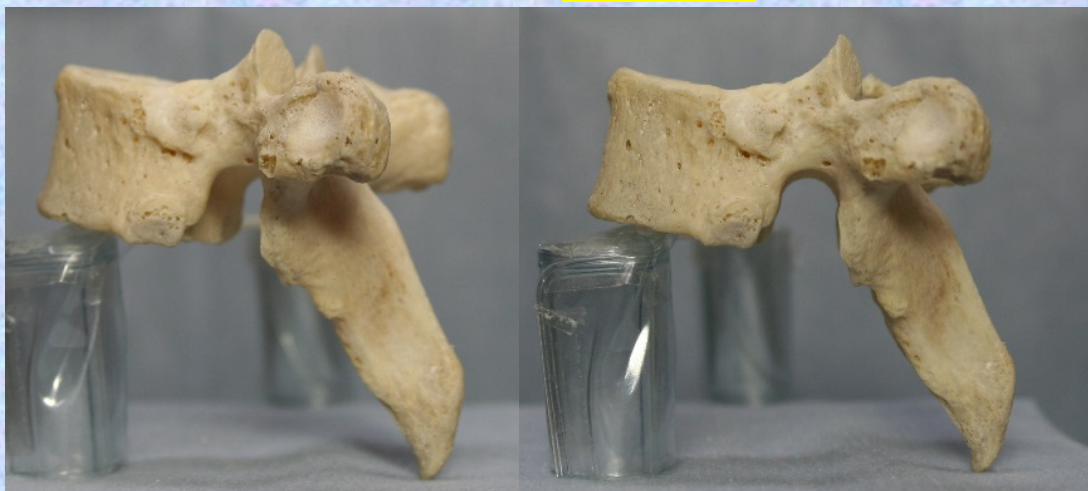- ①下関節面(下関節突起関節面) inferior articular surface
- ②椎体 transverse process
- ③横突起 transverse process
- ④椎弓板 lamina
- ⑤下関節突起 inferior articular process
- ⑥棘突起 spinous process

- ⑦上関節突起 superior articular process
- ⑧椎孔 vertebral foramen
- ⑨椎弓根 pedicle
- ⑩上肋骨窩 superior costal facet
- ⑪横突肋骨窩 costal facet of transverse process
- ⑫下肋骨窩 inferior costal facet



胸椎 Th4 側面

Th4



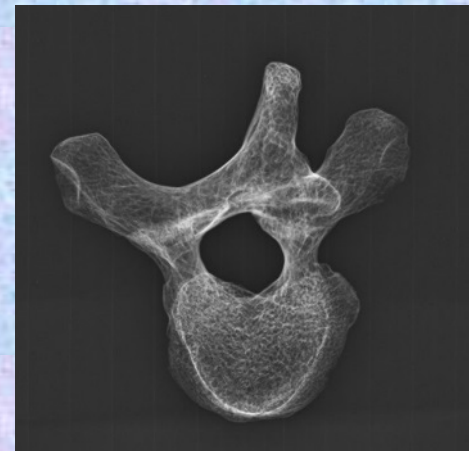
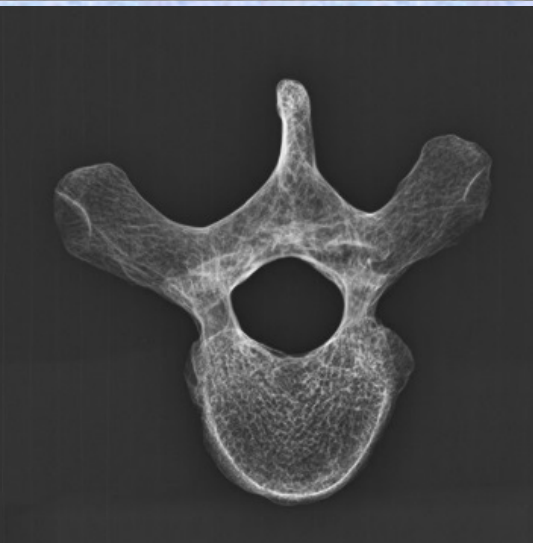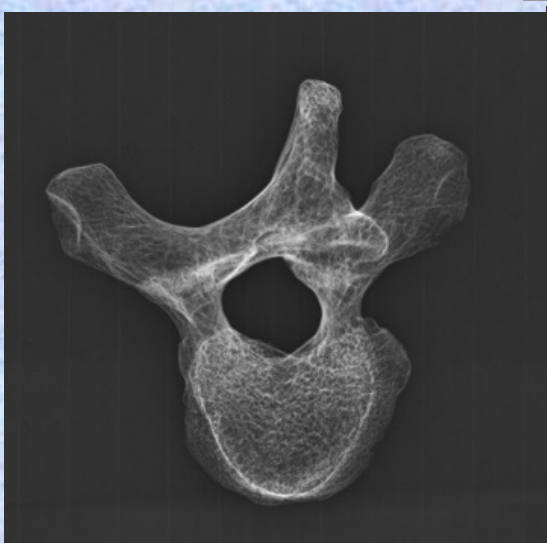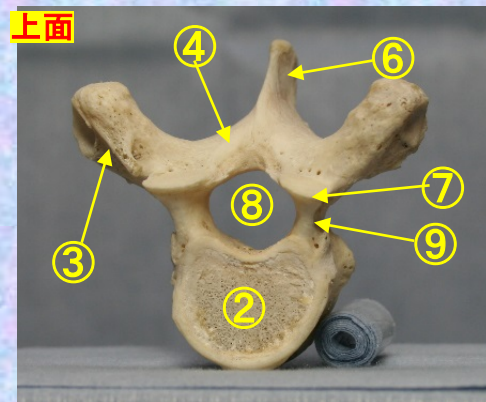
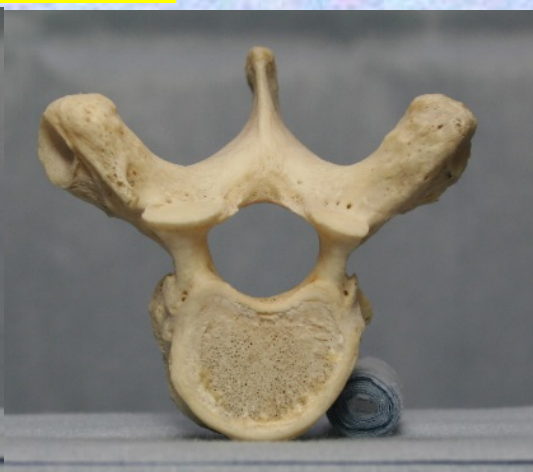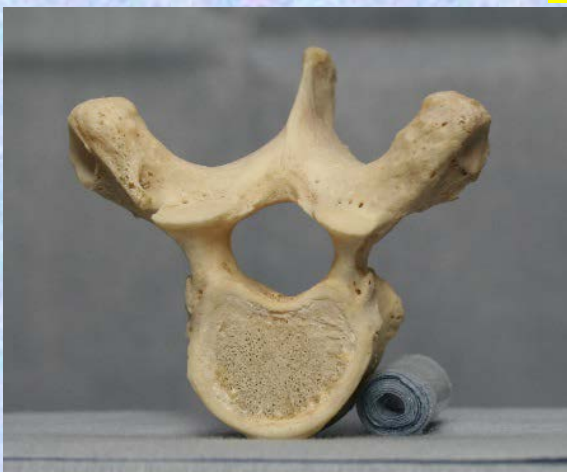- ① 下関節面(下関節突起関節面) inferior articular surface
- ② 椎体 transverse process
- ③ 横突起 transverse process
- ④ 椎弓板 lamina
- ⑤ 下関節突起 inferior articular process
- ⑥ 棘突起 spinous process

- ⑦ 上関節突起 superior articular process
- ⑧ 椎孔 vertebral foramen
- ⑨ 椎弓根 pedicle
- ⑩ 上肋骨窩 superior costal facet
- ⑪ 横突肋骨窩 costal facet of transverse process
- ⑫ 下肋骨窩 inferior costal facet



胸椎 Th4 上面

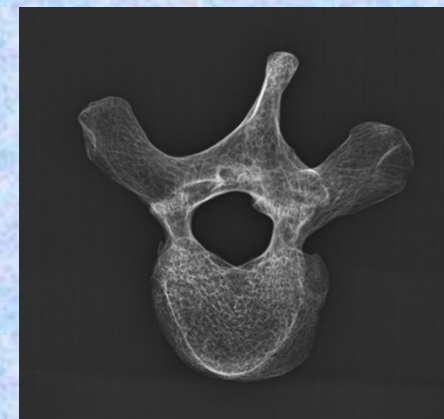
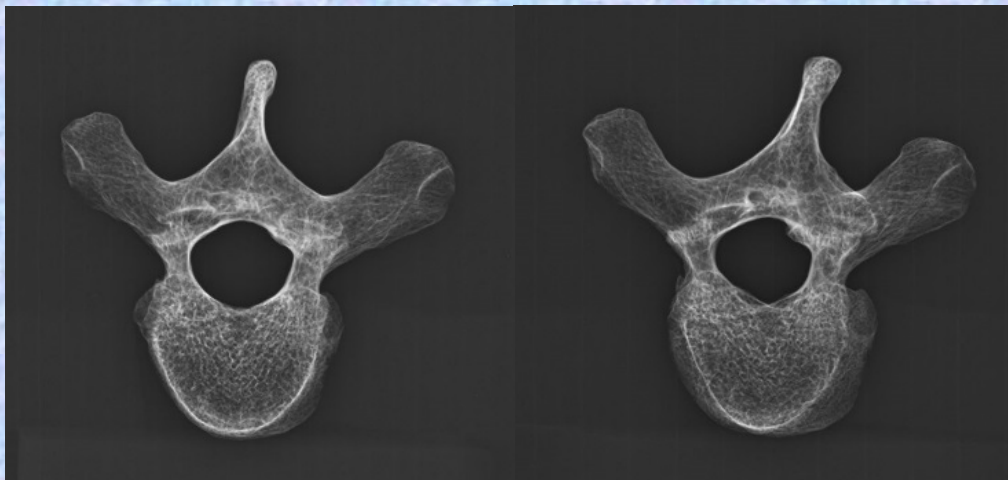
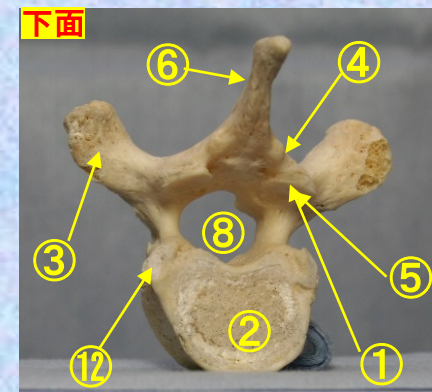
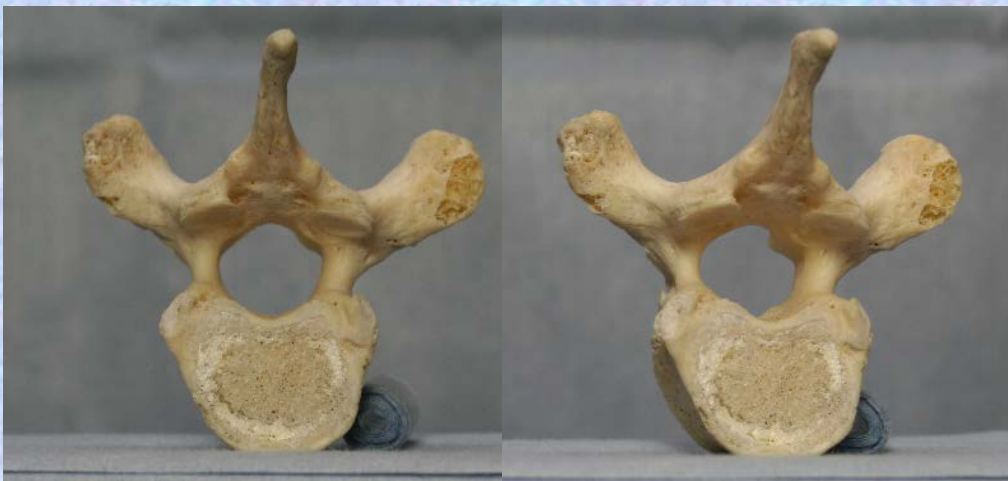Th4



- ① 下関節面(下関節突起関節面) inferior articular surface
- ② 椎体 transverse process
- ③ 横突起 transverse process
- ④ 椎弓板 lamina
- ⑤ 下関節突起 inferior articular process
- ⑥ 棘突起 spinous process

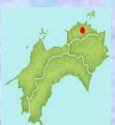- ⑦ 上関節突起 superior articular process
- ⑧ 椎孔 vertebral foramen
- ⑨ 椎弓根 pedicle
- ⑩ 上肋骨窩 superior costal facet
- ⑪ 横突肋骨窩 costal facet of transverse process
- ⑫ 下肋骨窩 inferior costal facet





- ① 下関節面(下関節突起関節面) inferior articular surface
- ② 椎体 transverse process
- ③ 横突起 transverse process
- ④ 椎弓板 lamina
- ⑤ 下関節突起 inferior articular process
- ⑥ 棘突起 spinous process

- ⑦ 上関節突起 superior articular process
- ⑧ 椎孔 vertebral foramen
- ⑨ 椎弓根 pedicle
- ⑩ 上肋骨窩 superior costal facet
- ⑪ 横突肋骨窩 costal facet of transverse process
- ⑫ 下肋骨窩 inferior costal facet



第5胸椎

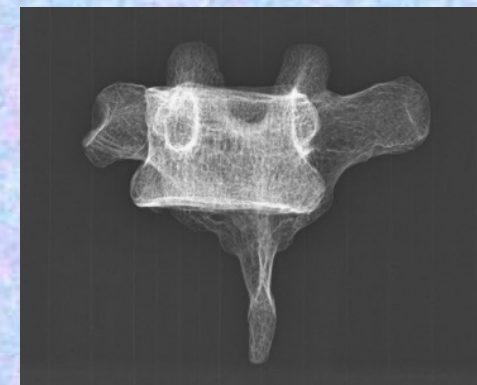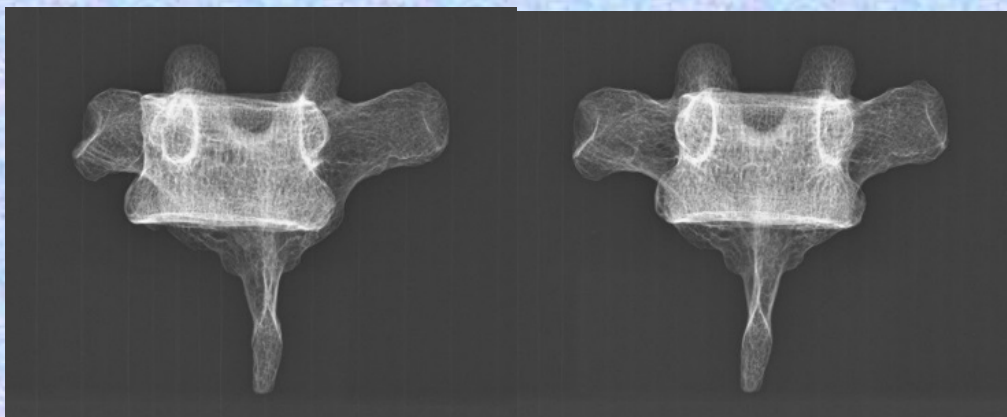
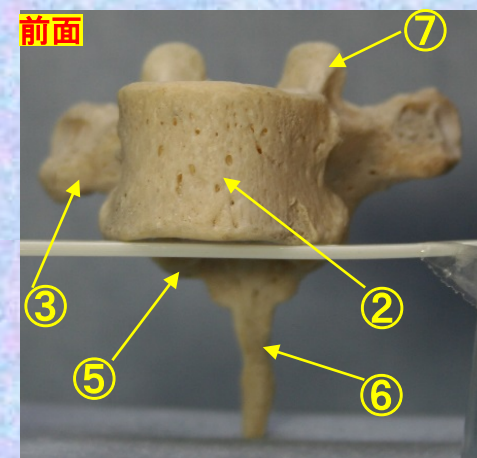
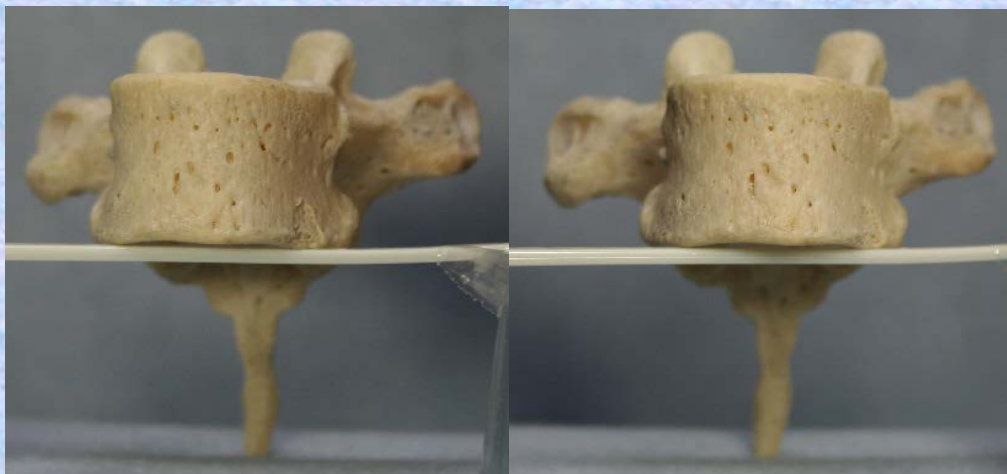Thoracic vertebra 5

Th5



胸椎 Th5 前面

Th5



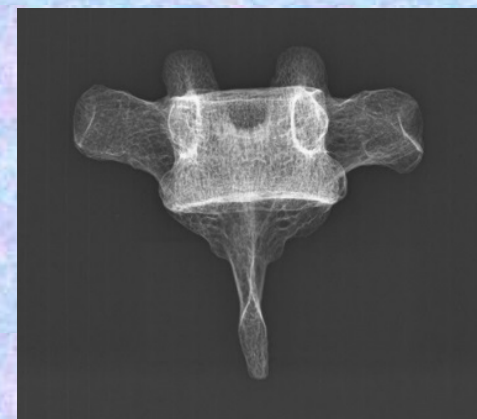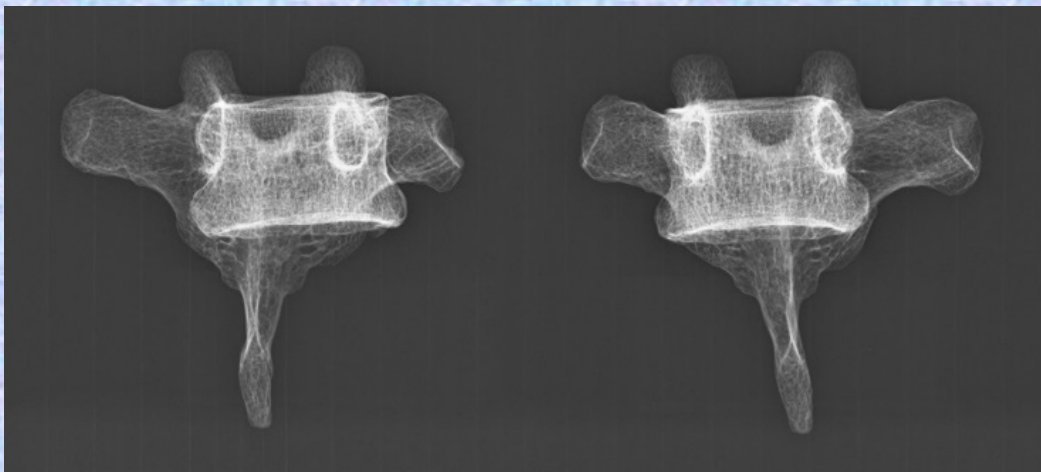
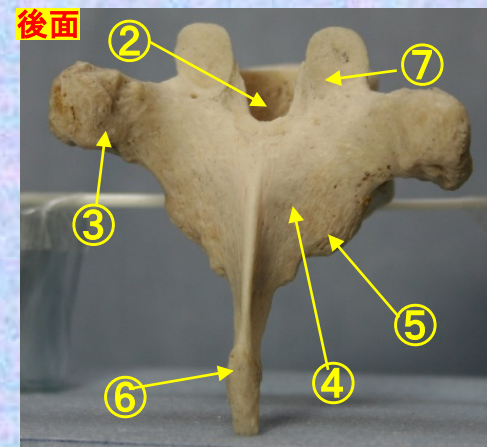
- ① 下関節面(下関節突起関節面) inferior articular surface
- ② 椎体 transverse process
- ③ 横突起 transverse process
- ④ 椎弓板 lamina
- ⑤ 下関節突起 inferior articular process
- ⑥ 棘突起 spinous process

- ⑦ 上関節突起 superior articular process
- ⑧ 椎孔 vertebral foramen
- ⑨ 椎弓根 pedicle
- ⑩ 上肋骨窩 superior costal facet
- ⑪ 横突肋骨窩 costal facet of transverse process
- ⑫ 下肋骨窩 inferior costal facet



胸椎 Th5 後面

Th5



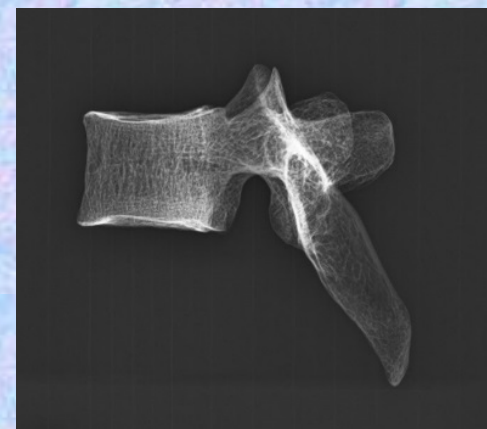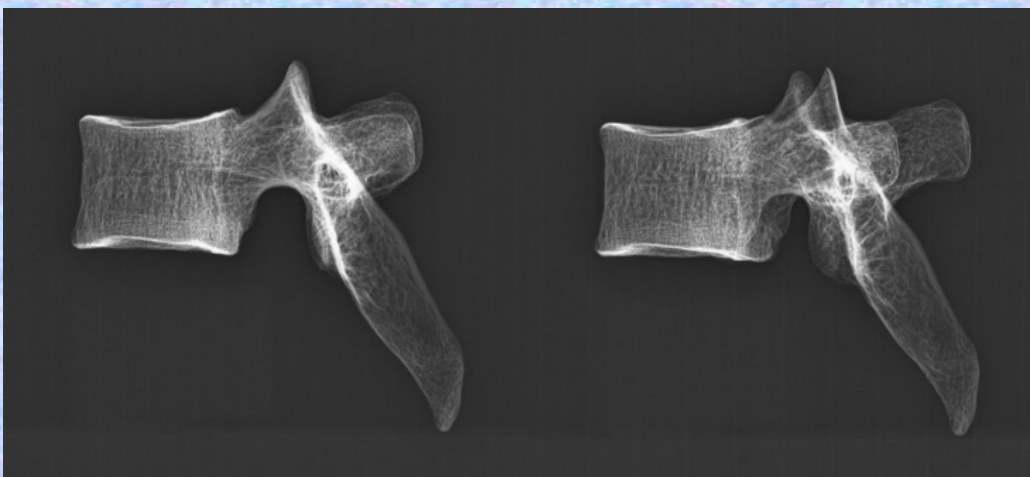
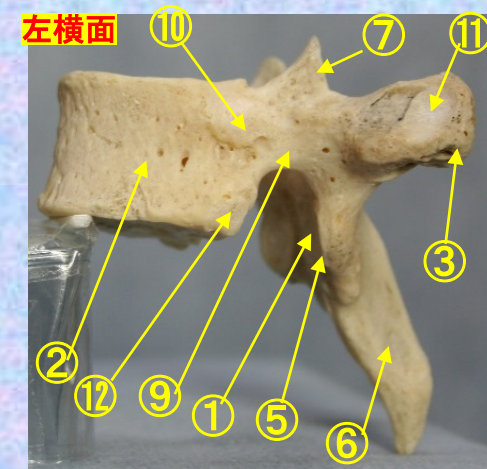
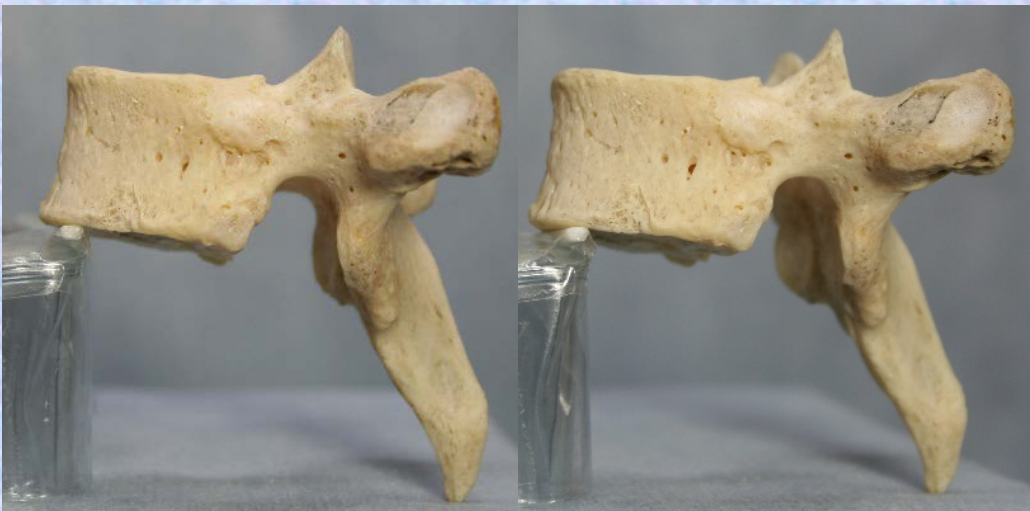- ①下関節面(下関節突起関節面) inferior articular surface
- ②椎体 transverse process
- ③横突起 transverse process
- ④椎弓板 lamina
- ⑤下関節突起 inferior articular process
- ⑥棘突起 spinous process

- ⑦上関節突起 superior articular process
- ⑧椎孔 vertebral foramen
- ⑨椎弓根 pedicle
- ⑩上肋骨窩 superior costal facet
- ⑪横突肋骨窩 costal facet of transverse process
- ⑫下肋骨窩 inferior costal facet



胸椎 Th5 側面

Th5



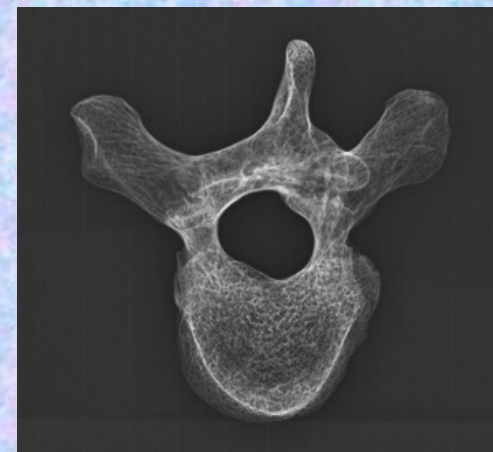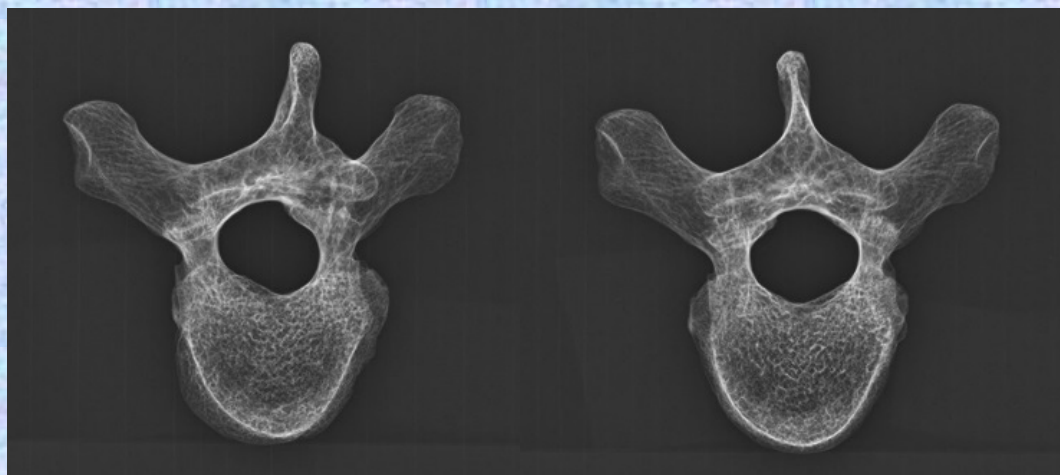
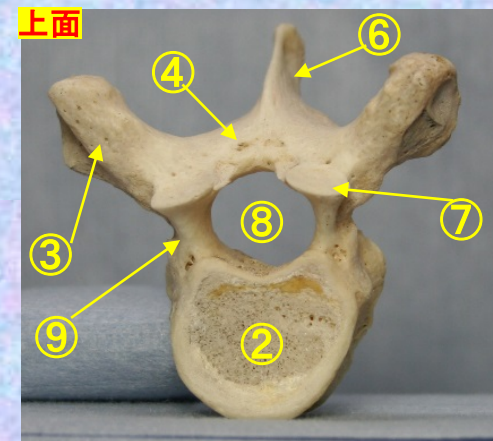
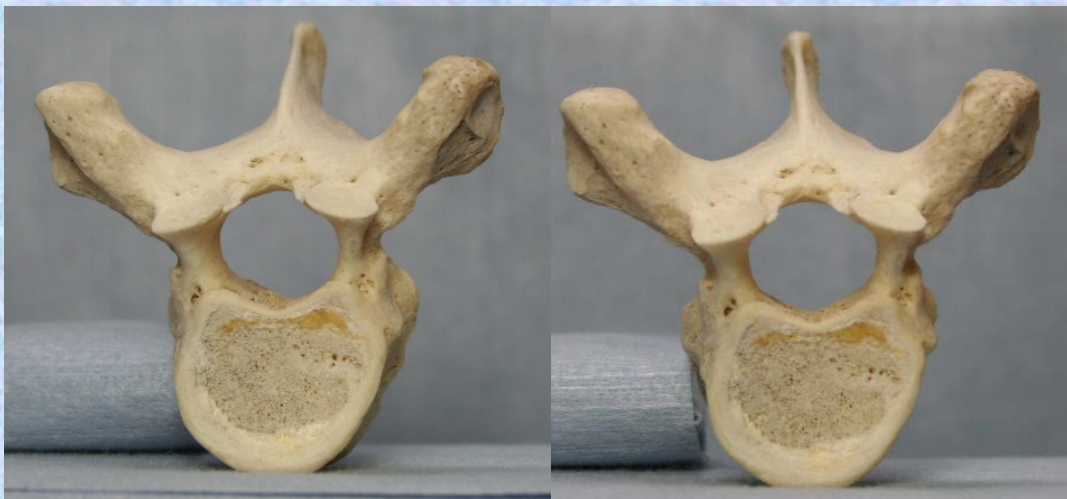- ① 下関節面(下関節突起関節面) inferior articular surface
- ② 椎体 transverse process
- ③ 横突起 transverse process
- ④ 椎弓板 lamina
- ⑤ 下関節突起 inferior articular process
- ⑥ 棘突起 spinous process

- ⑦ 上関節突起 superior articular process
- ⑧ 椎孔 vertebral foramen
- ⑨ 椎弓根 pedicle
- ⑩ 上肋骨窩 superior costal facet
- ⑪ 横突肋骨窩 costal facet of transverse process
- ⑫ 下肋骨窩 inferior costal facet



胸椎 Th5 上面

Th5



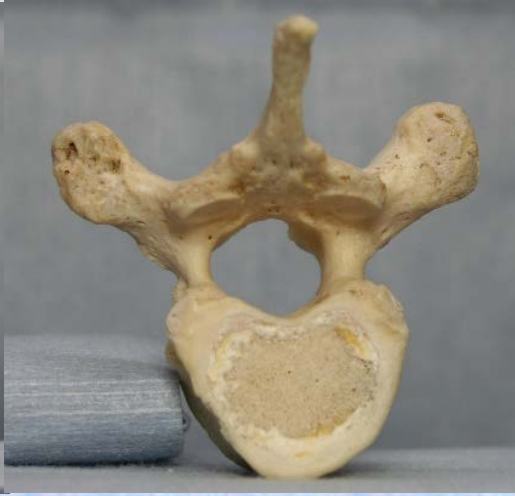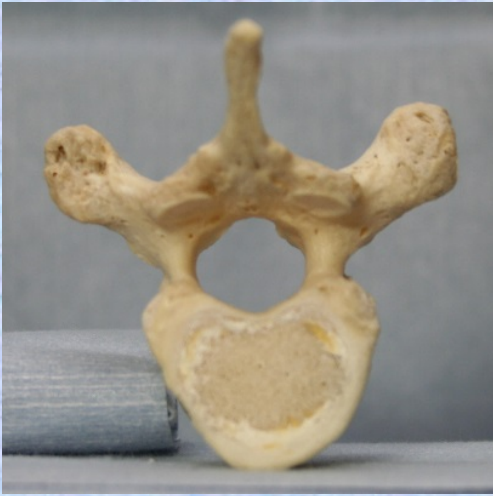
- ① 下関節面(下関節突起関節面) inferior articular surface
- ② 椎体 transverse process
- ③ 横突起 transverse process
- ④ 椎弓板 lamina
- ⑤ 下関節突起 inferior articular process
- ⑥ 棘突起 spinous process

- ⑦ 上関節突起 superior articular process
- ⑧ 椎孔 vertebral foramen
- ⑨ 椎弓根 pedicle
- ⑩ 上肋骨窩 superior costal facet
- ⑪ 横突肋骨窩 costal facet of transverse process
- ⑫ 下肋骨窩 inferior costal facet

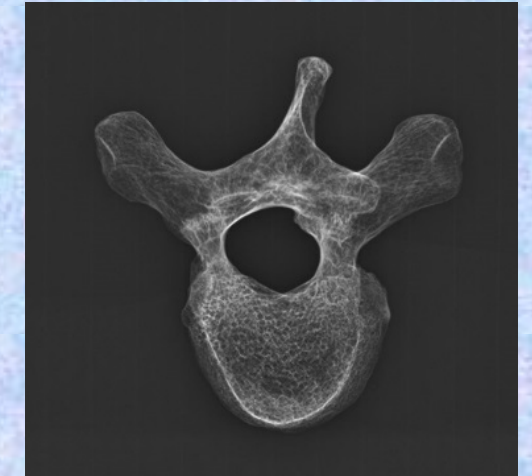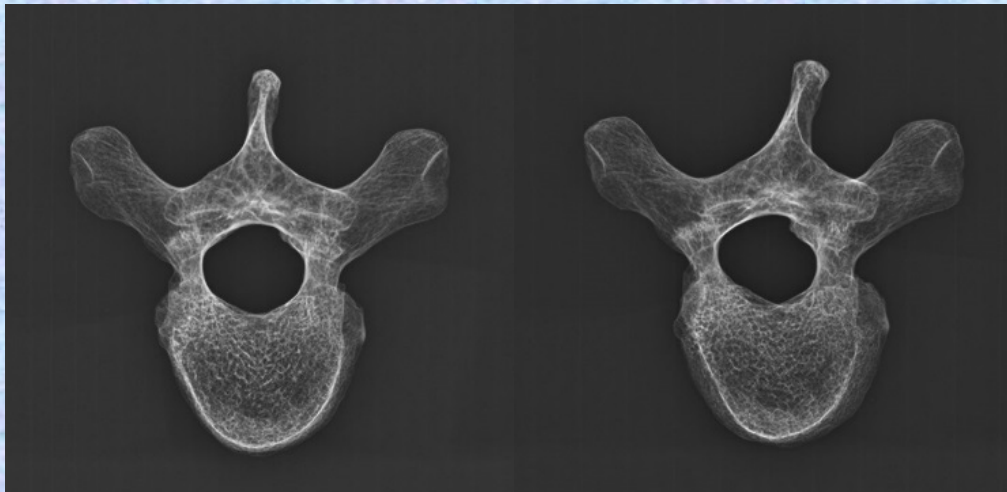
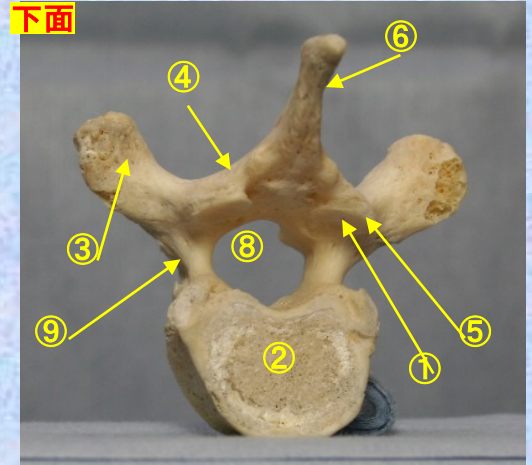


胸椎 Th5 下面

Th5



下面



- ① 下関節面(下関節突起関節面) inferior articular surface
- ② 椎体 transverse process
- ③ 横突起 transverse process
- ④ 椎弓板 lamina
- ⑤ 下関節突起 inferior articular process
- ⑥ 棘突起 spinous process

- ⑦ 上関節突起 superior articular process
- ⑧ 椎孔 vertebral foramen
- ⑨ 椎弓根 pedicle
- ⑩ 上肋骨窩 superior costal facet
- ⑪ 横突肋骨窩 costal facet of transverse process
- ⑫ 下肋骨窩 inferior costal facet



第6胸椎

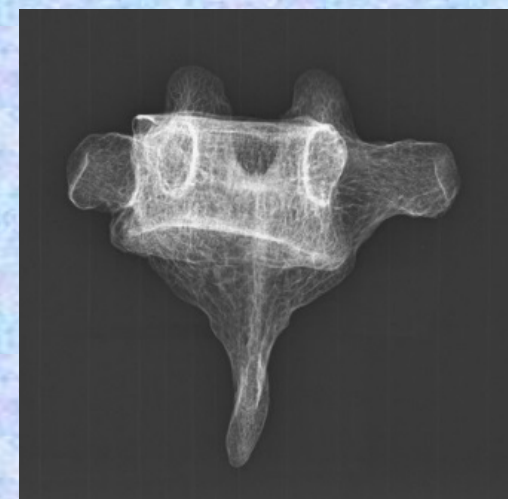
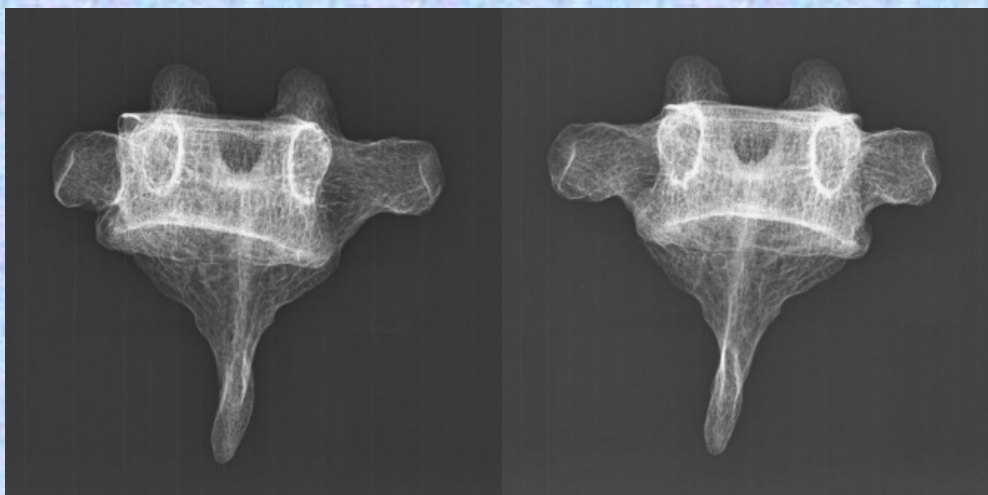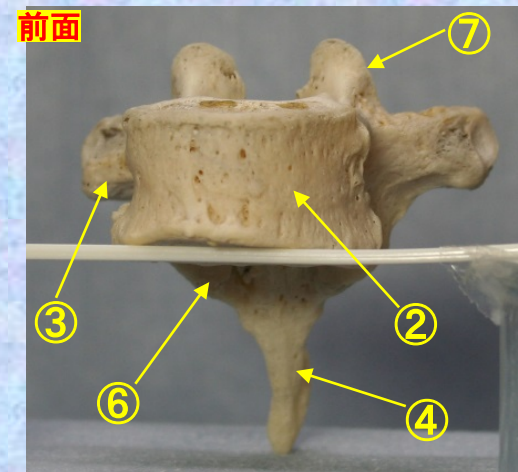
Thoracic vertebra 6

Th6



胸椎 Th6 前面

Th6



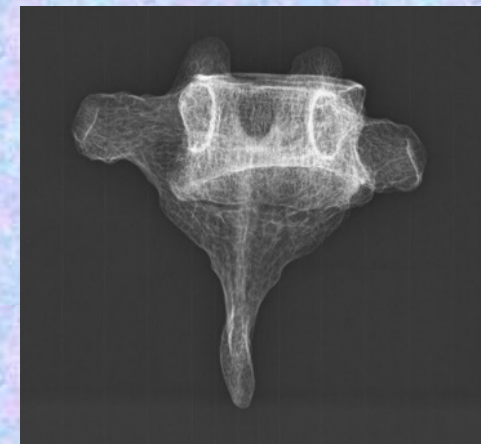
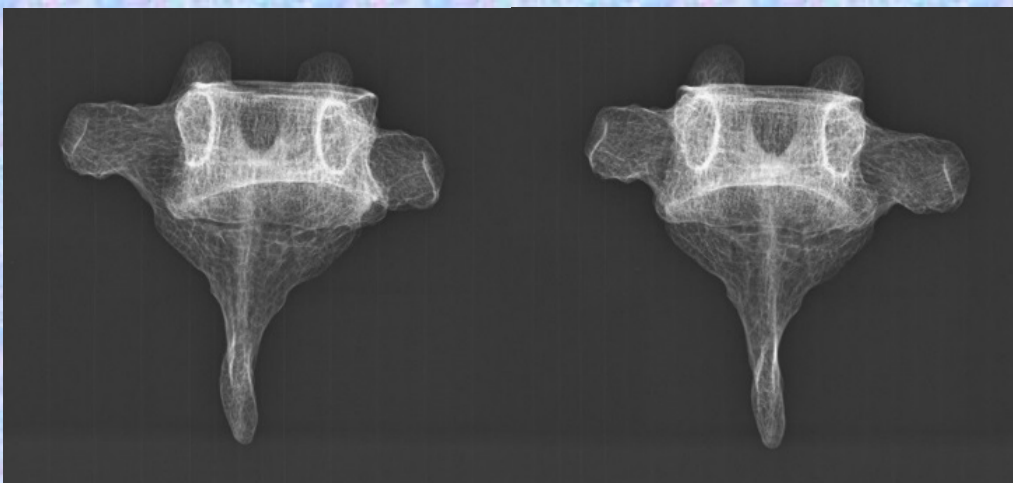
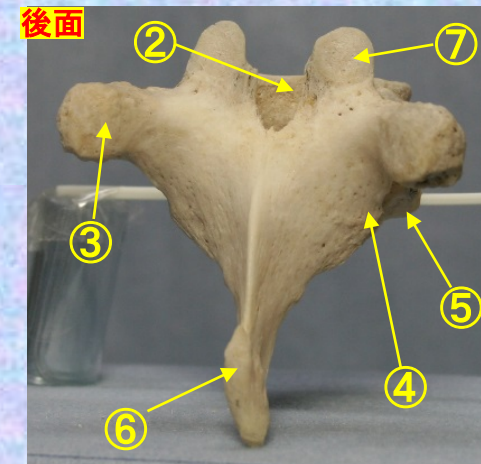
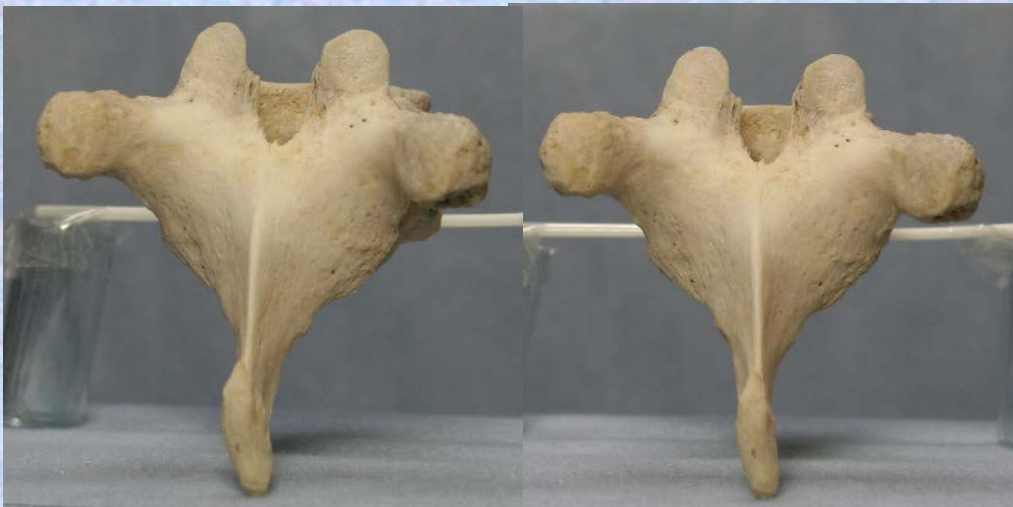- ① 下関節面(下関節突起関節面) inferior articular surface
- ② 椎体 transverse process
- ③ 横突起 transverse process
- ④ 椎弓板 lamina
- ⑤ 下関節突起 inferior articular process
- ⑥ 棘突起 spinous process

- ⑦ 上関節突起 superior articular process
- ⑧ 椎孔 vertebral foramen
- ⑨ 椎弓根 pedicle
- ⑩ 上肋骨窩 superior costal facet
- ⑪ 横突肋骨窩 costal facet of transverse process
- ⑫ 下肋骨窩 inferior costal facet



胸椎 Th6 後面

Th6



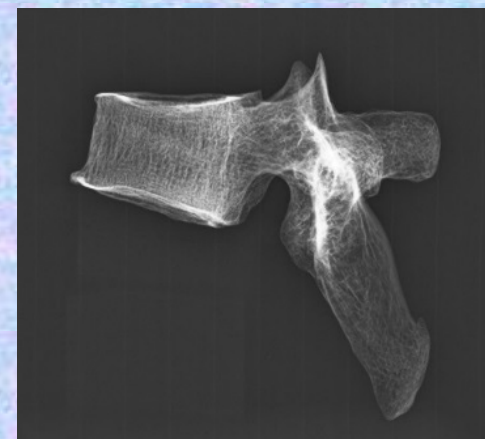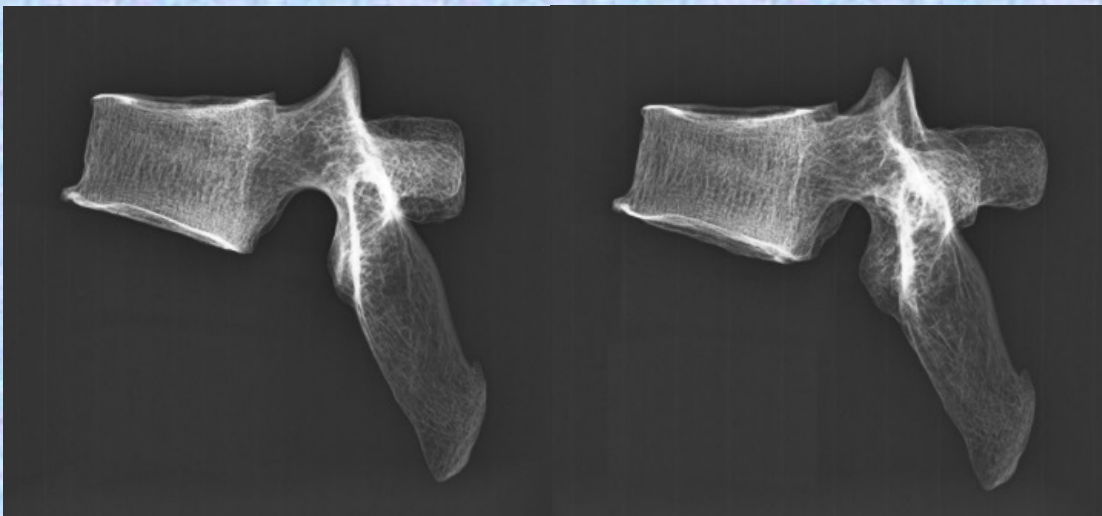
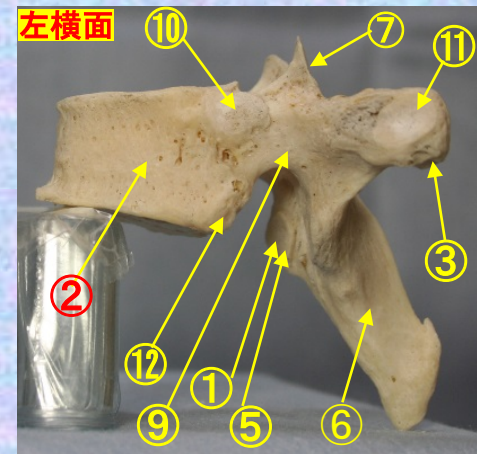
- ① 下関節面(下関節突起関節面) inferior articular surface
- ② 椎体 transverse process
- ③ 横突起 transverse process
- ④ 椎弓板 lamina
- ⑤ 下関節突起 inferior articular process
- ⑥ 棘突起 spinous process

- ⑦ 上関節突起 superior articular process
- ⑧ 椎孔 vertebral foramen
- ⑨ 椎弓根 pedicle
- ⑩ 上肋骨窩 superior costal facet
- ⑪ 横突肋骨窩 costal facet of transverse process
- ⑫ 下肋骨窩 inferior costal facet



胸椎 Th6 側面

Th6



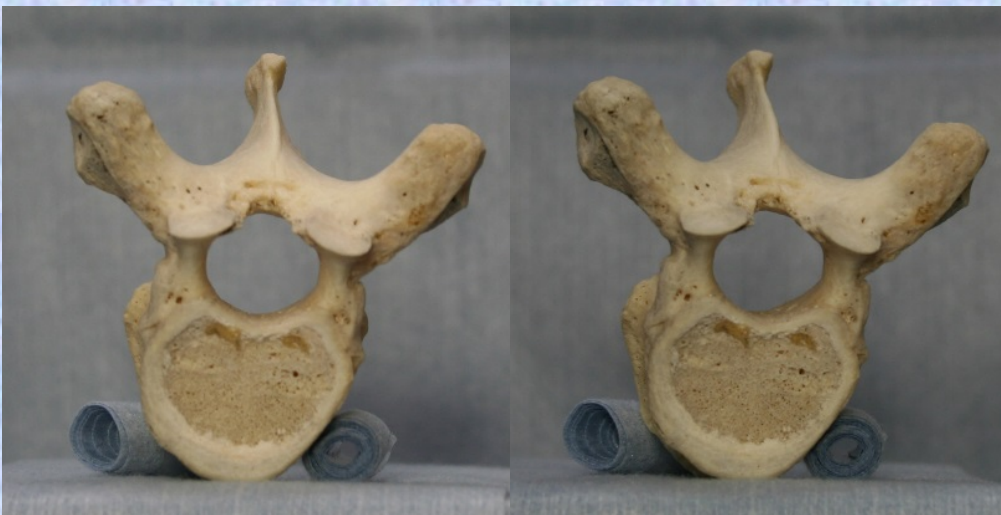
- ①下関節面(下関節突起関節面) inferior articular surface
- ②椎体 transverse process
- ③横突起 transverse process
- ④椎弓板 lamina
- ⑤下関節突起 inferior articular process
- ⑥棘突起 spinous process

- ⑦上関節突起 superior articular process
- ⑧椎孔 vertebral foramen
- ⑨椎弓根 pedicle
- ⑩上肋骨窩 superior costal facet
- ⑪横突肋骨窩 costal facet of transverse process
- ⑫下肋骨窩 inferior costal facet

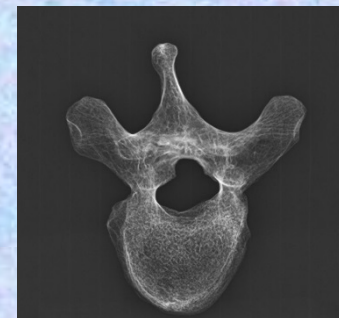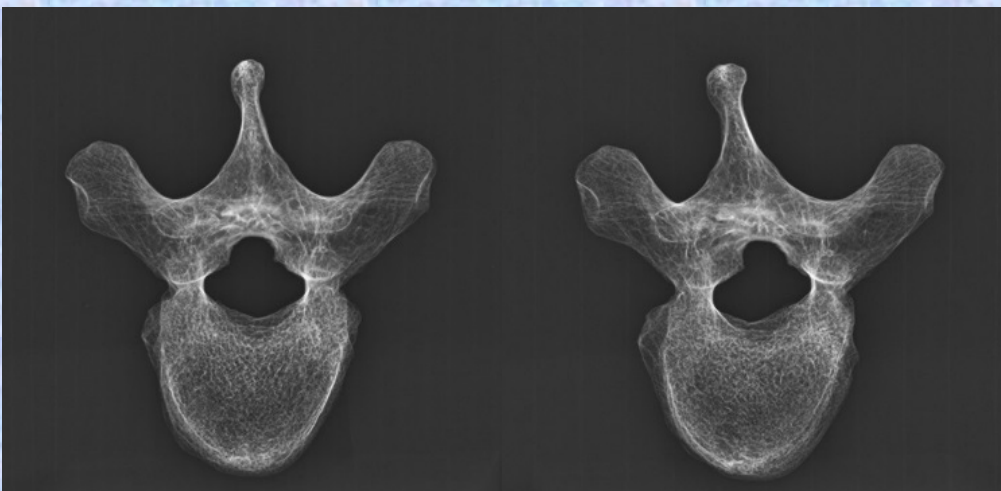
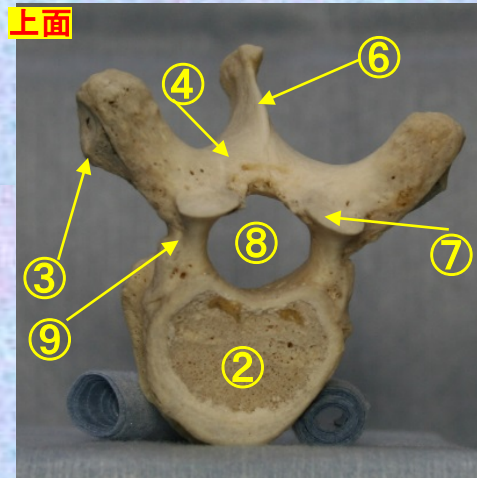


胸椎 Th6 上面

Th6



上面



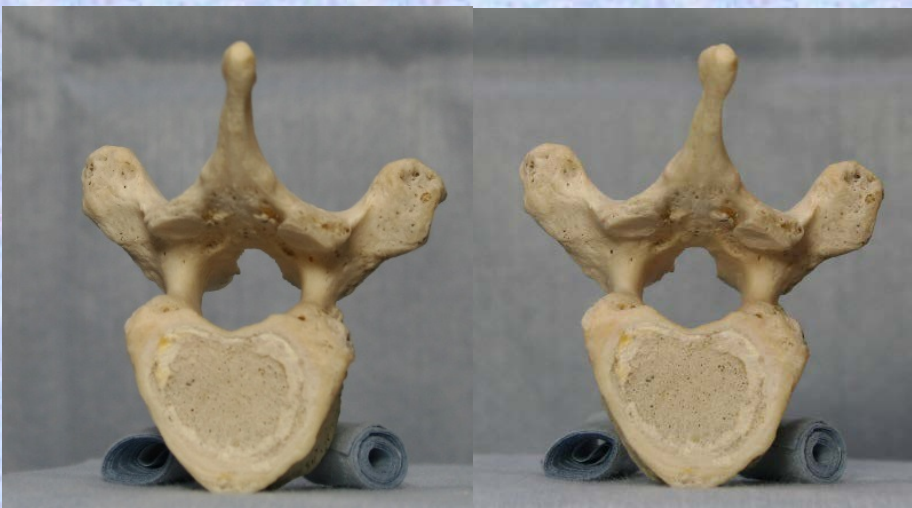- ① 下関節面(下関節突起関節面) inferior articular surface
- ② 椎体 transverse process
- ③ 横突起 transverse process
- ④ 椎弓板 lamina
- ⑤ 下関節突起 inferior articular process
- ⑥ 棘突起 spinous process

- ⑦ 上関節突起 superior articular process
- ⑧ 椎孔 vertebral foramen
- ⑨ 椎弓根 pedicle
- ⑩ 上肋骨窩 superior costal facet
- ⑪ 横突肋骨窩 costal facet of transverse process
- ⑫ 下肋骨窩 inferior costal facet

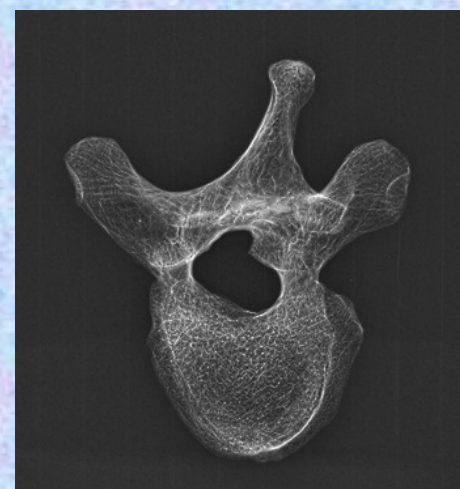
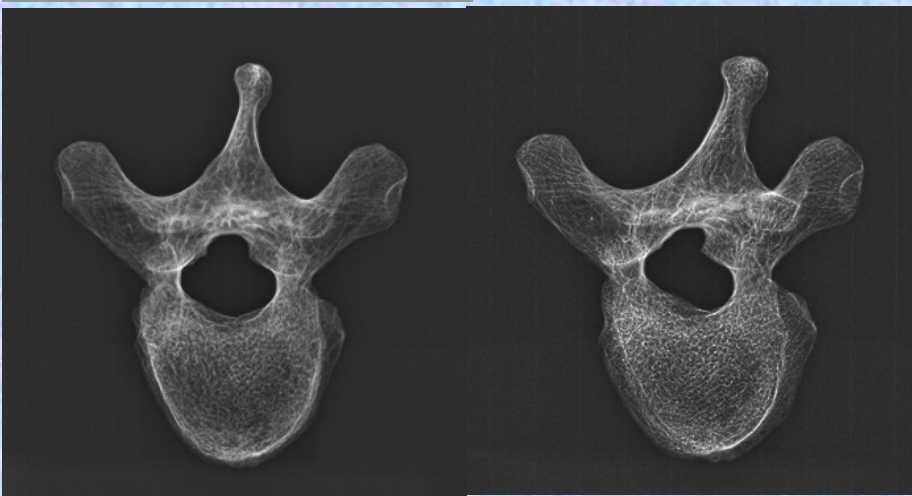
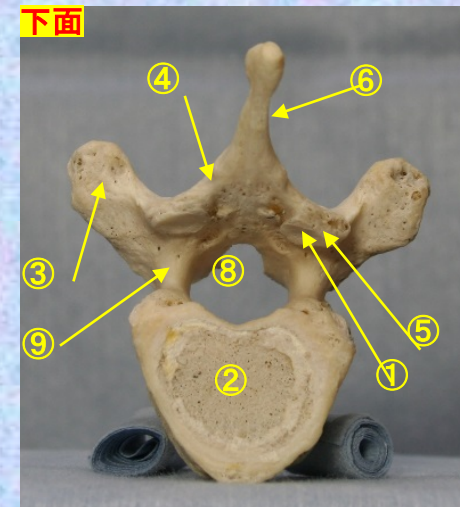


胸椎 Th6 下面

Th6

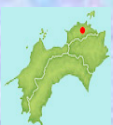

下面



- ① 下関節面(下関節突起関節面) inferior articular surface
- ② 椎体 transverse process
- ③ 横突起 transverse process
- ④ 椎弓板 lamina
- ⑤ 下関節突起 inferior articular process
- ⑥ 棘突起 spinous process

- ⑦ 上関節突起 superior articular process
- ⑧ 椎孔 vertebral foramen
- ⑨ 椎弓根 pedicle
- ⑩ 上肋骨窩 superior costal facet
- ⑪ 横突肋骨窩 costal facet of transverse process
- ⑫ 下肋骨窩 inferior costal facet



第7胸椎

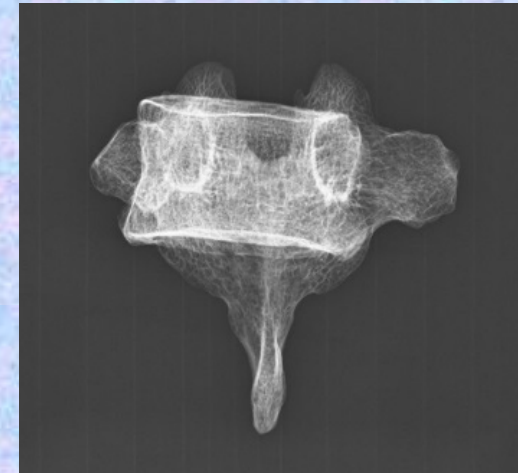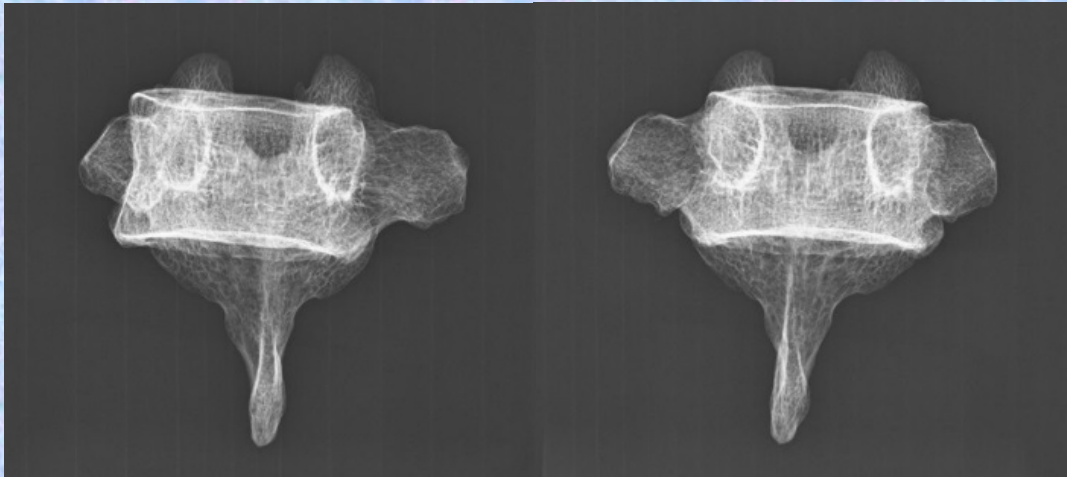

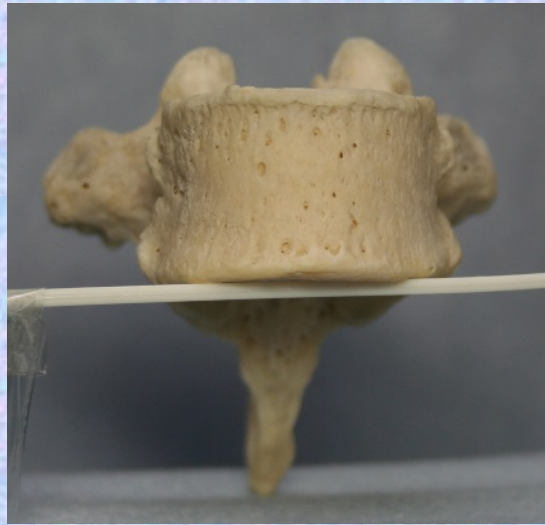
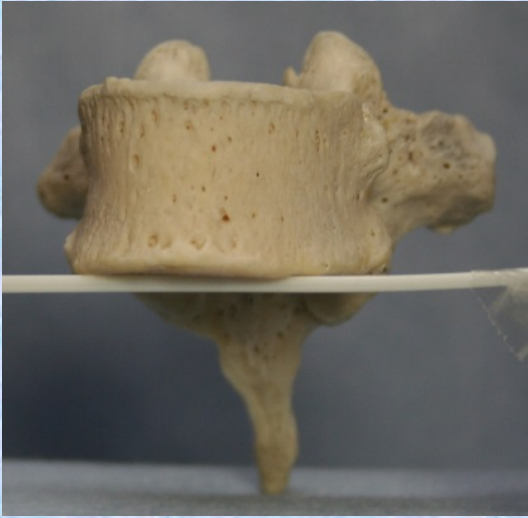
Thoracic vertebra 7

Th7



胸椎 Th7 前面

Th7



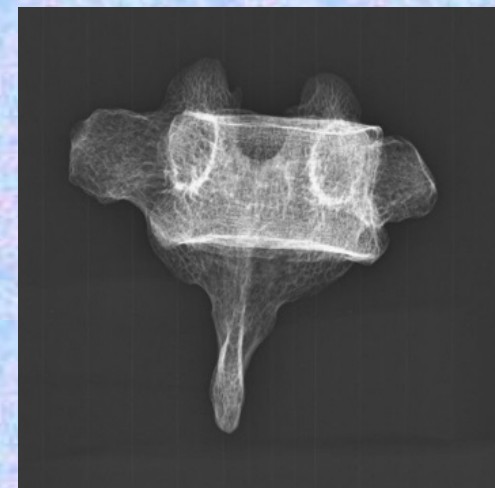
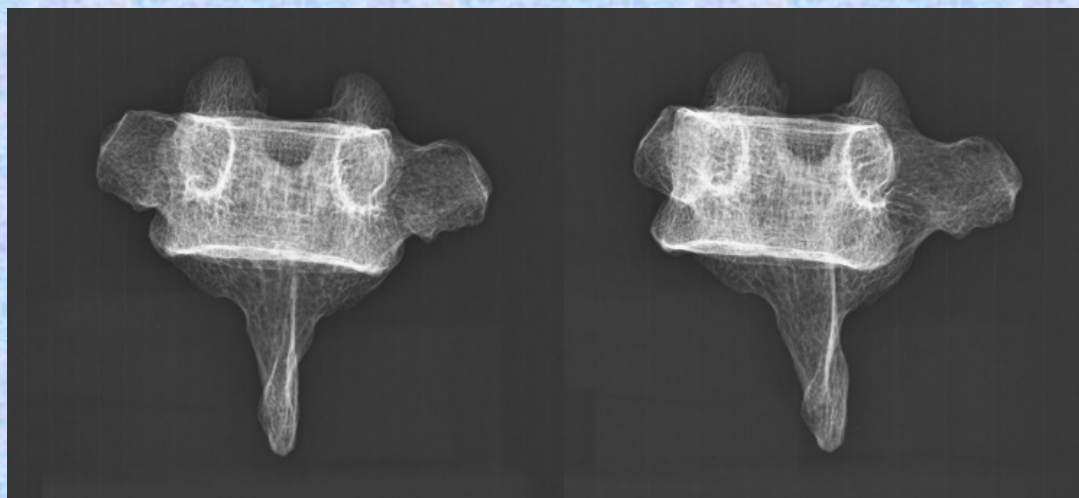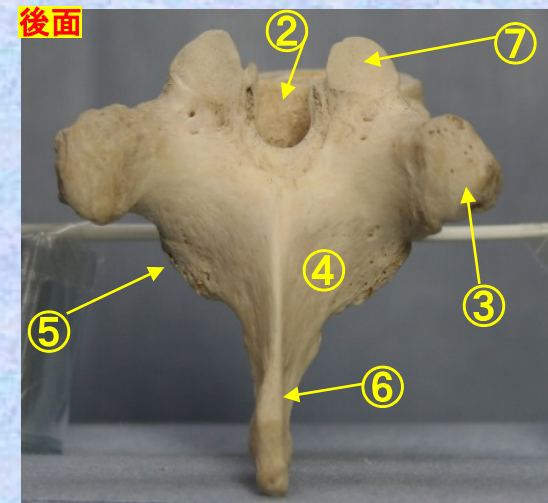
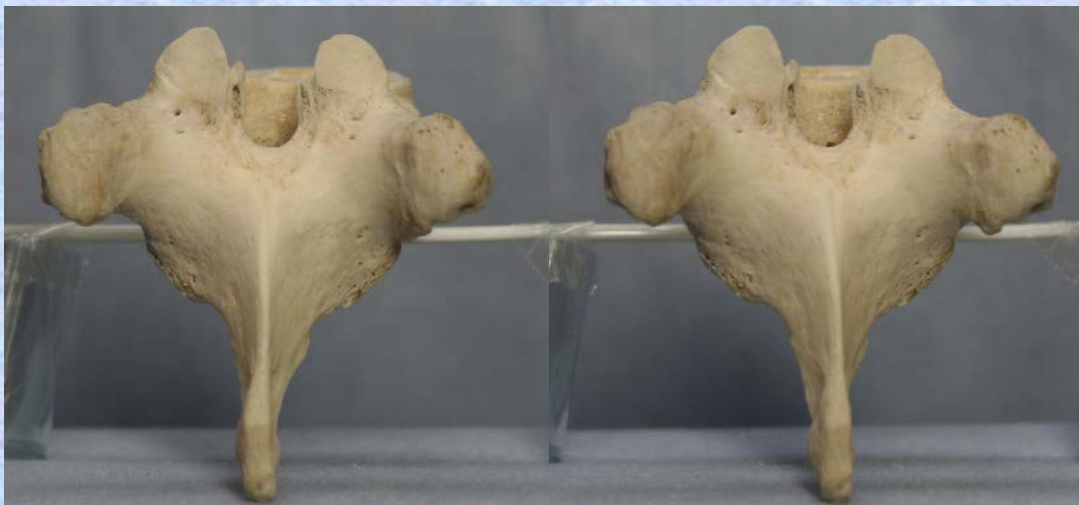- ① 下関節面(下関節突起関節面) inferior articular surface
- ② 椎体 transverse process
- ③ 横突起 transverse process
- ④ 椎弓板 lamina
- ⑤ 下関節突起 inferior articular process
- ⑥ 棘突起 spinous process

- ⑦ 上関節突起 superior articular process
- ⑧ 椎孔 vertebral foramen
- ⑨ 椎弓根 pedicle
- ⑩ 上肋骨窩 superior costal facet
- ⑪ 横突肋骨窩 costal facet of transverse process
- ⑫ 下肋骨窩 inferior costal facet



胸椎 Th7 後面

Th7



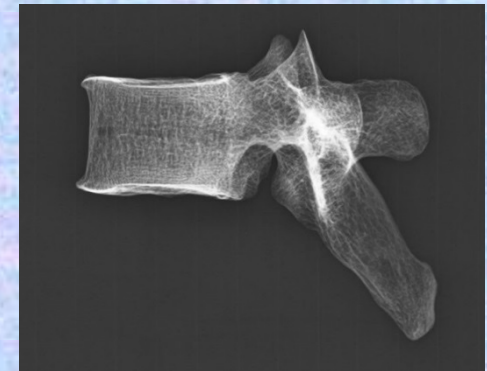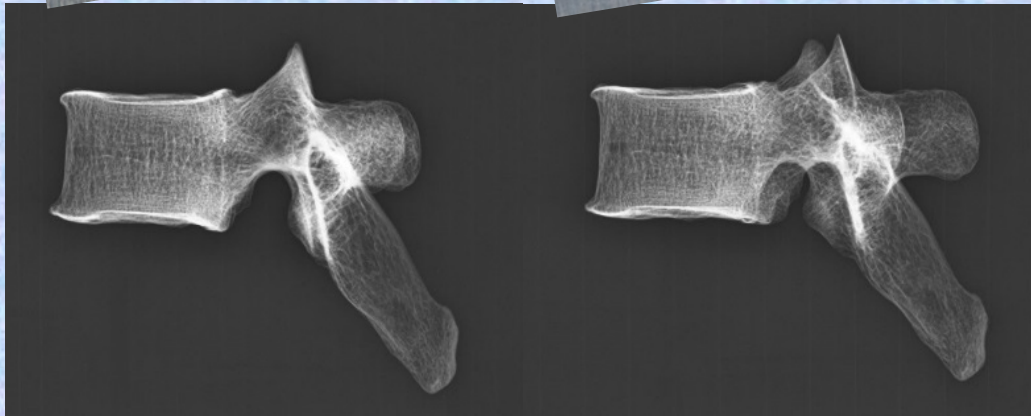
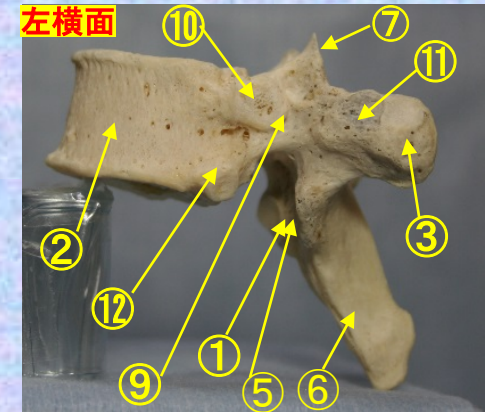
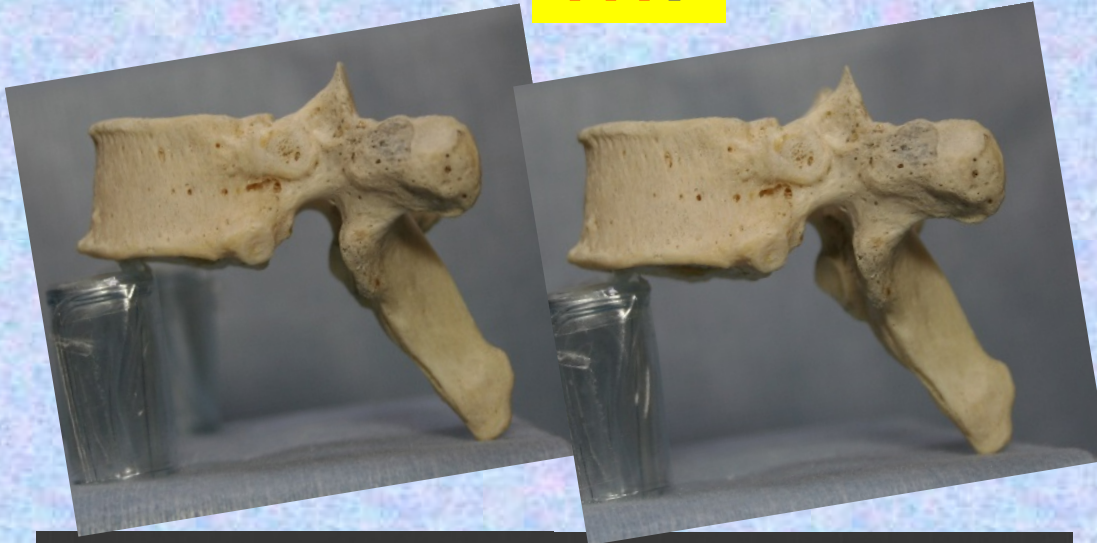- ① 下関節面(下関節突起関節面) inferior articular surface
- ② 椎体 transverse process
- ③ 横突起 transverse process
- ④ 椎弓板 lamina
- ⑤ 下関節突起 inferior articular process
- ⑥ 棘突起 spinous process

- ⑦ 上関節突起 superior articular process
- ⑧ 椎孔 vertebral foramen
- ⑨ 椎弓根 pedicle
- ⑩ 上肋骨窩 superior costal facet
- ⑪ 横突肋骨窩 costal facet of transverse process
- ⑫ 下肋骨窩 inferior costal facet



胸椎 Th7 側面

Th7

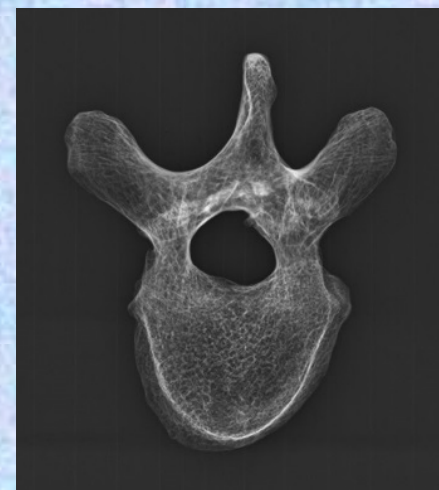
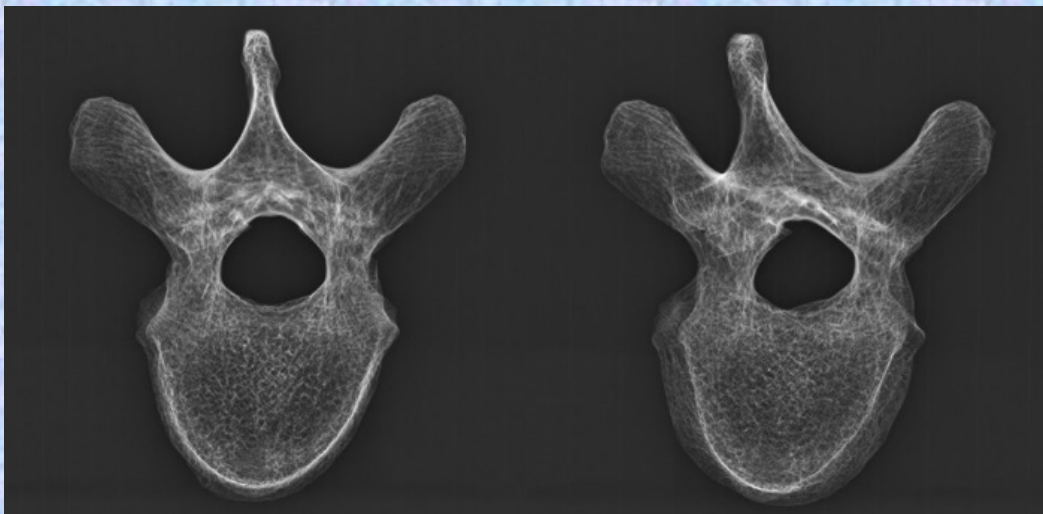
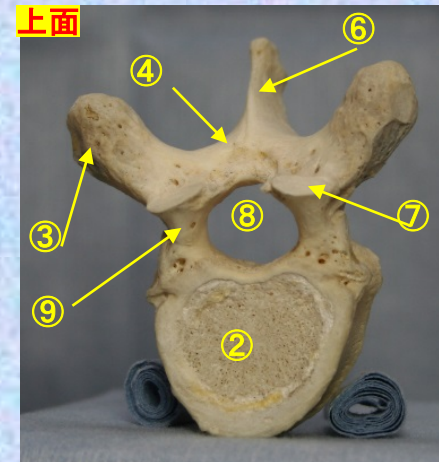
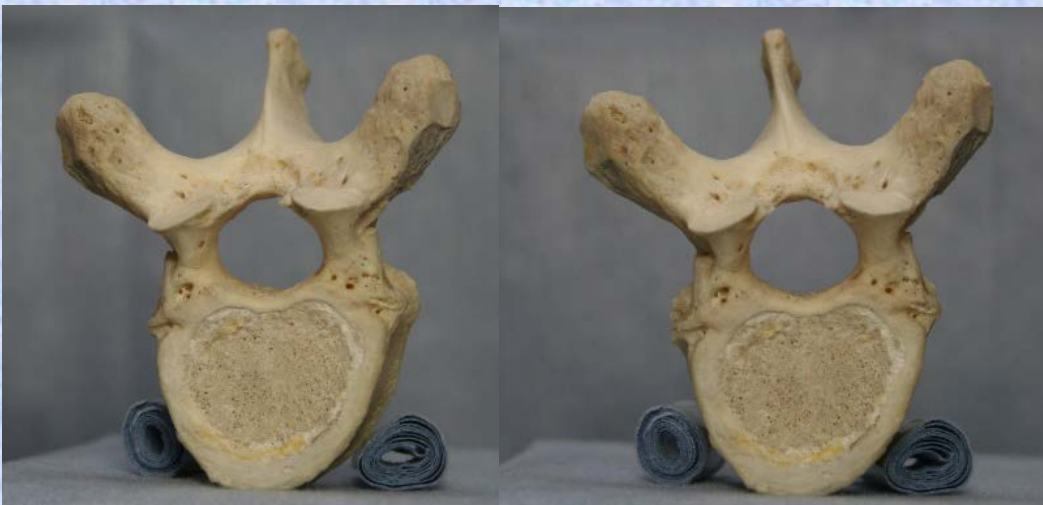

- ① 下関節面(下関節突起関節面) inferior articular surface
- ② 椎体 transverse process
- ③ 横突起 transverse process
- ④ 椎弓板 lamina
- ⑤ 下関節突起 inferior articular process
- ⑥ 棘突起 spinous process

- ⑦ 上関節突起 superior articular process
- ⑧ 椎孔 vertebral foramen
- ⑨ 椎弓根 pedicle
- ⑩ 上肋骨窩 superior costal facet
- ⑪ 横突肋骨窩 costal facet of transverse process
- ⑫ 下肋骨窩 inferior costal facet

胸椎 Th7 上面

Th7

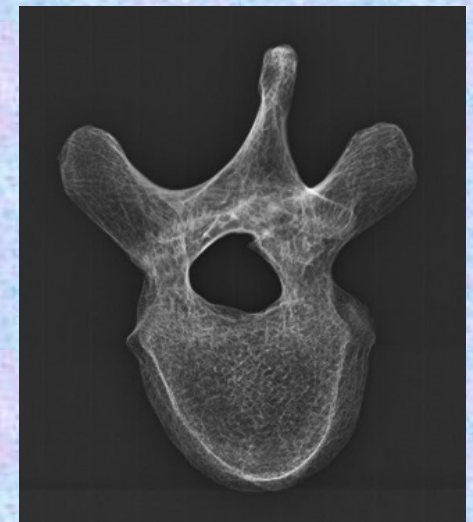
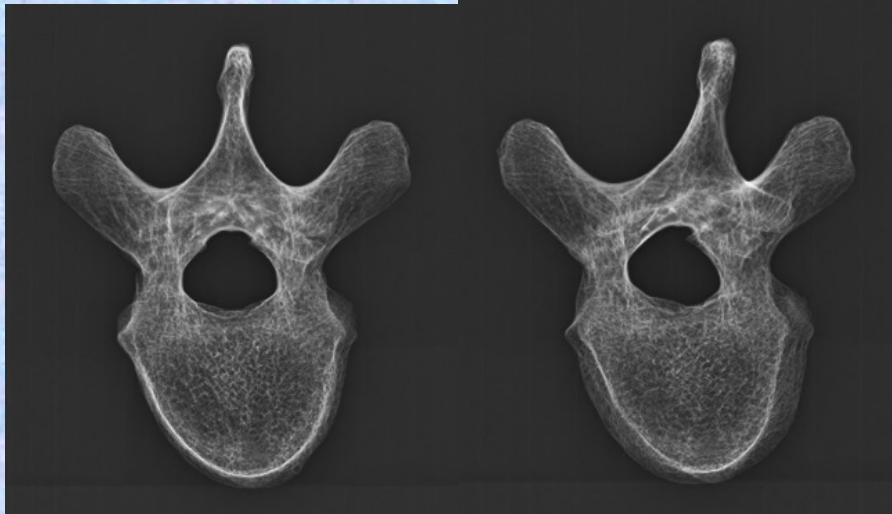
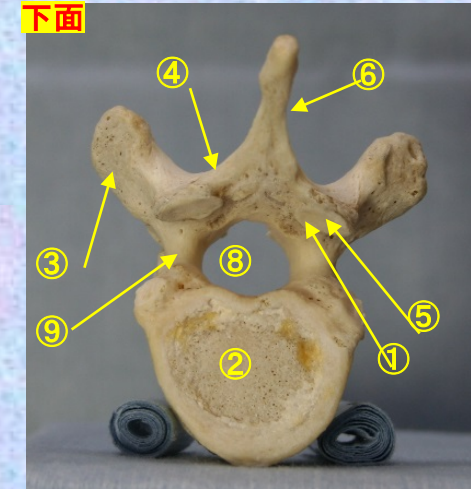
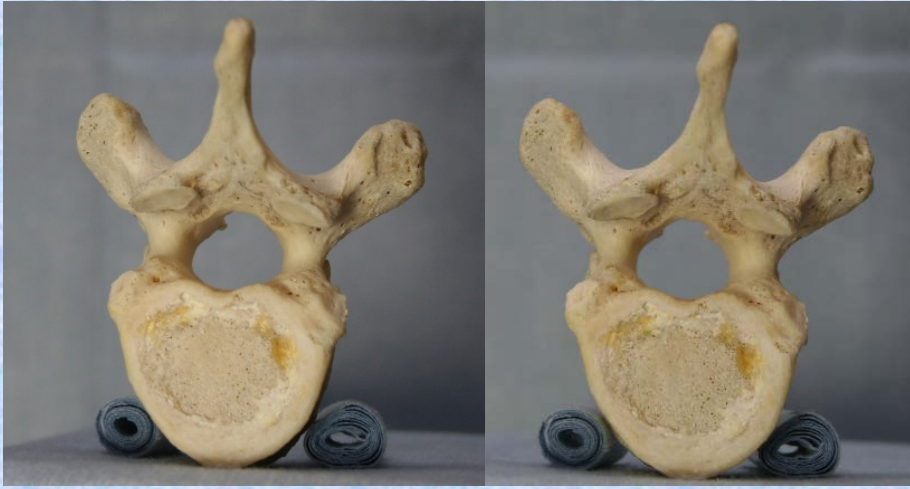

- ① 下関節面(下関節突起関節面) inferior articular surface
 ② 椎体 transverse process
 ③ 横突起 transverse process
 ④ 椎弓板 lamina
 ⑤ 下関節突起 inferior articular process
 ⑥ 棘突起 spinous process

- ⑦ 上関節突起 superior articular process
 ⑧ 椎孔 vertebral foramen
 ⑨ 椎弓根 pedicle
 ⑩ 上肋骨窩 superior costal facet
 ⑪ 横突肋骨窩 costal facet of transverse process
 ⑫ 下肋骨窩 inferior costal facet

胸椎 Th7 下面

Th7



- ① 下関節面(下関節突起関節面) inferior articular surface
 ② 椎体 transverse process
 ③ 横突起 transverse process
 ④ 椎弓板 lamina
 ⑤ 下関節突起 inferior articular process
 ⑥ 棘突起 spinous process

- ⑦ 上関節突起 superior articular process
 ⑧ 椎孔 vertebral foramen
 ⑨ 椎弓根 pedicle
 ⑩ 上肋骨窩 superior costal facet
 ⑪ 横突肋骨窩 costal facet of transverse process
 ⑫ 下肋骨窩 inferior costal facet

第8胸椎

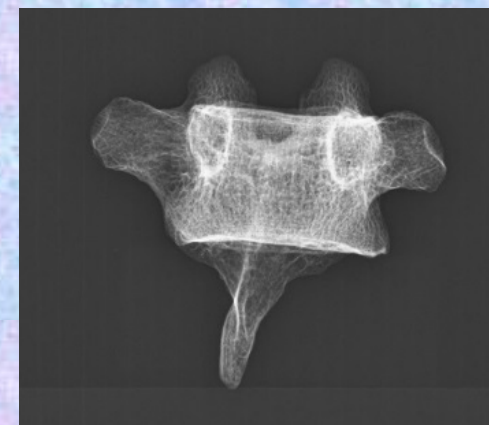
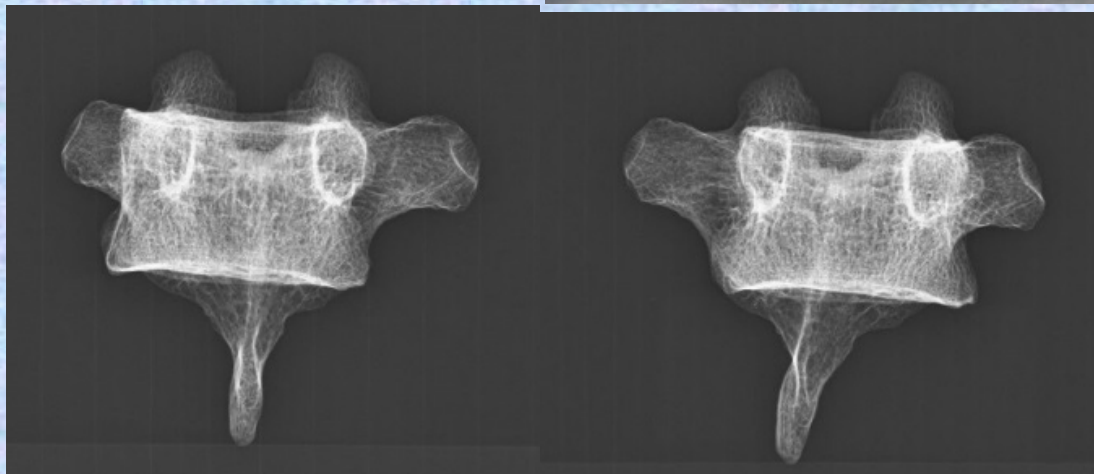
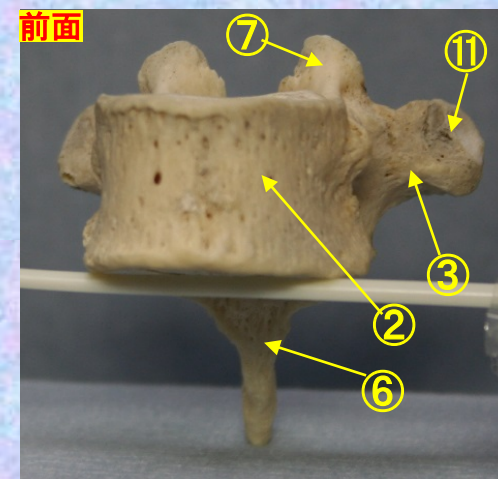
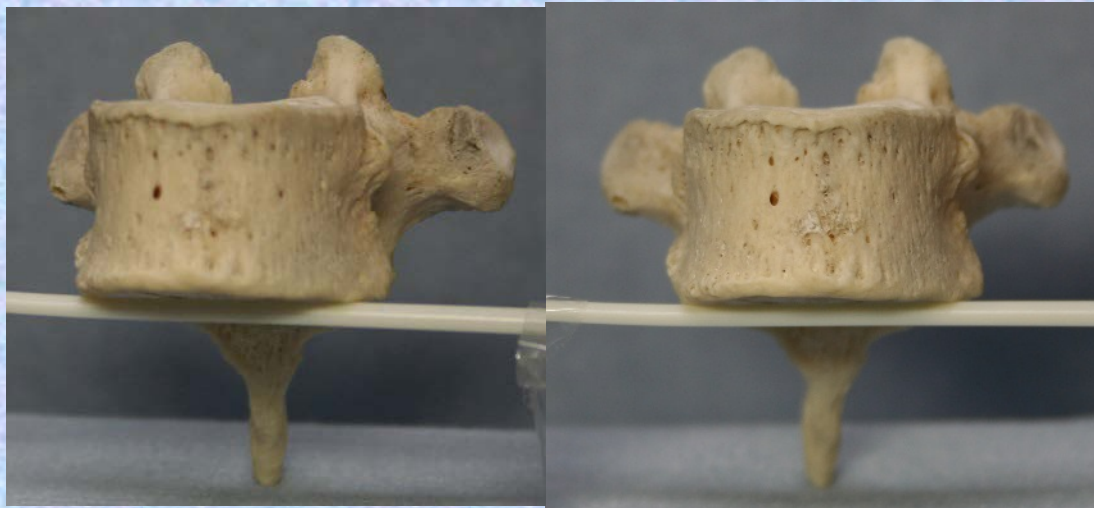
Thoracic vertebra 8

Th8



胸椎 Th8 前面

Th8



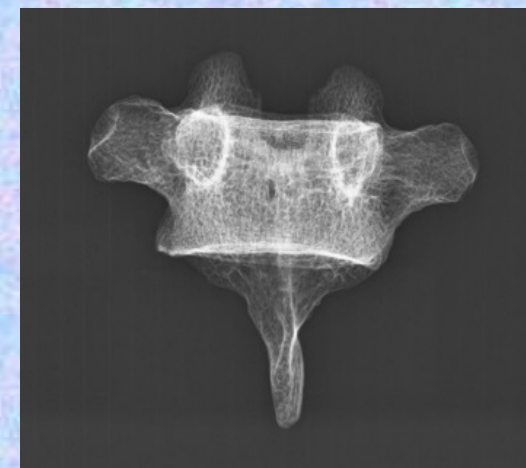
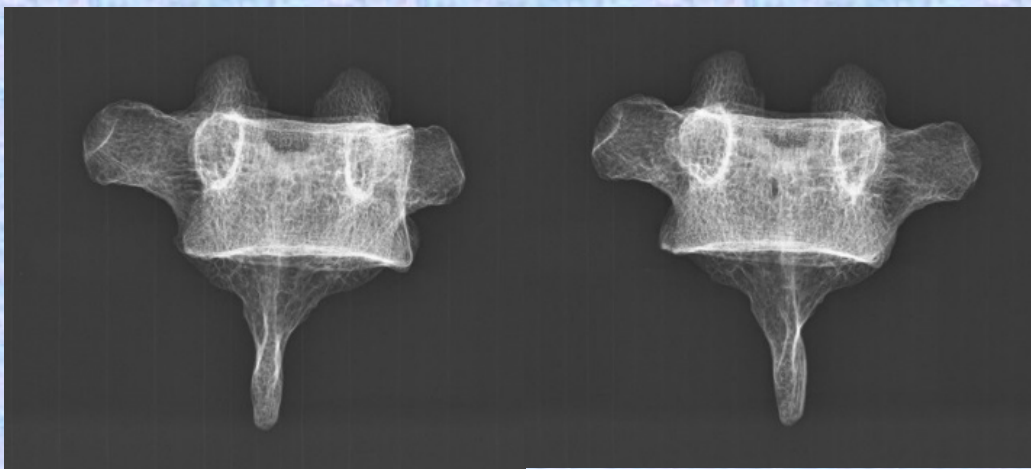
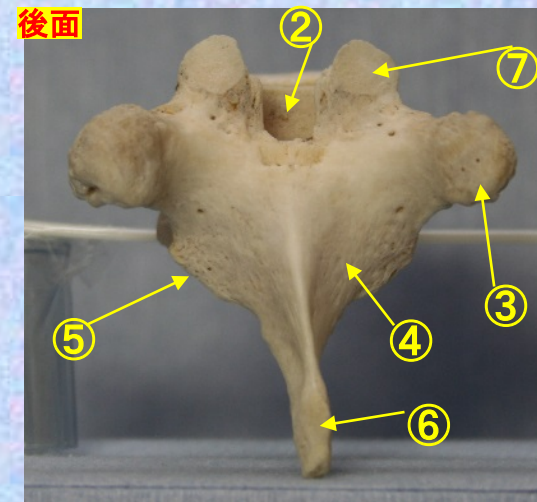
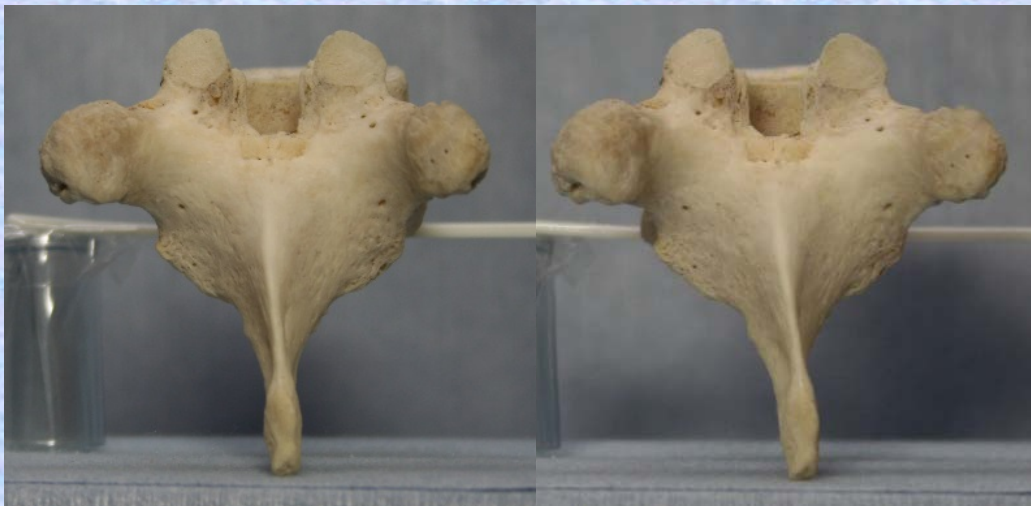
- ① 下関節面(下関節突起関節面) inferior articular surface
- ② 椎体 transverse process
- ③ 横突起 transverse process
- ④ 椎弓板 lamina
- ⑤ 下関節突起 inferior articular process
- ⑥ 棘突起 spinous process

- ⑦ 上関節突起 superior articular process
- ⑧ 椎孔 vertebral foramen
- ⑨ 椎弓根 pedicle
- ⑩ 上肋骨窩 superior costal facet
- ⑪ 横突肋骨窩 costal facet of transverse process
- ⑫ 下肋骨窩 inferior costal facet



胸椎 Th8 後面

Th8



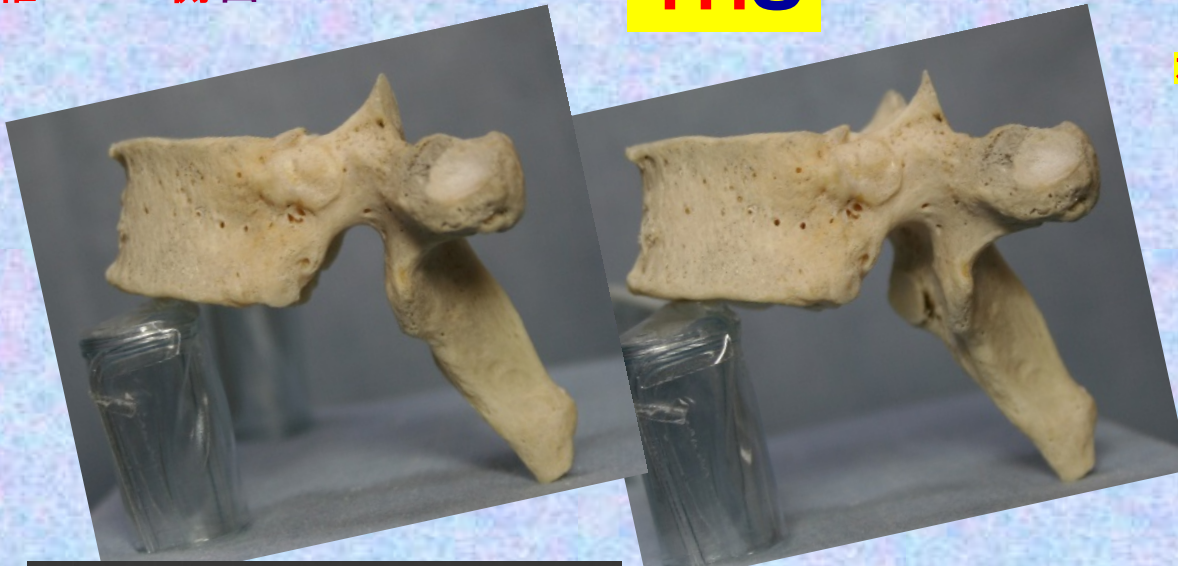- ① 下関節面(下関節突起関節面) inferior articular surface
- ② 椎体 transverse process
- ③ 横突起 transverse process
- ④ 椎弓板 lamina
- ⑤ 下関節突起 inferior articular process
- ⑥ 棘突起 spinous process

- ⑦ 上関節突起 superior articular process
- ⑧ 椎孔 vertebral foramen
- ⑨ 椎弓根 pedicle
- ⑩ 上肋骨窩 superior costal facet
- ⑪ 横突肋骨窩 costal facet of transverse process
- ⑫ 下肋骨窩 inferior costal facet

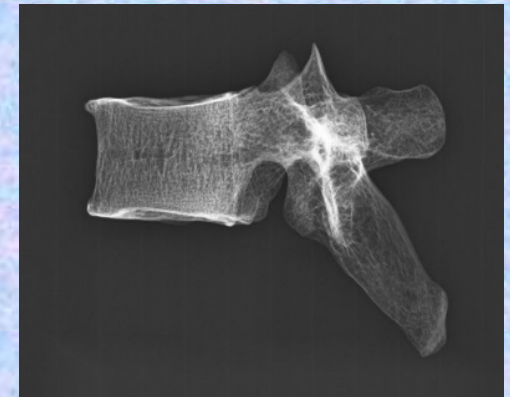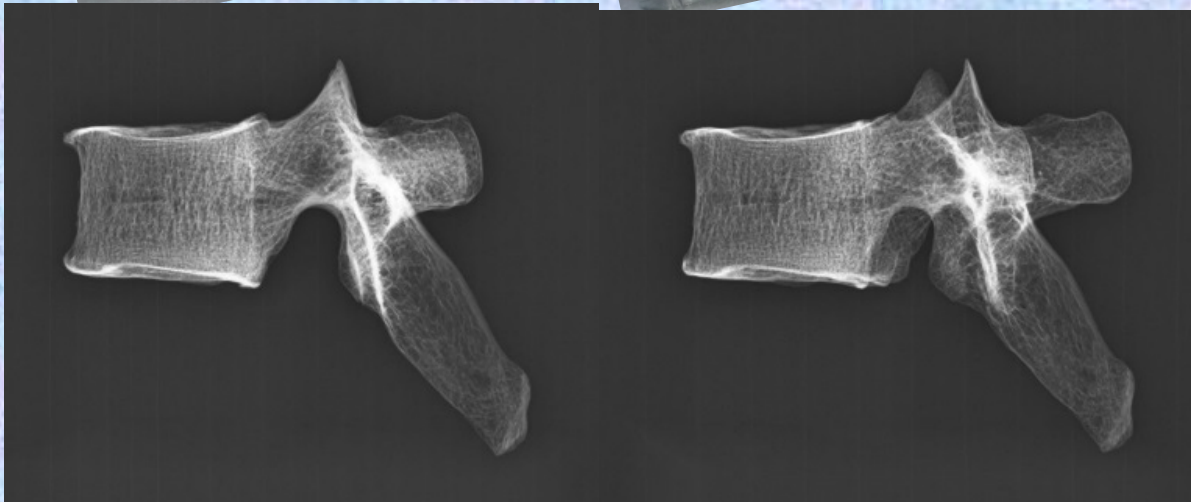
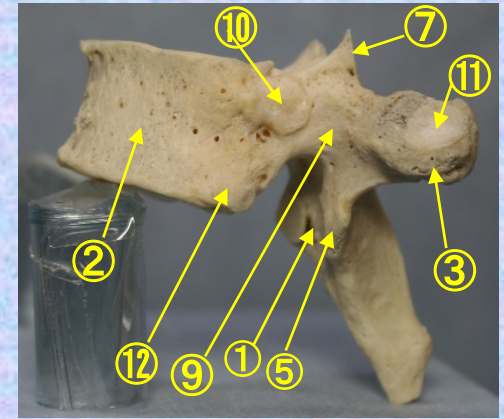


胸椎 Th8 側面

Th8



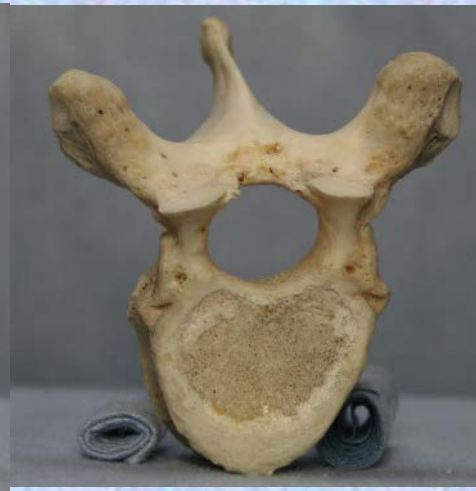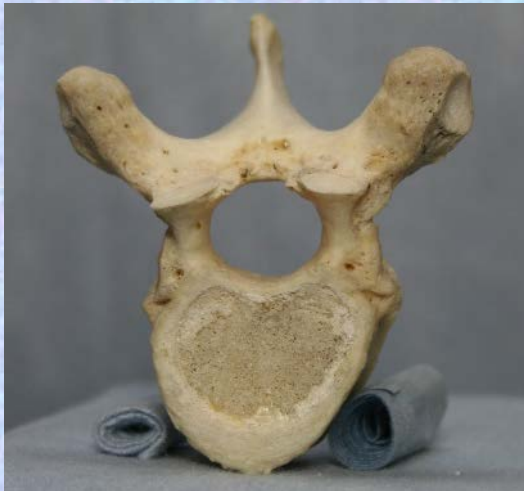左横面



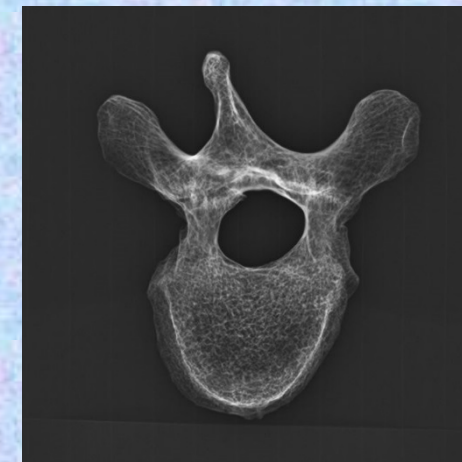
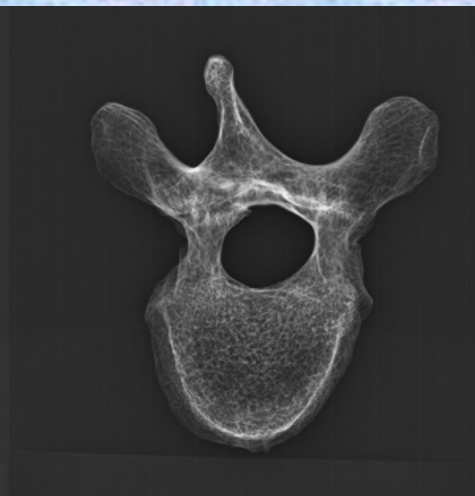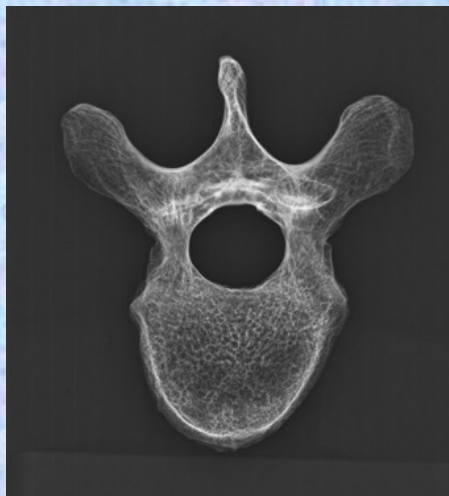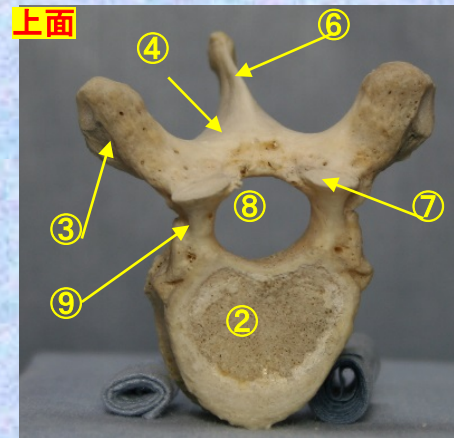
- ①下関節面(下関節突起関節面) inferior articular surface
- ②椎体 transverse process
- ③横突起 transverse process
- ④椎弓板 lamina
- ⑤下関節突起 inferior articular process
- ⑥棘突起 spinous process

- ⑦上関節突起 superior articular process
- ⑧椎孔 vertebral foramen
- ⑨椎弓根 pedicle
- ⑩上肋骨窩 superior costal facet
- ⑪横突肋骨窩 costal facet of transverse process
- ⑫下肋骨窩 inferior costal facet





上面



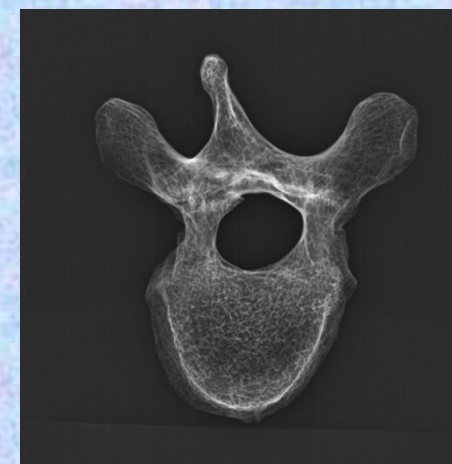
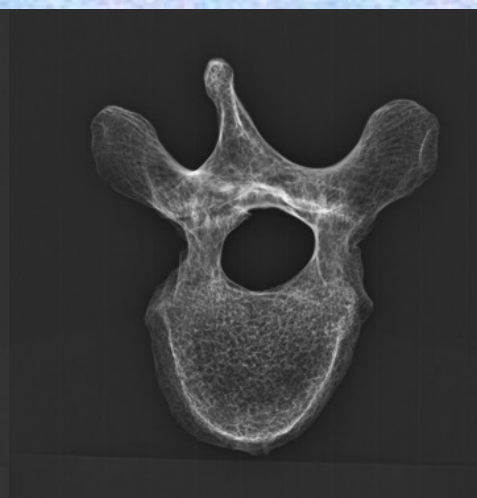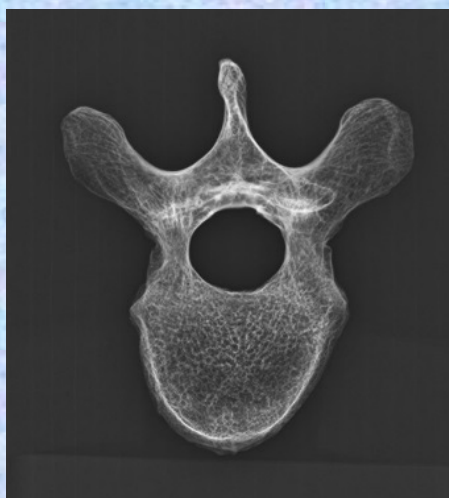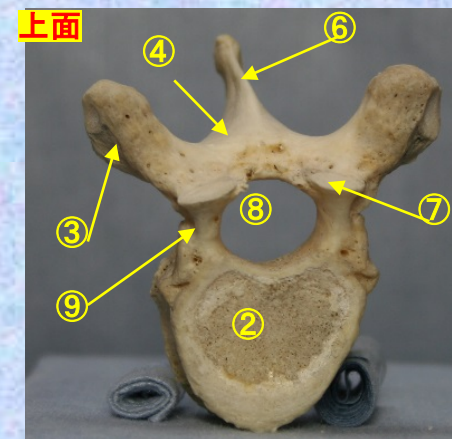
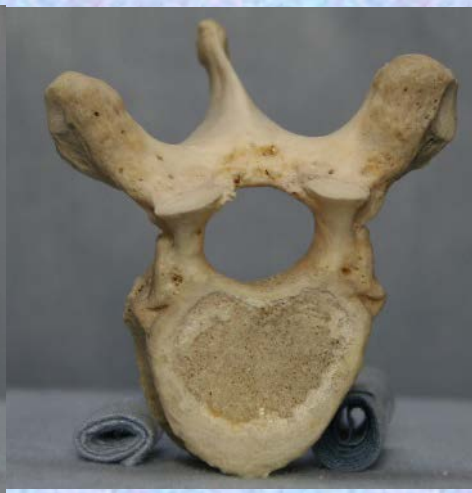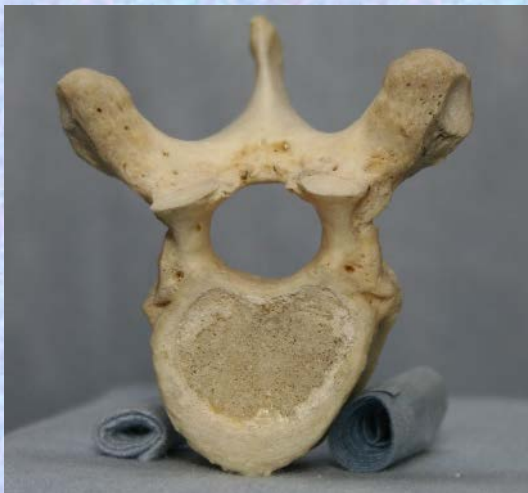- ① 下関節面(下関節突起関節面) inferior articular surface
- ② 椎体 transverse process
- ③ 横突起 transverse process
- ④ 椎弓板 lamina
- ⑤ 下関節突起 inferior articular process
- ⑥ 棘突起 spinous process

- ⑦ 上関節突起 superior articular process
- ⑧ 椎孔 vertebral foramen
- ⑨ 椎弓根 pedicle
- ⑩ 上肋骨窩 superior costal facet
- ⑪ 横突肋骨窩 costal facet of transverse process
- ⑫ 下肋骨窩 inferior costal facet



胸椎 Th8 下面

Th8



- ① 下関節面(下関節突起関節面) inferior articular surface
- ② 椎体 transverse process
- ③ 横突起 transverse process
- ④ 椎弓板 lamina
- ⑤ 下関節突起 inferior articular process
- ⑥ 棘突起 spinous process

- ⑦ 上関節突起 superior articular process
- ⑧ 椎孔 vertebral foramen
- ⑨ 椎弓根 pedicle
- ⑩ 上肋骨窩 superior costal facet
- ⑪ 横突肋骨窩 costal facet of transverse process
- ⑫ 下肋骨窩 inferior costal facet



第9胸椎

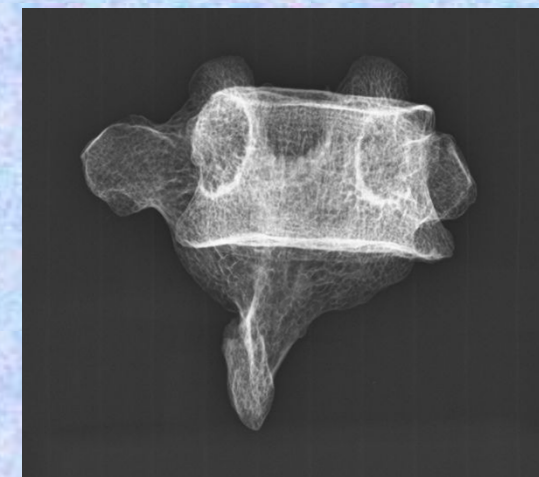
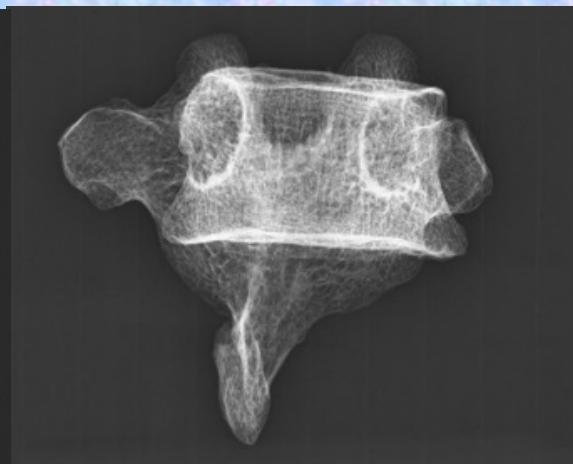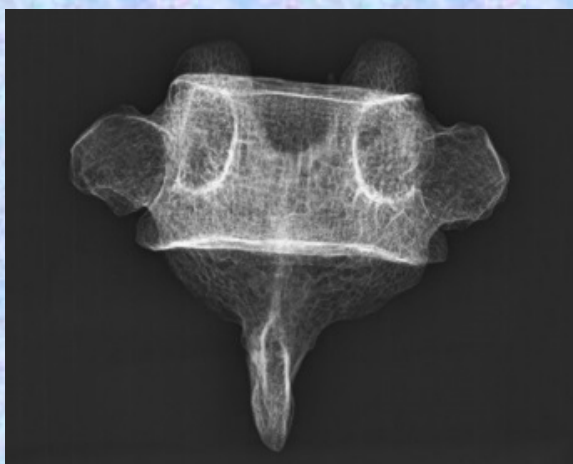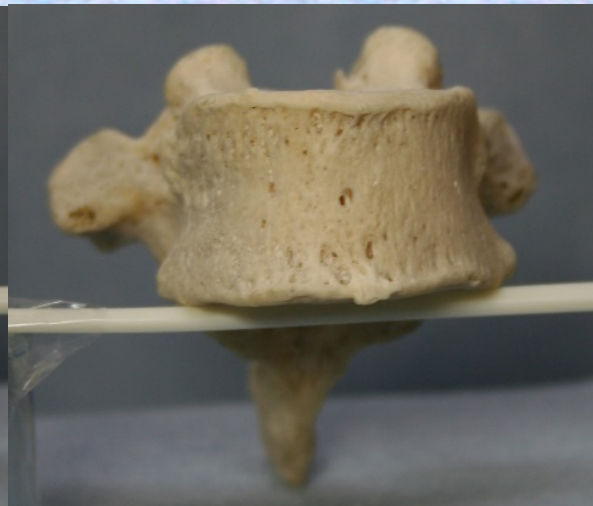
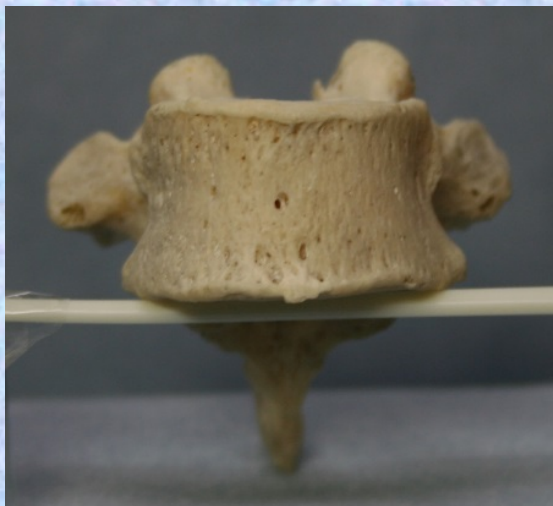
Thoracic vertebra 9

Th9



胸椎 Th9 前面

Th9



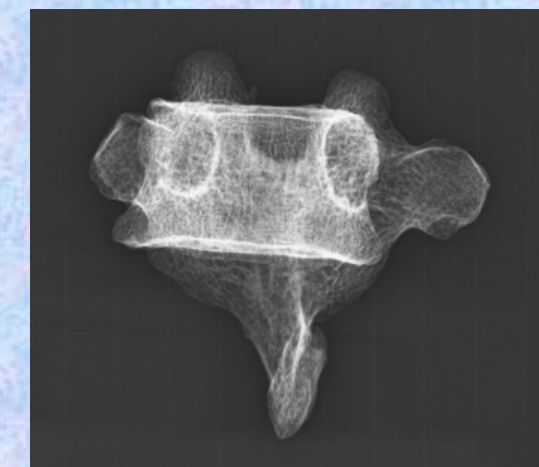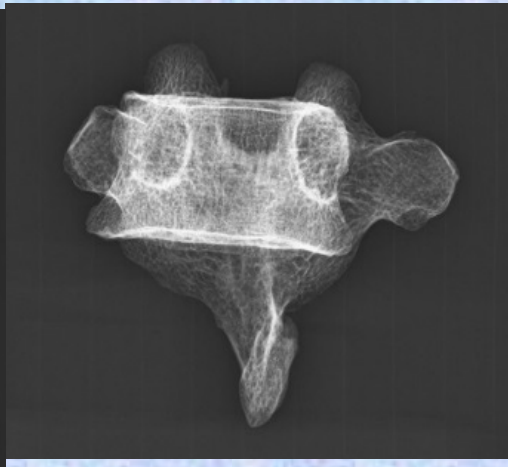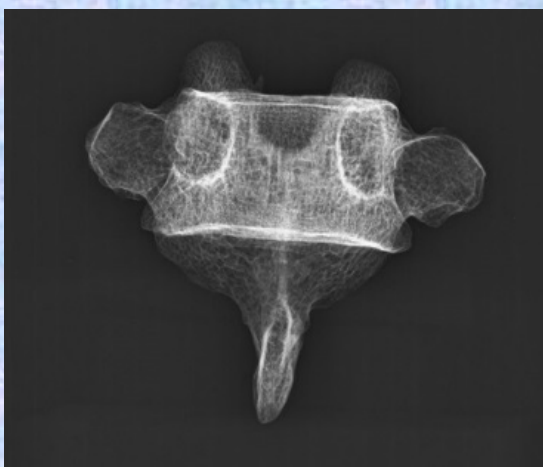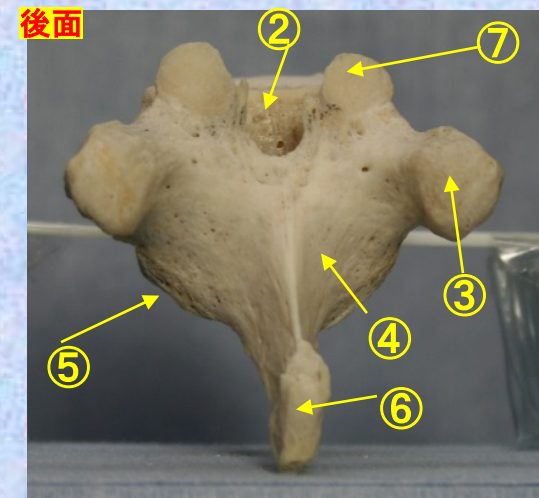
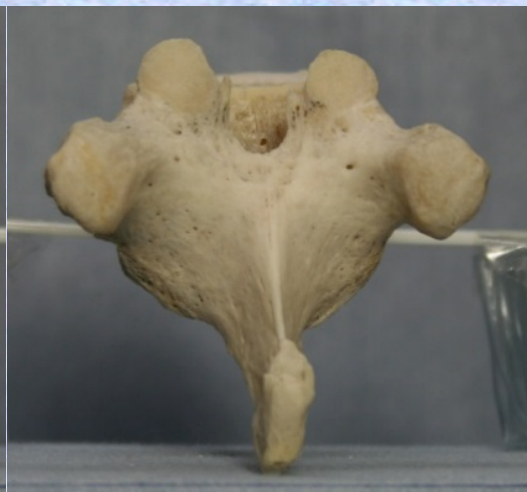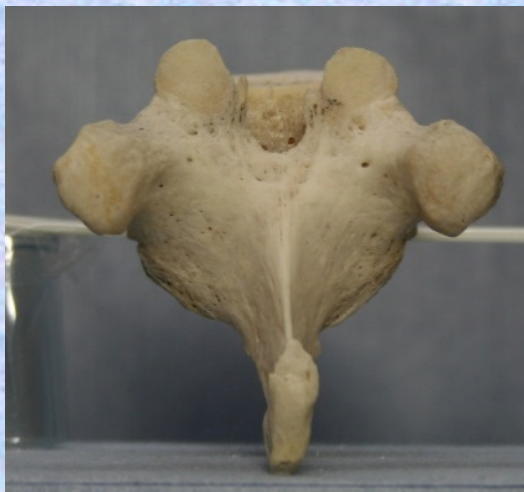- ① 下関節面(下関節突起関節面) inferior articular surface
- ② 椎体 transverse process
- ③ 横突起 transverse process
- ④ 椎弓板 lamina
- ⑤ 下関節突起 inferior articular process
- ⑥ 棘突起 spinous process

- ⑦ 上関節突起 superior articular process
- ⑧ 椎孔 vertebral foramen
- ⑨ 椎弓根 pedicle
- ⑩ 上肋骨窩 superior costal facet
- ⑪ 横突肋骨窩 costal facet of transverse process
- ⑫ 下肋骨窩 inferior costal facet



胸椎 Th9 後面

Th9



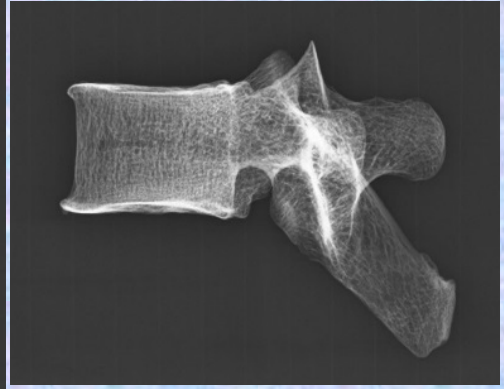
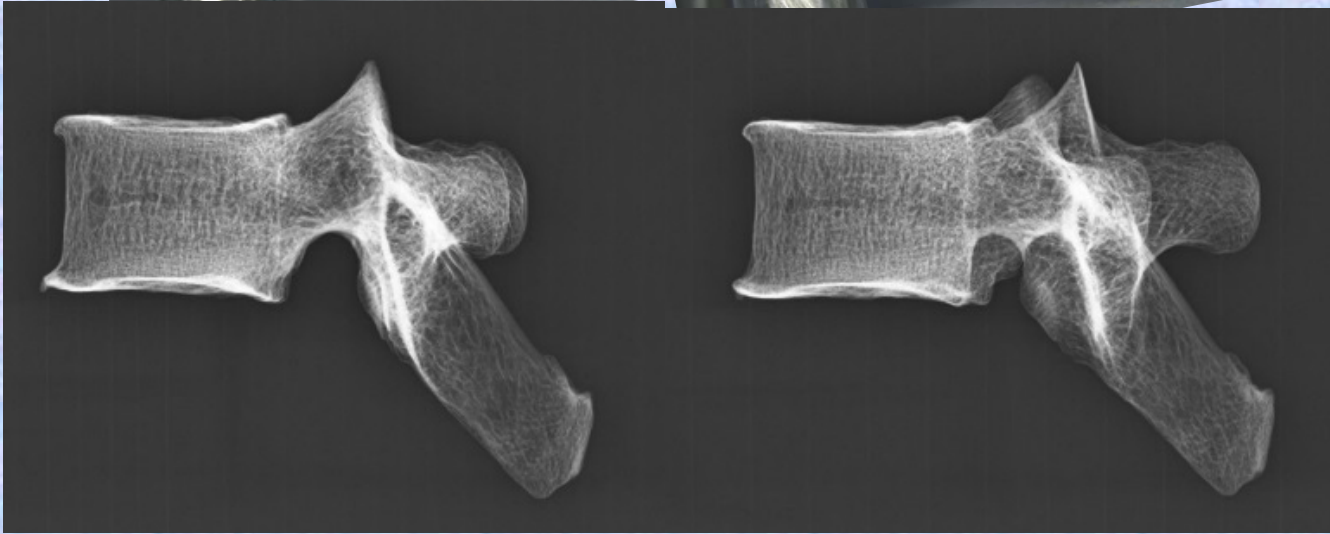
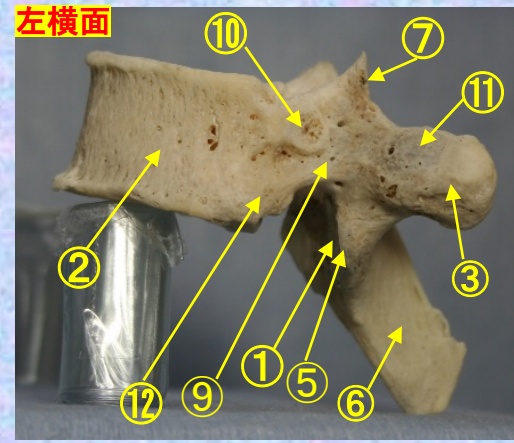

- ① 下関節面(下関節突起関節面) inferior articular surface
- ② 椎体 transverse process
- ③ 横突起 transverse process
- ④ 椎弓板 lamina
- ⑤ 下関節突起 inferior articular process
- ⑥ 棘突起 spinous process

- ⑦ 上関節突起 superior articular process
- ⑧ 椎孔 vertebral foramen
- ⑨ 椎弓根 pedicle
- ⑩ 上肋骨窩 superior costal facet
- ⑪ 横突肋骨窩 costal facet of transverse process
- ⑫ 下肋骨窩 inferior costal facet



胸椎 Th9 側面

Th9



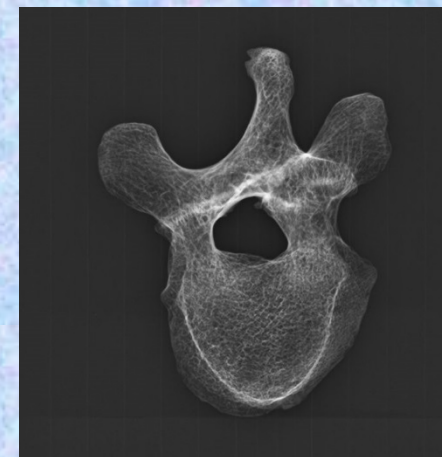
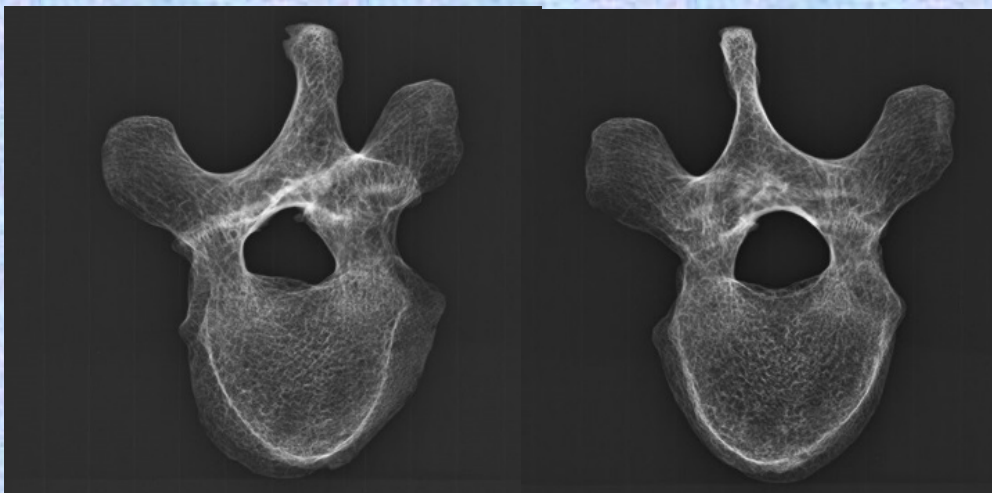
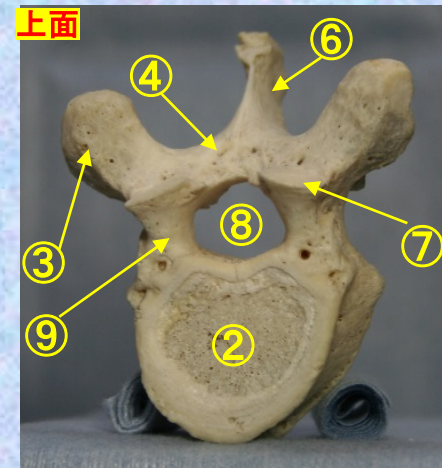
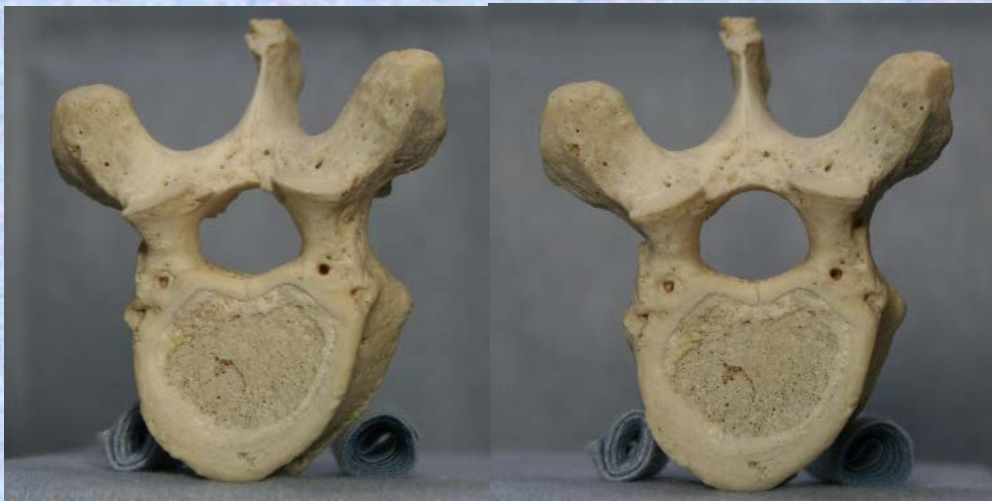- ① 下関節面(下関節突起関節面) inferior articular surface
- ② 椎体 transverse process
- ③ 横突起 transverse process
- ④ 椎弓板 lamina
- ⑤ 下関節突起 inferior articular process
- ⑥ 棘突起 spinous process

- ⑦ 上関節突起 superior articular process
- ⑧ 椎孔 vertebral foramen
- ⑨ 椎弓根 pedicle
- ⑩ 上肋骨窩 superior costal facet
- ⑪ 横突肋骨窩 costal facet of transverse process
- ⑫ 下肋骨窩 inferior costal facet



胸椎 Th9 上面

Th9



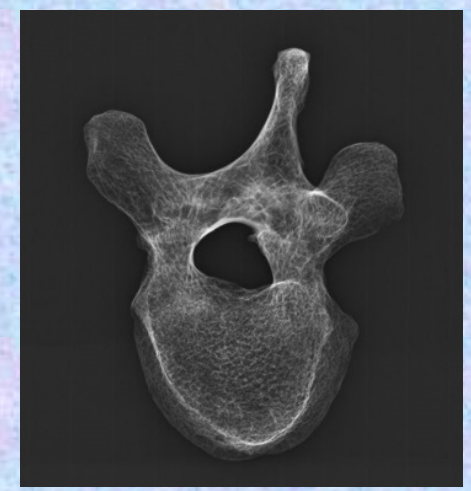
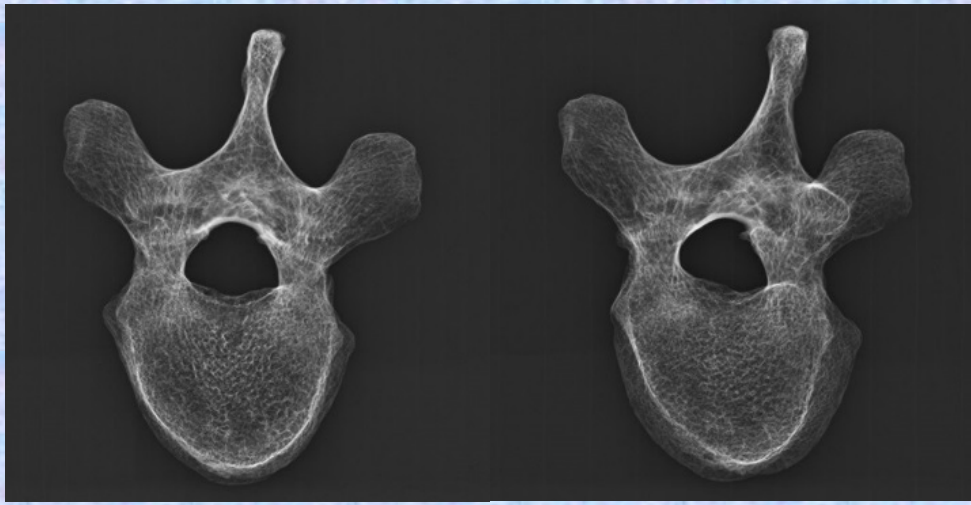
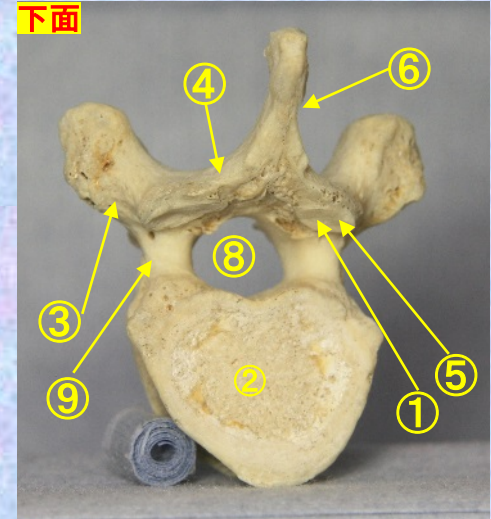
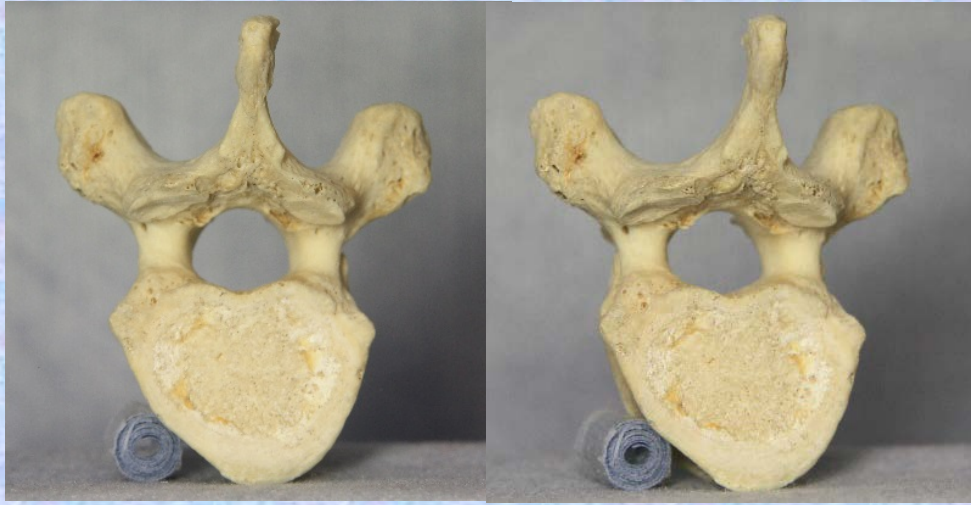- ① 下関節面(下関節突起関節面) inferior articular surface
- ② 椎体 transverse process
- ③ 横突起 transverse process
- ④ 椎弓板 lamina
- ⑤ 下関節突起 inferior articular process
- ⑥ 棘突起 spinous process

- ⑦ 上関節突起 superior articular process
- ⑧ 椎孔 vertebral foramen
- ⑨ 椎弓根 pedicle
- ⑩ 上肋骨窩 superior costal facet
- ⑪ 横突肋骨窩 costal facet of transverse process
- ⑫ 下肋骨窩 inferior costal facet



胸椎 Th9 下面

Th9



- ① 下関節面(下関節突起関節面) inferior articular surface
- ② 椎体 transverse process
- ③ 横突起 transverse process
- ④ 椎弓板 lamina
- ⑤ 下関節突起 inferior articular process
- ⑥ 棘突起 spinous process

- ⑦ 上関節突起 superior articular process
- ⑧ 椎孔 vertebral foramen
- ⑨ 椎弓根 pedicle
- ⑩ 上肋骨窩 superior costal facet
- ⑪ 横突肋骨窩 costal facet of transverse process
- ⑫ 下肋骨窩 inferior costal facet



第10胸椎

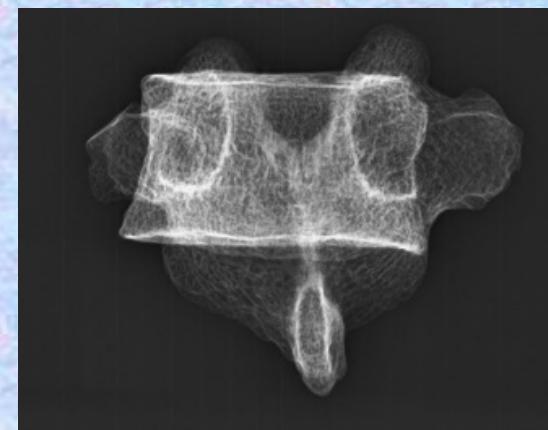
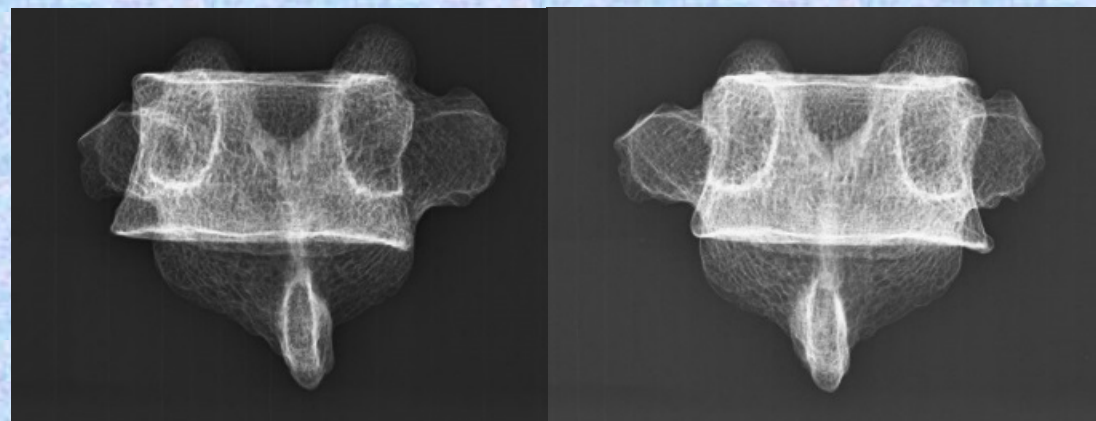


Thoracic vertebra 10

Th10



胸椎 Th10 前面

Th10



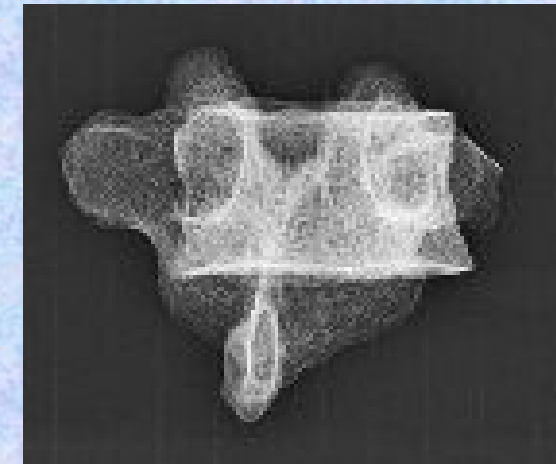
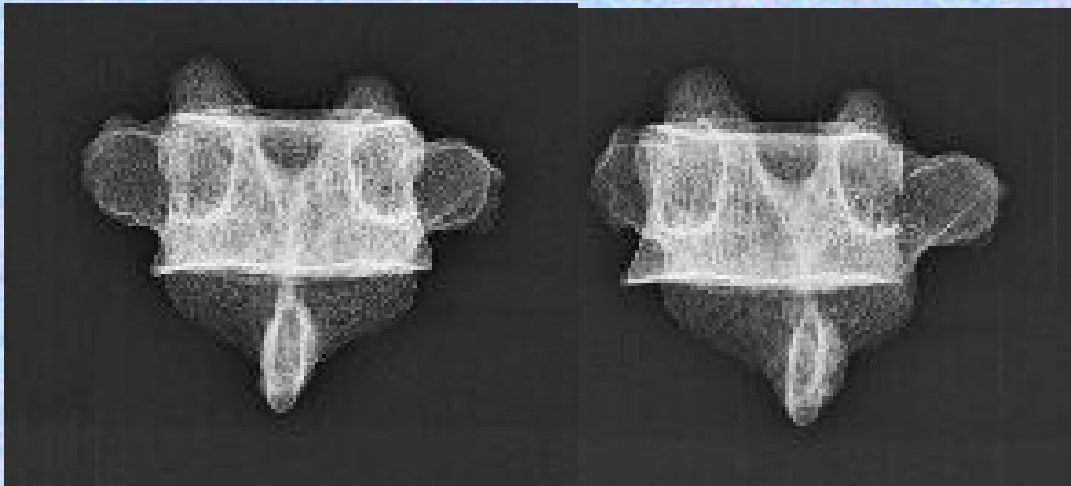
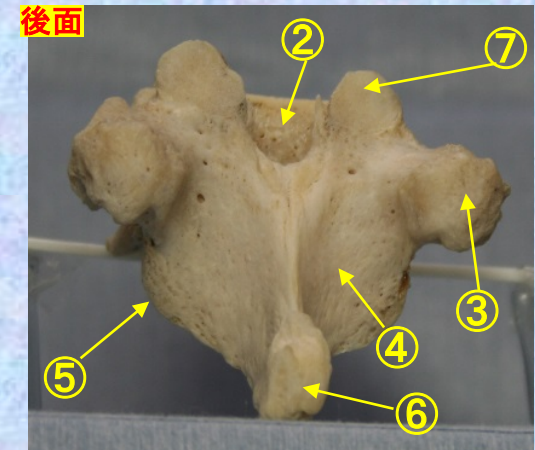
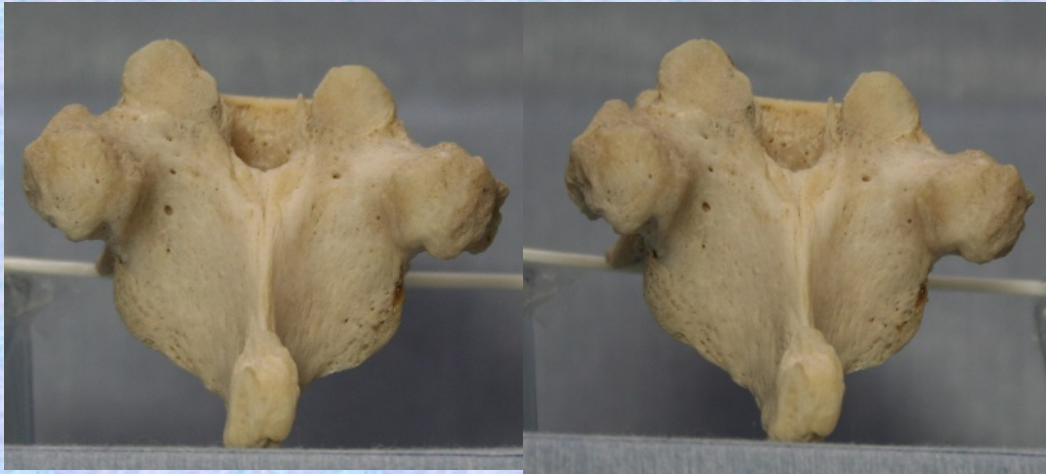- ① 下関節面(下関節突起関節面) inferior articular surface
- ② 椎体 transverse process
- ③ 横突起 transverse process
- ④ 椎弓板 lamina
- ⑤ 下関節突起 inferior articular process
- ⑥ 棘突起 spinous process

- ⑦ 上関節突起 superior articular process
- ⑧ 椎孔 vertebral foramen
- ⑨ 椎弓根 pedicle
- ⑩ 上肋骨窩 superior costal facet
- ⑪ 横突肋骨窩 costal facet of transverse process
- ⑫ 下肋骨窩 inferior costal facet



胸椎 Th 10 後面

Th10



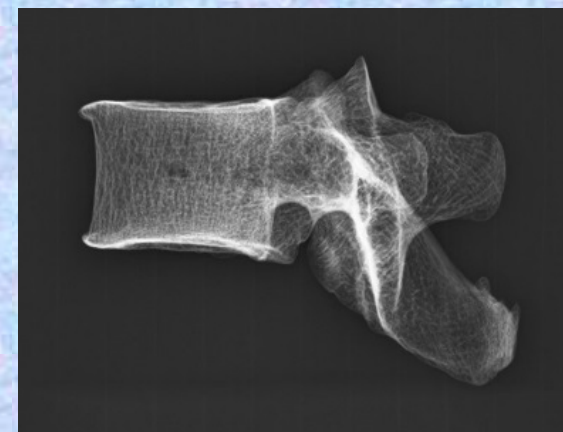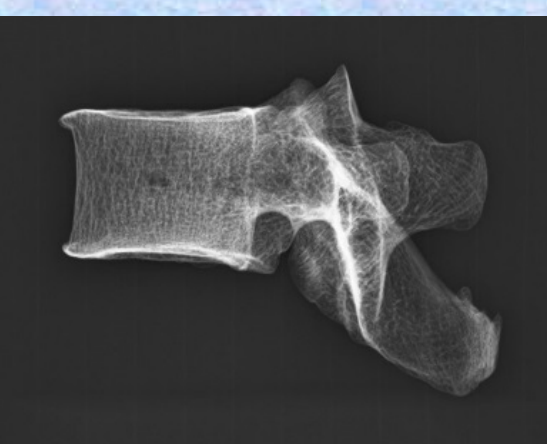
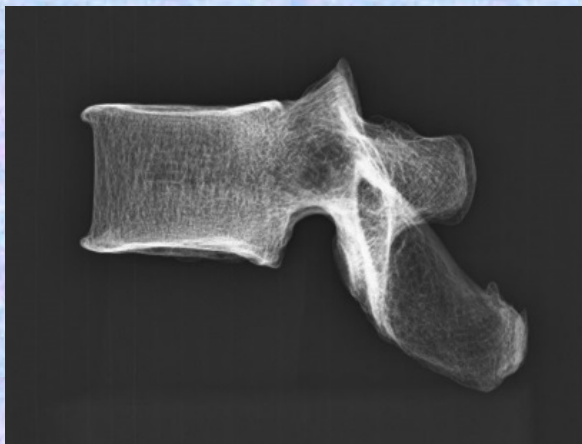
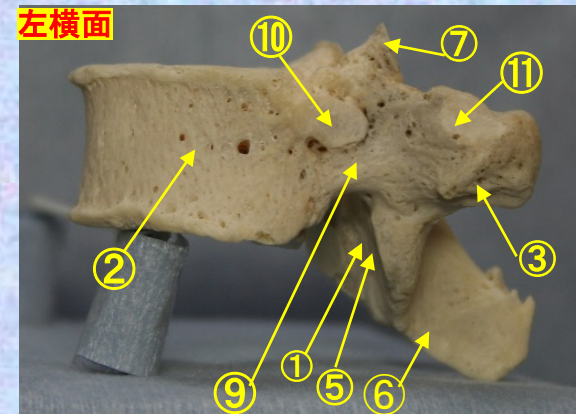
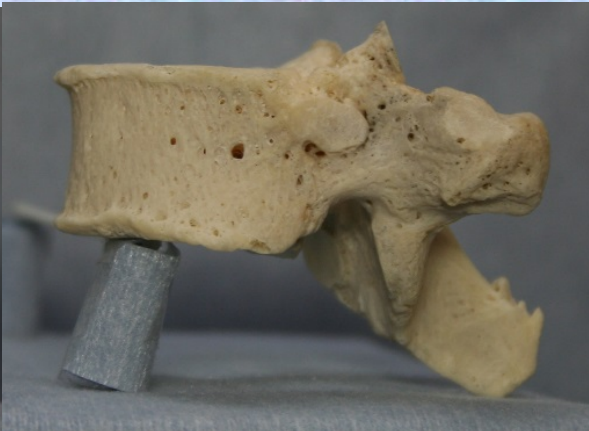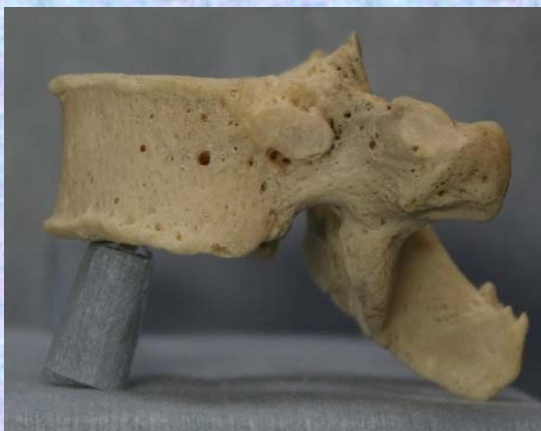- ① 下関節面(下関節突起関節面) inferior articular surface
- ② 椎体 transverse process
- ③ 横突起 transverse process
- ④ 椎弓板 lamina
- ⑤ 下関節突起 inferior articular process
- ⑥ 棘突起 spinous process

- ⑦ 上関節突起 superior articular process
- ⑧ 椎孔 vertebral foramen
- ⑨ 椎弓根 pedicle
- ⑩ 上肋骨窩 superior costal facet
- ⑪ 横突肋骨窩 costal facet of transverse process
- ⑫ 下肋骨窩 inferior costal facet



胸椎 Th10 側面

Th10



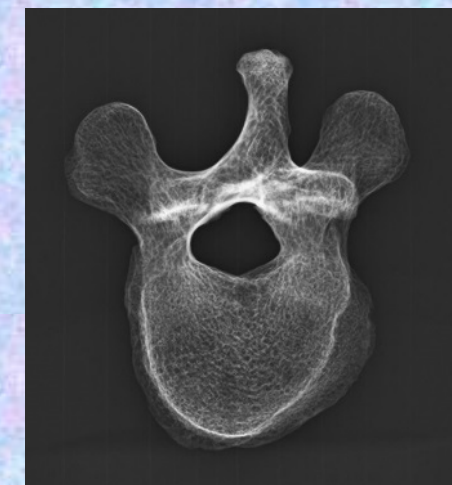
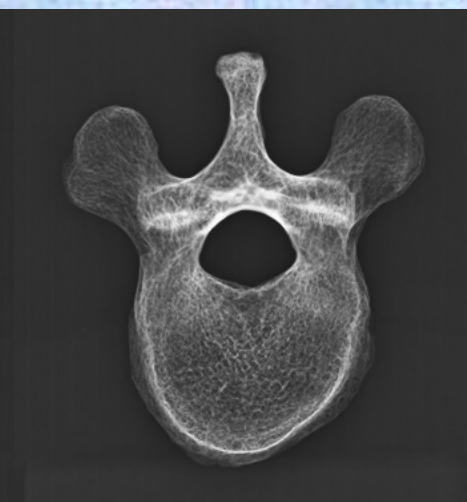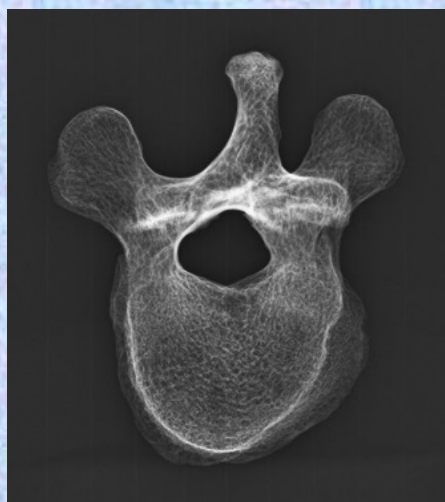
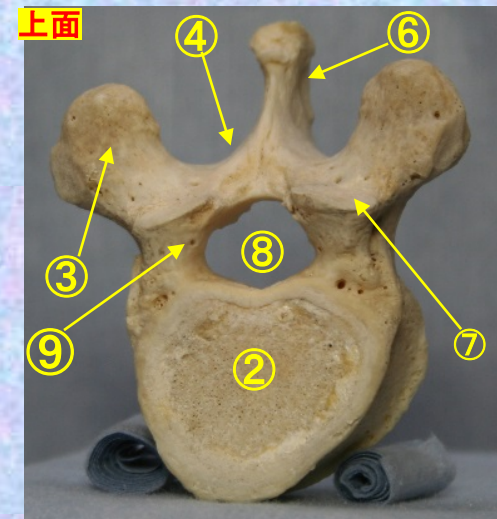
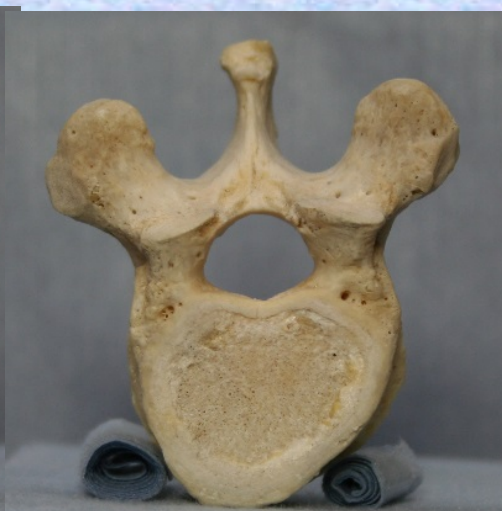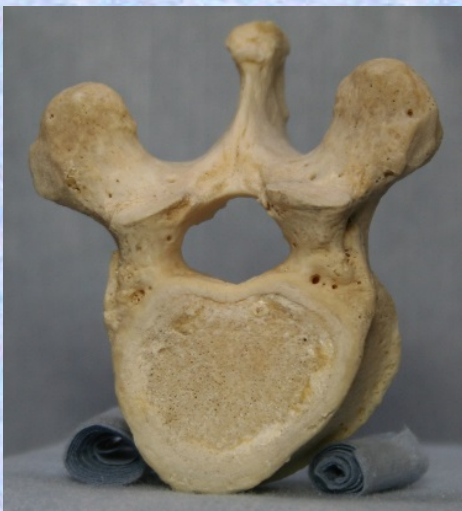- ① 下関節面(下関節突起関節面) inferior articular surface
- ② 椎体 transverse process
- ③ 横突起 transverse process
- ④ 椎弓板 lamina
- ⑤ 下関節突起 inferior articular process
- ⑥ 棘突起 spinous process

- ⑦ 上関節突起 superior articular process
- ⑧ 椎孔 vertebral foramen
- ⑨ 椎弓根 pedicle
- ⑩ 上肋骨窩 superior costal facet
- ⑪ 横突肋骨窩 costal facet of transverse process
- ⑫ 下肋骨窩 inferior costal facet



胸椎 Th 10 上面

Th10



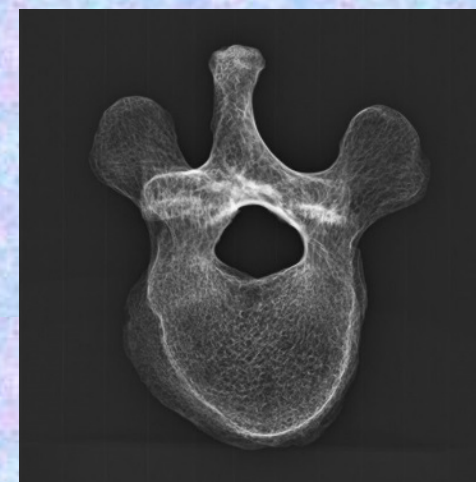
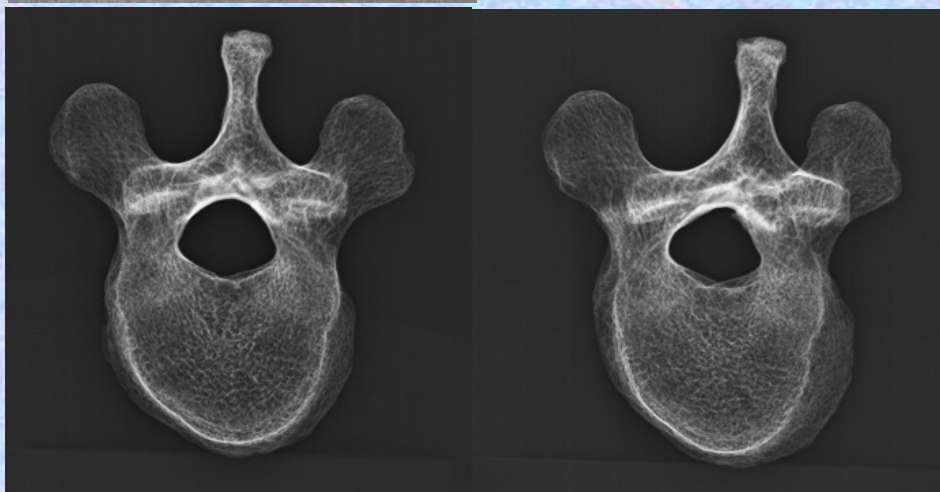
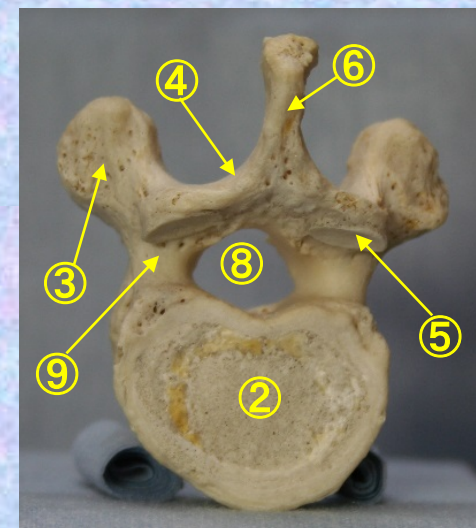
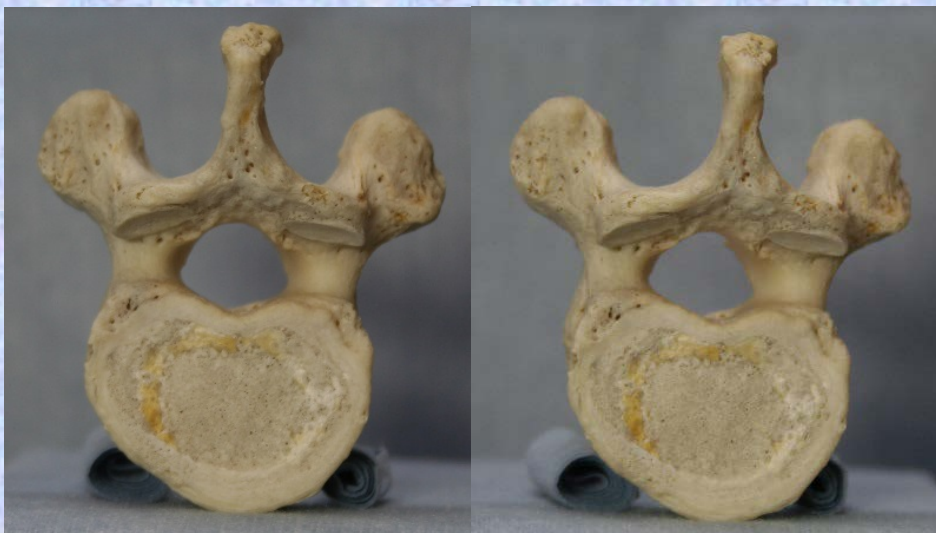
- ① 下関節面(下関節突起関節面) inferior articular surface
- ② 椎体 transverse process
- ③ 横突起 transverse process
- ④ 椎弓板 lamina
- ⑤ 下関節突起 inferior articular process
- ⑥ 棘突起 spinous process

- ⑦ 上関節突起 superior articular process
- ⑧ 椎孔 vertebral foramen
- ⑨ 椎弓根 pedicle
- ⑩ 上肋骨窩 superior costal facet
- ⑪ 横突肋骨窩 costal facet of transverse process
- ⑫ 下肋骨窩 inferior costal facet



胸椎 Th 10 下面

Th10



- ① 下関節面(下関節突起関節面) inferior articular surface
- ② 椎体 transverse process
- ③ 横突起 transverse process
- ④ 椎弓板 lamina
- ⑤ 下関節突起 inferior articular process
- ⑥ 棘突起 spinous process

- ⑦ 上関節突起 superior articular process
- ⑧ 椎孔 vertebral foramen
- ⑨ 椎弓根 pedicle
- ⑩ 上肋骨窩 superior costal facet
- ⑪ 横突肋骨窩 costal facet of transverse process
- ⑫ 下肋骨窩 inferior costal facet

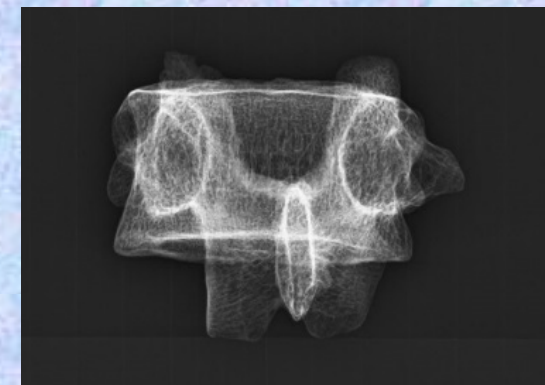
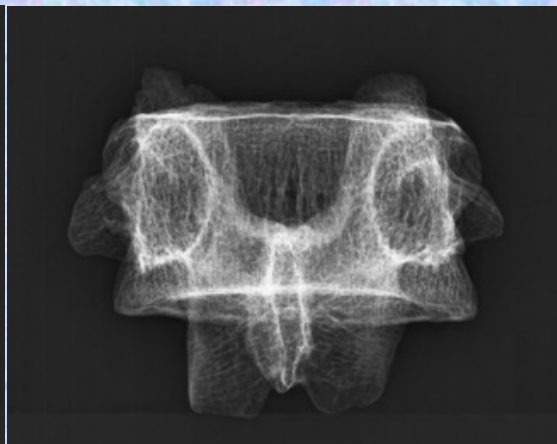
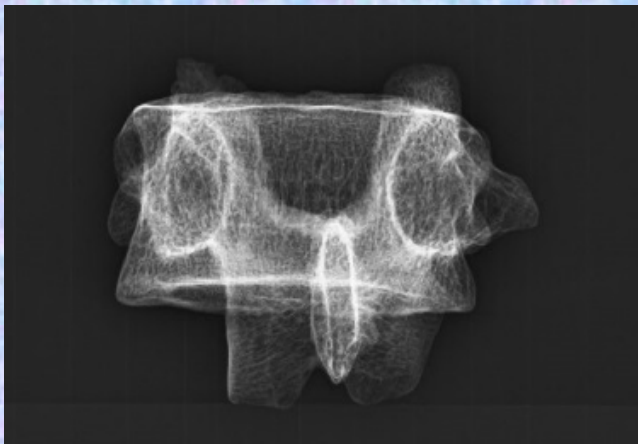


第11胸椎

Thoracic vertebra 11

Th11

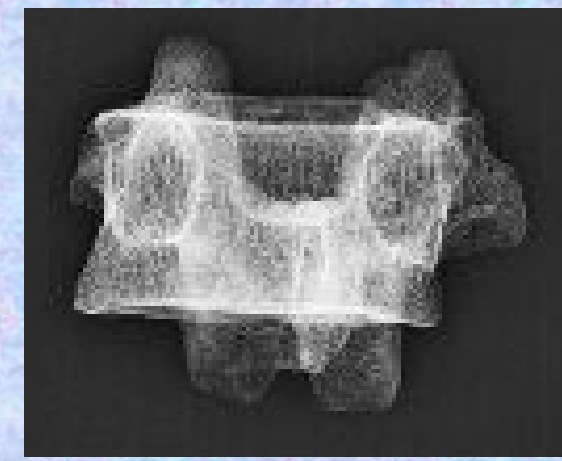
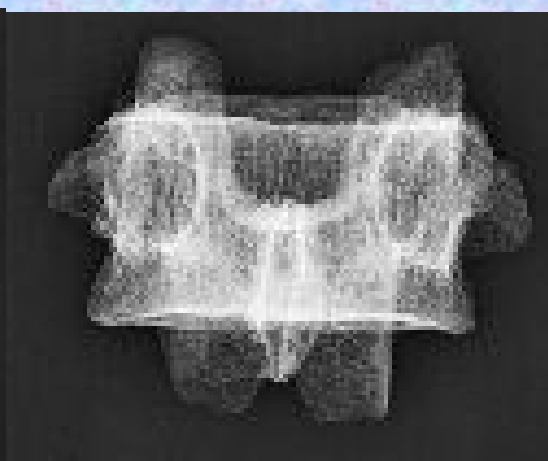
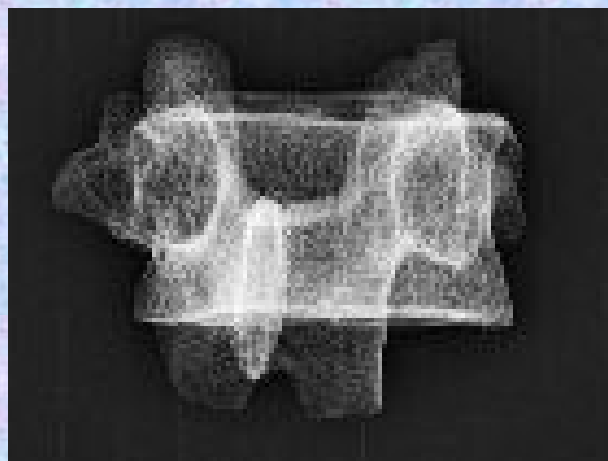
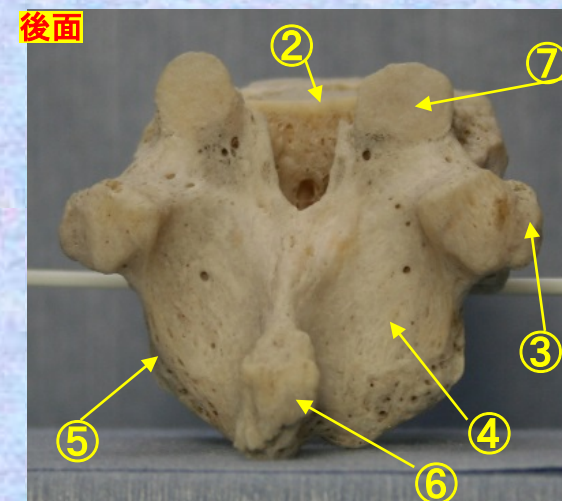
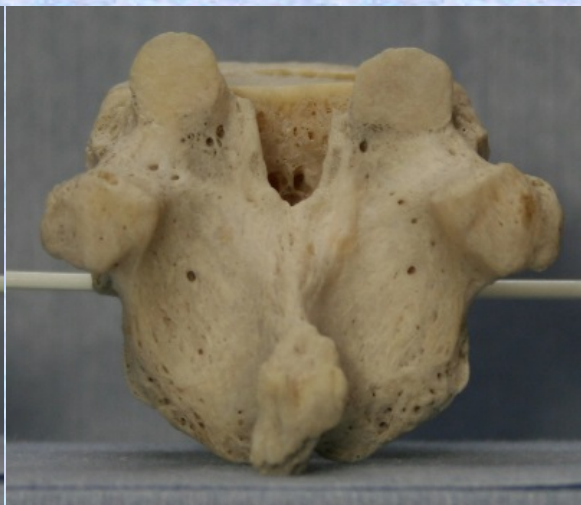
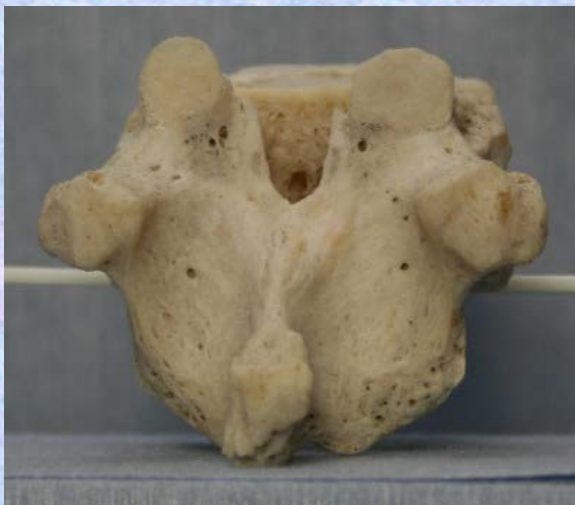


- ①下関節面(下関節突起関節面) inferior articular surface
- ②椎体 transverse process
- ③横突起 transverse process
- ④椎弓板 lamina
- ⑤下関節突起 inferior articular process
- ⑥棘突起 spinous process

- ⑦上関節突起 superior articular process
- ⑧椎孔 vertebral foramen
- ⑨椎弓根 pedicle
- ⑩上肋骨窩 superior costal facet
- ⑪横突肋骨窩 costal facet of transverse process
- ⑫下肋骨窩 inferior costal facet





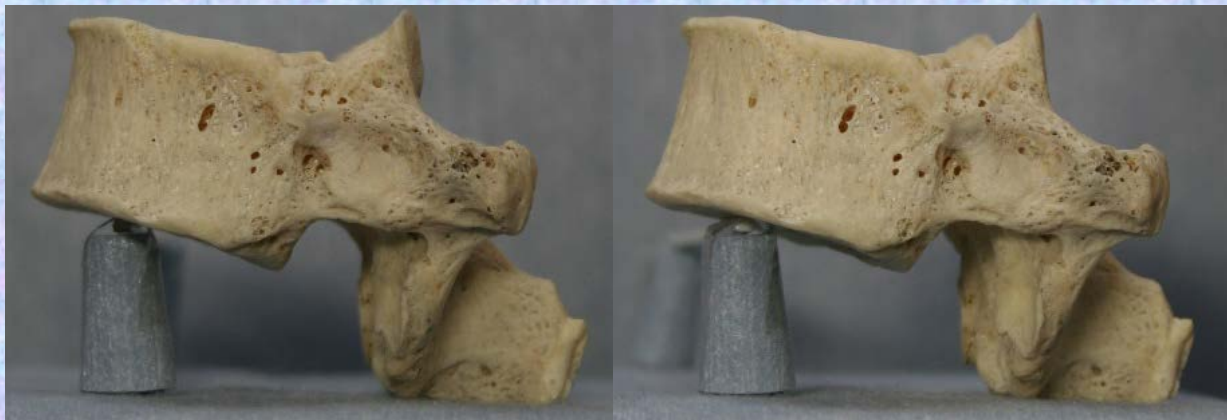- ①下関節面(下関節突起関節面) inferior articular surface
- ②椎体 transverse process
- ③横突起 transverse process
- ④椎弓板 lamina
- ⑤下関節突起 inferior articular process
- ⑥棘突起 spinous process

- ⑦上関節突起 superior articular process
- ⑧椎孔 vertebral foramen
- ⑨椎弓根 pedicle
- ⑩上肋骨窩 superior costal facet
- ⑪横突肋骨窩 costal facet of transverse process
- ⑫下肋骨窩 inferior costal facet

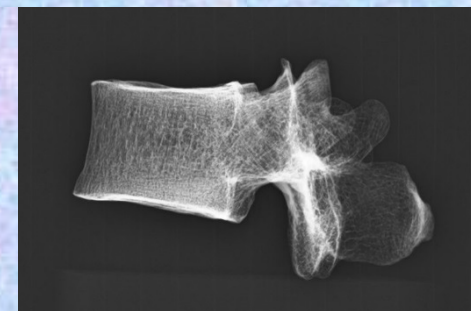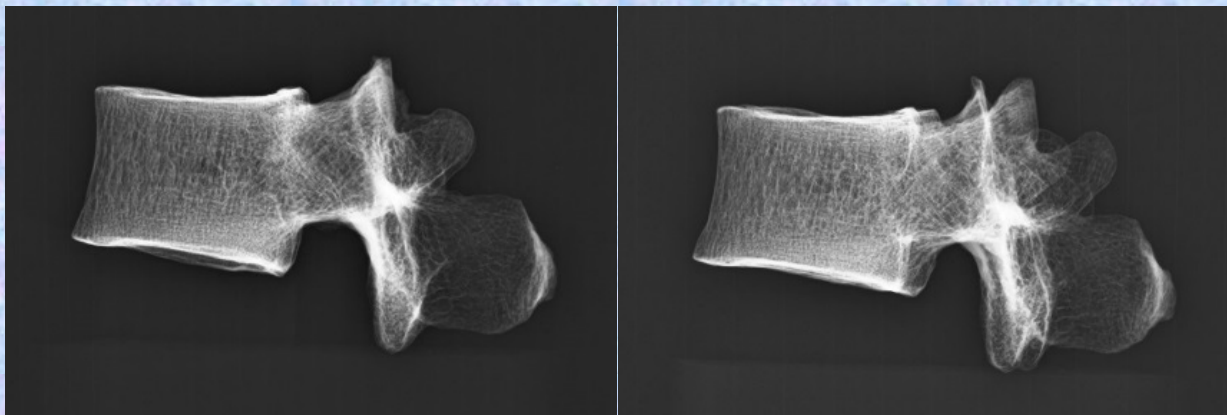
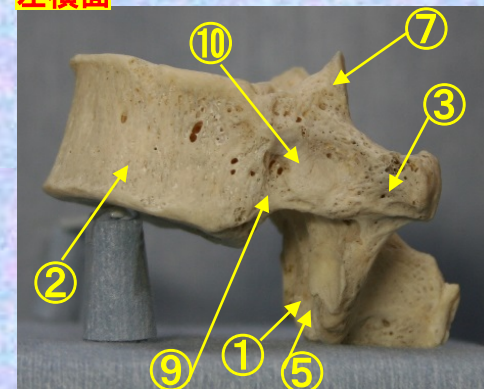


胸椎 Th11 側面

Th11



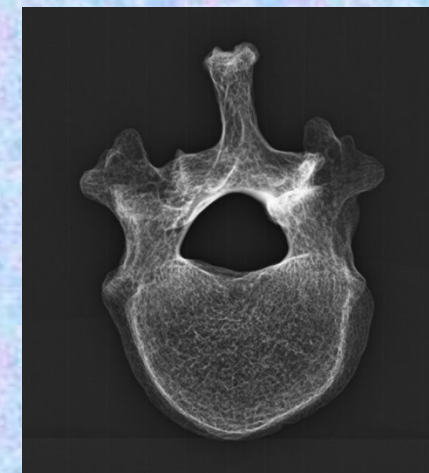
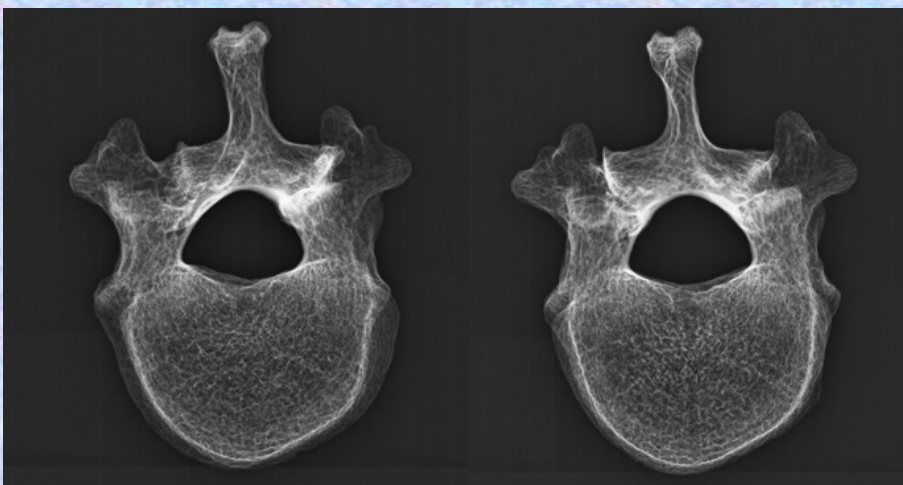
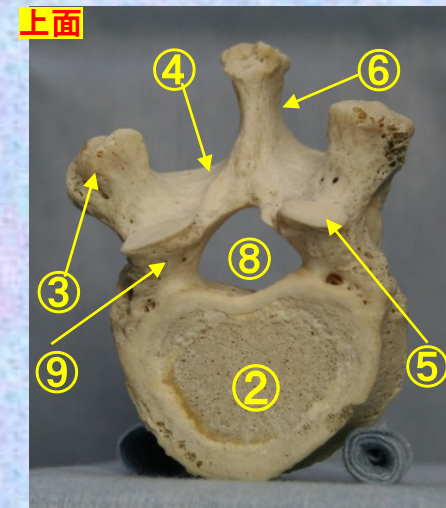
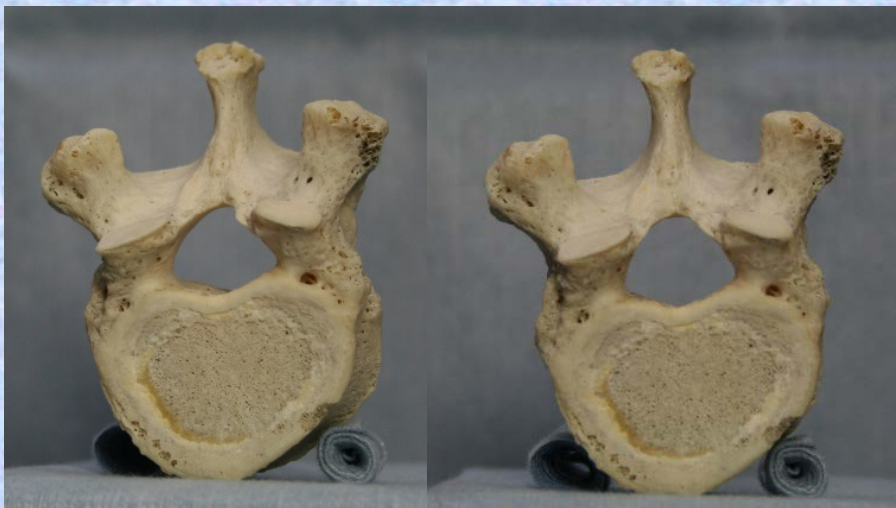左横面



- ①下関節面(下関節突起関節面) inferior articular surface
- ②椎体 transverse process
- ③横突起 transverse process
- ④椎弓板 lamina
- ⑤下関節突起 inferior articular process
- ⑥棘突起 spinous process

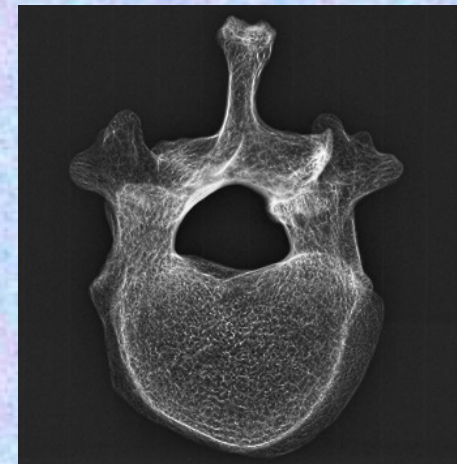
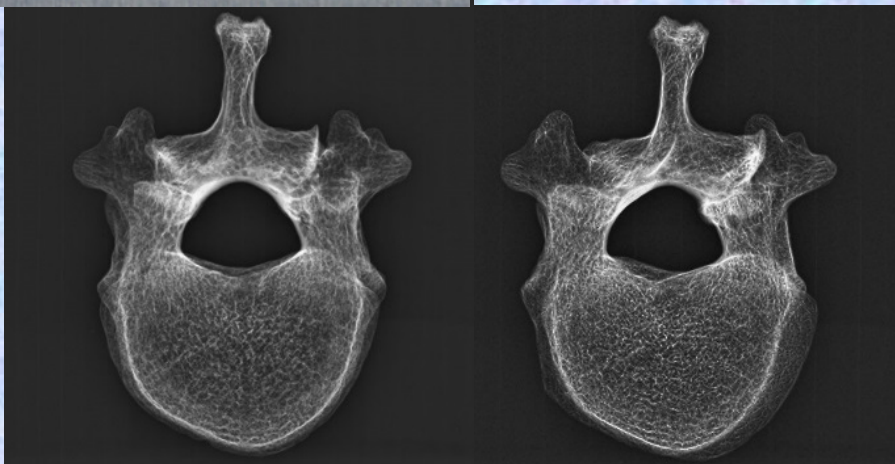
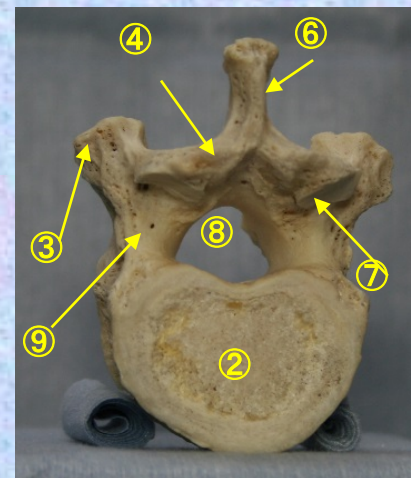
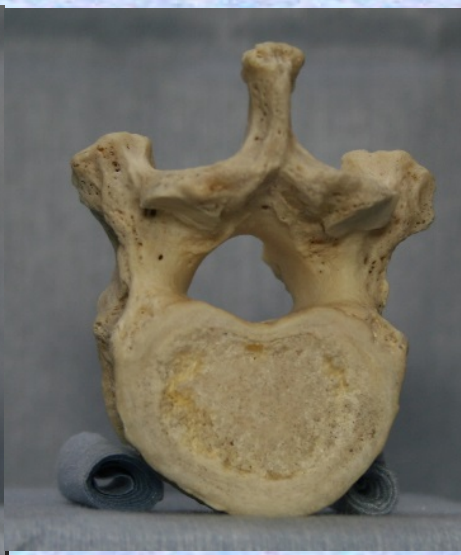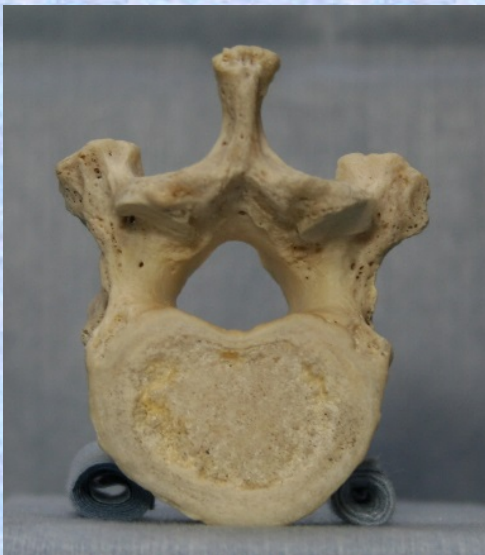- ⑦上関節突起 superior articular process
- ⑧椎孔 vertebral foramen
- ⑨椎弓根 pedicle
- ⑩上肋骨窩 superior costal facet
- ⑪横突肋骨窩 costal facet of transverse process
- ⑫下肋骨窩 inferior costal facet





- ①下関節面(下関節突起関節面) inferior articular surface
- ②椎体 transverse process
- ③横突起 transverse process
- ④椎弓板 lamina
- ⑤下関節突起 inferior articular process
- ⑥棘突起 spinous process

- ⑦上関節突起 superior articular process
- ⑧椎孔 vertebral foramen
- ⑨椎弓根 pedicle
- ⑩上肋骨窩 superior costal facet
- ⑪横突肋骨窩 costal facet of transverse process
- ⑫下肋骨窩 inferior costal facet



- ① 下関節面(下関節突起関節面) inferior articular surface
- ② 椎体 transverse process
- ③ 横突起 transverse process
- ④ 椎弓板 lamina
- ⑤ 下関節突起 inferior articular process
- ⑥ 棘突起 spinous process

- ⑦ 上関節突起 superior articular process
- ⑧ 椎孔 vertebral foramen
- ⑨ 椎弓根 pedicle
- ⑩ 上肋骨窩 superior costal facet
- ⑪ 横突肋骨窩 costal facet of transverse process
- ⑫ 下肋骨窩 inferior costal facet



第12胸椎

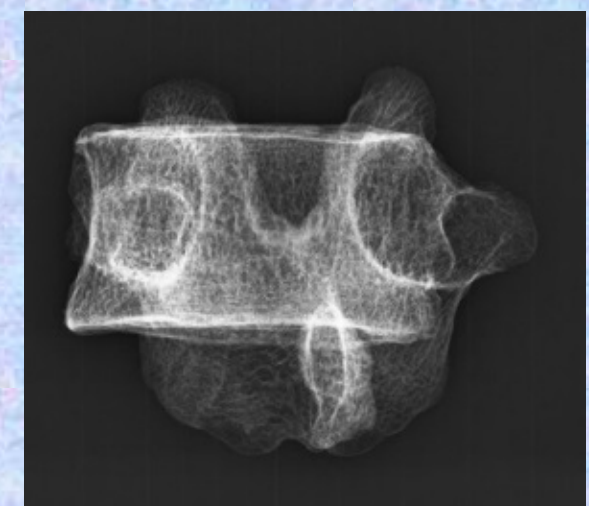
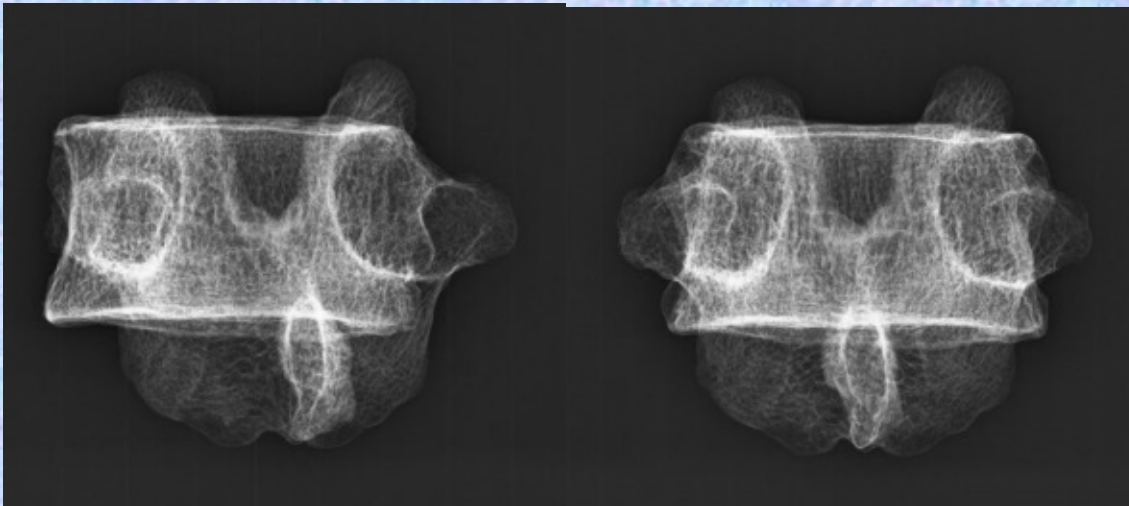

Thoracic vertebra 12

Th12



胸椎 Th12 前面

Th12



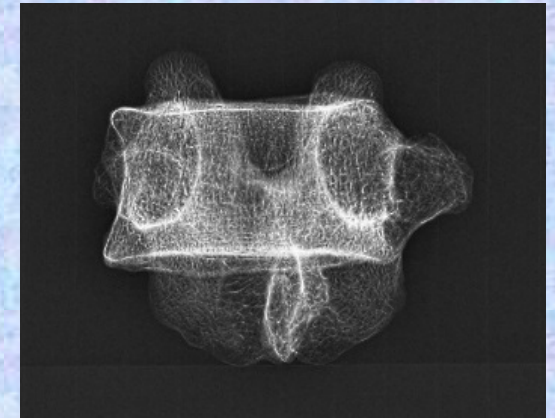
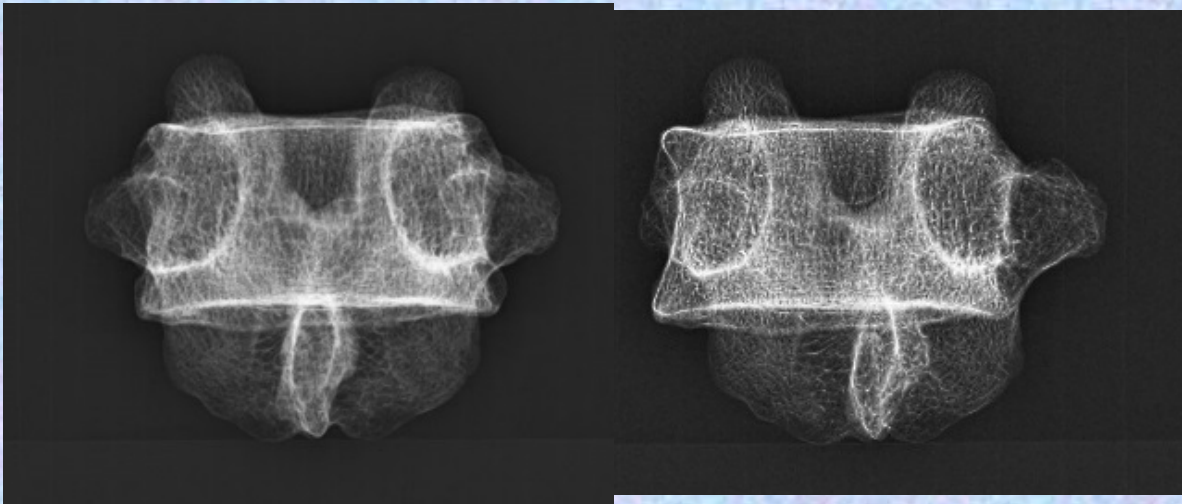
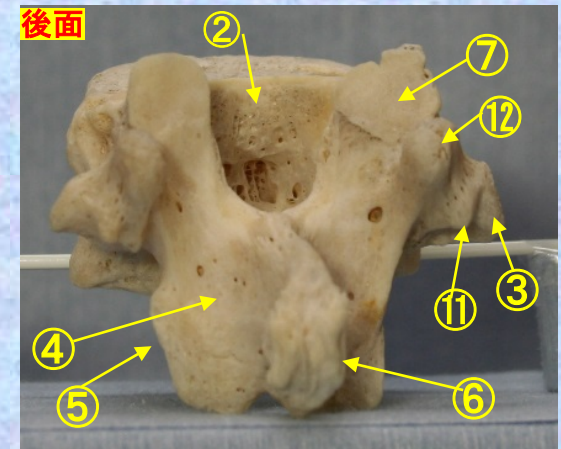
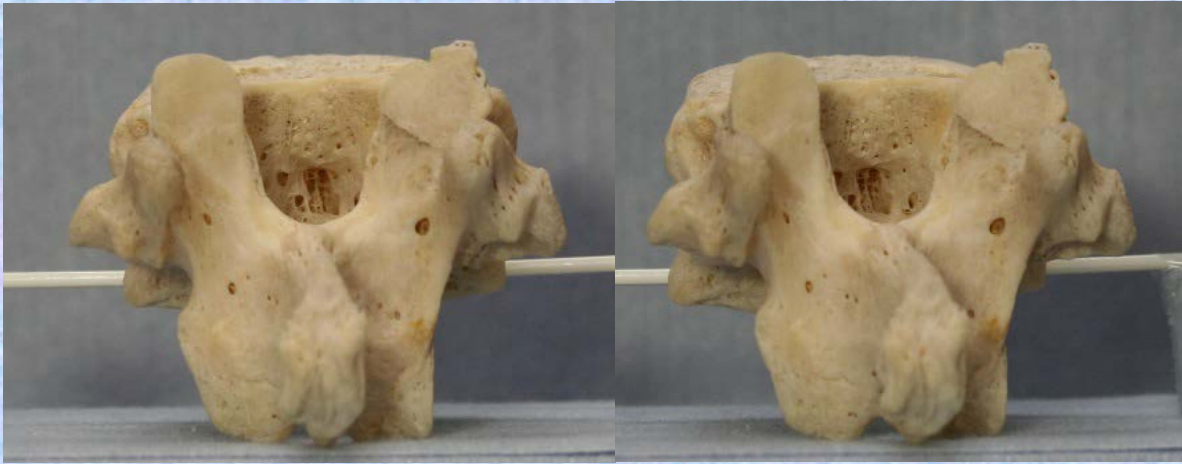- ① 下関節面(下関節突起関節面) inferior articular surface
- ② 椎体 transverse process
- ③ 横突起 transverse process
- ④ 椎弓板 lamina
- ⑤ 下関節突起 inferior articular process
- ⑥ 棘突起 spinous process

- ⑦ 上関節突起 superior articular process
- ⑧ 椎孔 vertebral foramen
- ⑨ 椎弓根 pedicle
- ⑩ 上肋骨窩 superior costal facet
- ⑪ 横突肋骨窩 costal facet of transverse process
- ⑫ 下肋骨窩 inferior costal facet



Th12

胸椎 Th12 後面



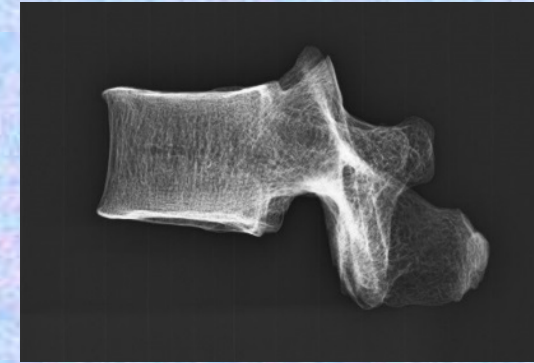
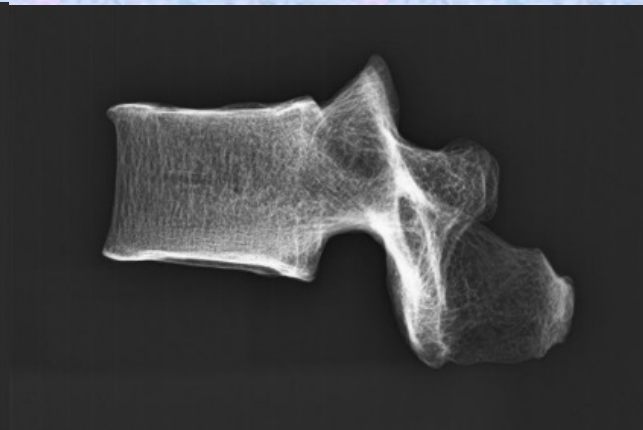
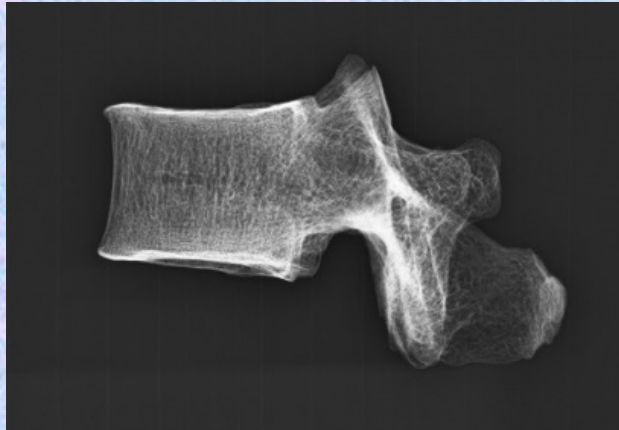
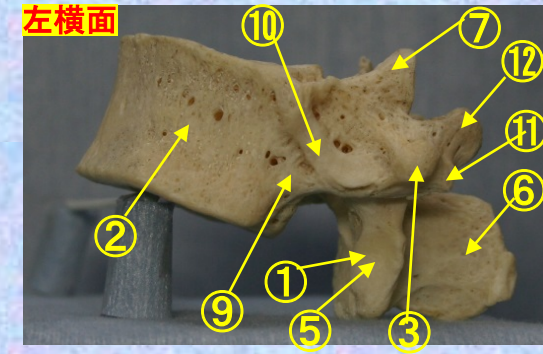
- ① 下関節面(下関節突起関節面) inferior articular surface
- ② 椎体 transverse process
- ③ 横突起 transverse process
- ④ 椎弓板 lamina
- ⑤ 下関節突起 inferior articular process
- ⑥ 棘突起 spinous process

- ⑦ 上関節突起 superior articular process
- ⑧ 椎孔 vertebral foramen
- ⑨ 椎弓根 pedicle
- ⑩ 上肋骨窩 superior costal facet
- ⑪ 横突肋骨窩 costal facet of transverse process
- ⑫ 下肋骨窩 inferior costal facet



Th12

胸椎 Th 12 側面



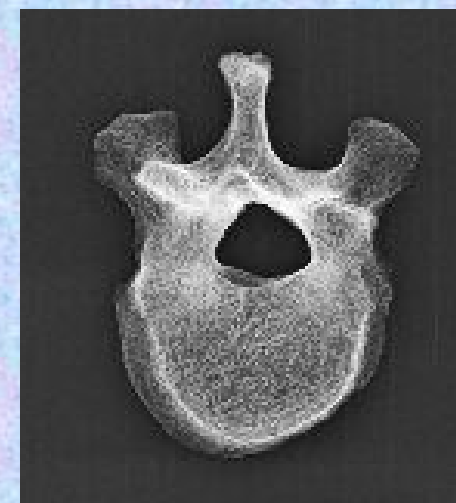
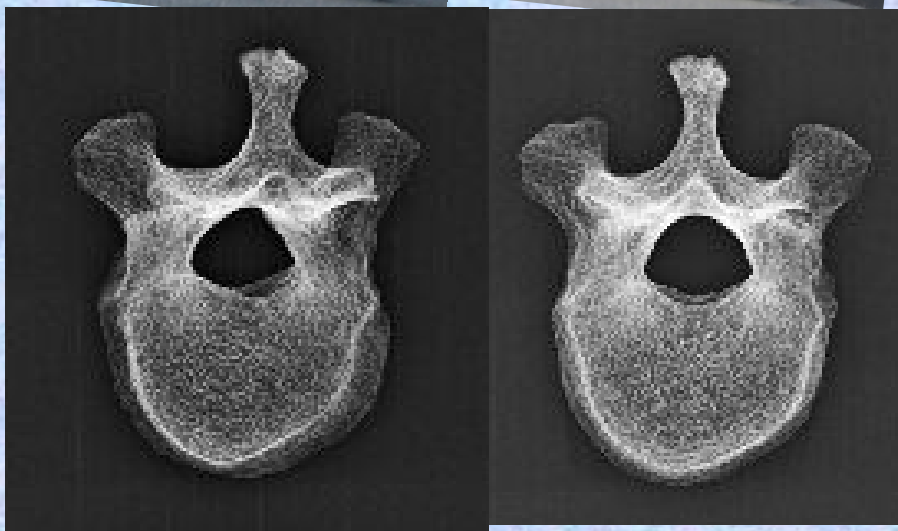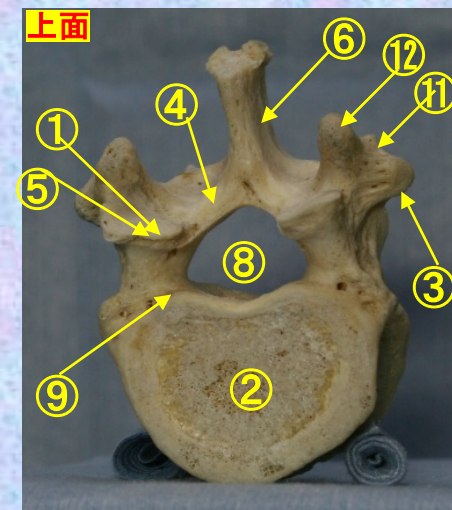
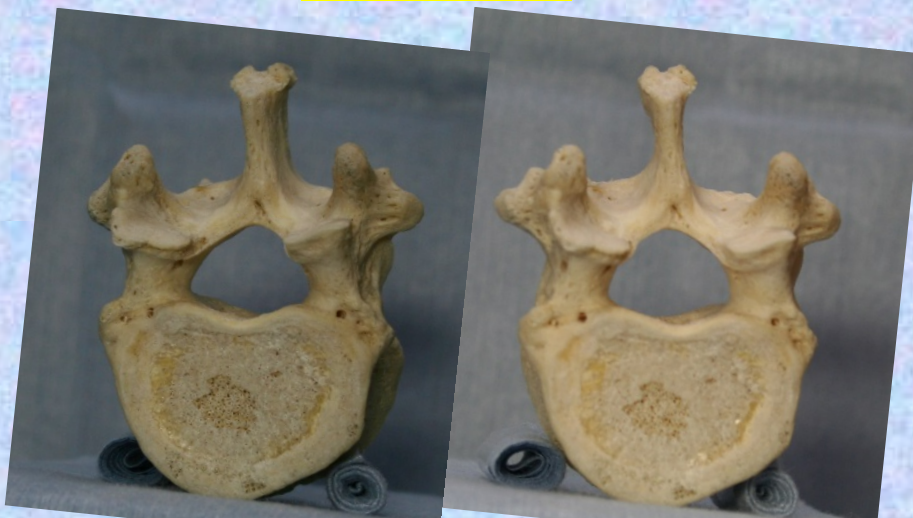
- ①下関節面(下関節突起関節面) inferior articular surface
- ②椎体 transverse process
- ③横突起 transverse process
- ④椎弓板 lamina
- ⑤下関節突起 inferior articular process
- ⑥棘突起 spinous process

- ⑦上関節突起 superior articular process
- ⑧椎孔 vertebral foramen
- ⑨椎弓根 pedicle
- ⑩上肋骨窩 superior costal facet
- ⑪横突肋骨窩 costal facet of transverse process
- ⑫下肋骨窩 inferior costal facet



胸椎 Th 12 上面

Th12



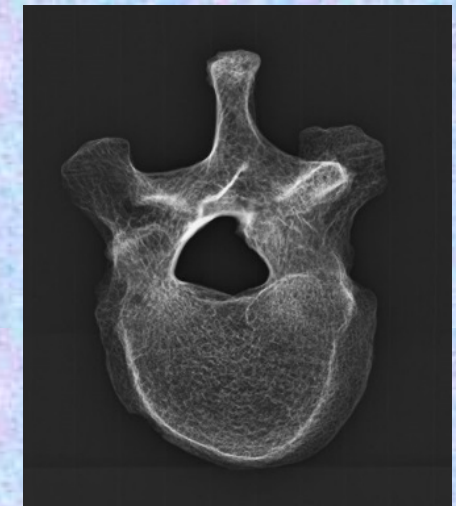
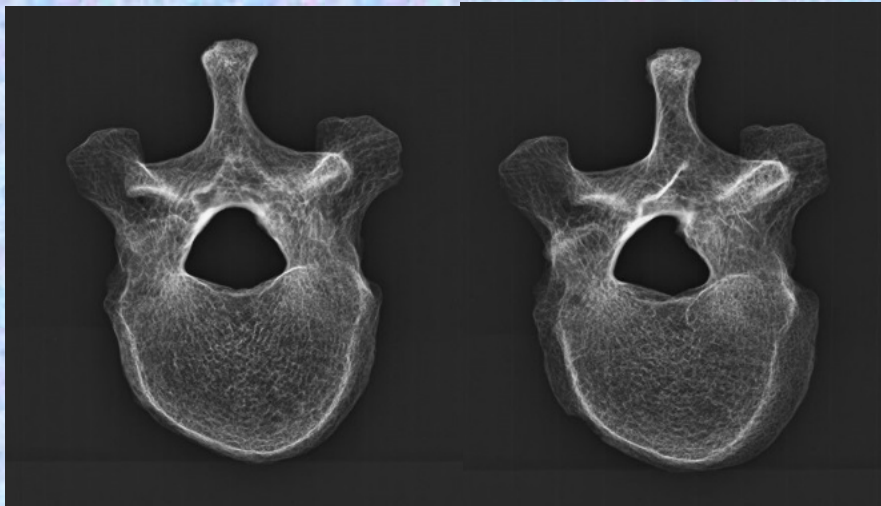
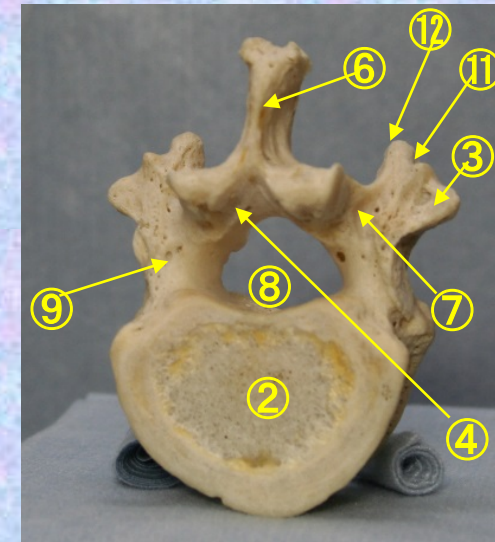
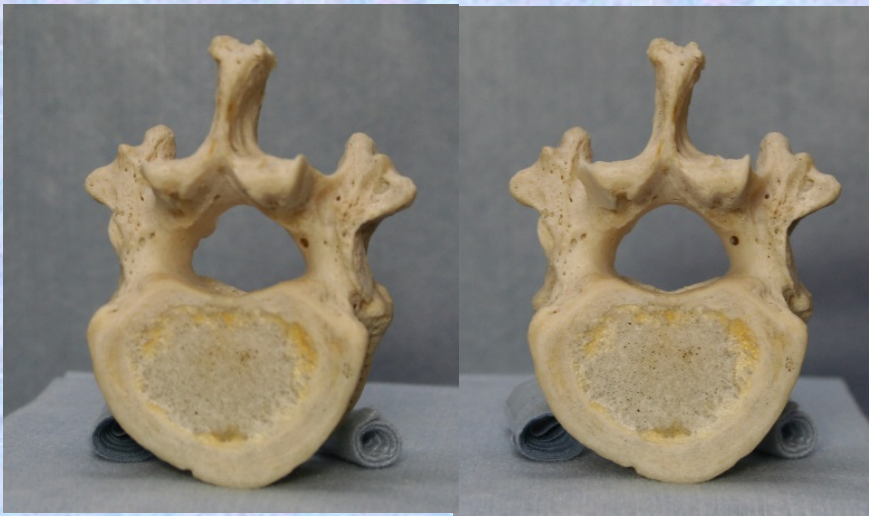
- ①下関節面(下関節突起関節面) inferior articular surface
- ②椎体 transverse process
- ③横突起 transverse process
- ④椎弓板 lamina
- ⑤下関節突起 inferior articular process
- ⑥棘突起 spinous process

- ⑦上関節突起 superior articular process
- ⑧椎孔 vertebral foramen
- ⑨椎弓根 pedicle
- ⑩上肋骨窩 superior costal facet
- ⑪横突肋骨窩 costal facet of transverse process
- ⑫下肋骨窩 inferior costal facet



Th12

胸椎 Th 12 下面



- ① 下関節面(下関節突起関節面) inferior articular surface
- ② 椎体 transverse process
- ③ 横突起 transverse process
- ④ 椎弓板 lamina
- ⑤ 下関節突起 inferior articular process
- ⑥ 棘突起 spinous process

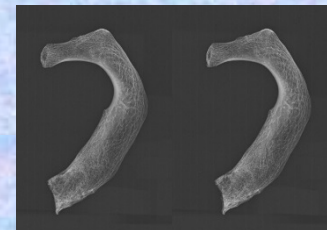
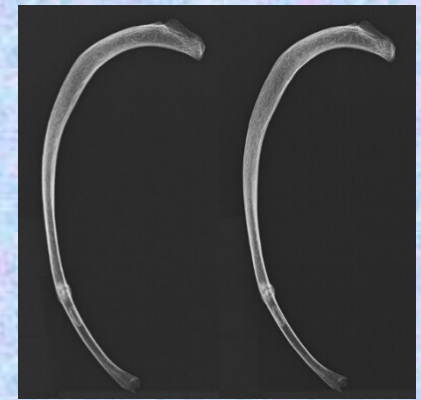
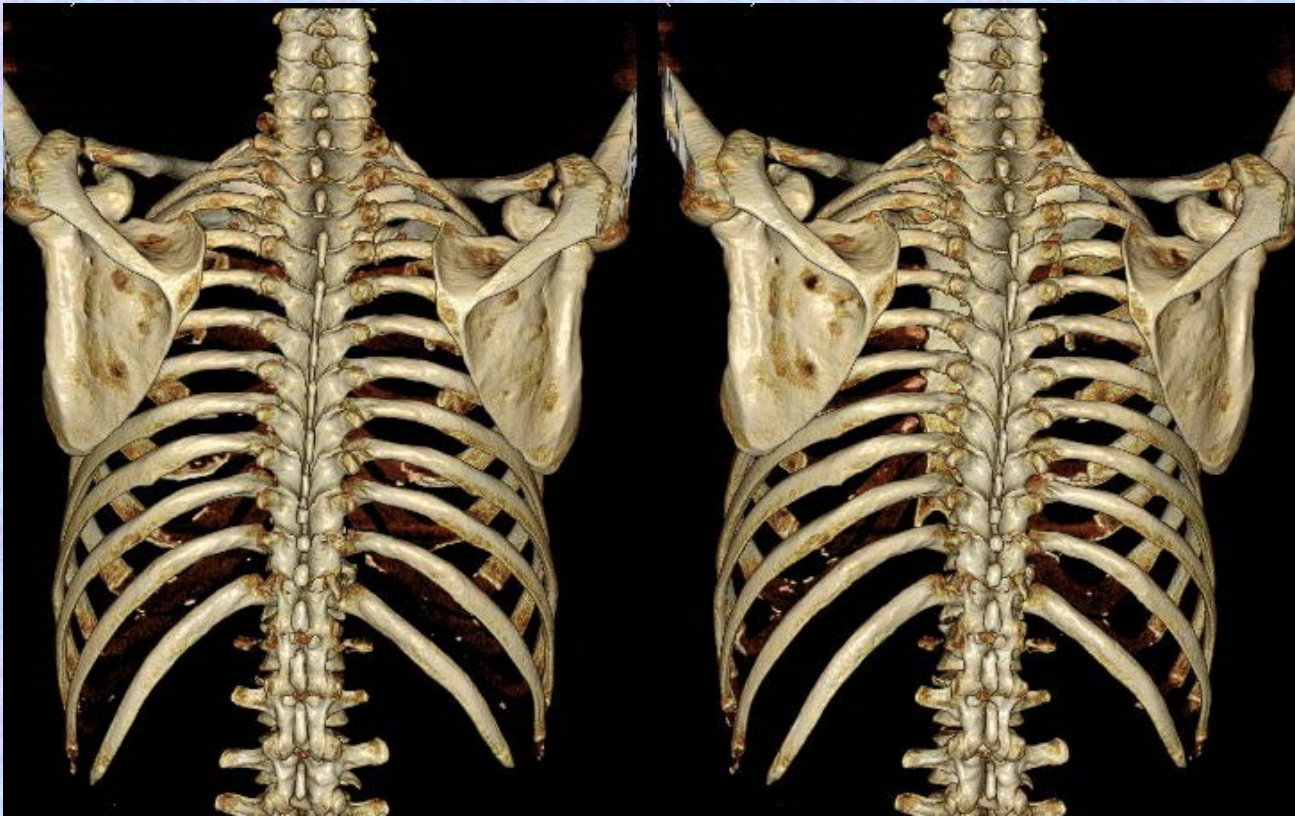
- ⑦ 上関節突起 superior articular process
- ⑧ 椎孔 vertebral foramen
- ⑨ 椎弓根 pedicle
- ⑩ 上肋骨窩 superior costal facet
- ⑪ 横突肋骨窩 costal facet of transverse process
- ⑫ 下肋骨窩 inferior costal facet



骨標本 X線ステレオ解剖図

肋骨

肋骨



監修 香川大学医学部 組織細胞生物学 教授 荒木 伸一
 作成 香川大学医学部附属病院 放射線部 勢川 博雄 2014.9

肋骨

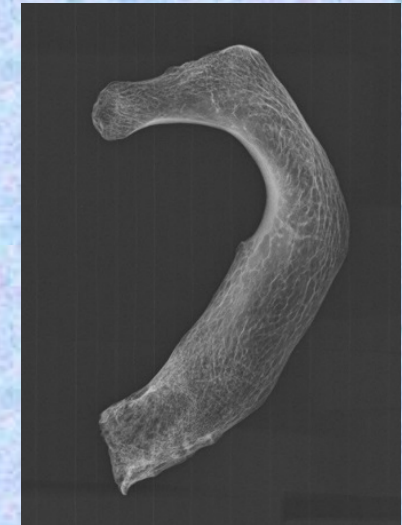
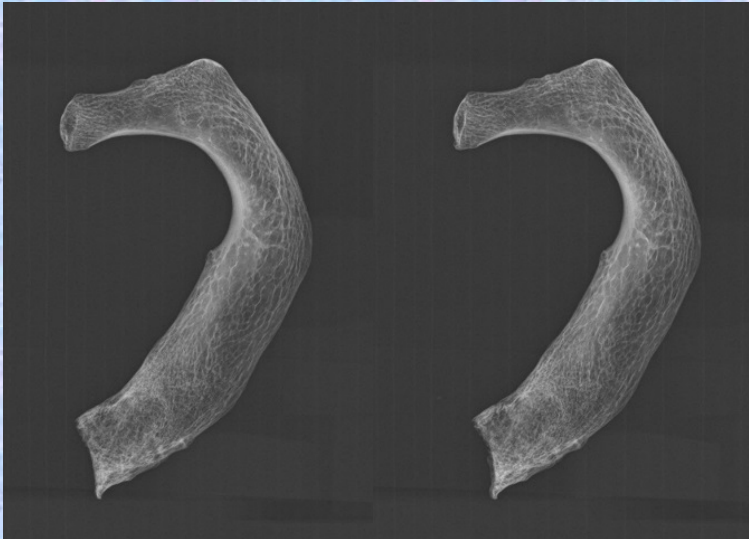
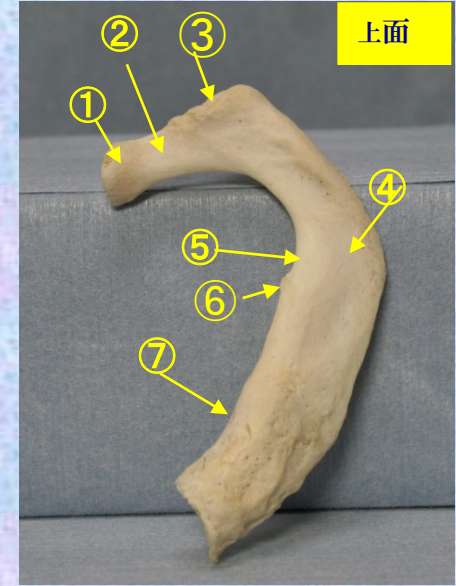
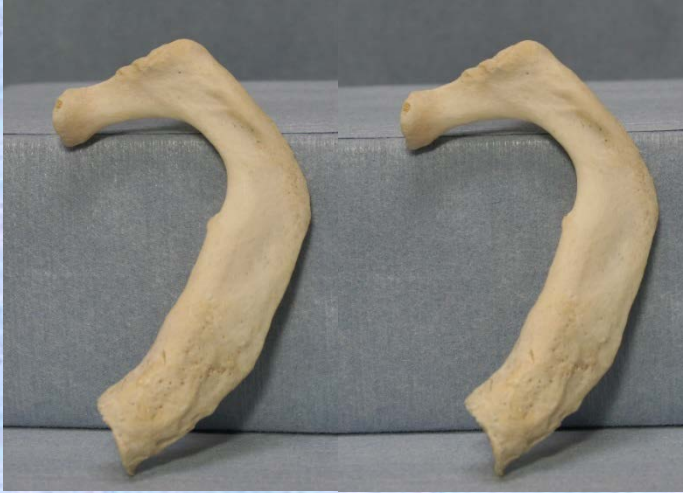Rib

第1肋骨

Rib 1

第一肋骨 R1 前面

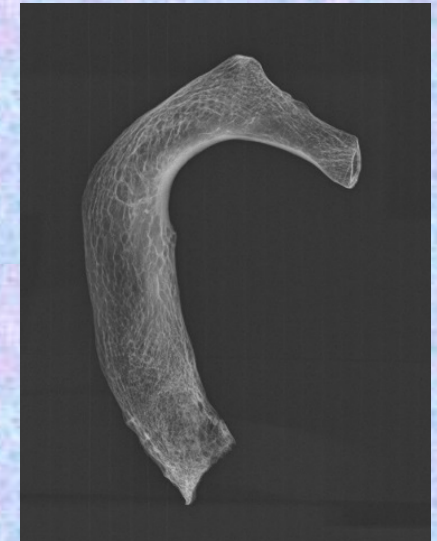
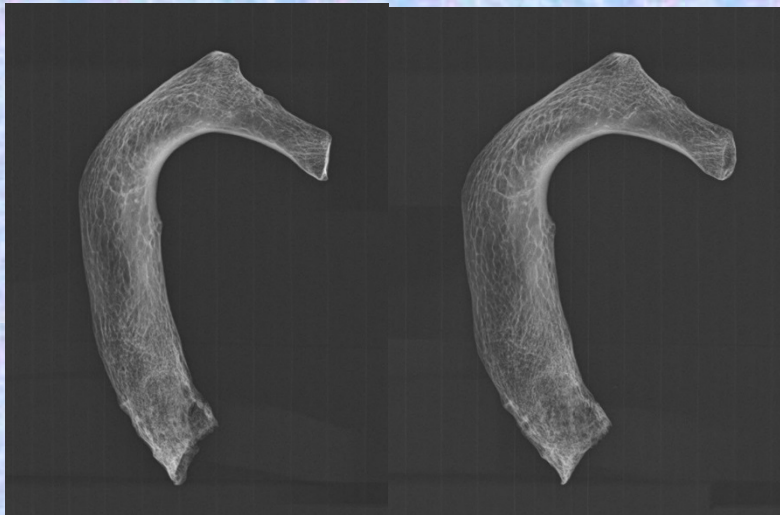
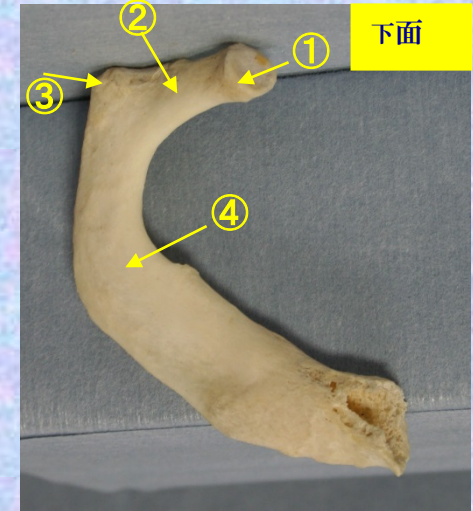
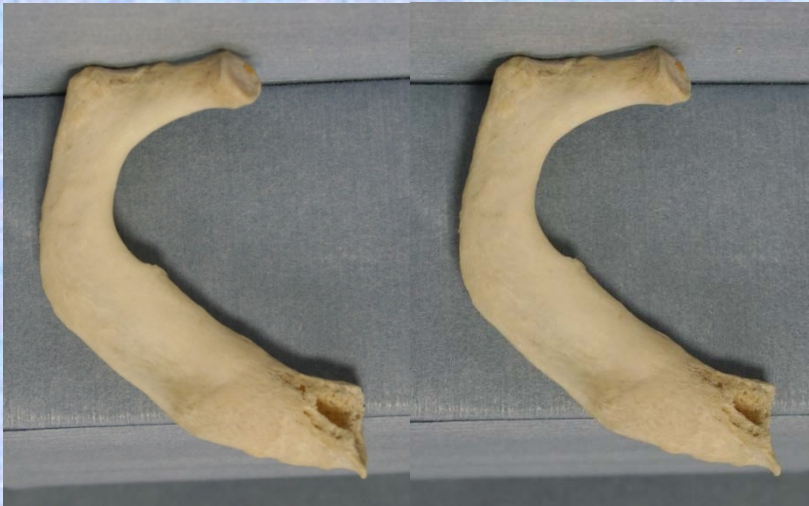前面 (Rib 1 anterior surface)



- | | | | |
|--------|-----------------|----------|------------------------------|
| ① 肋骨頭 | head of rib | ⑤ 肋骨体 | shaft of rib |
| ② 肋骨頸 | neck of rib | ⑥ 鎖骨下動脈溝 | groove for subclavian artery |
| ③ 肋骨結節 | tubercle of rib | ⑦ 前斜角筋結節 | scalene tubercle |
| ④ 肋骨体 | shaft of rib | ⑧ 鎖骨下靜脈溝 | groove for subclavian vein |

第一肋骨 R1 後面

後面 (Rib 1 posterior surface)

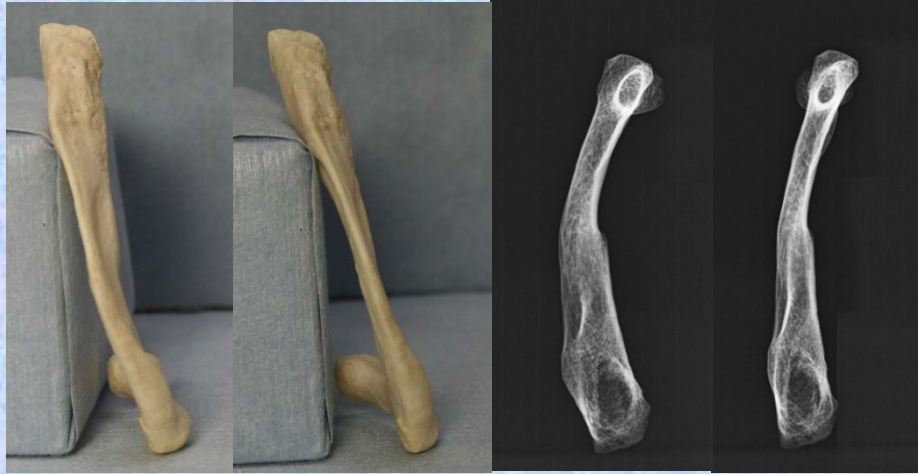

- ① 肋骨頭 head of rib
- ② 肋骨頸 neck of rib
- ③ 肋骨結節 tubercle of rib
- ④ 肋骨体 shaft of rib

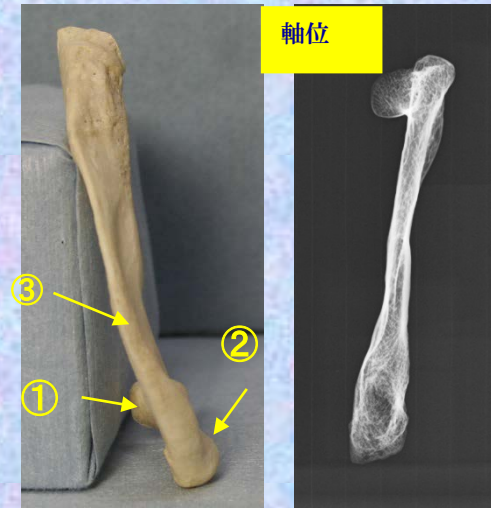- ⑤ 肋骨体 shaft of rib
- ⑥ 鎖骨下動脈溝 groove for subclavian artery
- ⑦ 前斜角筋結節 scalene tubercle
- ⑧ 鎖骨下靜脈溝 groove for subclavian vein

第一肋骨 R1 軸面

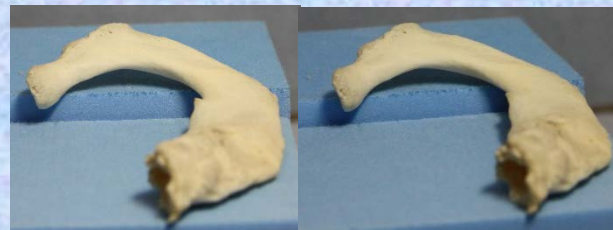
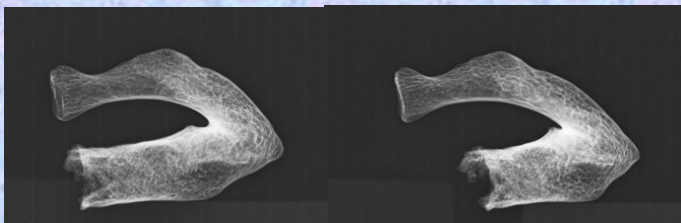
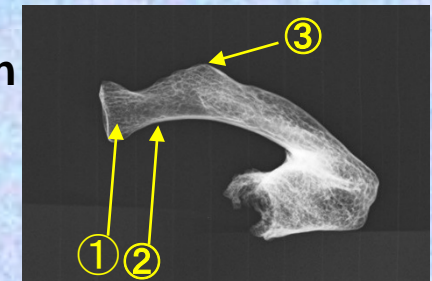
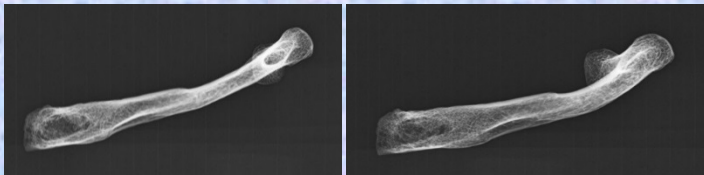
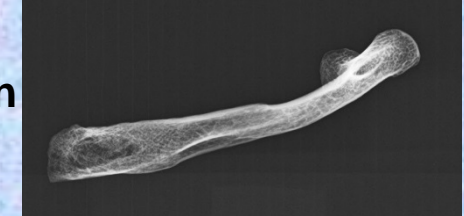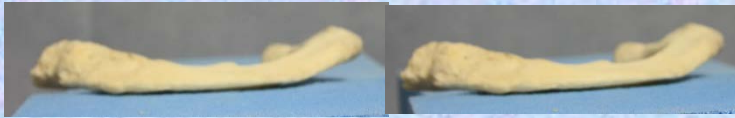軸面 (Rib 1 Axial surface)



- ① 肋骨頭
head of rib
- ② 肋骨頸
neck of rib
- ③ 肋骨結節
tubercle of rib
- ④ 肋骨體
shaft of rib



- ⑤ 肋骨體
shaft of rib
- ⑥ 鎖骨下動脈溝
groove for subclavian
- ⑦ 前斜角筋結節
scalene tubercle
- ⑧ 鎖骨下靜脈溝
groove for subclavian

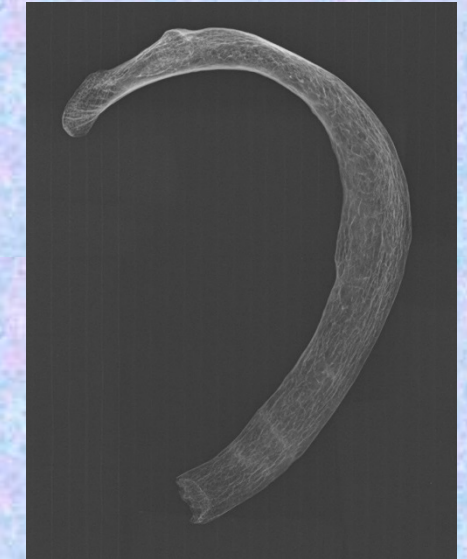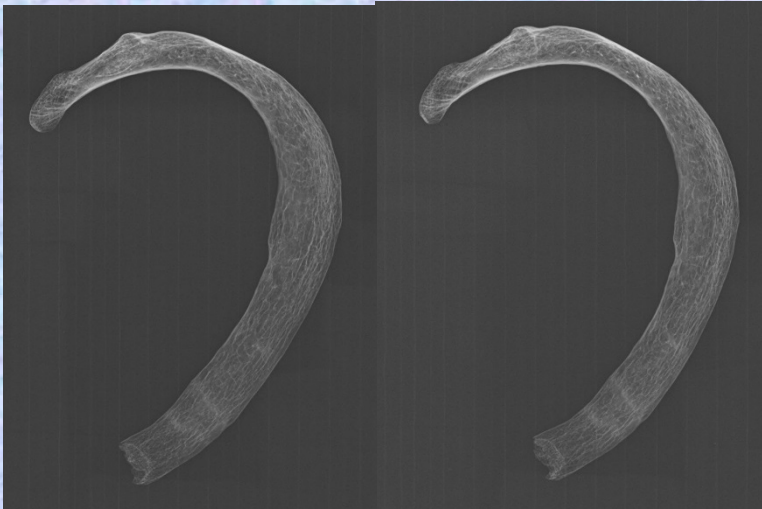
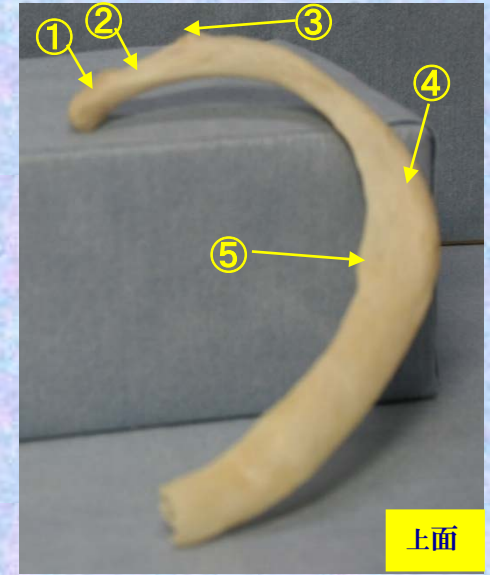


第2肋骨

Rib 2

第二肋骨 R2 前面

前面 (Rib 2 anterior surface)




- ① 肋骨頭 head of rib
- ② 肋骨頸 neck of rib
- ③ 肋骨結節 tubercle of rib

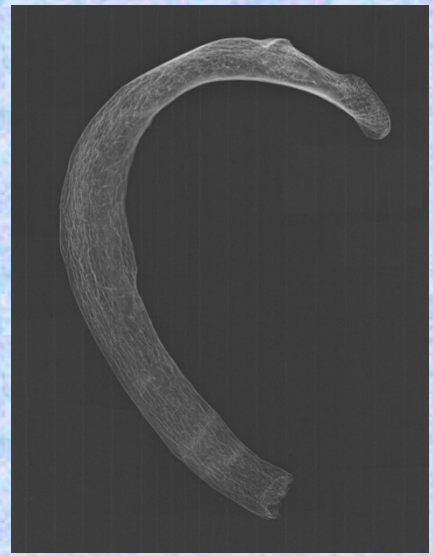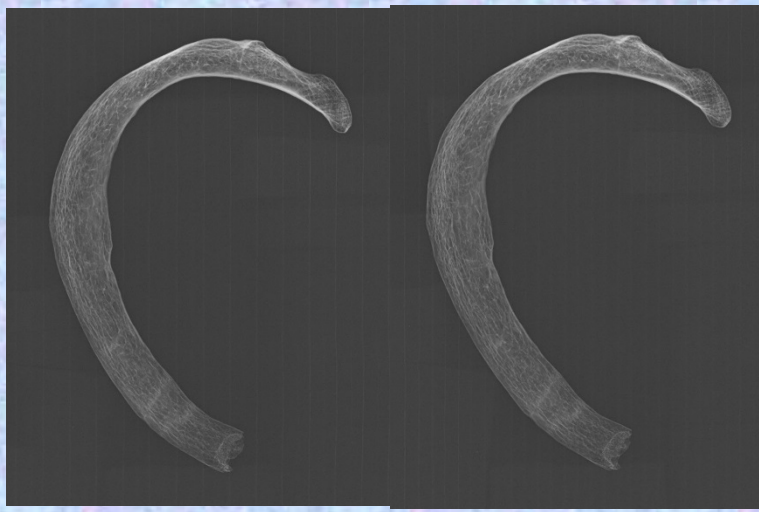
- ④ 肋骨体 shaft of rib
- ⑤ 前斜角筋結節 scalene tubercle
- ⑥ 肋骨溝 costal groove

第二肋骨 R2 後面

後面 (Rib 2 posterior surface)



下面




- ① 肋骨頭 head of rib
- ② 肋骨頸 neck of rib
- ③ 肋骨結節 tubercle of rib

- ④ 肋骨體 shaft of rib
- ⑤ 前斜角筋結節 scalene tubercle
- ⑥ 肋骨溝 costal groove

第二肋骨 R2 軸面

軸面 (Rib 2 Axial surface)



① 肋骨頭

Head of rib

② 肋骨頸

neck of rib

③ 肋骨結節

tubercle of rib

④ 肋骨體

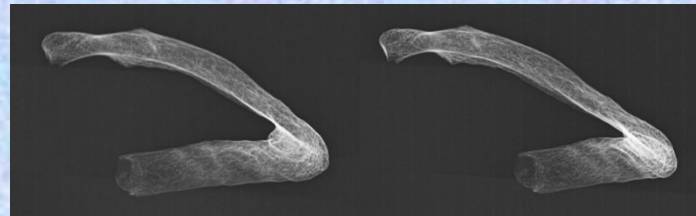
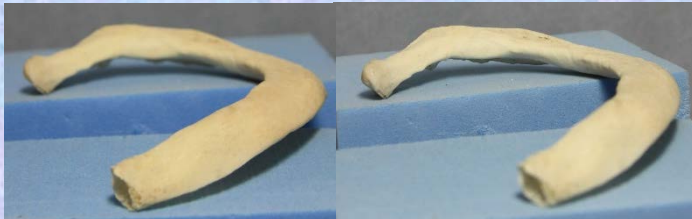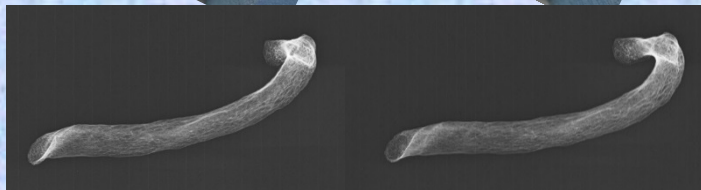
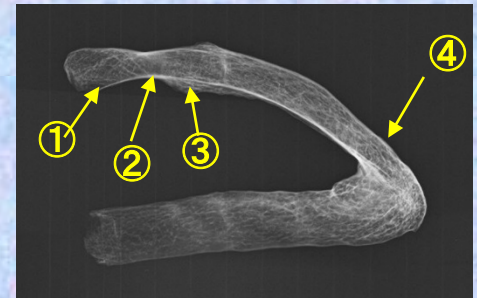

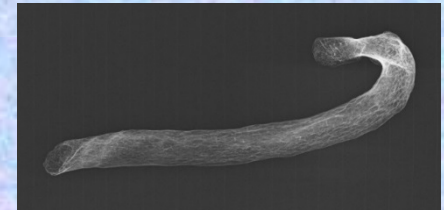
shaft of rib

⑤ 前斜角筋結節

scalene tubercle

⑥ 肋骨溝

costal groove

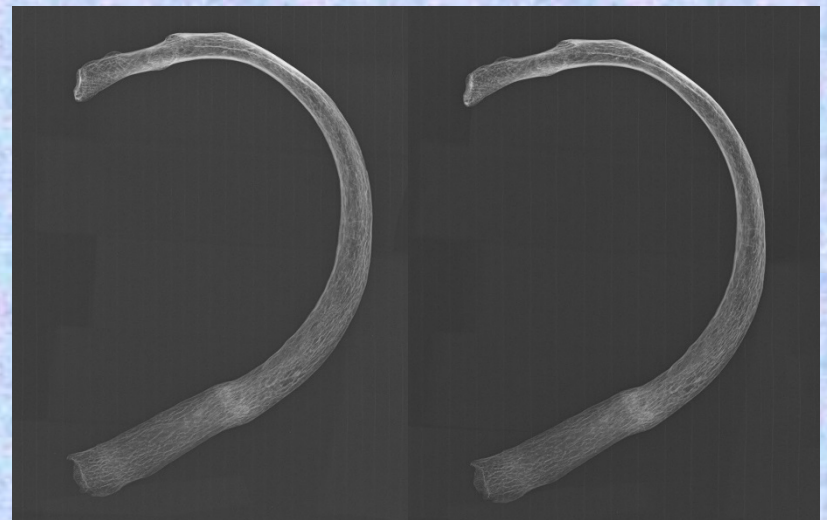



第3肋骨

Rib 3

第三肋骨 R3 前面

前面 (Rib 3 anterior surface)




- ① 肋骨頭 head of rib
- ② 肋骨頸 neck of rib
- ③ 肋骨結節 tubercle of rib

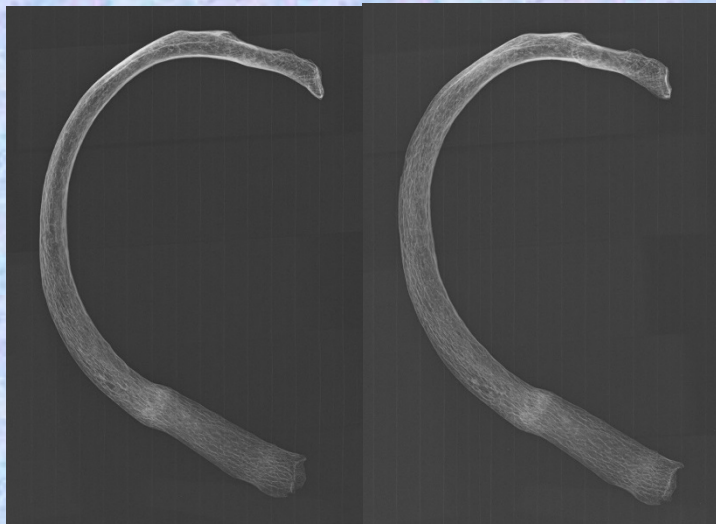
- ④ 肋骨體 shaft of rib
- ⑤ 前斜角筋結節 scalene tubercle
- ⑥ 肋骨溝 costal groove

第三肋骨 R3 後面

後面 (Rib 3 posterior surface)



下面

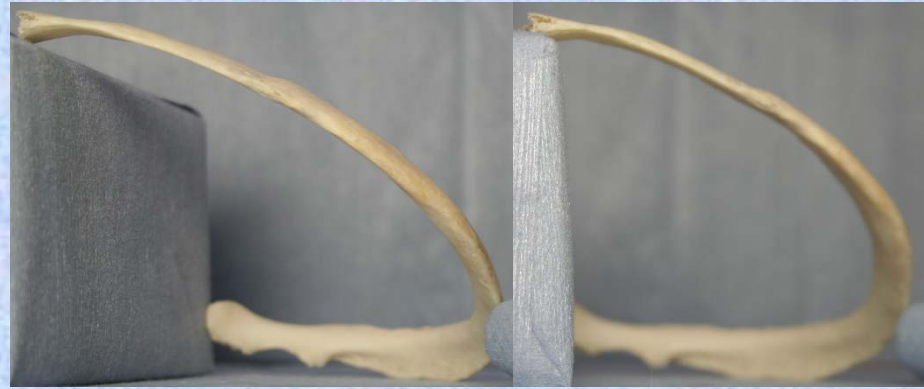

- ① 肋骨頭 head of rib
- ② 肋骨頸 neck of rib
- ③ 肋骨結節 tubercle of rib


- ④ 肋骨體 shaft of rib
- ⑤ 前斜角筋結節 scalene tubercle
- ⑥ 肋骨溝 costal groove

第三肋骨 R3 軸面

軸面 (Rib 3 Axial surface)



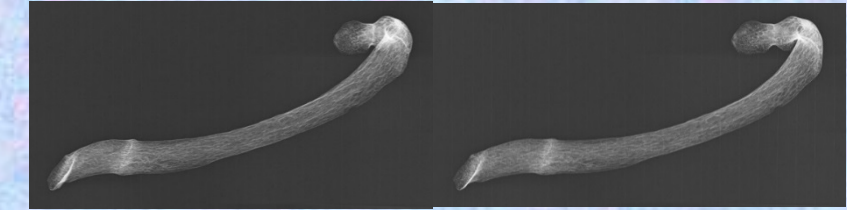
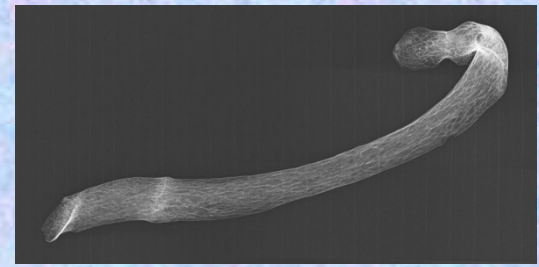
- ① 肋骨頭
Head of rib
- ② 肋骨頸
neck of rib
- ③ 肋骨結節
tubercle of rib



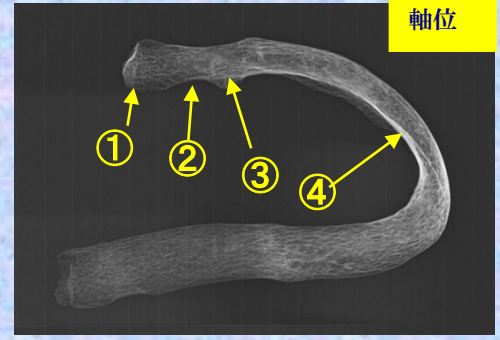
軸位



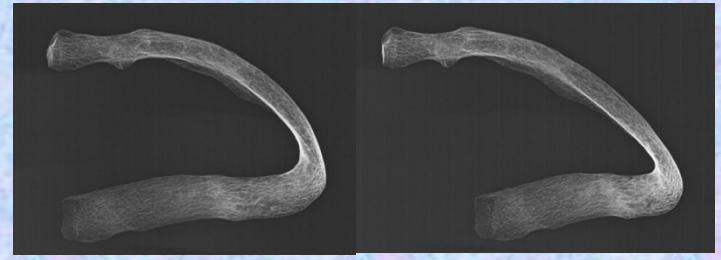
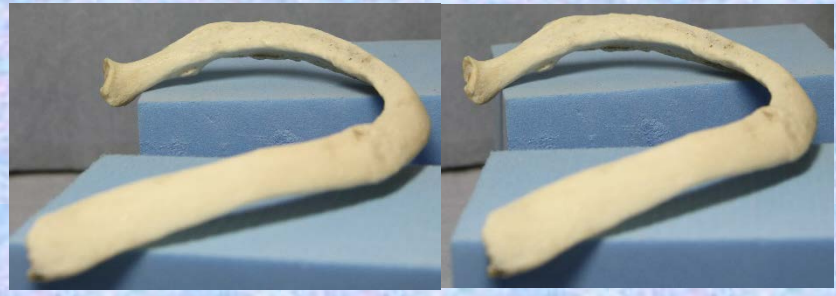- ④ 肋骨體
shaft of rib
- ⑤ 前斜角筋結節
scalene tubercle



- ⑥ 肋骨溝
costal groove



軸位

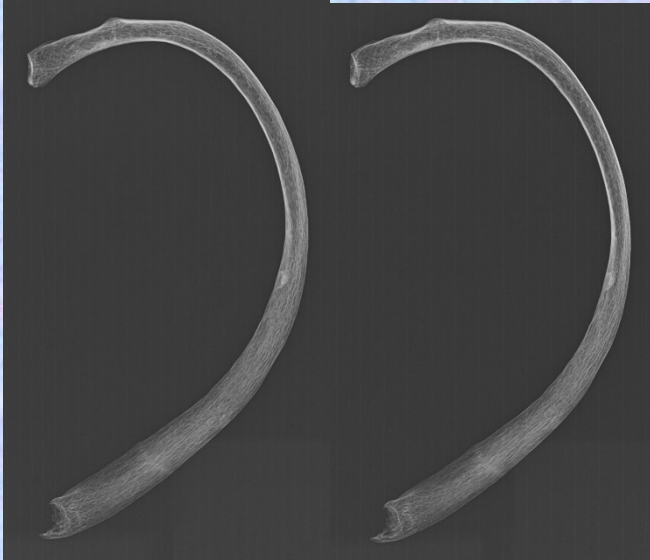


第4肋骨

Rib 4

第四肋骨 R4 前面

前面 (Rib 4 anterior surface)



① 肋骨頭 head of rib

② 肋骨頸 neck of rib

③ 肋骨結節 tubercle of rib


④ 肋骨體 shaft of rib

⑤ 前斜角筋結節 scalene tubercle

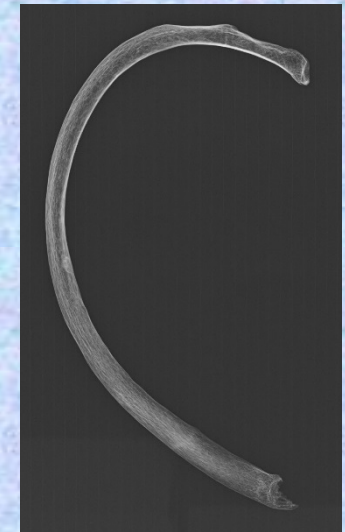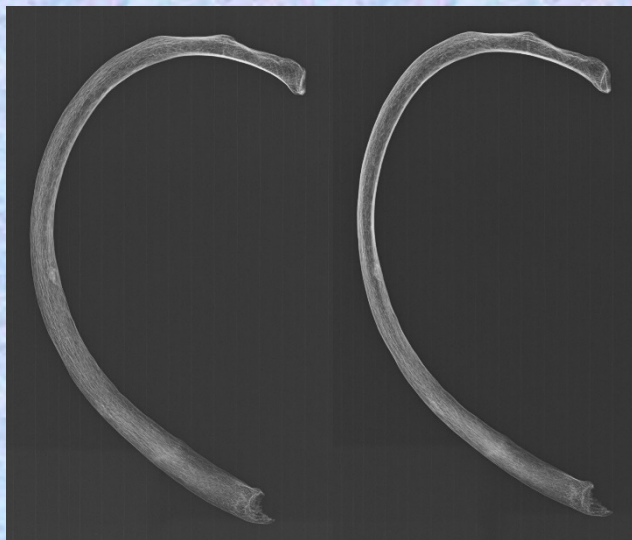⑥ 肋骨溝 costal groove

第四肋骨 R4 後面

後面 (Rib 4 posterior surface)



下面



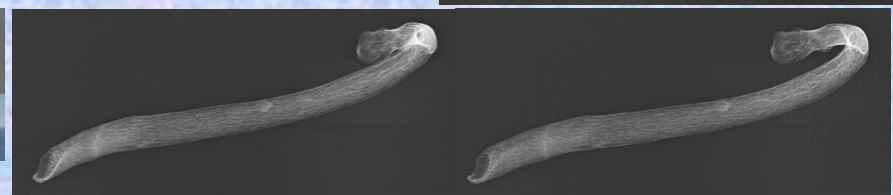
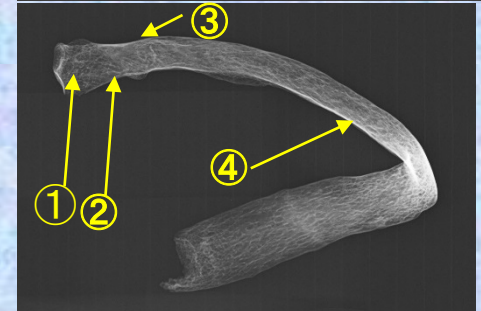
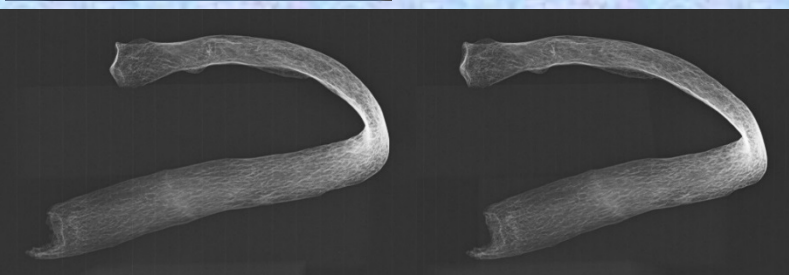


- | | | | |
|--------|-----------------|----------|------------------|
| ① 肋骨頭 | head of rib | ④ 肋骨体 | shaft of rib |
| ② 肋骨頸 | neck of rib | ⑤ 前斜角筋結節 | scalene tubercle |
| ③ 肋骨結節 | tubercle of rib | ⑥ 肋骨溝 | costal groove |

第四肋骨 R4 軸面

軸面 (Rib 4 Axial surface)



- ① 肋骨頭
Head of rib
- ② 肋骨頸
neck of rib
- ③ 肋骨結節
tubercle of rib
- ④ 肋骨體
shaft of rib
- ⑤ 前斜角筋結節
scalene tubercle
- ⑥ 肋骨溝
costal groove





第5肋骨

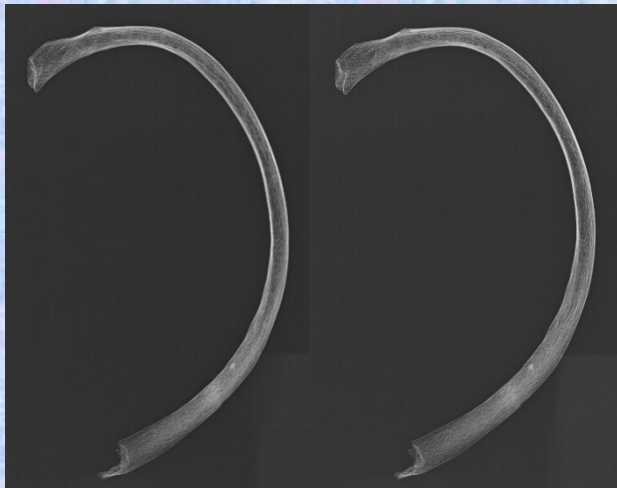Rib 5

第五肋骨 R5 前面

前面 (Rib 5 anterior surface)



上面




- ① 肋骨頭 head of rib
- ② 肋骨頸 neck of rib
- ③ 肋骨結節 tubercle of rib

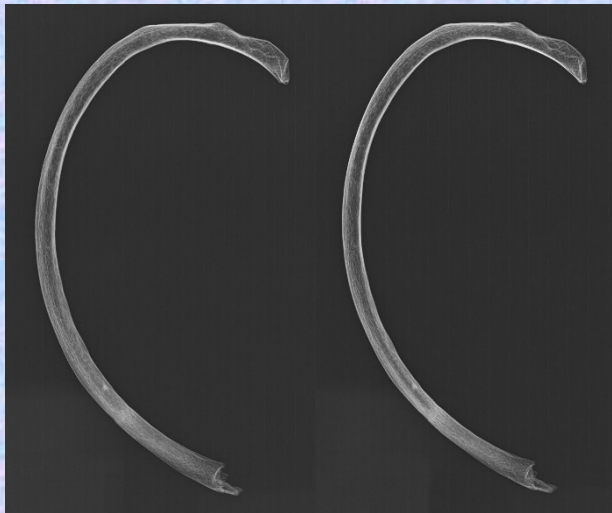
- ④ 肋骨體 shaft of rib
- ⑤ 前斜角筋結節 scalene tubercle
- ⑥ 肋骨溝 costal groove

第五肋骨 R5 後面

後面 (Rib 5 posterior surface)



下面



- ① 肋骨頭 head of rib
- ② 肋骨頸 neck of rib
- ③ 肋骨結節 tubercle of rib

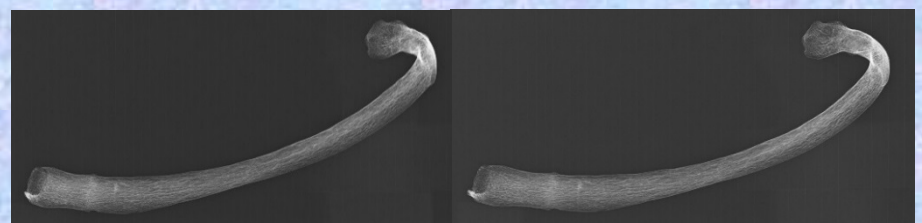
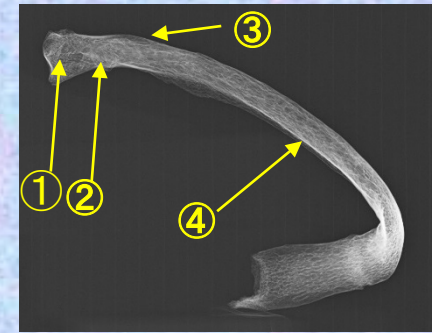
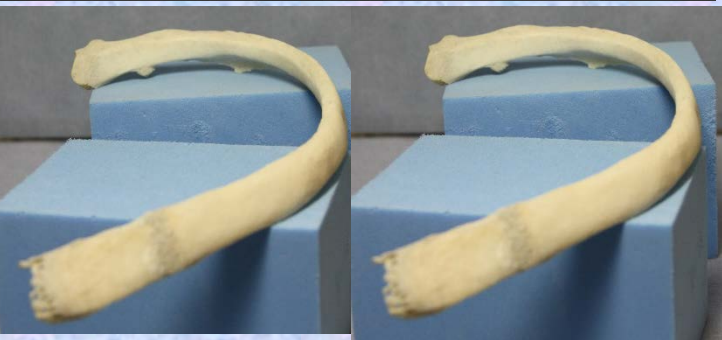
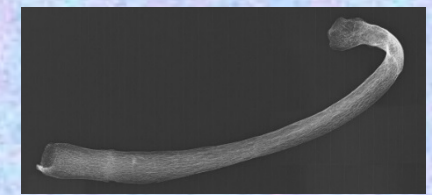
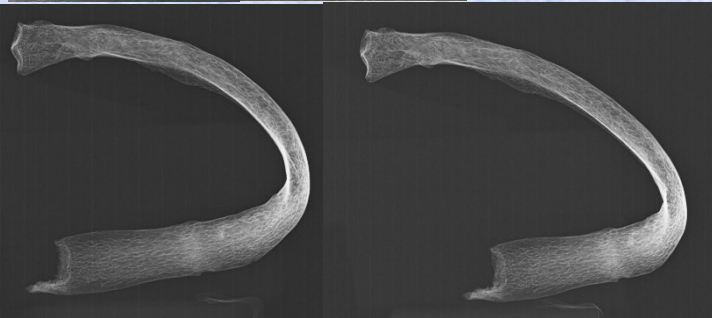

- ④ 肋骨体 shaft of rib
- ⑤ 前斜角筋結節 scalene tubercle
- ⑥ 肋骨溝 costal groove

第五肋骨 R 5軸面

軸面 (Rib 5 Axial surface)



- ① 肋骨頭
Head of rib
- ② 肋骨頸
neck of rib
- ③ 肋骨結節
tubercle of rib
- ④ 肋骨體
shaft of rib
- ⑤ 前斜角筋結節
scalene tubercle
- ⑥ 肋骨溝
costal groove

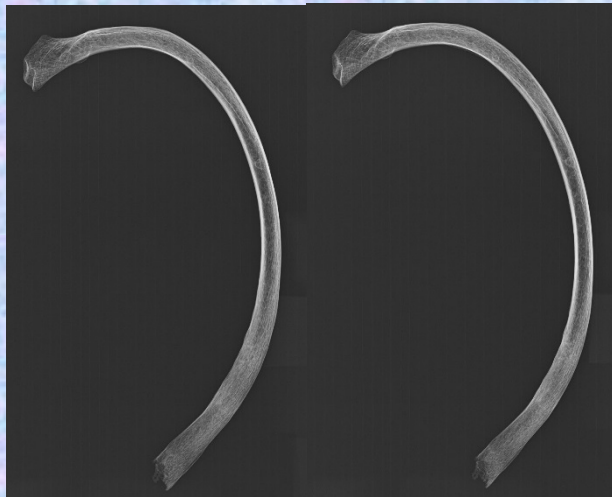


第6肋骨

Rib 6

第六肋骨 R6 前面

前面 (Rib 6 anterior surface)

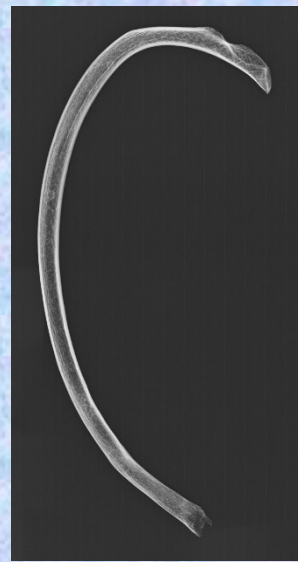
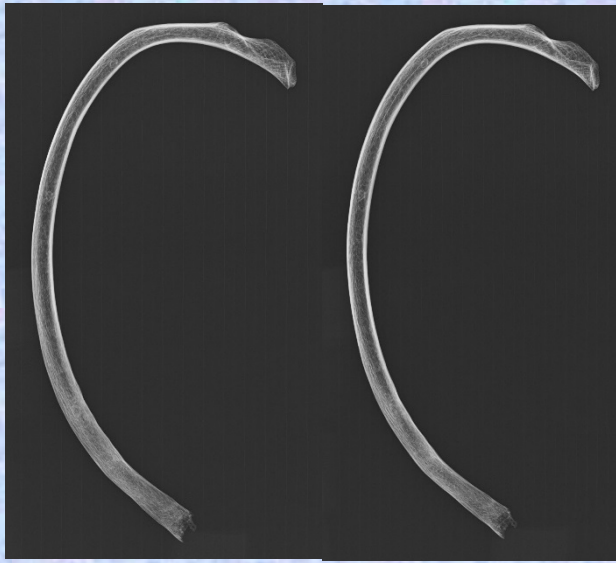



- ① 肋骨頭 head of rib
- ② 肋骨頸 neck of rib
- ③ 肋骨結節 tubercle of rib

- ④ 肋骨體 shaft of rib
- ⑤ 前斜角筋結節 scalene tubercle
- ⑥ 肋骨溝 costal groove

第六肋骨 R6 後面

後面 (Rib 6 posterior surface)




- ① 肋骨頭 head of rib
- ② 肋骨頸 neck of rib
- ③ 肋骨結節 tubercle of rib

- ④ 肋骨體 shaft of rib
- ⑤ 前斜角筋結節 scalene tubercle
- ⑥ 肋骨溝 costal groove

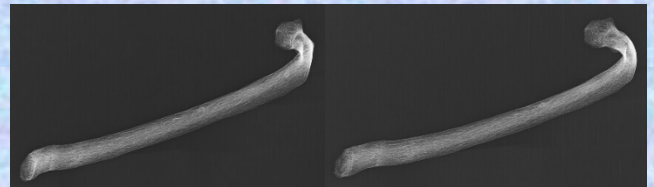
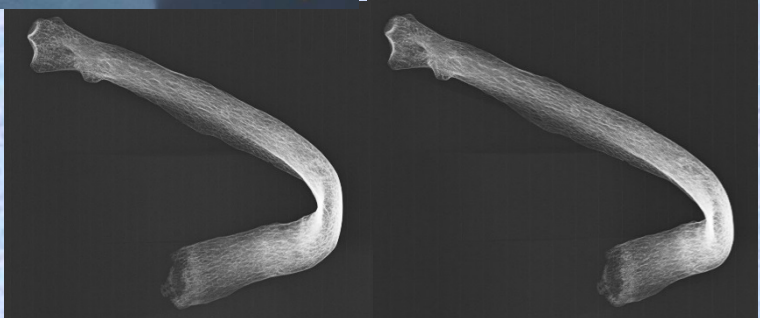
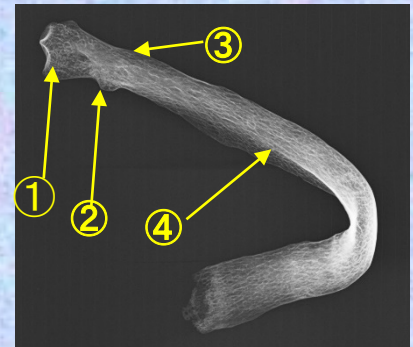
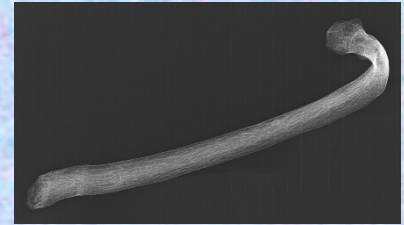
第六肋骨 R6 軸面

軸面 (Rib 6 Axial surface)



- ① 肋骨頭
Head of rib
- ② 肋骨頸
neck of rib
- ③ 肋骨結節
tubercle of rib

- ④ 肋骨體
shaft of rib
- ⑤ 前斜角筋結節
scalene tubercle
- ⑥ 肋骨溝
costal groove

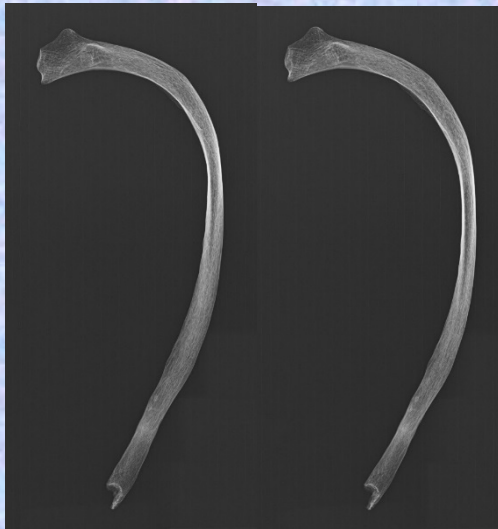


第7肋骨

Rib 7

第七肋骨 R7 前面

前面 (Rib 7 anterior surface)

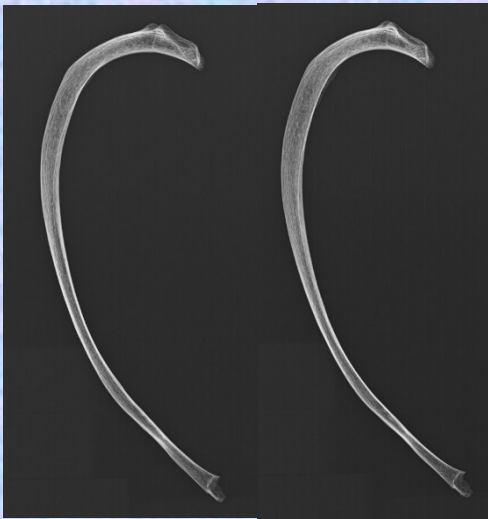



- ① 肋骨頭 head of rib
- ② 肋骨頸 neck of rib
- ③ 肋骨結節 tubercle of rib

- ④ 肋骨体 shaft of rib
- ⑤ 前斜角筋結節 scalene tubercle
- ⑥ 肋骨溝 costal groove

第七肋骨 R7 後面

後面 (Rib 7 posterior surface)




- ① 肋骨頭 head of rib
- ② 肋骨頸 neck of rib
- ③ 肋骨結節 tubercle of rib


- ④ 肋骨體 shaft of rib
- ⑤ 前斜角筋結節 scalene tubercle
- ⑥ 肋骨溝 costal groove

第七肋骨 R7 軸面

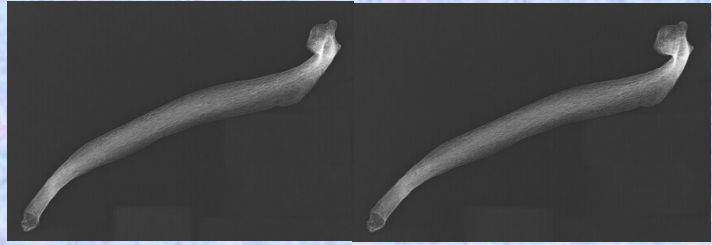

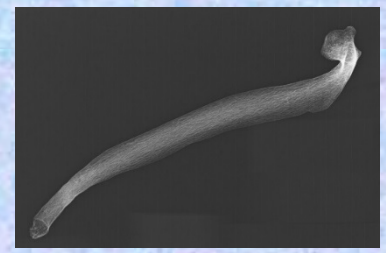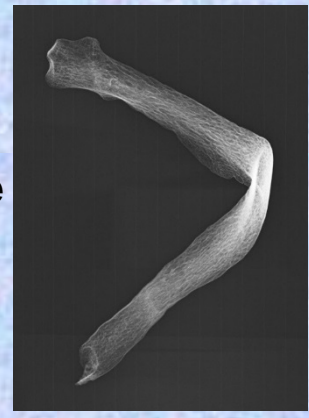

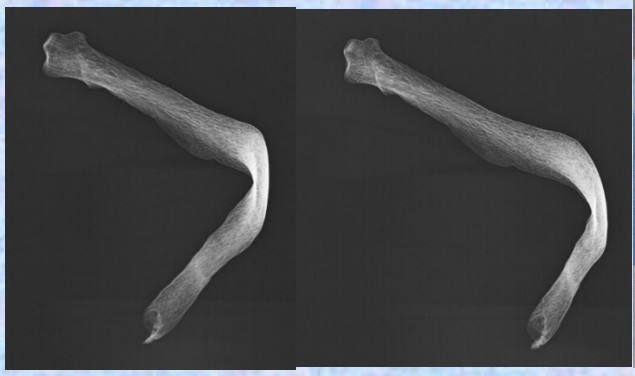
軸面 (Rib 7 Axial surface)



- ① 肋骨頭
Head of rib
- ② 肋骨頸
neck of rib
- ③ 肋骨結節
tubercle of rib



- ④ 肋骨體
shaft of rib
- ⑤ 前斜角筋結節
scalene tubercle
- ⑥ 肋骨溝
costal groove

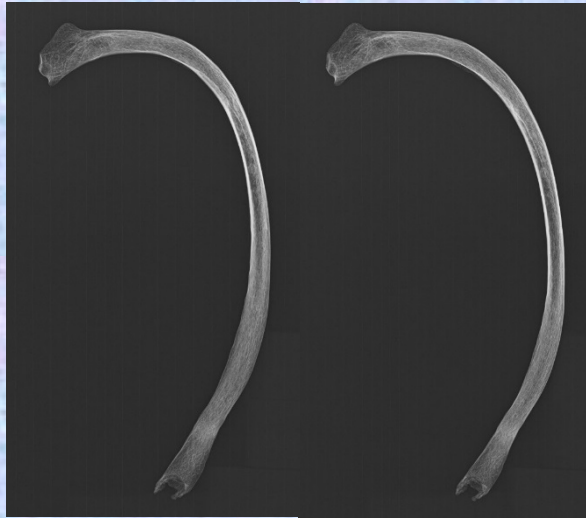


第8肋骨

Rib 8

第八肋骨 R8 前面

前面 (Rib 8 anterior surface)

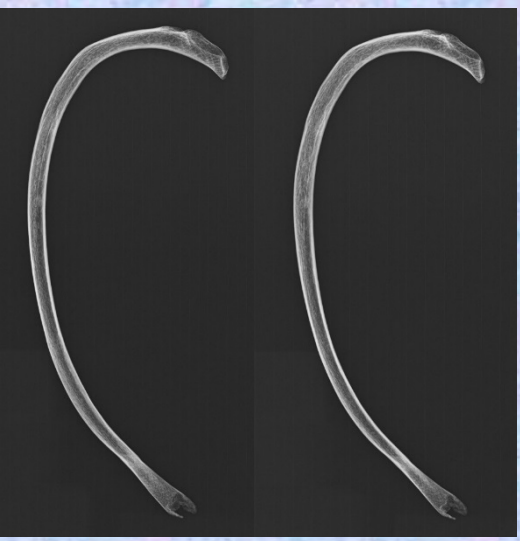



- ① 肋骨頭 head of rib
- ② 肋骨頸 neck of rib
- ③ 肋骨結節 tubercle of rib

- ④ 肋骨體 shaft of rib
- ⑤ 前斜角筋結節 scalene tubercle
- ⑥ 肋骨溝 costal groove

第八肋骨 R8 後面

後面 (Rib 8 posterior surface)



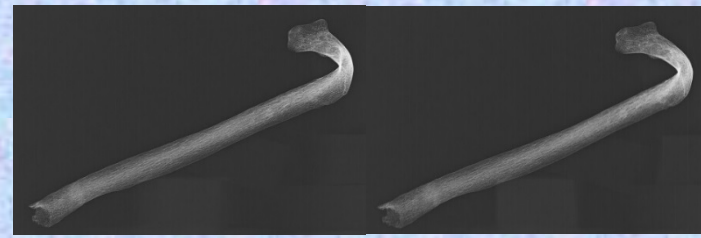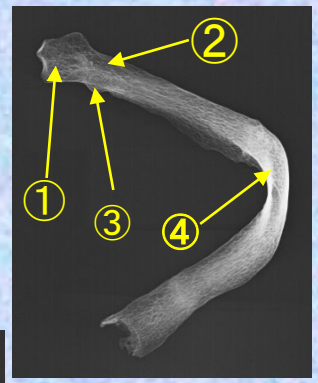


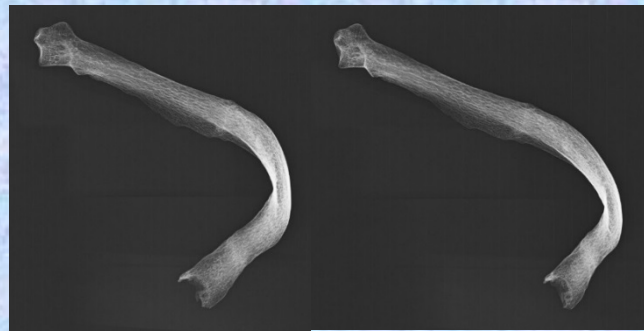

- ① 肋骨頭 head of rib
- ② 肋骨頸 neck of rib
- ③ 肋骨結節 tubercle of rib

- ④ 肋骨體 shaft of rib
- ⑤ 前斜角筋結節 scalene tubercle
- ⑥ 肋骨溝 costal groove

第八肋骨 R8 軸面

軸面 (Rib 8 Axial surface)

- ① 肋骨頭
Head of rib
- ② 肋骨頸
neck of rib
- ③ 肋骨結節
tubercle of rib
- ④ 肋骨體
shaft of rib

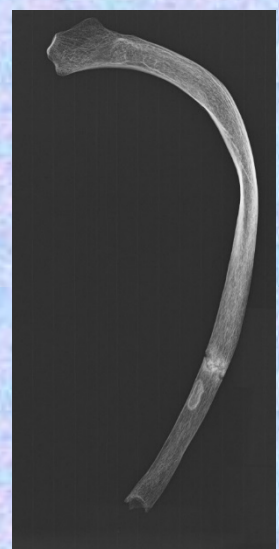
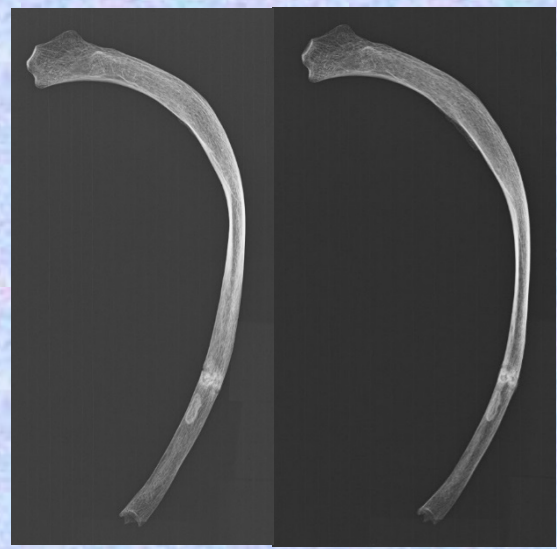



第9肋骨

Rib 9

第九肋骨 R9 前面

前面 (Rib 9 anterior surface)



① 肋骨頭 head of rib

② 肋骨頸 neck of rib

③ 肋骨結節 tubercle of rib

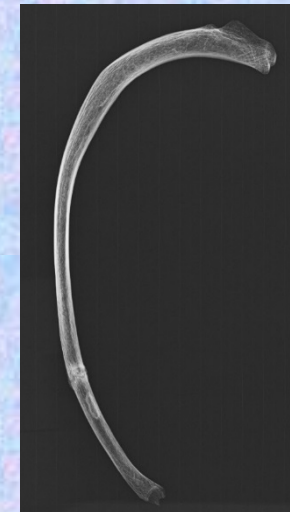
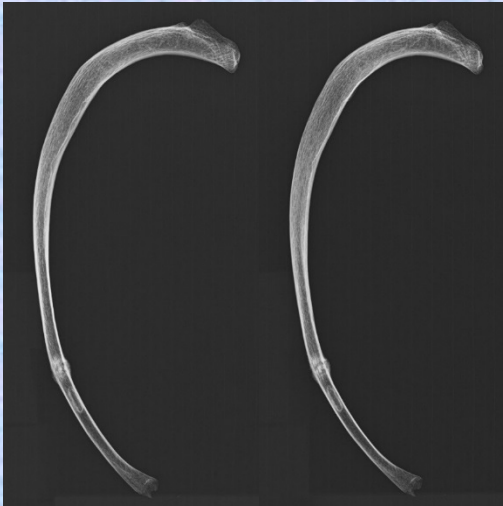

④ 肋骨体 shaft of rib

⑤ 前斜角筋結節 scalene tubercle

⑥ 肋骨溝 costal groove

第九肋骨 R9 後面

後面 (Rib 9 posterior surface)

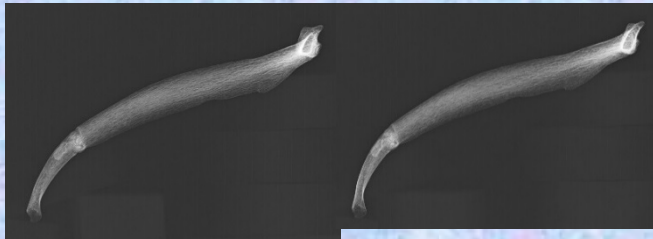

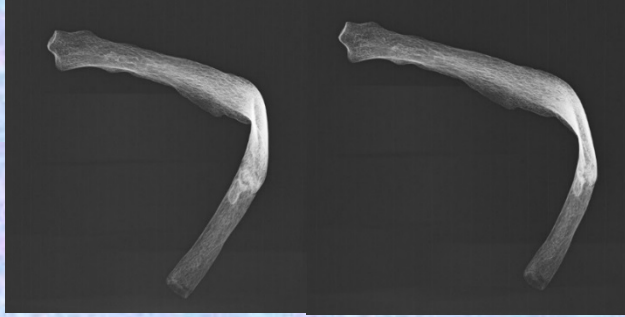



- ① 肋骨頭 head of rib
- ② 肋骨頸 neck of rib
- ③ 肋骨結節 tubercle of rib


- ④ 肋骨體 shaft of rib
- ⑤ 前斜角筋結節 scalene tubercle
- ⑥ 肋骨溝 costal groove

第9肋骨 R9 軸面

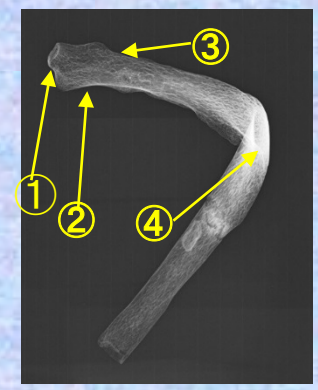
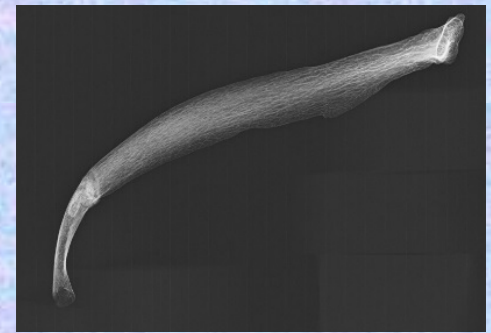
軸面 (Rib 9 Axial surface)



- ① 肋骨頭
Head of rib
- ② 肋骨頸
neck of rib
- ③ 肋骨結節
tubercle of rib



- ④ 肋骨體
shaft of rib
- ⑤ 前斜角筋結節
scalene tubercle
- ⑥ 肋骨溝
costal groove

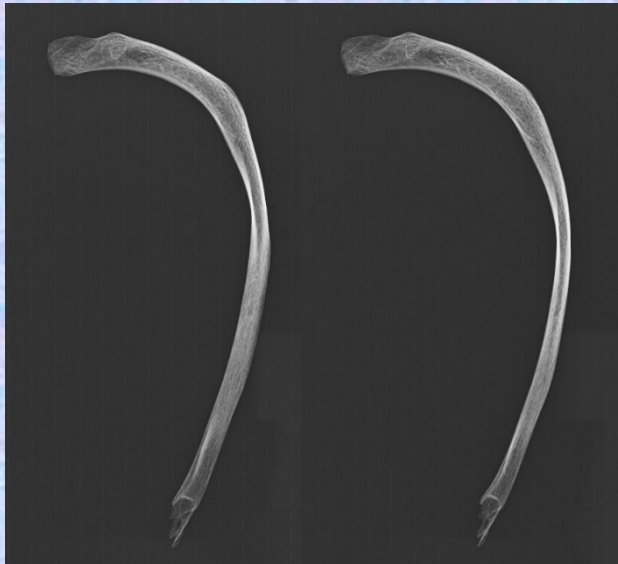


第10肋骨

Rib 10

第十肋骨 R10 前面

前面 (Rib 10 anterior surface)

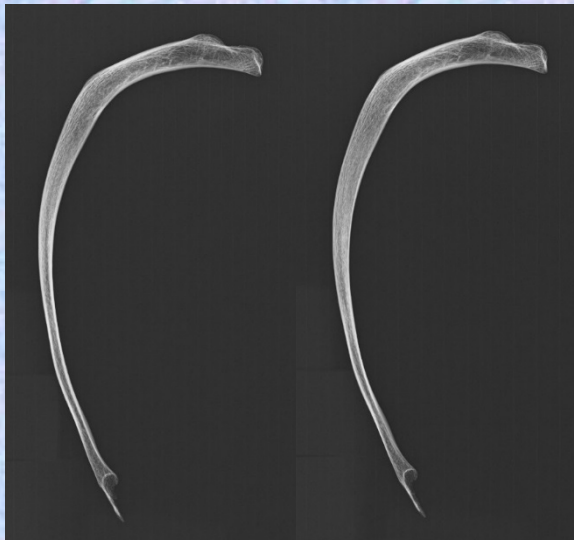



- ① 肋骨頭 head of rib
- ② 肋骨頸 neck of rib
- ③ 肋骨結節 tubercle of rib

- ④ 肋骨体 shaft of rib
- ⑤ 前斜角筋結節 scalene tubercle
- ⑥ 肋骨溝 costal groove

第十肋骨 R10 後面

後面 (Rib 10 posterior surface)



- ① 肋骨頭 head of rib
- ② 肋骨頸 neck of rib
- ③ 肋骨結節 tubercle of rib

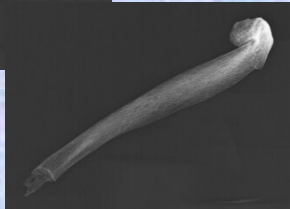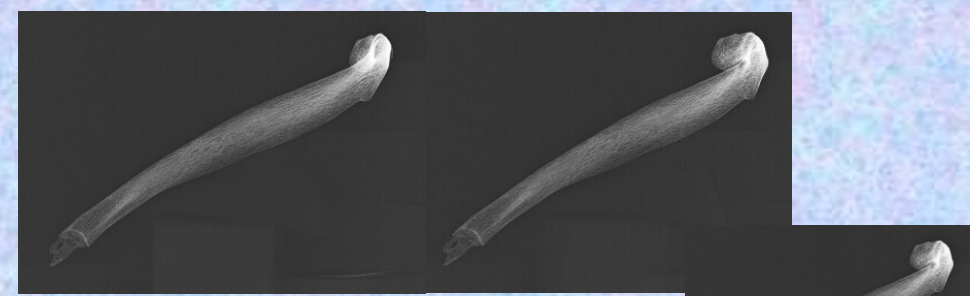
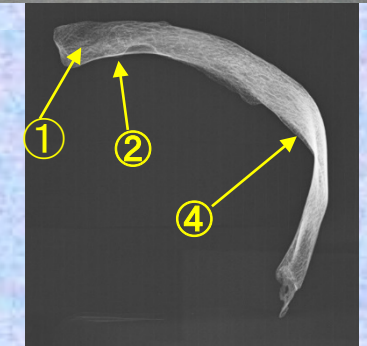
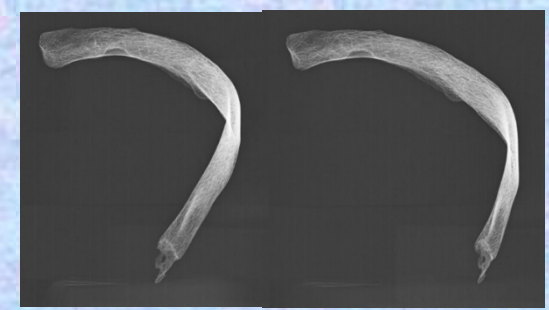

- ④ 肋骨体 shaft of rib
- ⑤ 前斜角筋結節 scalene tubercle
- ⑥ 肋骨溝 costal groove

第十肋骨 R10 軸面

軸面 (Rib 10 Axial surface)



- ① 肋骨頭
Head of rib
- ② 肋骨頸
neck of rib
- ③ 肋骨結節
tubercle of rib
- ④ 肋骨體
shaft of rib

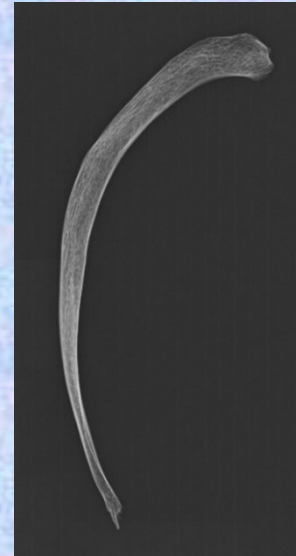
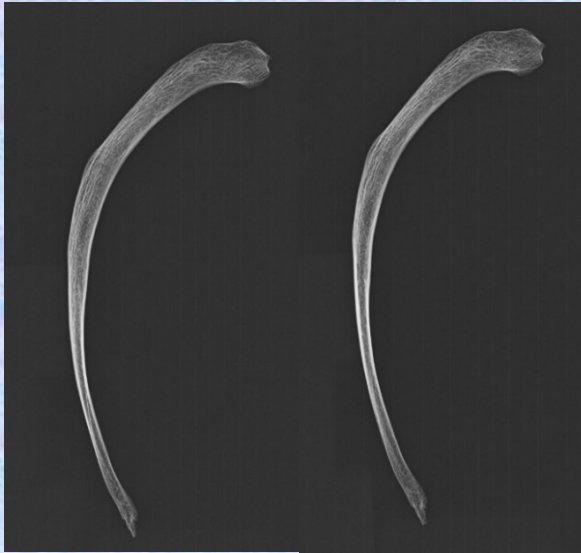



第11肋骨

Rib 11

第十一肋骨 R11 前面

前面 (Rib 11 anterior surface)

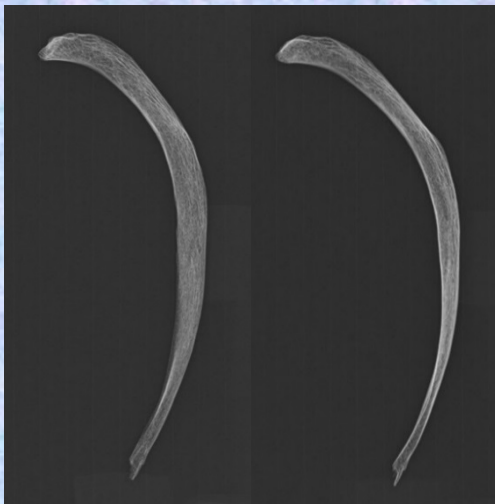


- ① 肋骨頭 head of rib
- ② 肋骨頸 neck of rib
- ③ 肋骨結節 tubercle of rib

- ④ 肋骨体 shaft of rib
- ⑤ 前斜角筋結節 scalene tubercle
- ⑥ 肋骨溝 costal groove

第十一肋骨 R11 後面

後面 (Rib 11 posterior surface)



- ① 肋骨頭 head of rib
- ② 肋骨頸 neck of rib
- ③ 肋骨結節 tubercle of rib

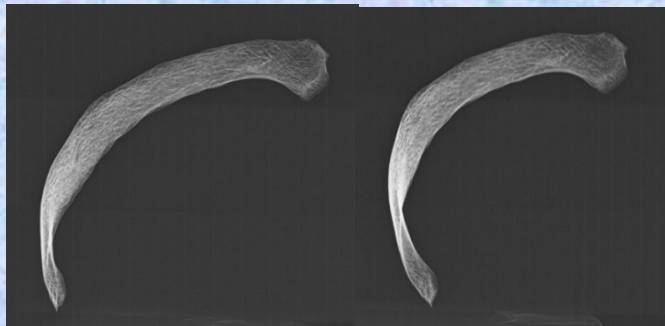
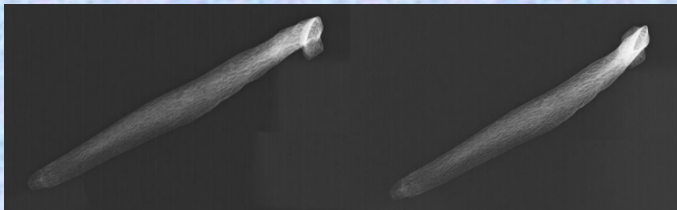
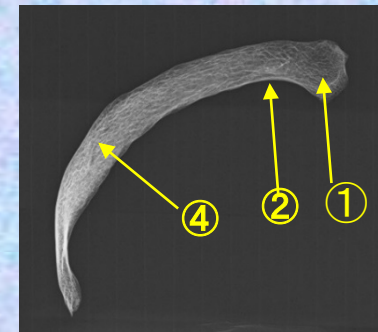


- ④ 肋骨體 shaft of rib
- ⑤ 前斜角筋結節 scalene tubercle
- ⑥ 肋骨溝 costal groove

第十一肋骨 R11 軸面

軸面 (Rib 11 Axial surface)



- ① 肋骨頭
Head of rib
- ② 肋骨頸
neck of rib
- ③ 肋骨結節
tubercle of rib
- ④ 肋骨體
shaft of rib

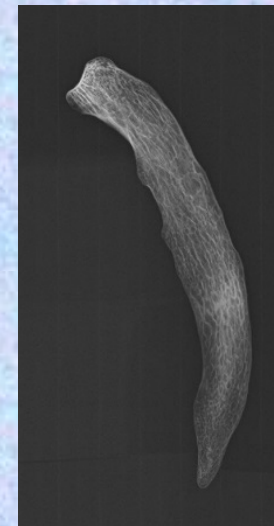
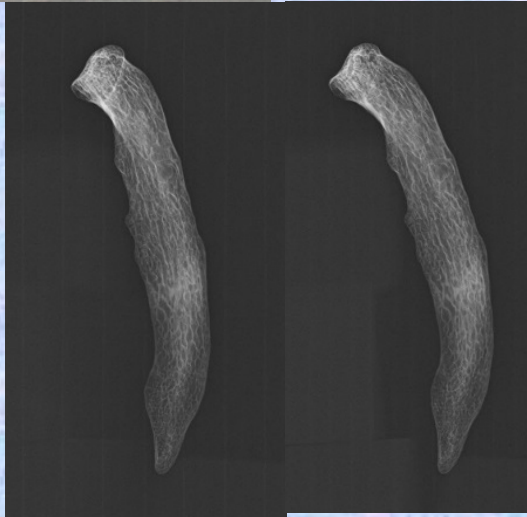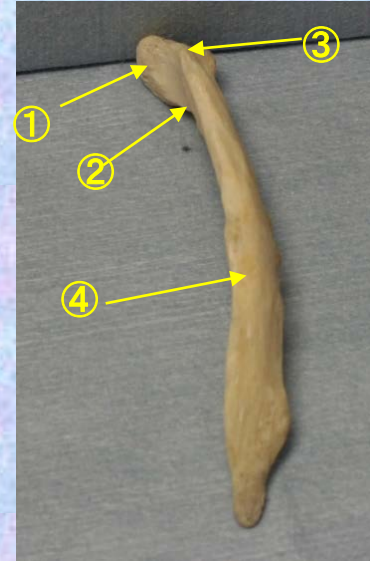


第12肋骨

Rib 12

第十二肋骨 R12 前面

前面 (Rib 12 anterior surface)

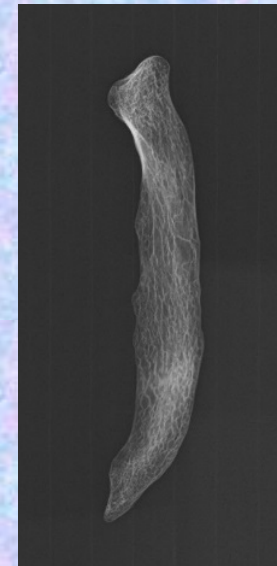
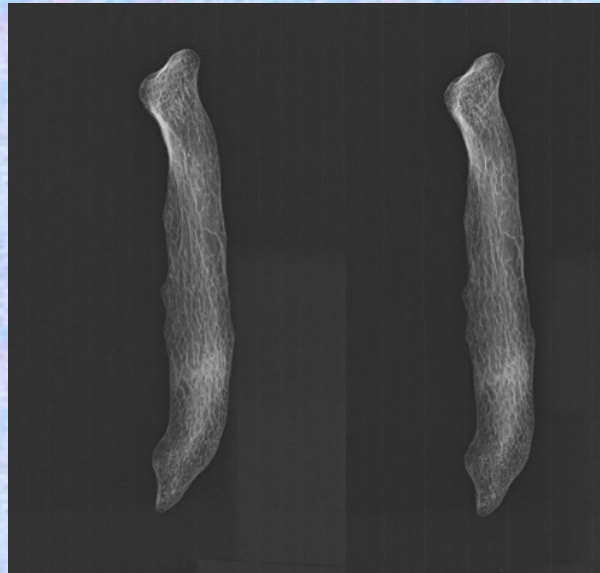
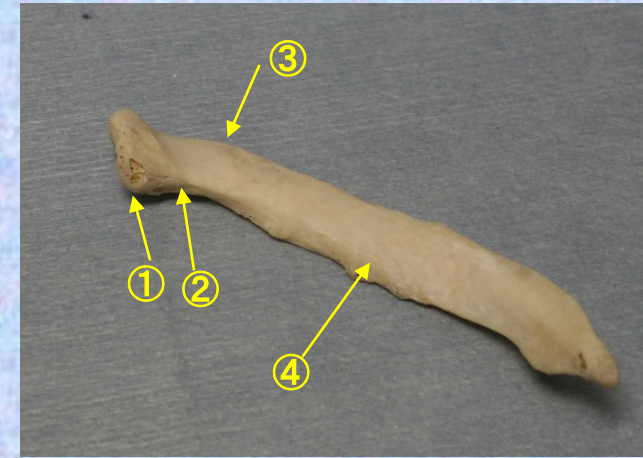
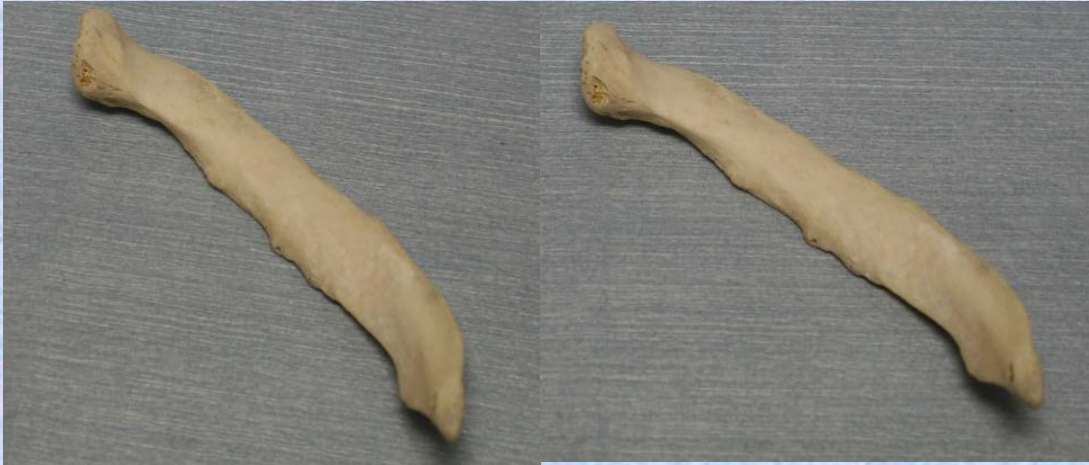

- ① 肋骨頭 head of rib
- ② 肋骨頸 neck of rib
- ③ 肋骨結節 tubercle of rib

- ④ 肋骨体 shaft of rib
- ⑤ 前斜角筋結節 scalene tubercle
- ⑥ 肋骨溝 costal groove

第十二肋骨 R12 後面

後面 (Rib 12 posterior surface)

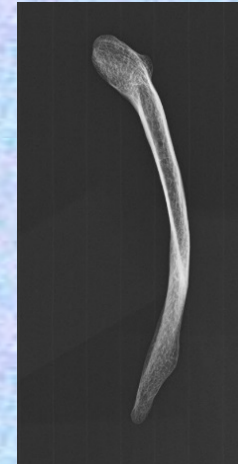
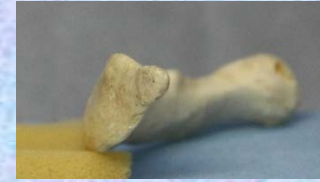
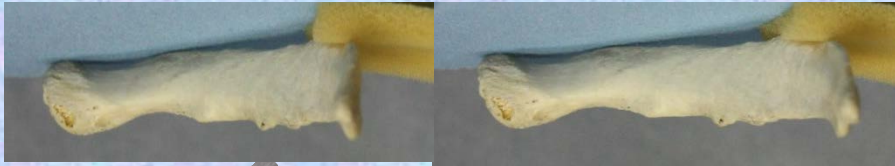- ① 肋骨頭 head of rib
 ② 肋骨頸 neck of rib
 ③ 肋骨結節 tubercle of rib

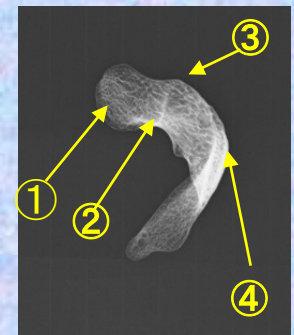
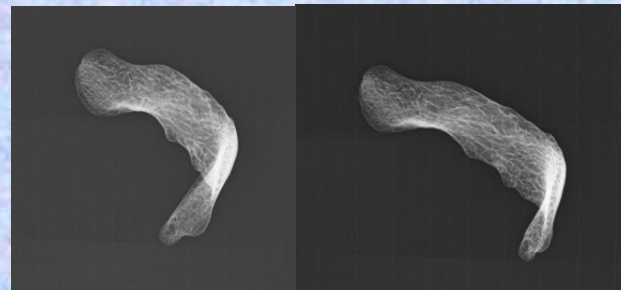
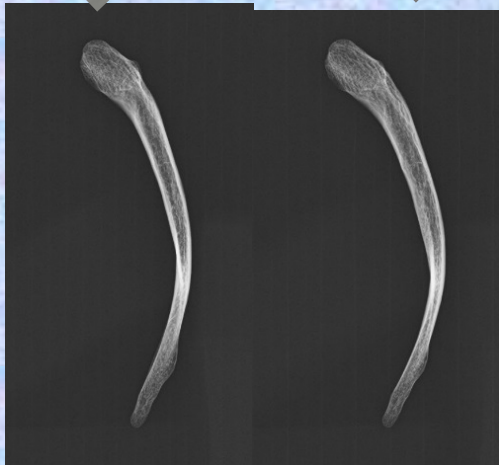- ④ 肋骨體 shaft of rib
 ⑤ 前斜角筋結節 scalene tubercle
 ⑥ 肋骨溝 costal groove

第十二肋骨 R12 軸面

軸面 (Rib 12 Axial surface)



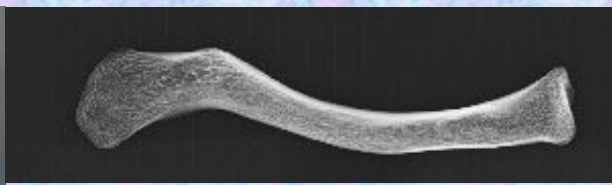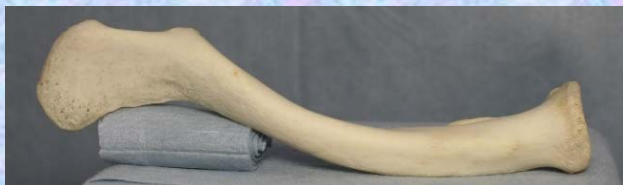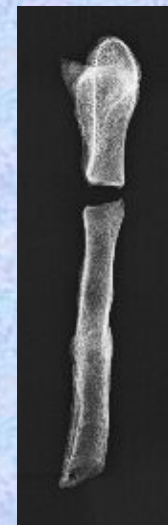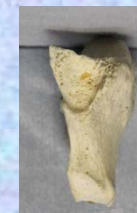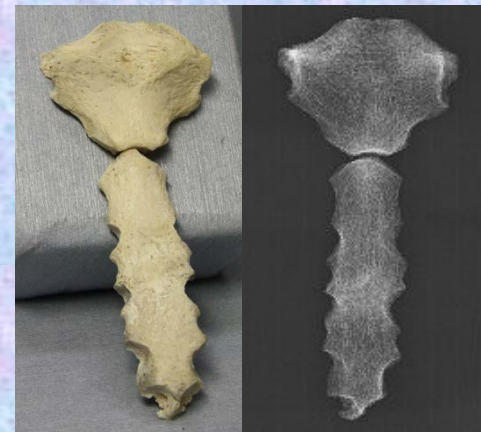
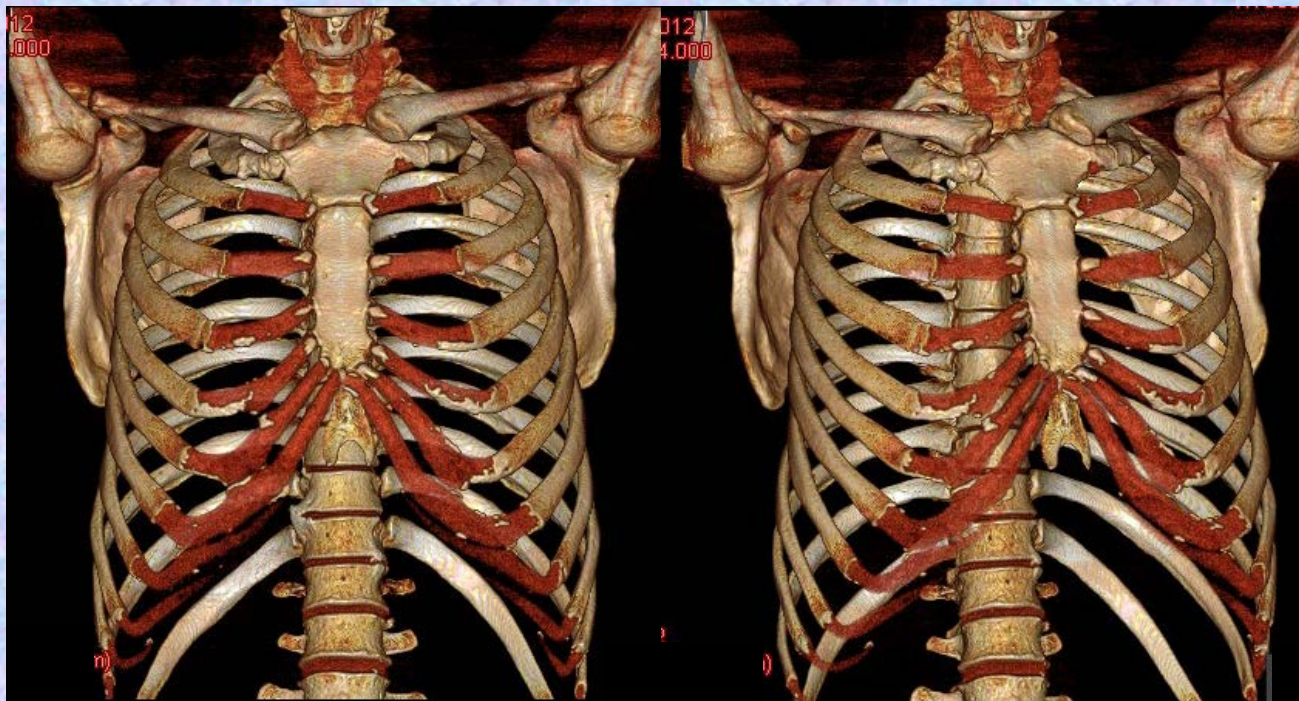
- ① 肋骨頭
Head of rib
- ② 肋骨頸
neck of rib
- ③ 肋骨結節
tubercle of rib
- ④ 肋骨體
shaft of rib



骨標本 X線ステレオ解剖図

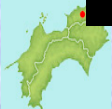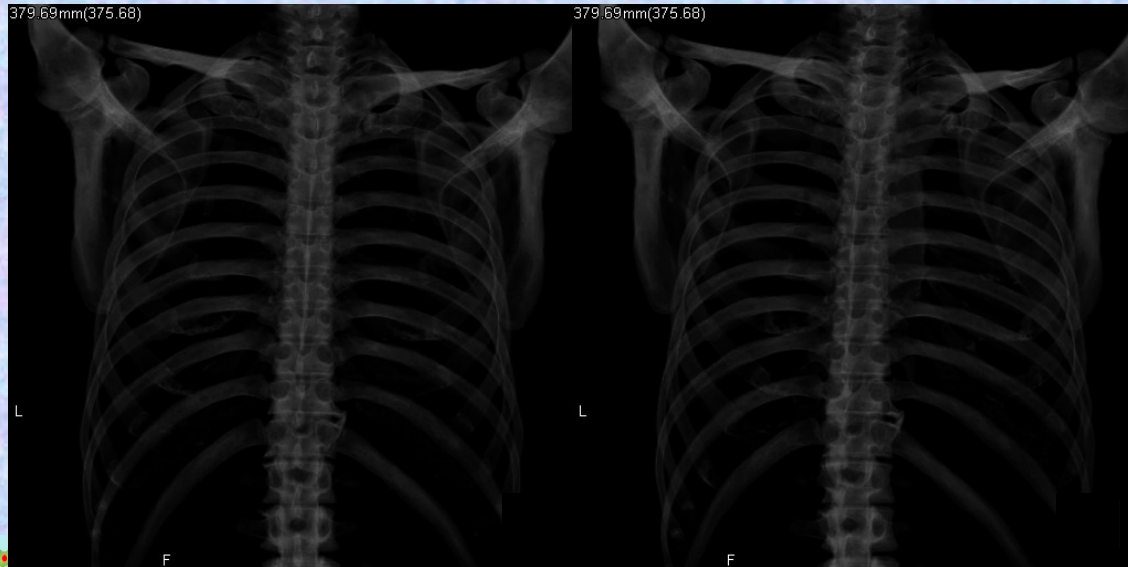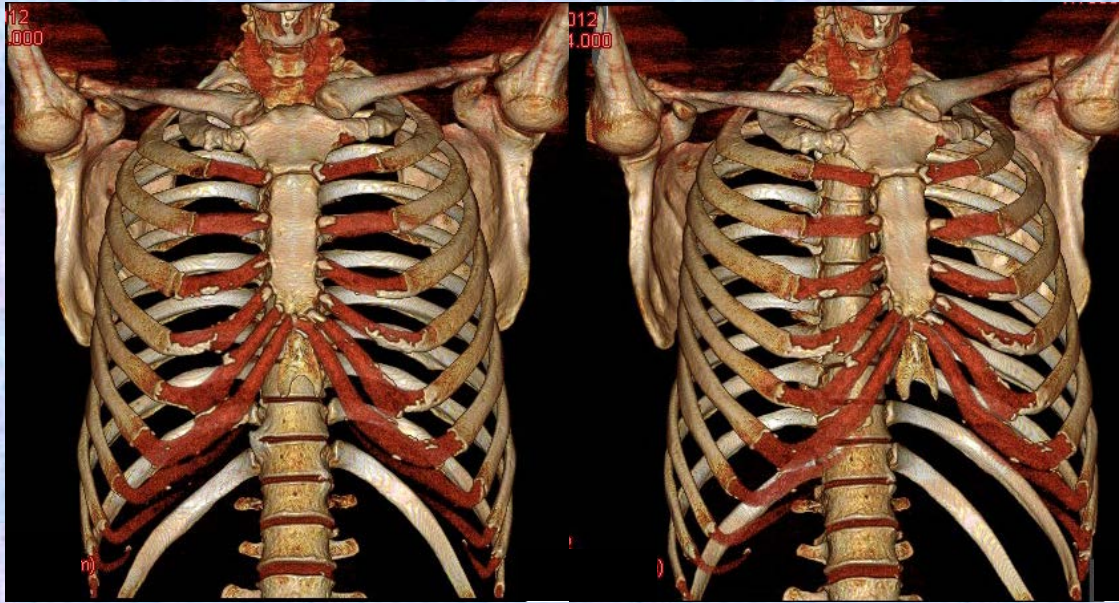
胸郭

胸郭



監修 香川大学医学部 組織細胞生物学 教授 荒木 伸一
 作成 香川大学医学部附属病院 放射線部 勢川 博雄 2014.9





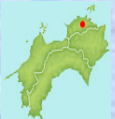胸郭

Thorax




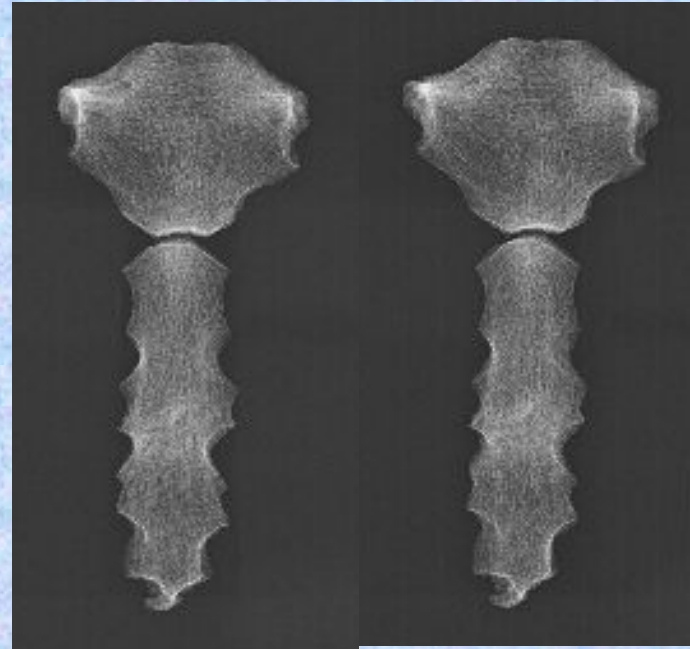
胸骨

Sternum



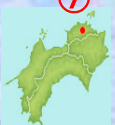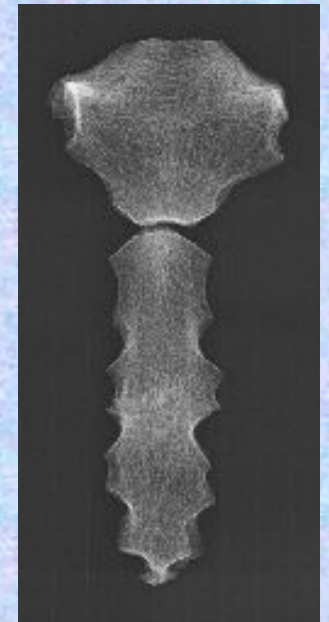
胸骨 Sternum 正面

正面 (Sternum anterior view)




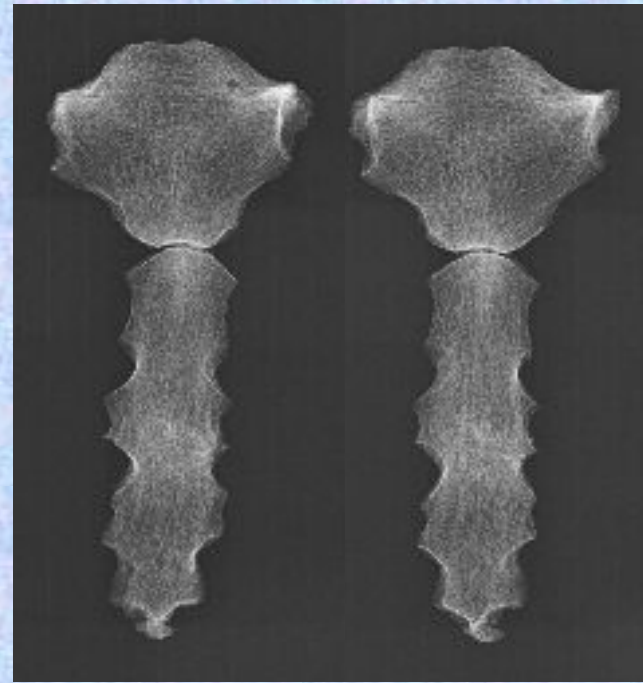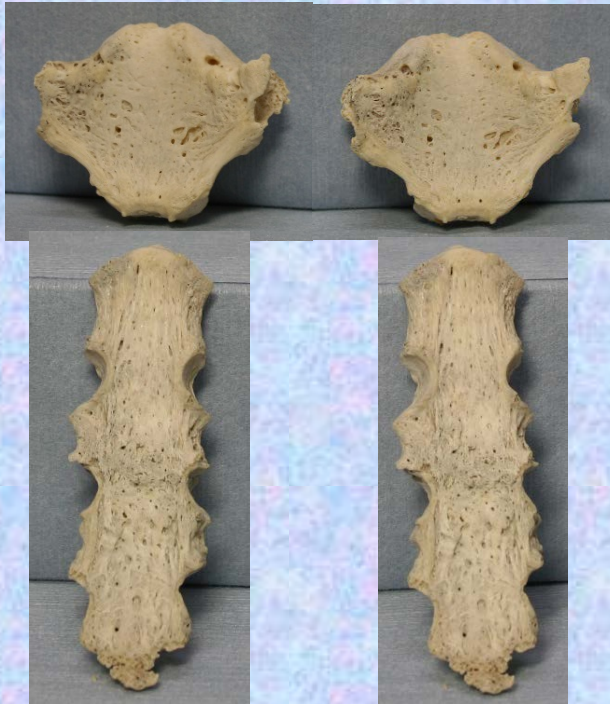
- ① 胸骨柄 manubrium
- ② 頸切痕 jugular notch
- ③ 鎖骨切痕 clavicular notch
- ④ 胸骨角 sternal angle
- ⑤ 胸骨体 gladiolus
- ⑥ 第1肋骨切痕 notch for first costal cartilage
- ⑦ 第2肋骨切痕 notches for second costal cartilage

- ⑧ 第3肋骨切痕 notch for third costal cartilage
- ⑨ 第4肋骨切痕 notch for fourth costal cartilage
- ⑩ 第5肋骨切痕 notch for fifth costal cartilage
- ⑪ 第6肋骨切痕 notch for sixth costal cartilage
- ⑫ 第7肋骨切痕 notch for seventh costal cartilage



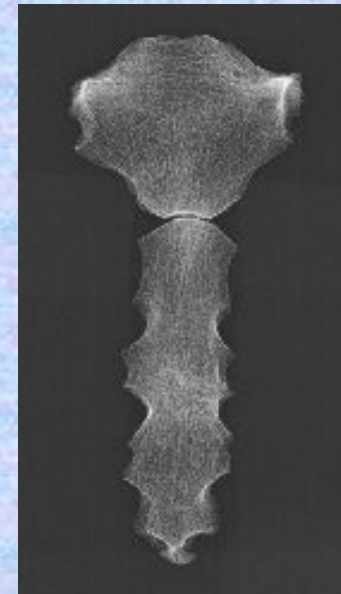
胸骨 Sternum 後面

後面 (Sternum posterior view)



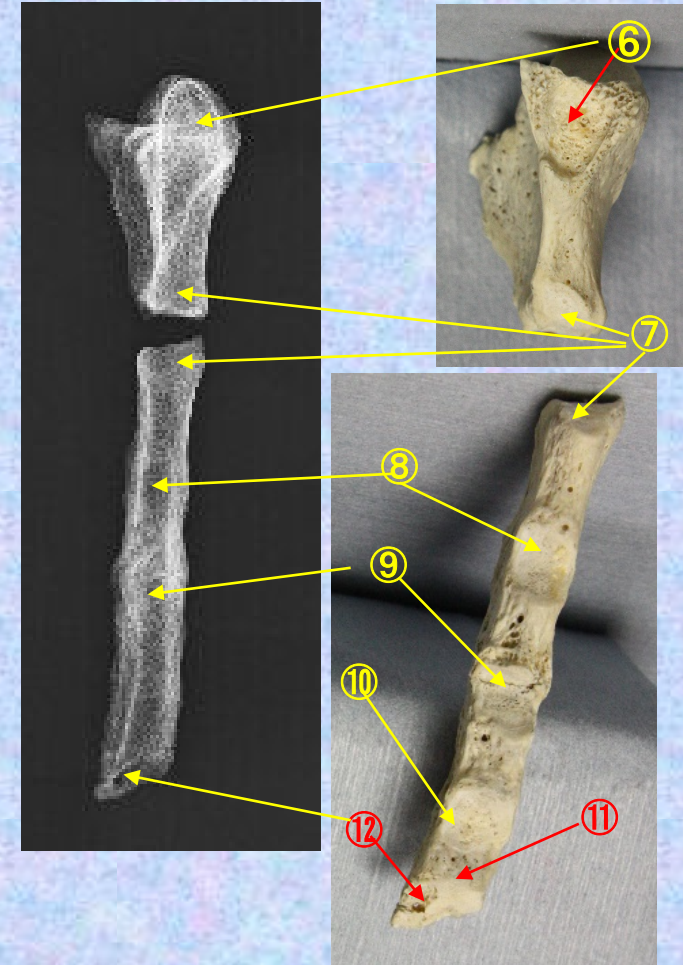
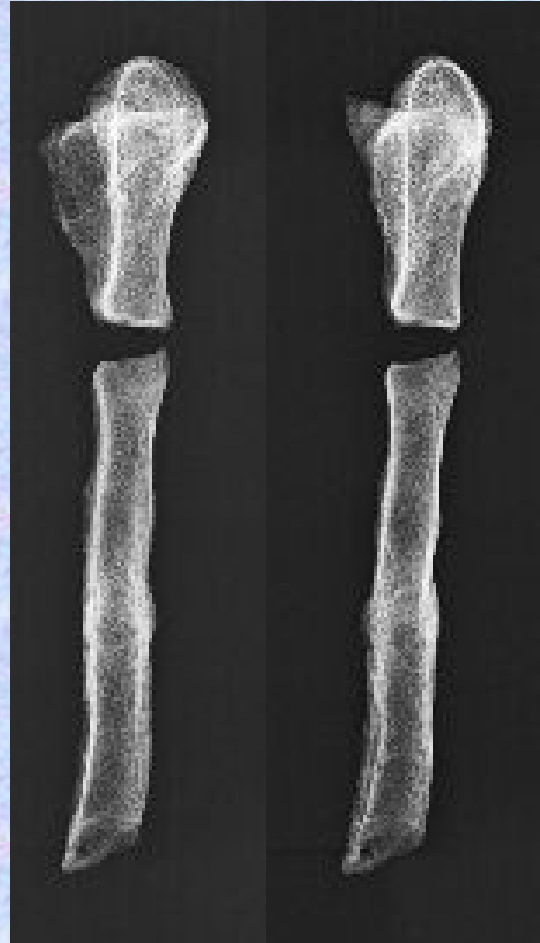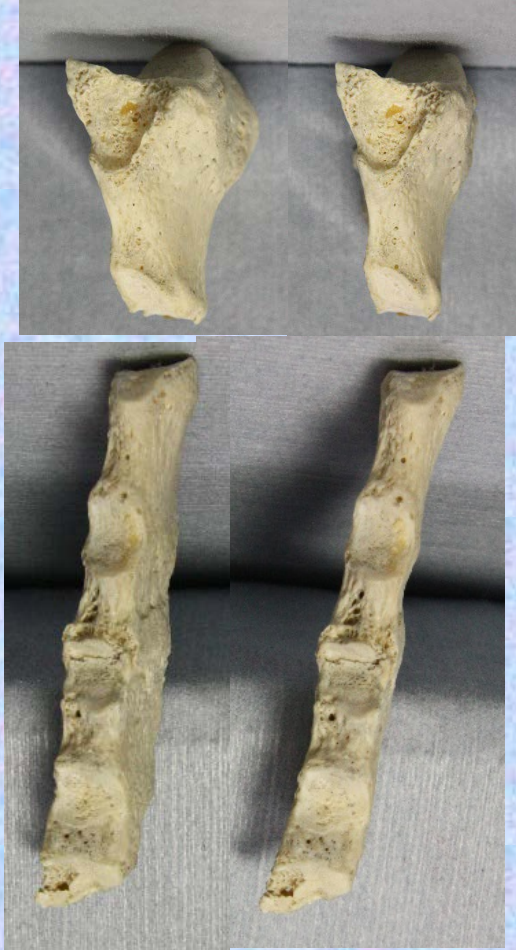- ① 胸骨柄 manubrium
- ② 頸切痕 jagular notch
- ③ 鎖骨切痕 clavicular notch
- ④ 胸骨角 sternal angle
- ⑤ 胸骨体 gladiolus
- ⑥ 第1肋骨切痕 notch for first costal cartilage
- ⑦ 第2肋骨切痕 notches for second costal cartilage

- ⑧ 第3肋骨切痕 notch for third costal cartilage
- ⑨ 第4肋骨切痕 notch for fourth costal cartilage
- ⑩ 第5肋骨切痕 notch for fifth costal cartilage
- ⑪ 第6肋骨切痕 notch for sixth costal cartilage
- ⑫ 第7肋骨切痕 notch for seventh costal cartilage



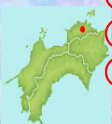胸骨 Sternum 側面

側面 (Sternum lateral view)



- ① 胸骨柄 manubrium
- ② 頸切痕 jugular notch
- ③ 鎖骨切痕 clavicular notch
- ④ 胸骨角 sternal angle
- ⑤ 胸骨体 gladiolus
- ⑥ 第1肋骨切痕 notch for first costal cartilage
- ⑦ 第2肋骨切痕 notches for second costal cartilage

- ⑧ 第3肋骨切痕 notch for third costal cartilage
- ⑨ 第4肋骨切痕 notch for fourth costal cartilage
- ⑩ 第5肋骨切痕 notch for fifth costal cartilage
- ⑪ 第6肋骨切痕 notch for sixth costal cartilage
- ⑫ 第7肋骨切痕 notch for seventh costal cartilage



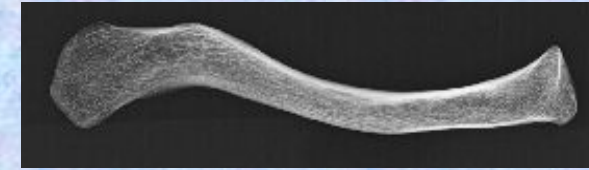
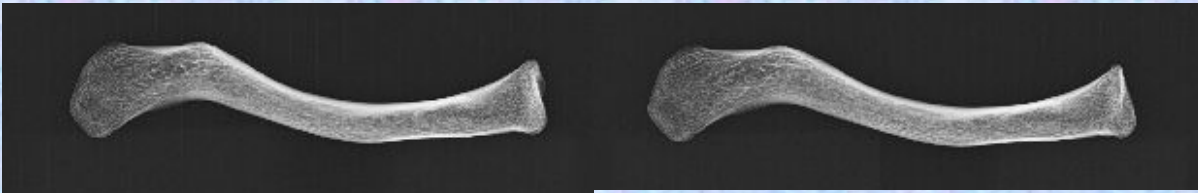
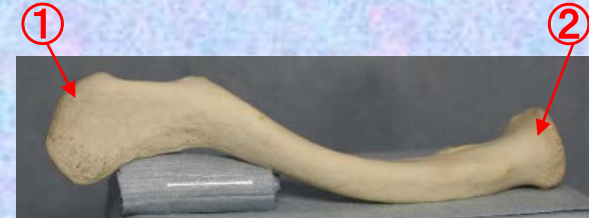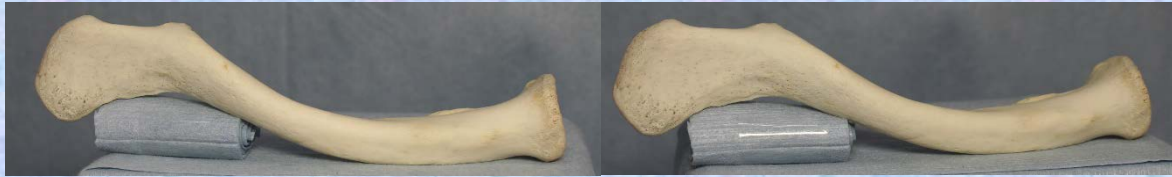鎖骨

Clavicle

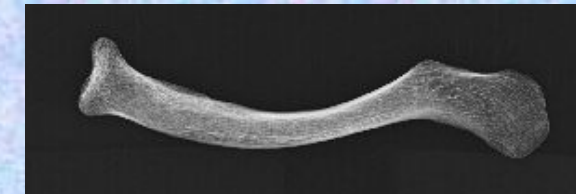
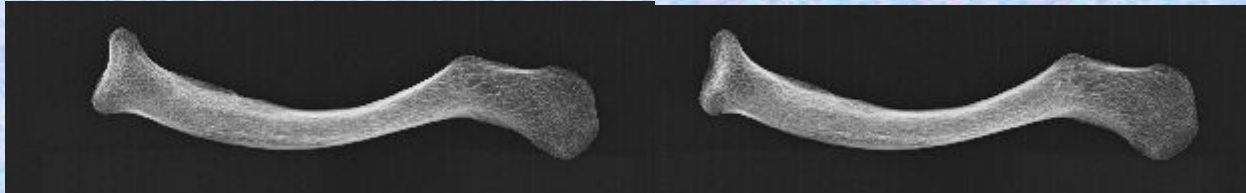
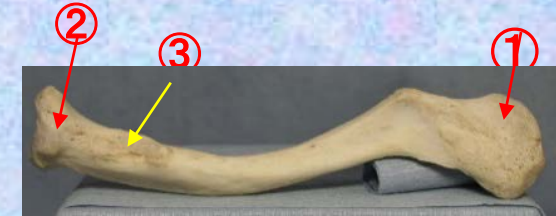
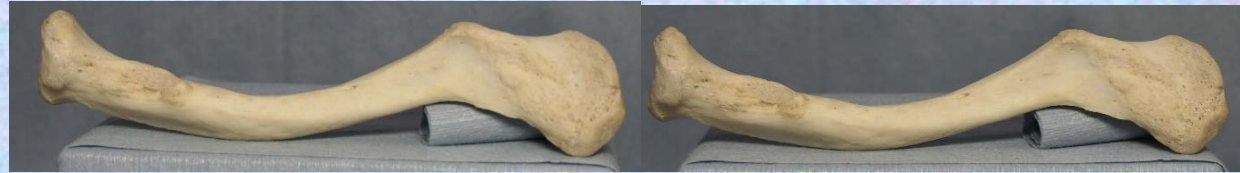
鎖骨 Clavicle

上面 (Clavicle superior view)



下面 (Clavicle inferior view)

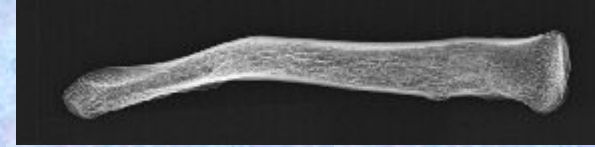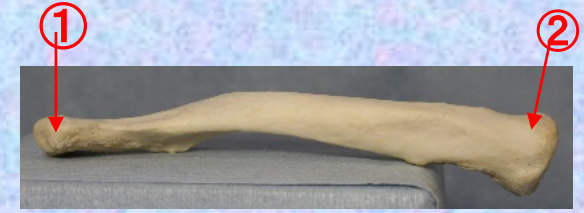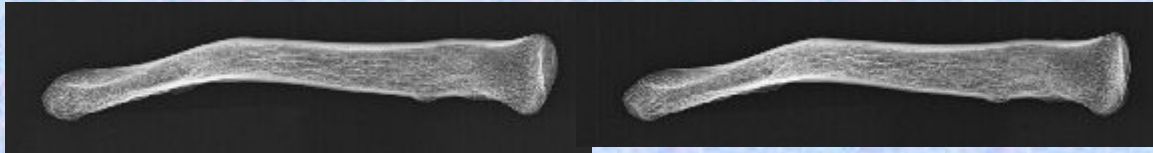


- ① 肩峰端 (肩峰關節面) acromial end with articular surface
- ② 胸骨端 (胸骨關節面) sternal end with articular surface
- ③ 肋鎖韌帶圧痕 impression for costoclavicular ligament

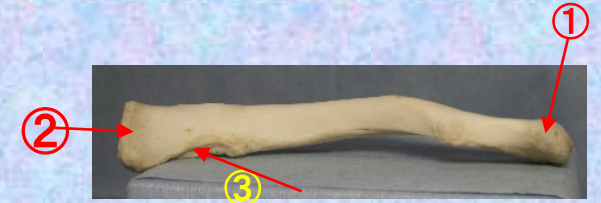
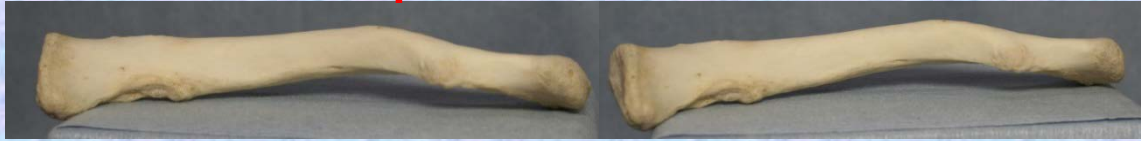
鎖骨 clavicle

正面 (Clavicle anterior view)



後面 (Clavicle posterior view)

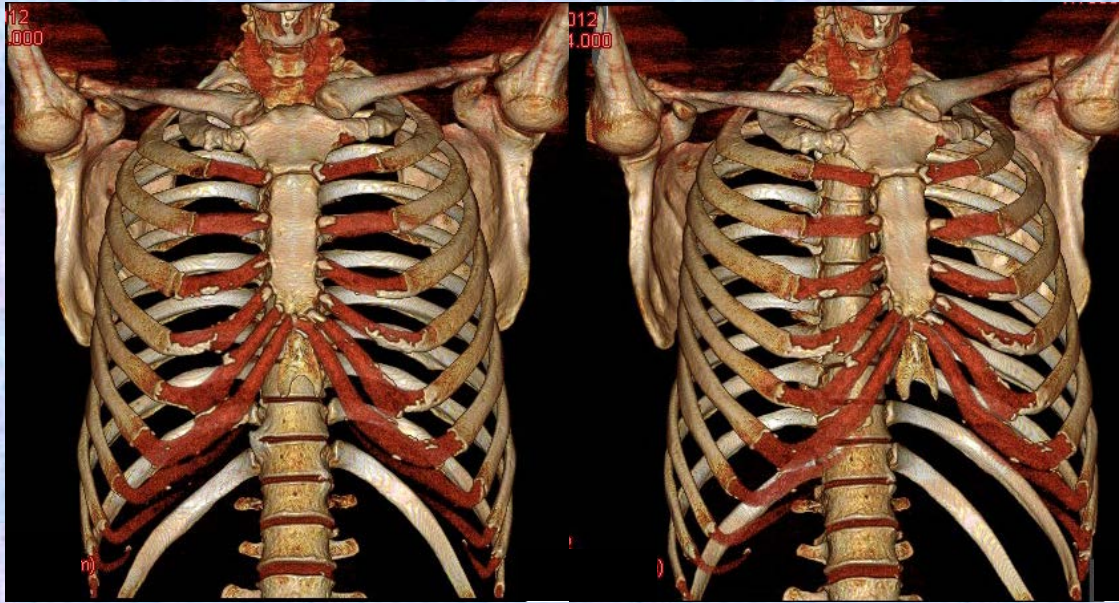


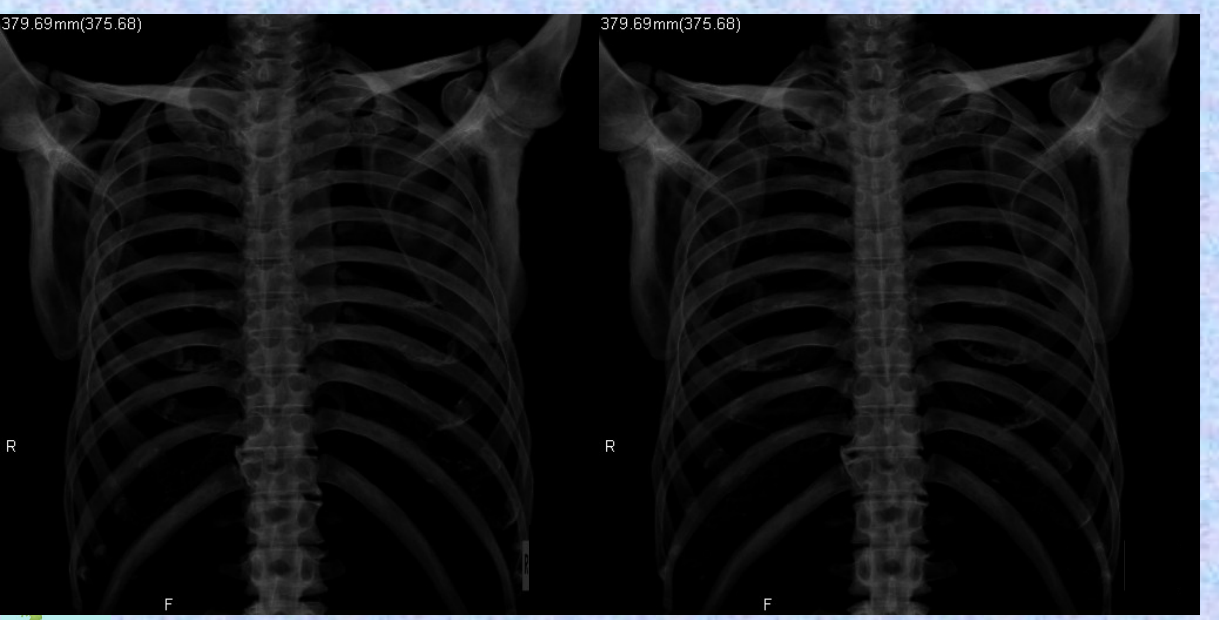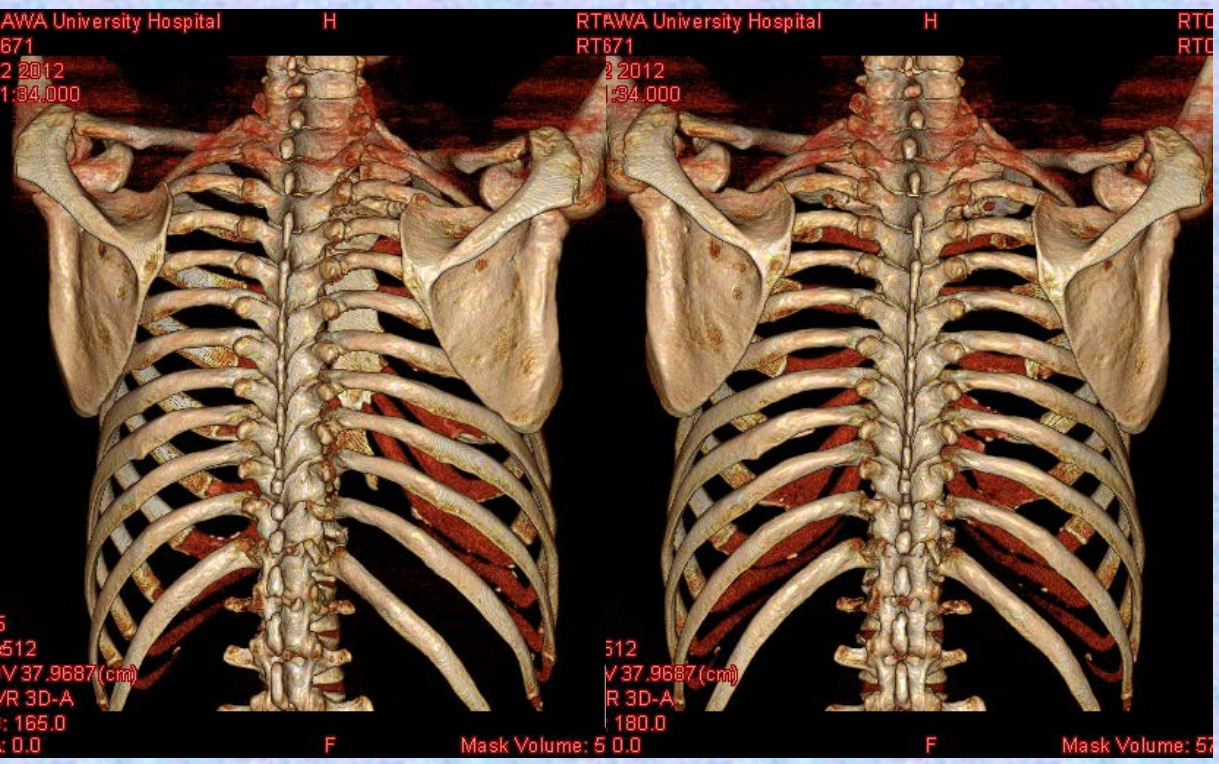
①側

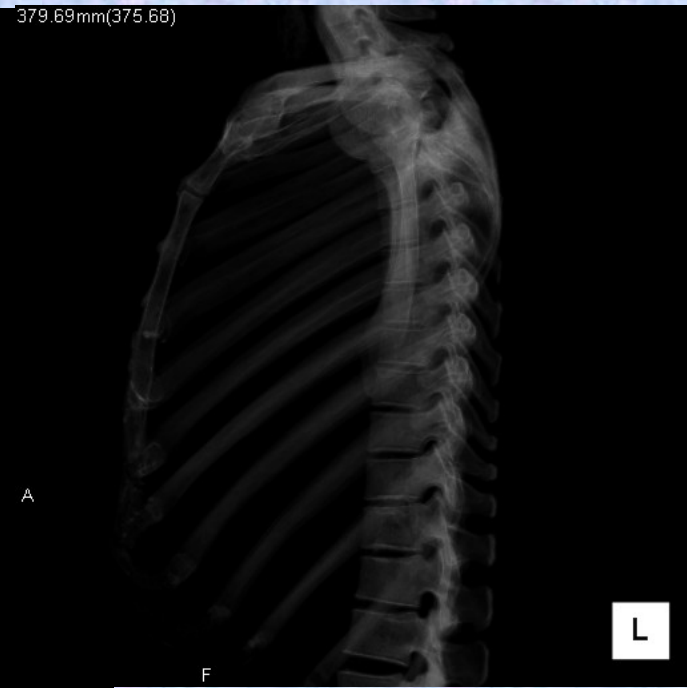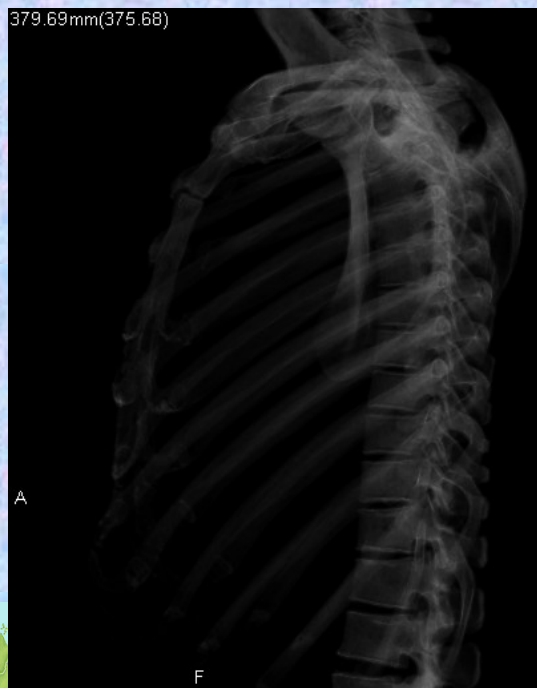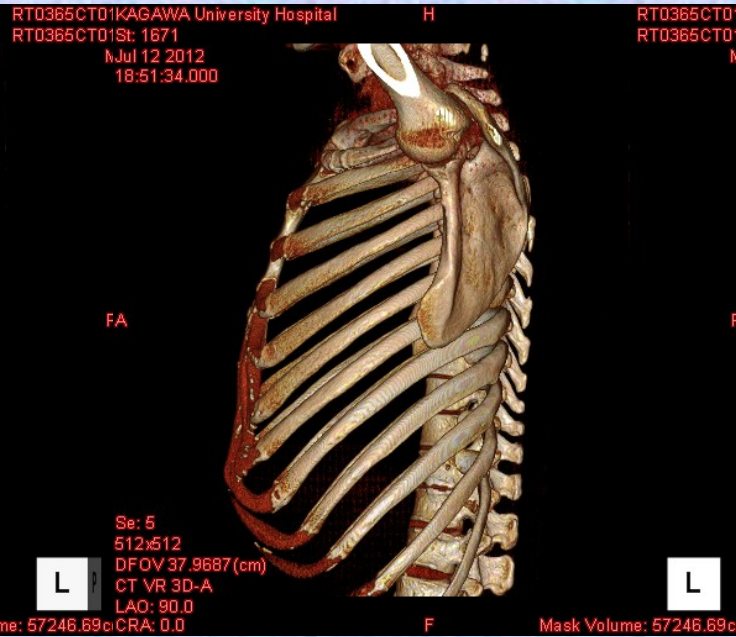
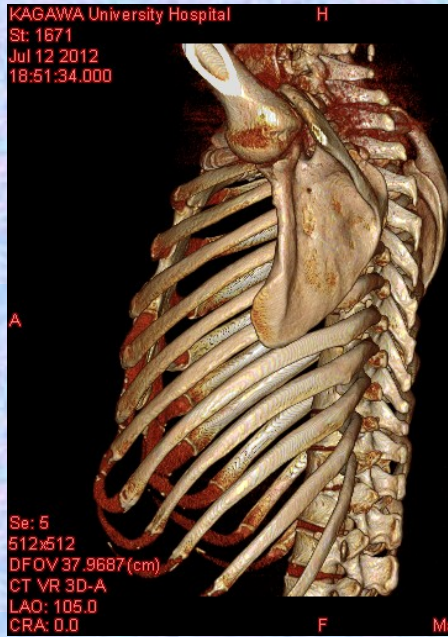


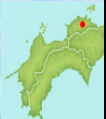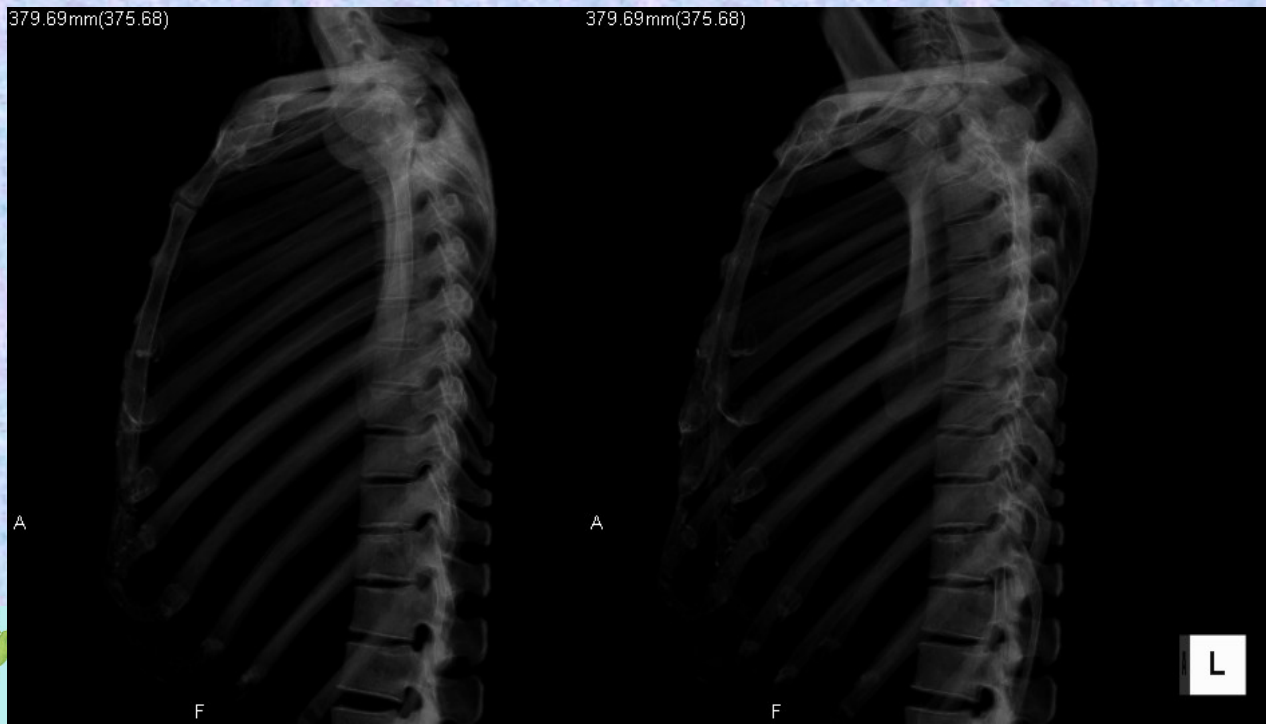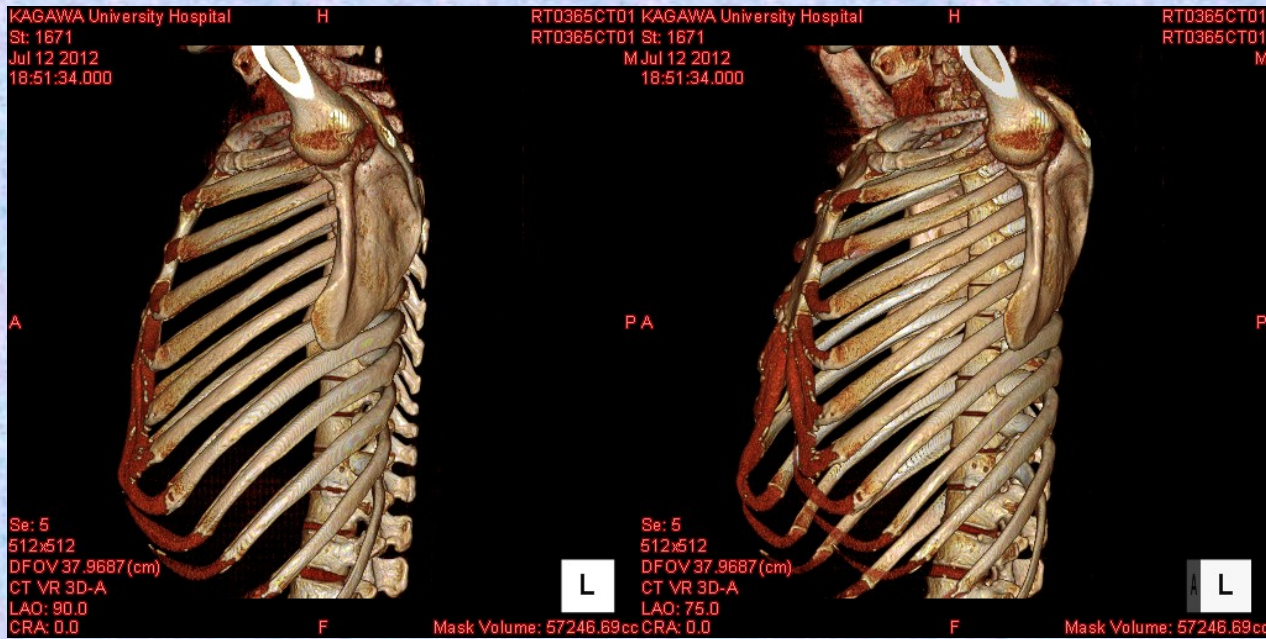
①側

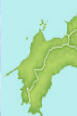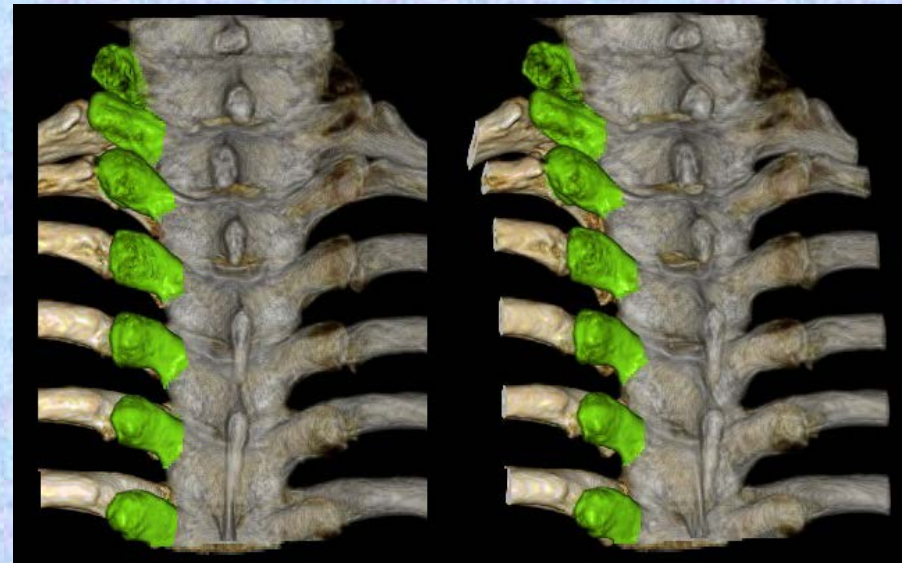
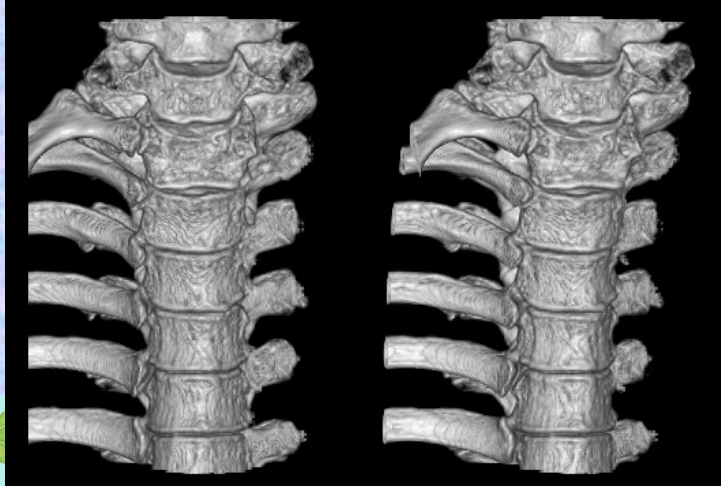
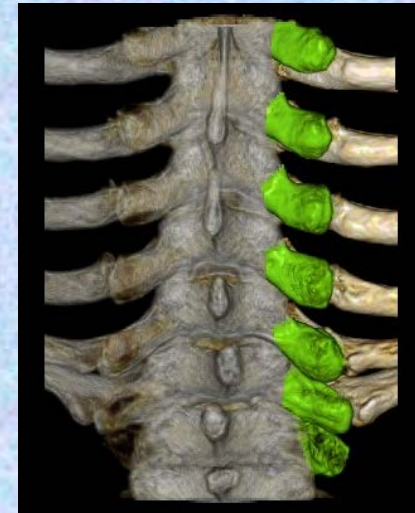
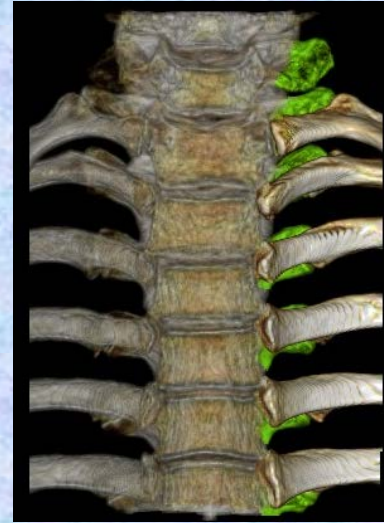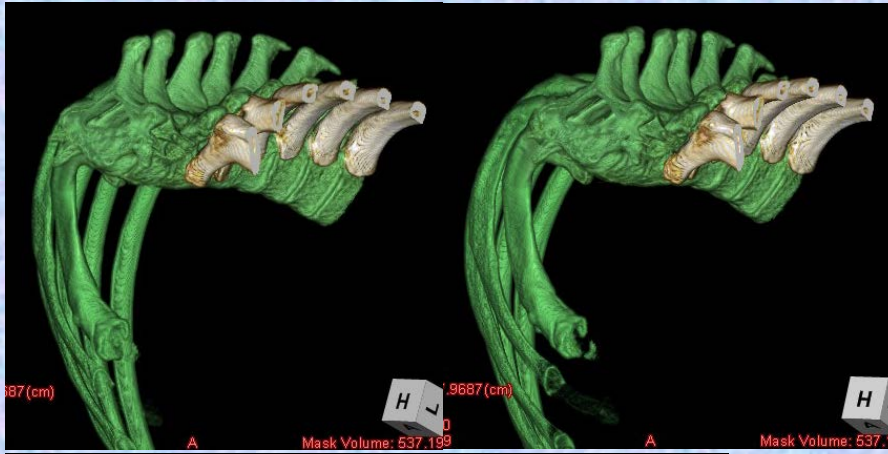
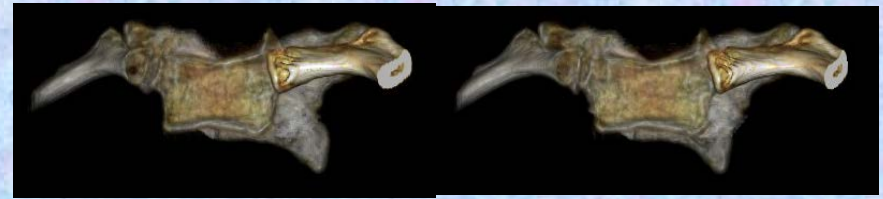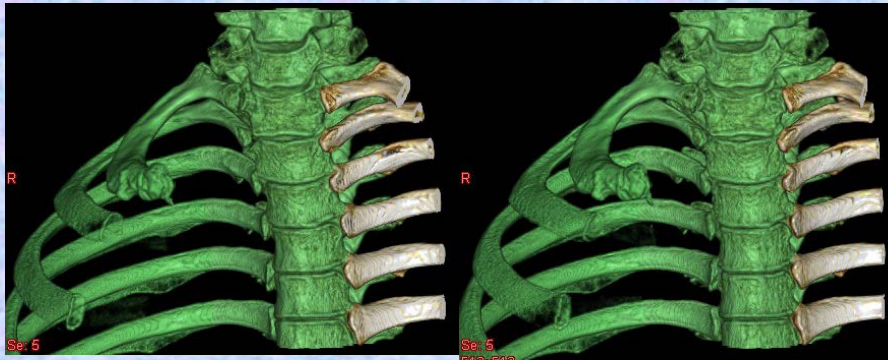


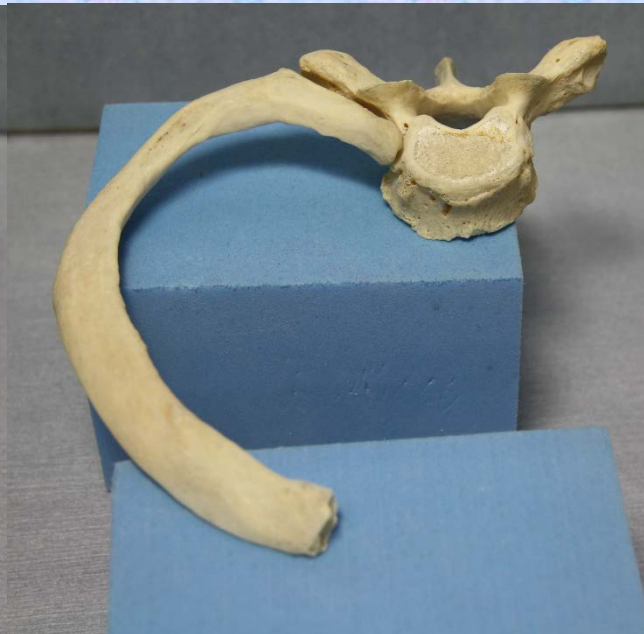




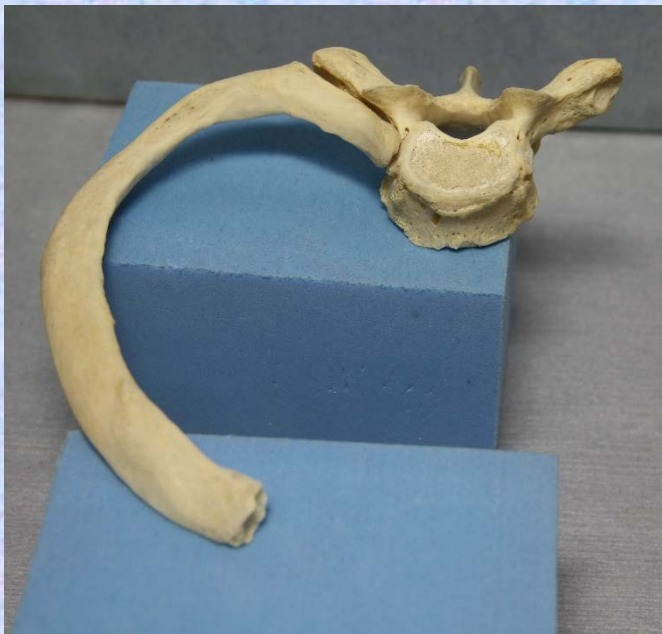
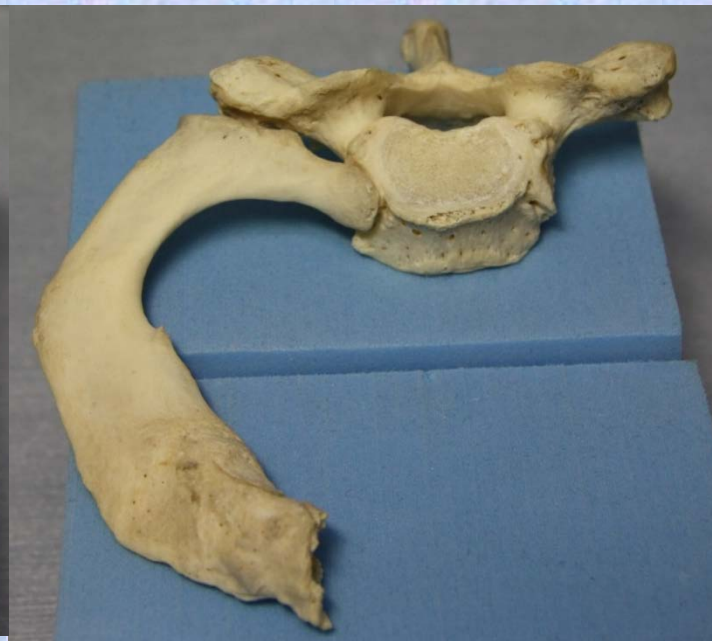
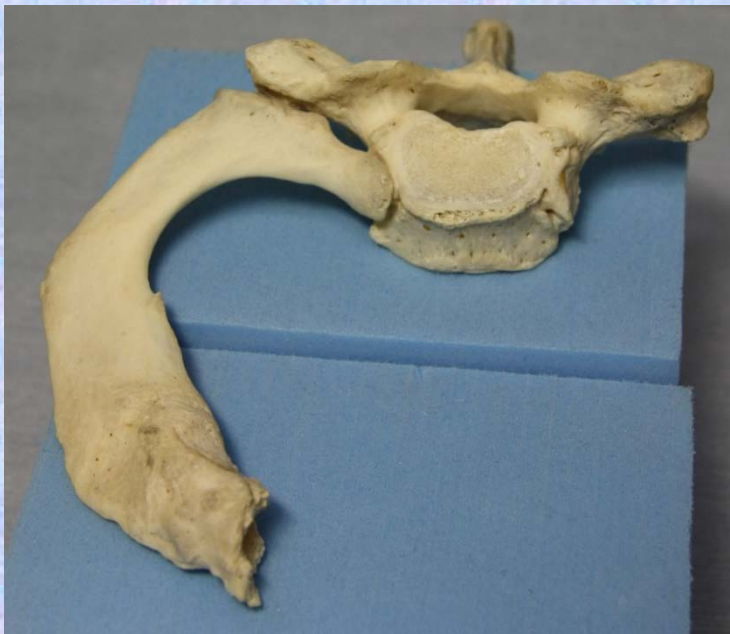



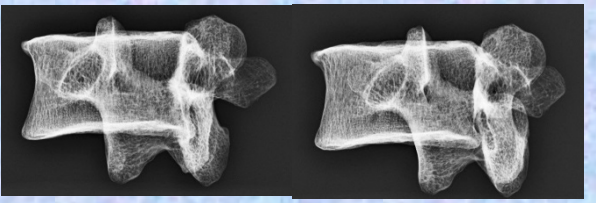
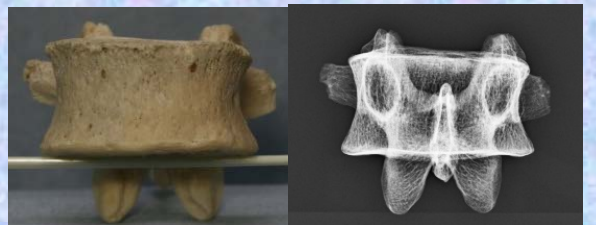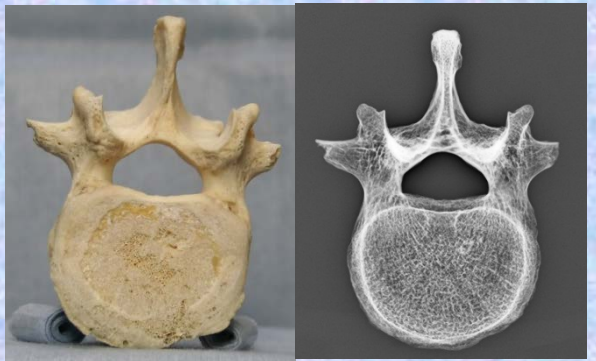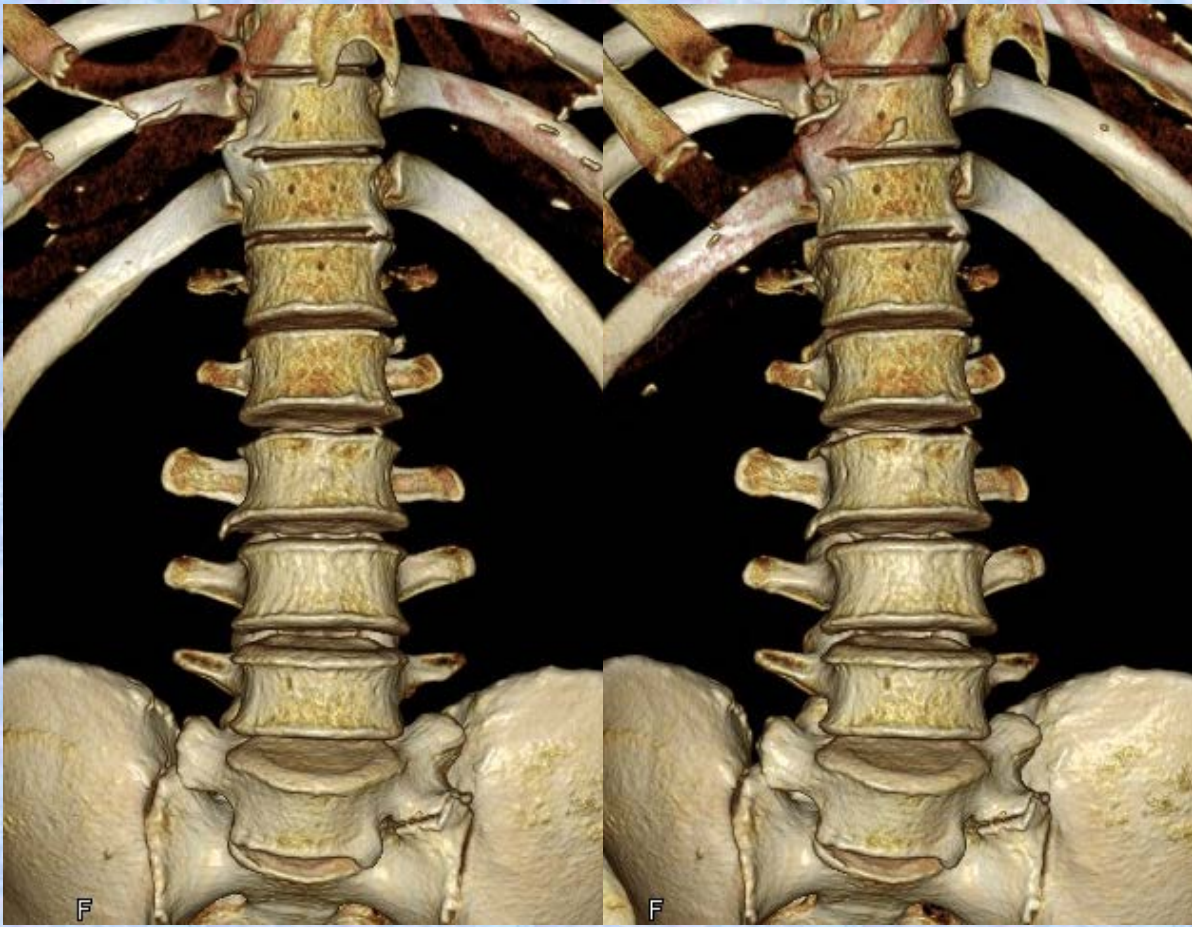




骨標本X線ステレオ解剖図

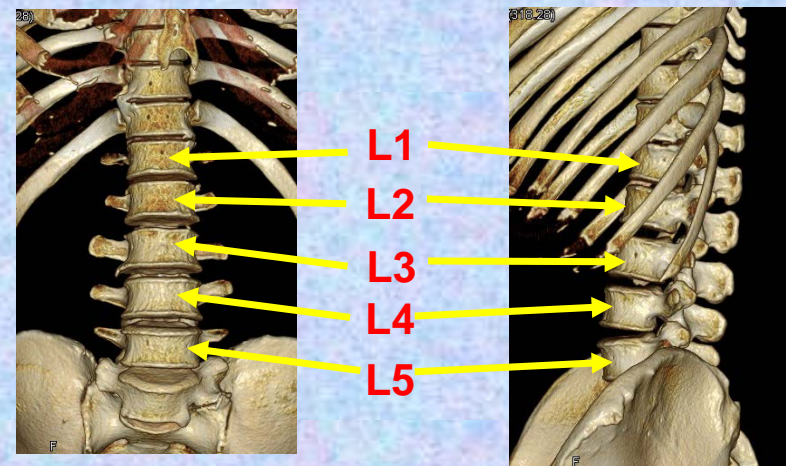
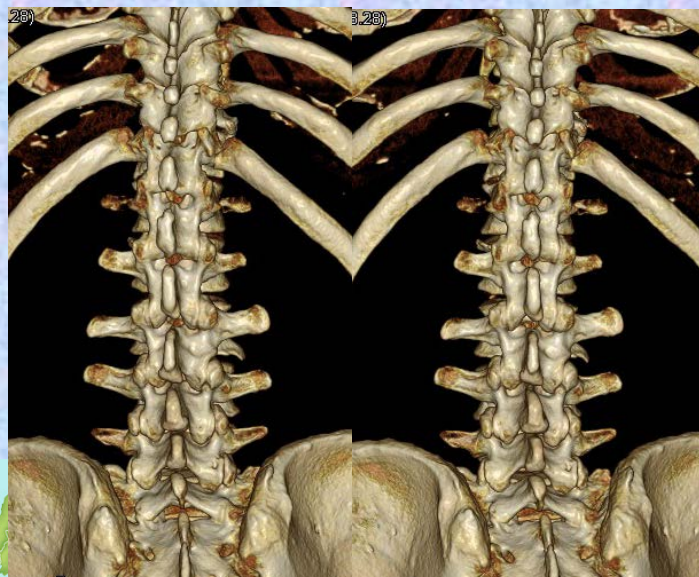
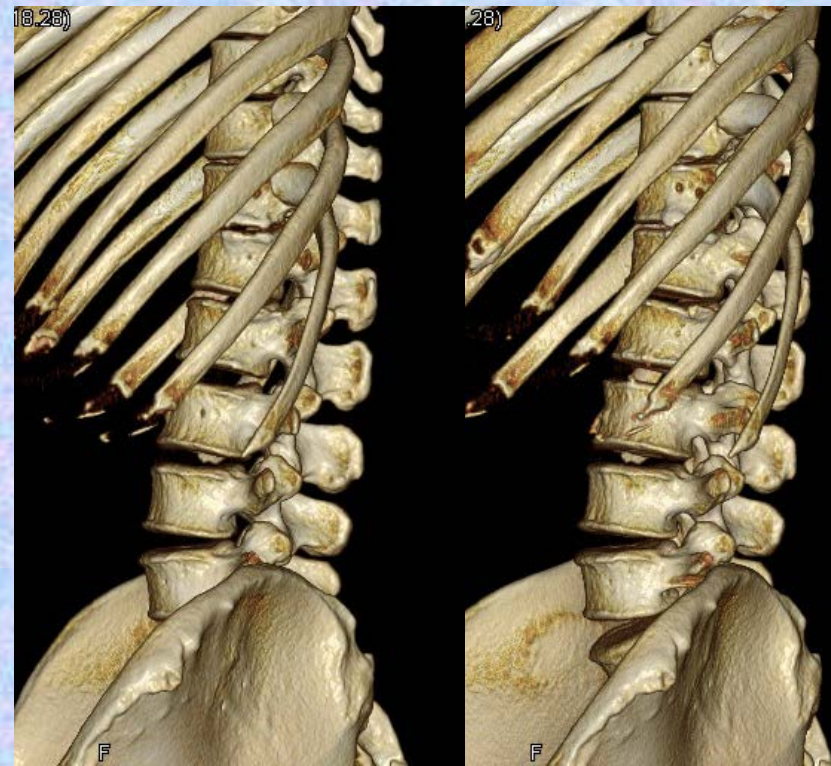
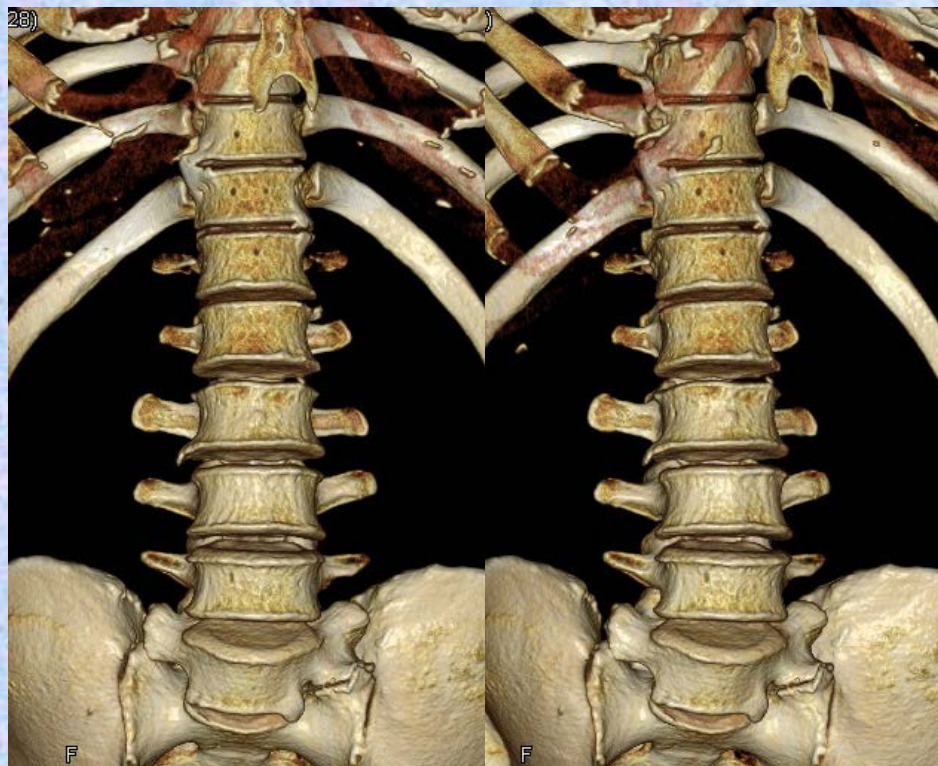
腰椎

腰椎



監修 香川大学医学部 組織細胞生物学 教授 荒木 伸一
 作成 香川大学医学部附属病院 放射線部 勢川 博雄 2014.9





腰椎

Lumbar vertebrae (複)

Lumbar vertebra (単)



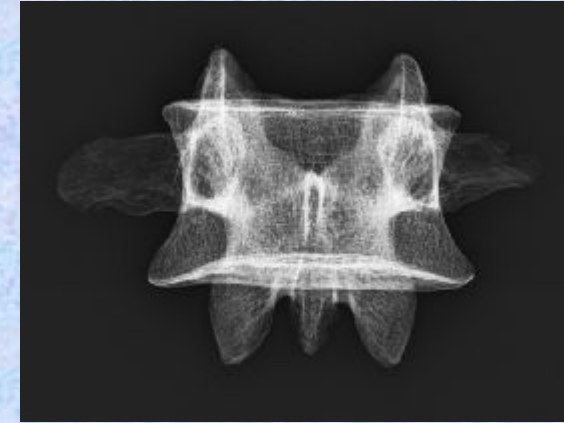
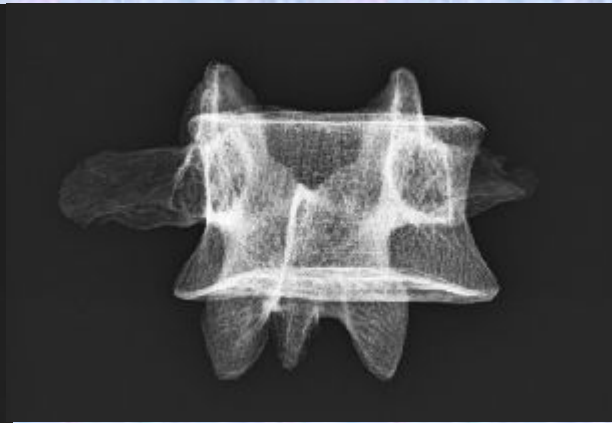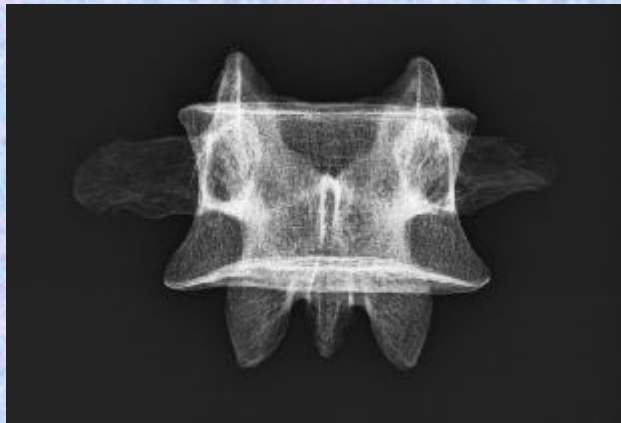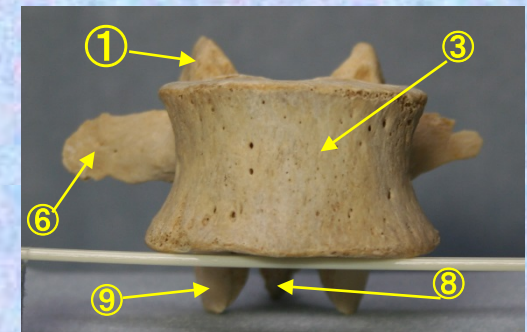
第1腰椎

Lumbar vertebra 1

L 1



腰椎 L1 前面



①上関節突起 superior articular process

②上椎切痕 superior vertebral notch

③椎体 transverse process

④下椎切痕 inferior vertebral notch

⑤乳頭突起 mamillary process

⑥肋骨突起(横突起) transverse process

⑦副突起 accessory process

⑧棘突起 spinous process

⑨下関節突起 inferior articular process

⑩椎弓板 lamina

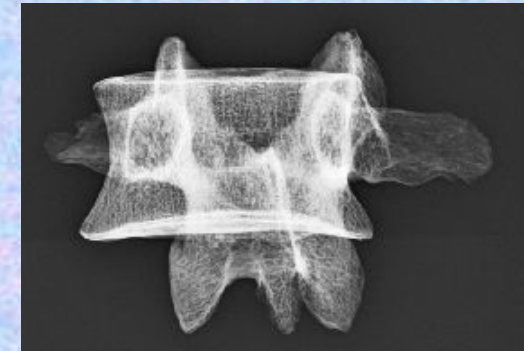
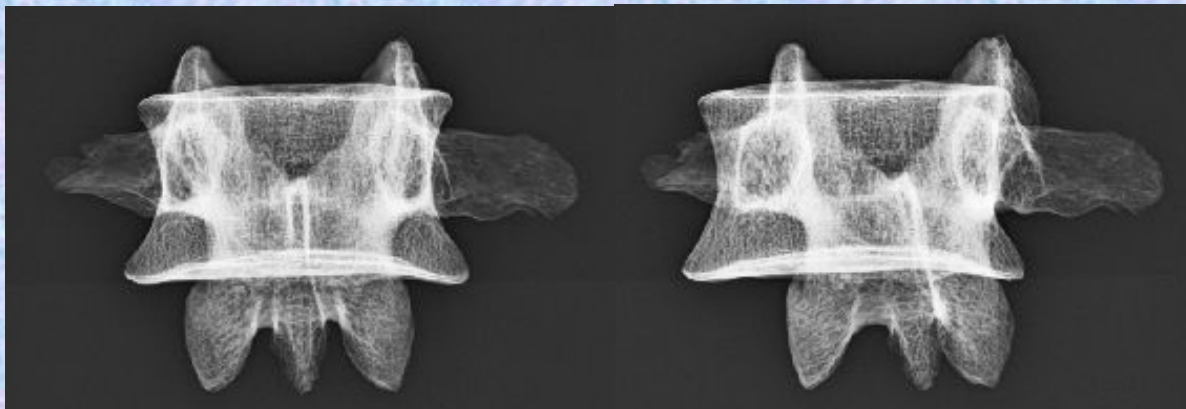
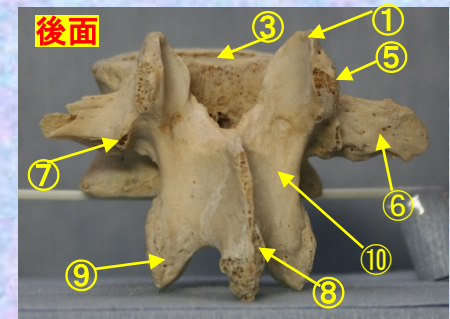
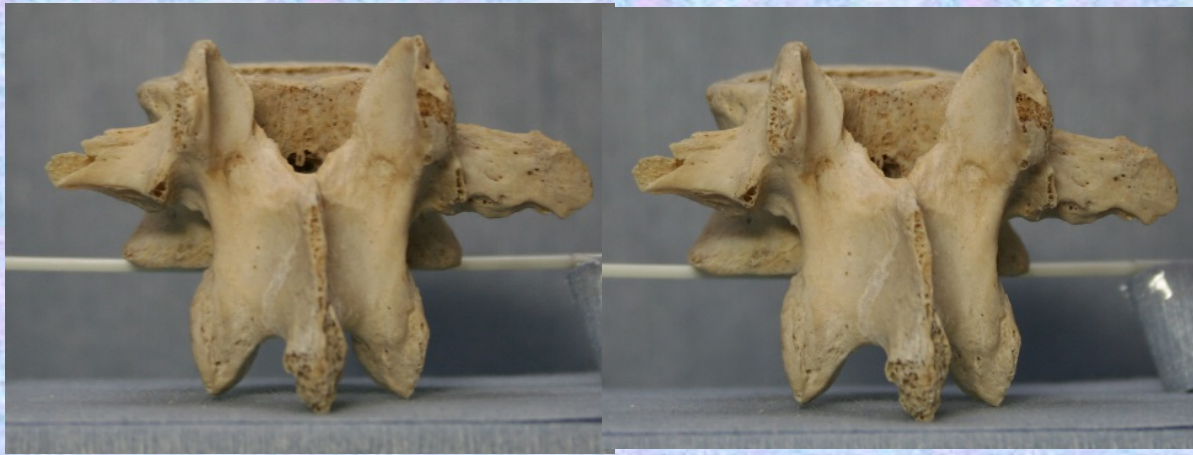⑪椎孔 vertebral foramen

⑫椎弓根pedicle

(注) 肋骨突起⑥の後ろの副突起⑦と乳頭突起⑤は、横突起の遺残を形成している。

腰椎の横突起は本来、この部の肋骨に相当するもので肋骨突起⑥といい、本来の横突起は上関節突起の外側から後方に向かう小さな隆起として残っており、乳頭突起⑤とよぶ。また、肋骨突起の根部の後面には下方に向かう小突起があり、副突起⑦というのが、これも本来の横突起の一部が変形したもの

腰椎 L1 後面

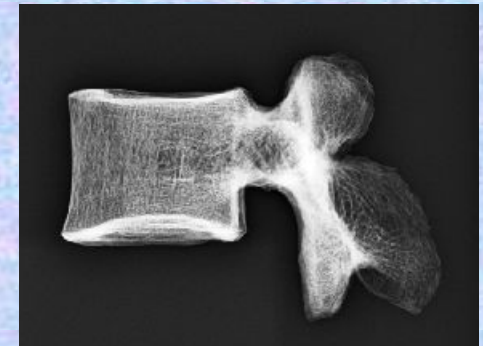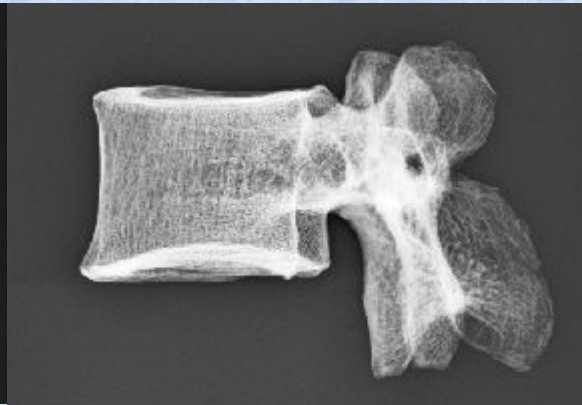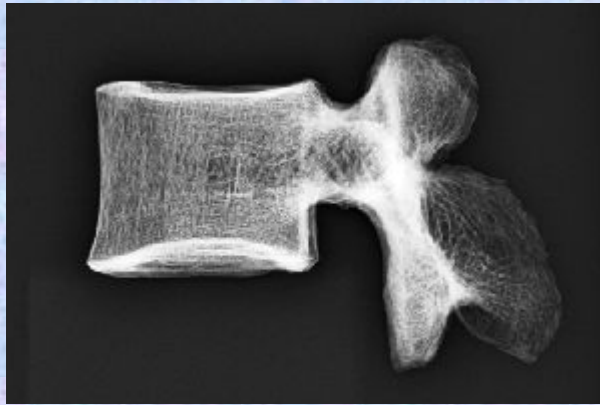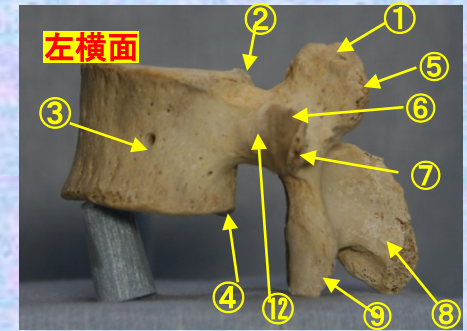


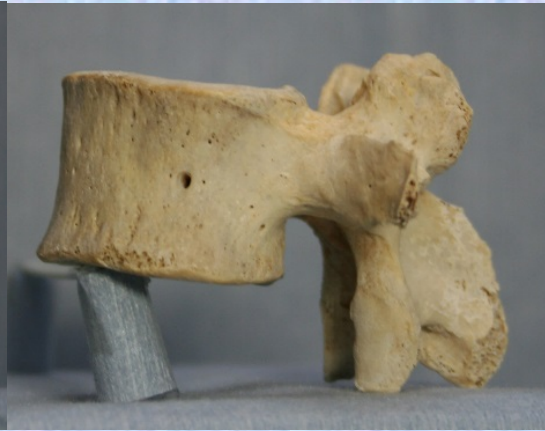- | | |
|-----------------------------------|-----------------------------------|
| ①上関節突起 superior articular process | ⑧棘突起 spinous process |
| ②上椎切痕 superior vertebral notch | ⑨下関節突起 inferior articular process |
| ③椎体 transverse process | ⑩椎弓板 lamina |
| ④下椎切痕 inferior vertebral notch | ⑪椎孔 vertebral foramen |
| ⑤乳頭突起 mamillary process | ⑫椎弓根pedicle |
| ⑥肋骨突起(横突起) transverse process | |
| ⑦副突起 accessory process | |

(注) 肋骨突起⑥の後ろの副突起⑦と乳頭突起⑤は、横突起の遺残を形成している。

腰椎の横突起は本来、この部の肋骨に相当するもので肋骨突起⑥といい、本来の横突起は上関節突起の外側から後方に向かう小さな隆起として残っており、乳頭突起⑤とよぶ。また、肋骨突起の根部の後面には下方に向かう小突起があり、副突起⑦というのが、これも本来の横突起の一部が変形したもの

腰椎 L1 側面

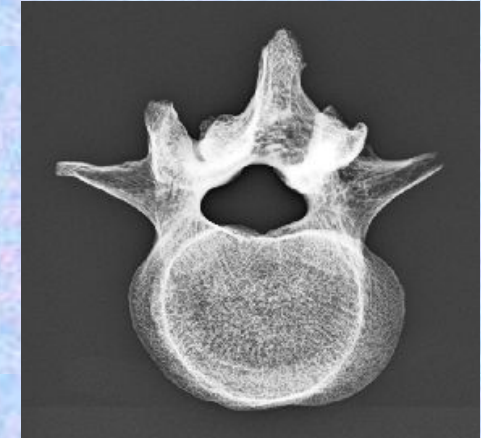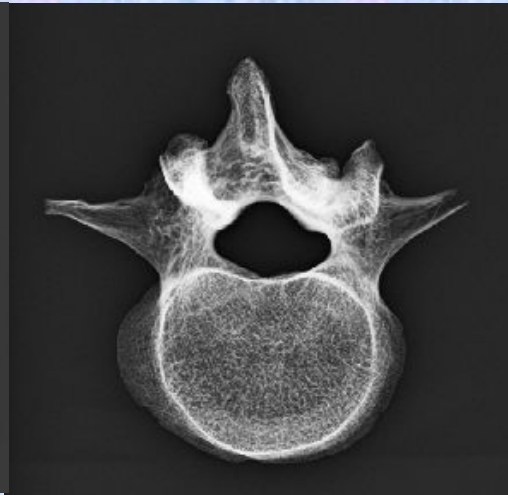

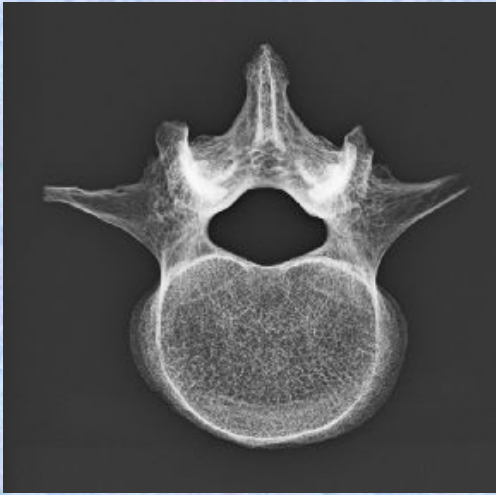

- | | |
|-----------------------------------|---|
| ①上関節突起 superior articular process | ⑧棘突起 spinous process |
| ②上椎切痕 superior vertebral notch | ⑨下関節突起 inferior articular process |
| ③椎体 transverse process | ⑩椎弓板 lamina |
| ④下椎切痕 inferior vertebral notch | ⑪椎孔 vertebral foramen |
| ⑤乳頭突起 mamillary process | ⑫椎弓根pedicle |
| ⑥肋骨突起(横突起) transverse process | (注) 肋骨突起⑥の後ろの副突起⑦と乳頭突起⑤は、横突起の遺残を形成している。 |
| ⑦副突起 accessory process | |

腰椎の横突起は本来、この部の肋骨に相当するもので肋骨突起⑥といい、本来の横突起は上関節突起の外側から後方に向かう小さな隆起として残っており、乳頭突起⑤とよぶ。また、肋骨突起の根部の後面には下方に向かう小突起があり、副突起⑦というのが、これも本来の横突起の一部が変形したもの



腰椎 L1 上面



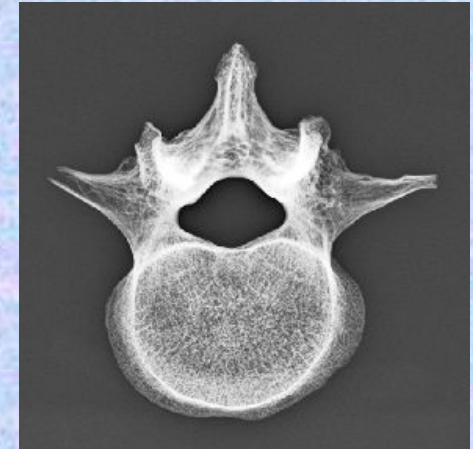
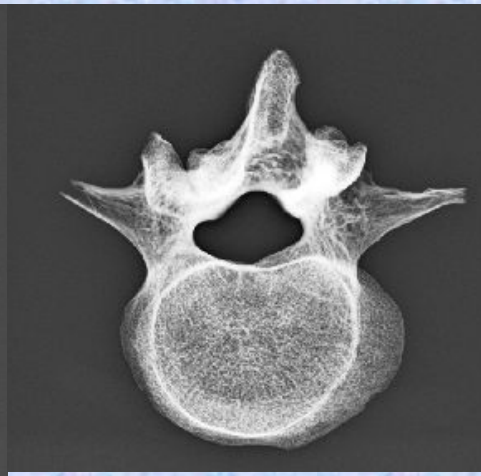
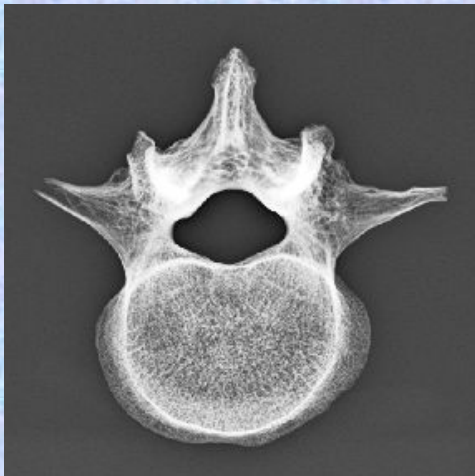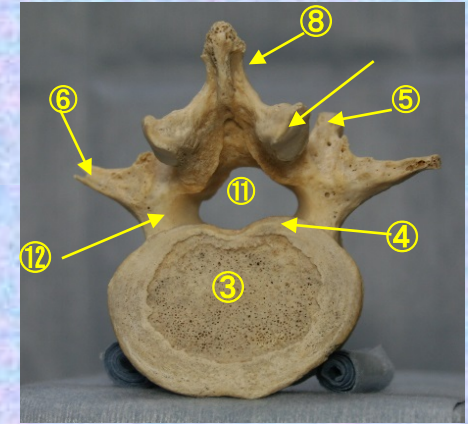
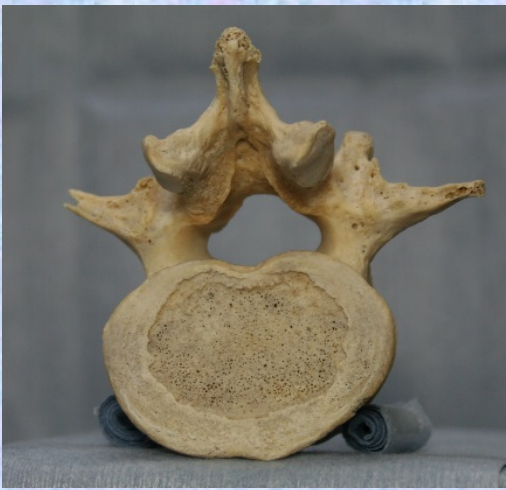- | | |
|-----------------------------------|-----------------------------------|
| ①上関節突起 superior articular process | ⑧棘突起 spinous process |
| ②上椎切痕 superior vertebral notch | ⑨下関節突起 inferior articular process |
| ③椎体 transverse process | ⑩椎弓板 lamina |
| ④下椎切痕 inferior vertebral notch | ⑪椎孔 vertebral foramen |
| ⑤乳頭突起 mamillary process | ⑫椎弓根 pedicle |
| ⑥肋骨突起(横突起) transverse process | |
| ⑦副突起 accessory process | |

(注) 肋骨突起⑥の後ろの副突起⑦と乳頭突起⑤は、横突起の遺残を形成している。

腰椎の横突起は本来、この部の肋骨に相当するもので肋骨突起⑥といい、本来の横突起は上関節突起の外側から後方に向かう小さな隆起として残っており、乳頭突起⑤とよぶ。また、肋骨突起の根部の後面には下方に向かう小突起があり、副突起⑦というのが、これも本来の横突起の一部が変形したもの



腰椎 L1 下面



- ①上関節突起 superior articular process
- ②上椎切痕 superior vertebral notch
- ③椎体 transverse process
- ④下椎切痕 inferior vertebral notch
- ⑤乳頭突起 mamillary process
- ⑥肋骨突起(横突起) transverse process
- ⑦副突起 accessory process

- ⑧棘突起 spinous process
- ⑨下関節突起 inferior articular process
- ⑩椎弓板 lamina
- ⑪椎孔 vertebral foramen
- ⑫椎弓根pedicle

(注) 肋骨突起⑥の後ろの副突起⑦と乳頭突起⑤は、横突起の遺残を形成している。

腰椎の横突起は本来、この部の肋骨に相当するもので肋骨突起⑥といい、本来の横突起は上関節突起の外側から後方に向かう小さな隆起として残っており、乳頭突起⑤とよぶ。また、肋骨突起の根部の後面には下方に向かう小突起があり、副突起⑦というのが、これも本来の横突起の一部が変形したもの



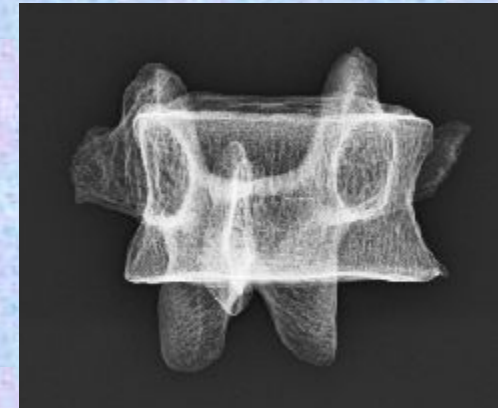
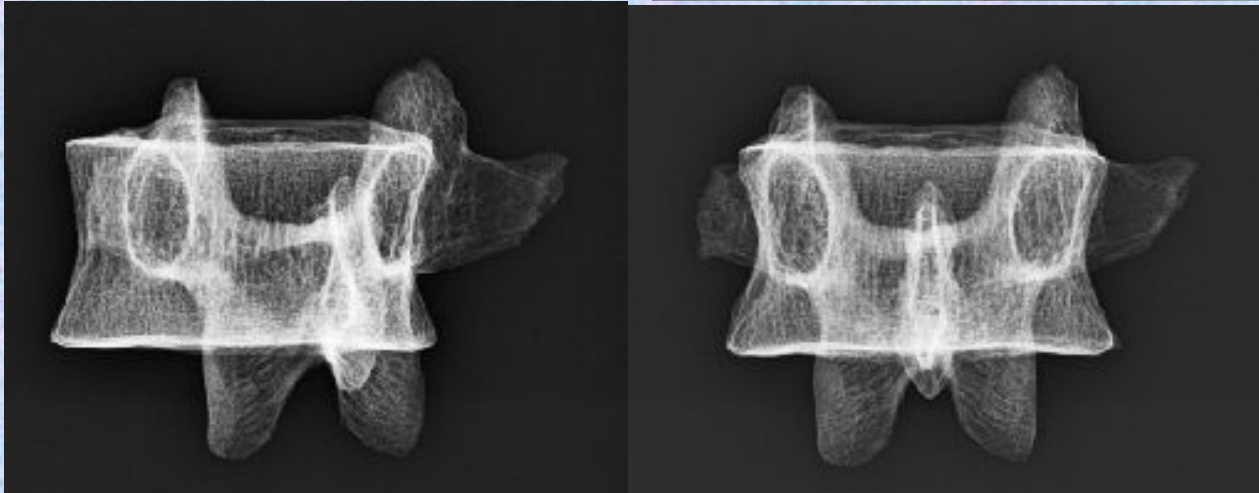
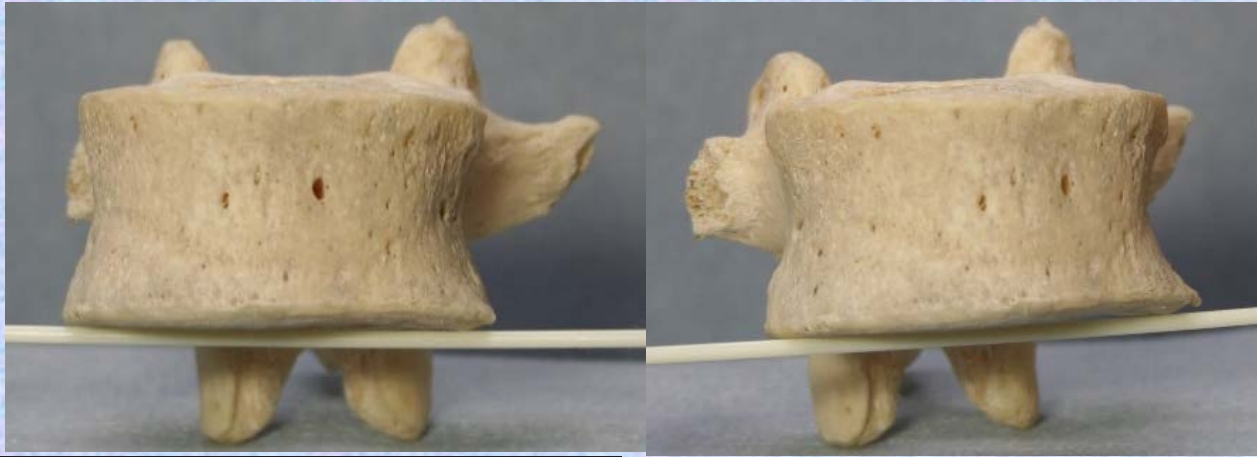
第2腰椎

Lumbar vertebra 2

L 2



腰椎 L 2 前面

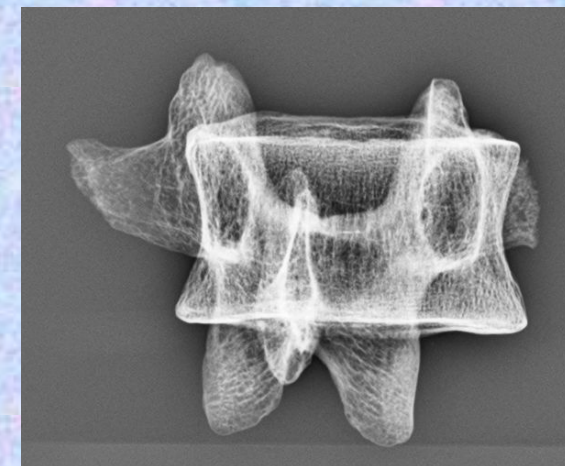
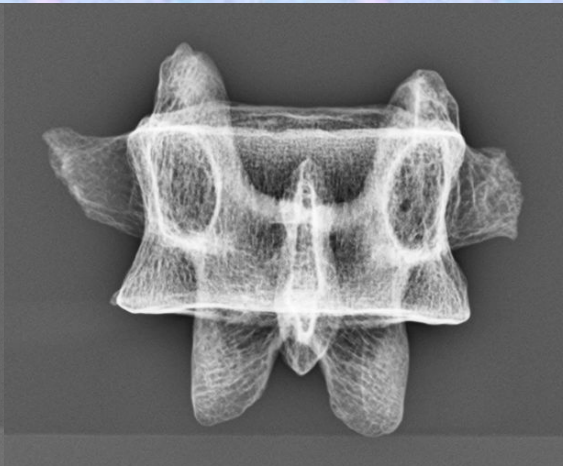
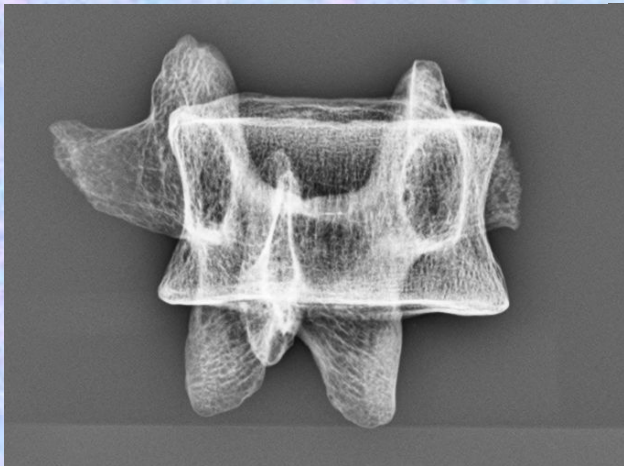
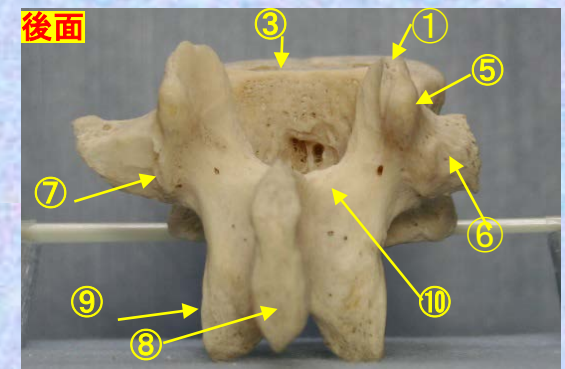
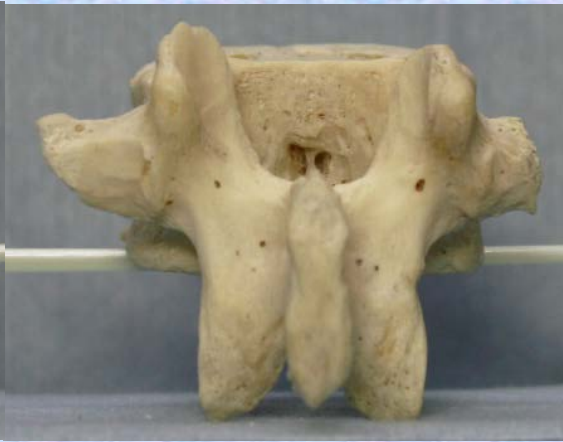
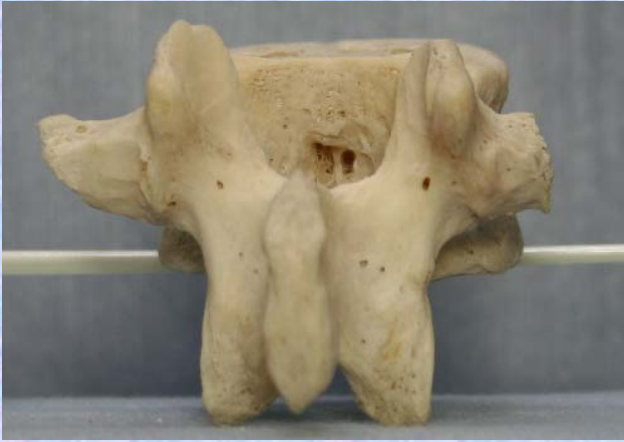
- | | |
|-----------------------------------|-----------------------------------|
| ①上関節突起 superior articular process | ⑧棘突起 spinous process |
| ②上椎切痕 superior vertebral notch | ⑨下関節突起 inferior articular process |
| ③椎体 transverse process | ⑩椎弓板 lamina |
| ④下椎切痕 inferior vertebral notch | ⑪椎孔 vertebral foramen |
| ⑤乳頭突起 mamillary process | ⑫椎弓根 pedicle |
| ⑥肋骨突起(横突起) transverse process | |
| ⑦副突起 accessory process | |

(注) 肋骨突起⑥の後ろの副突起⑦と乳頭突起⑤は、横突起の遺残を形成している。

腰椎の横突起は本来、この部の肋骨に相当するもので肋骨突起⑥といい、本来の横突起は上関節突起の外側から後方に向かう小さな隆起として残っており、乳頭突起⑤とよぶ。また、肋骨突起の根部の後面には下方に向かう小突起があり、副突起⑦というのが、これも本来の横突起の一部が変形したもの

腰椎 L 2 後面

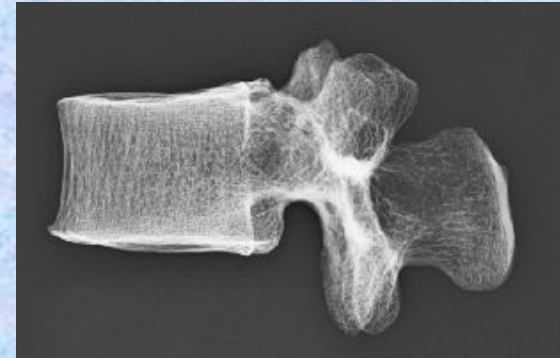
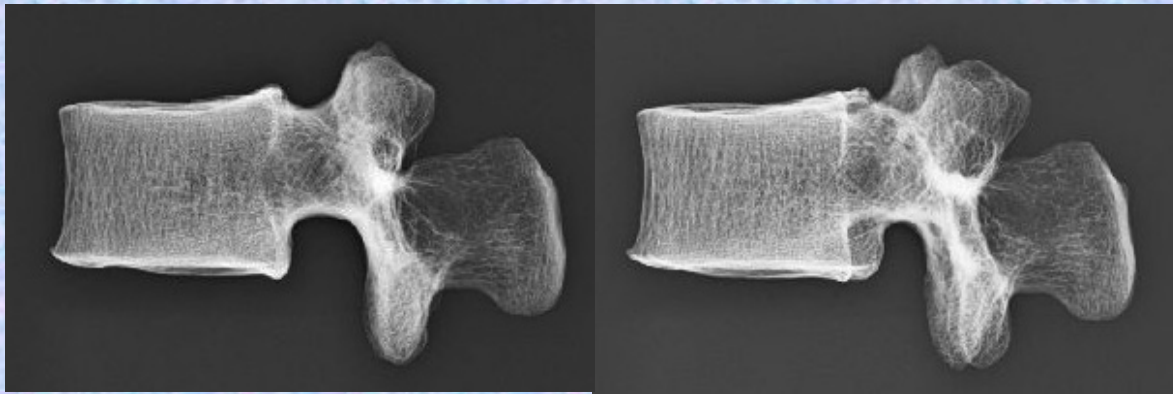



- | | |
|-----------------------------------|-----------------------------------|
| ①上関節突起 superior articular process | ⑧棘突起 spinous process |
| ②上椎切痕 superior vertebral notch | ⑨下関節突起 inferior articular process |
| ③椎体 transverse process | ⑩椎弓板 lamina |
| ④下椎切痕 inferior vertebral notch | ⑪椎孔 vertebral foramen |
| ⑤乳頭突起 mamillary process | ⑫椎弓根 pedicle |
| ⑥肋骨突起(横突起) transverse process | |
| ⑦副突起 accessory process | |

(注) 肋骨突起⑥の後ろの副突起⑦と乳頭突起⑤は、横突起の遺残を形成している。

腰椎の横突起は本来、この部の肋骨に相当するもので肋骨突起⑥といい、本来の横突起は上関節突起の外側から後方に向かう小さな隆起として残っており、乳頭突起⑤とよぶ。また、肋骨突起の根部の後面には下方に向かう小突起があり、副突起⑦というのが、これも本来の横突起の一部が変形したもの

腰椎 L 2 側面

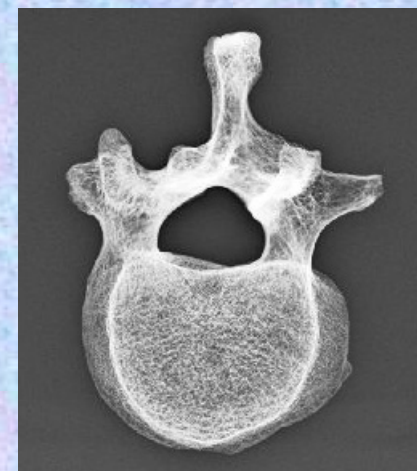
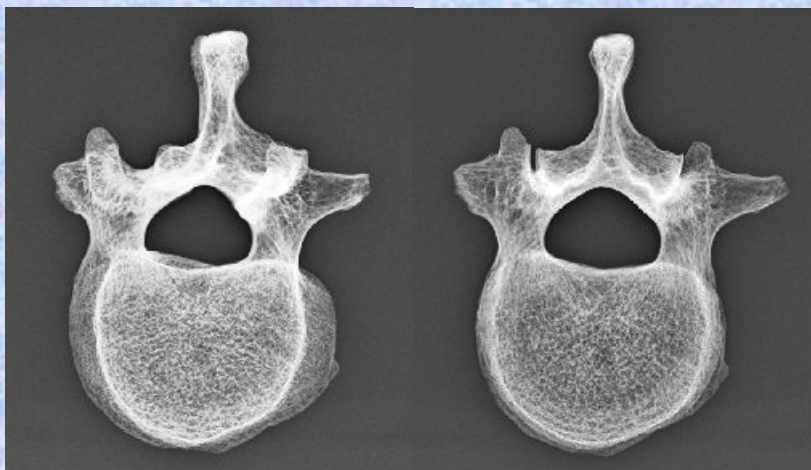
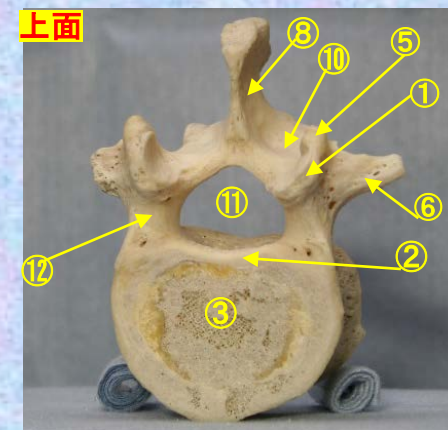
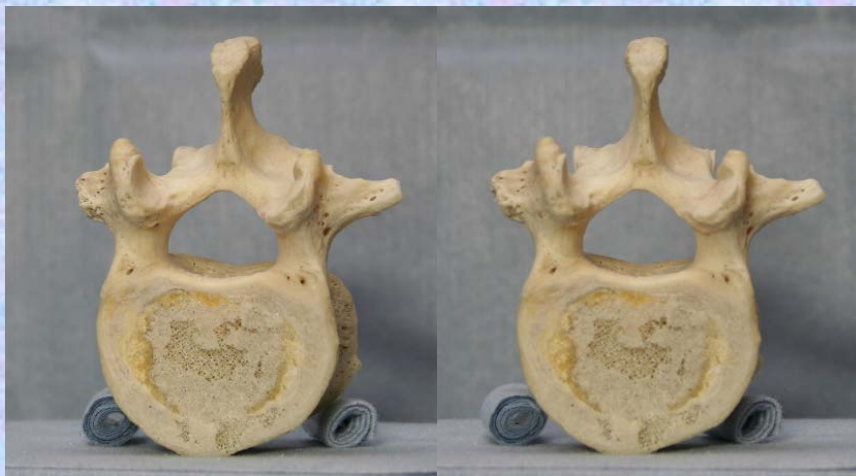

- | | |
|-----------------------------------|-----------------------------------|
| ①上関節突起 superior articular process | ⑧棘突起 spinous process |
| ②上椎切痕 superior vertebral notch | ⑨下関節突起 inferior articular process |
| ③椎体 transverse process | ⑩椎弓板 lamina |
| ④下椎切痕 inferior vertebral notch | ⑪椎孔 vertebral foramen |
| ⑤乳頭突起 mamillary process | ⑫椎弓根 pedicle |
| ⑥肋骨突起(横突起) transverse process | |
| ⑦副突起 accessory process | |

(注) 肋骨突起⑥の後ろの副突起⑦と乳頭突起⑤は、横突起の遺残を形成している。

腰椎の横突起は本来、この部の肋骨に相当するもので肋骨突起⑥といい、本来の横突起は上関節突起の外側から後方に向かう小さな隆起として残っており、乳頭突起⑤とよぶ。また、肋骨突起の根部の後面には下方に向かう小突起があり、副突起⑦というのが、これも本来の横突起の一部が変形したもの

腰椎 L 2 上面

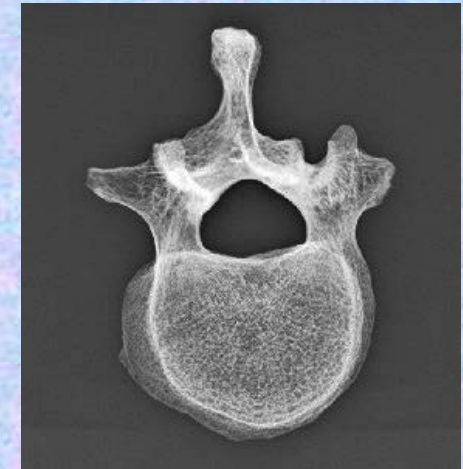
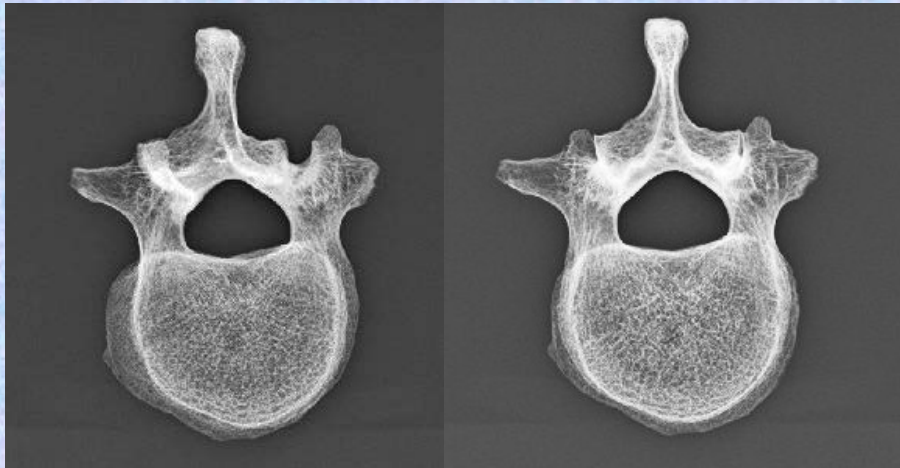
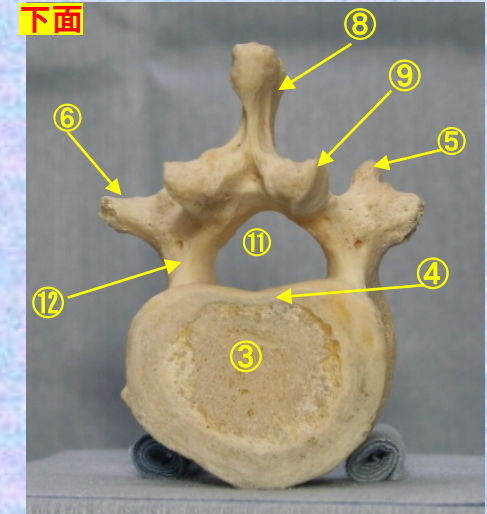
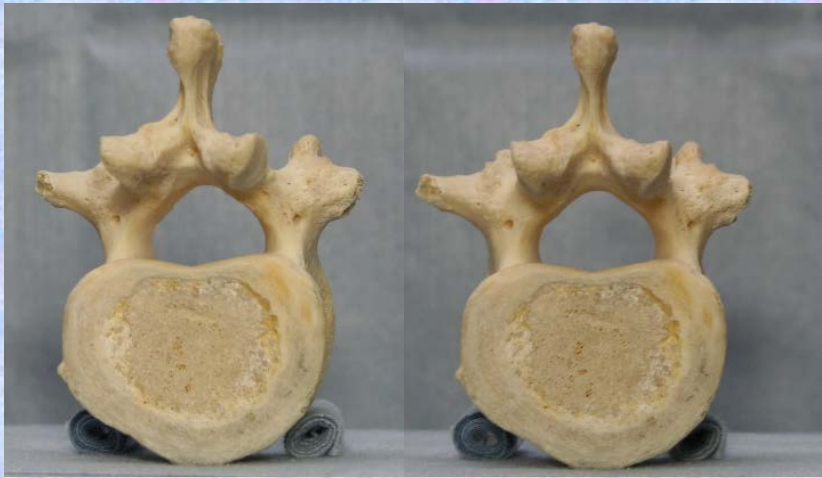

- | | |
|-----------------------------------|-----------------------------------|
| ①上関節突起 superior articular process | ⑧棘突起 spinous process |
| ②上椎切痕 superior vertebral notch | ⑨下関節突起 inferior articular process |
| ③椎体 transverse process | ⑩椎弓板 lamina |
| ④下椎切痕 inferior vertebral notch | ⑪椎孔 vertebral foramen |
| ⑤乳頭突起 mamillary process | ⑫椎弓根 pedicle |
| ⑥肋骨突起(横突起) transverse process | |
| ⑦副突起 accessory process | |

(注) 肋骨突起⑥の後ろの副突起⑦と乳頭突起⑤は、横突起の遺残を形成している。

腰椎の横突起は本来、この部の肋骨に相当するもので肋骨突起⑥といい、本来の横突起は上関節突起の外側から後方に向かう小さな隆起として残っており、乳頭突起⑤とよぶ。また、肋骨突起の根部の後面には下方に向かう小突起があり、副突起⑦というのが、これも本来の横突起の一部が変形したもの

腰椎 L 2 下面



- | | |
|-----------------------------------|-----------------------------------|
| ①上関節突起 superior articular process | ⑧棘突起 spinous process |
| ②上椎切痕 superior vertebral notch | ⑨下関節突起 inferior articular process |
| ③椎体 transverse process | ⑩椎弓板 lamina |
| ④下椎切痕 inferior vertebral notch | ⑪椎孔 vertebral foramen |
| ⑤乳頭突起 mamillary process | ⑫椎弓根 pedicle |
| ⑥肋骨突起(横突起) transverse process | |
| ⑦副突起 accessory process | |

(注) 肋骨突起⑥の後ろの副突起⑦と乳頭突起⑤は、横突起の遺残を形成している。

腰椎の横突起は本来、この部の肋骨に相当するもので肋骨突起⑥といい、本来の横突起は上関節突起の外側から後方に向かう小さな隆起として残っており、乳頭突起⑤とよぶ。また、肋骨突起の根部の後面には下方に向かう小突起があり、副突起⑦というのが、これも本来の横突起の一部が変形したもの

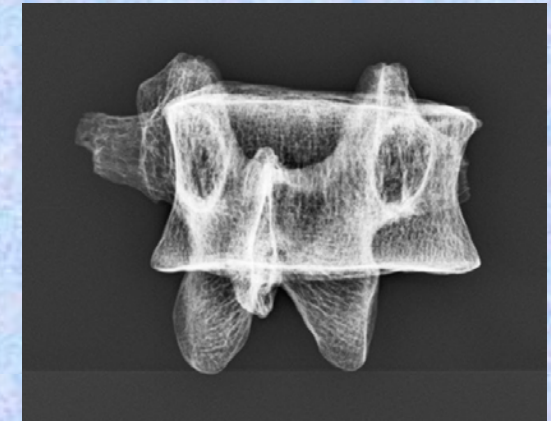
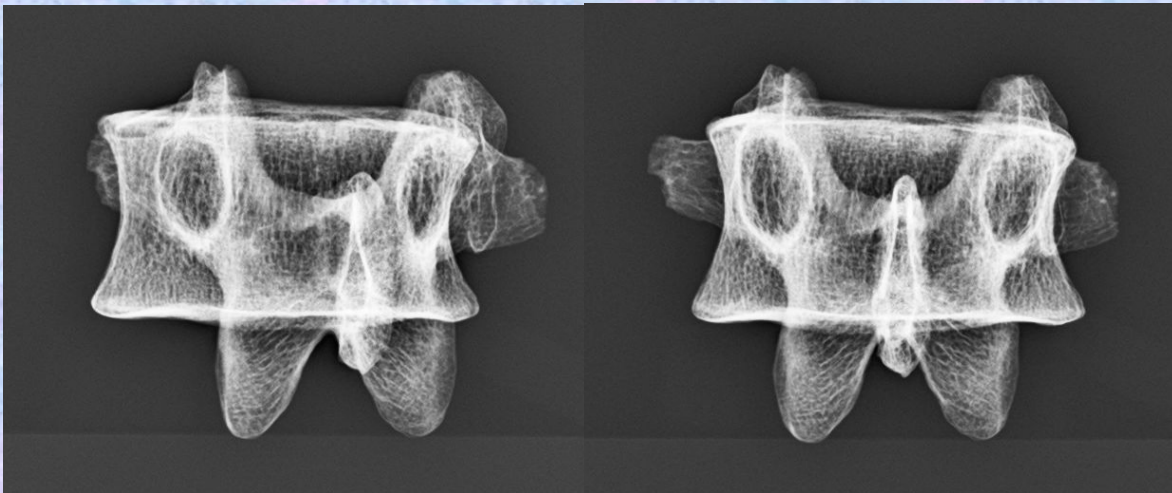
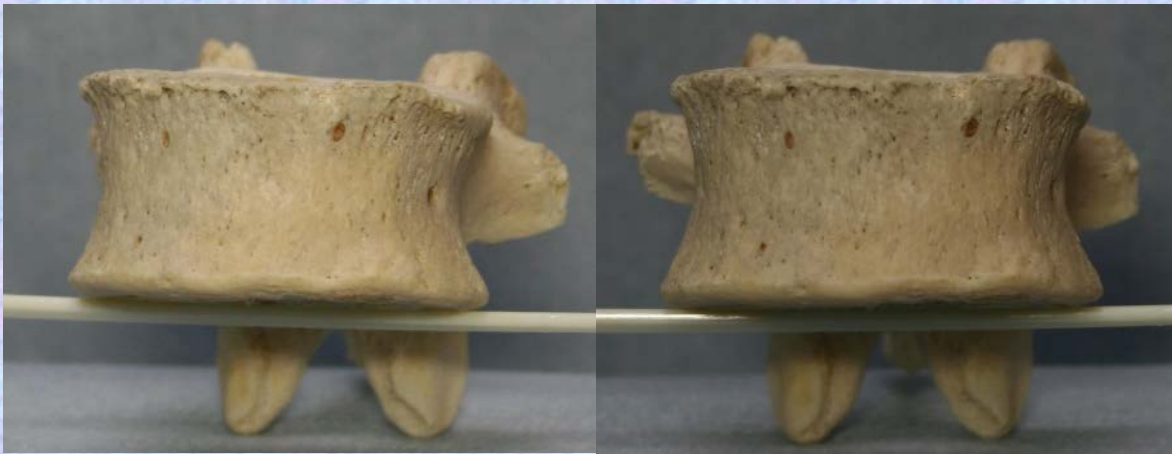
第3腰椎

Lumbar vertebra 3

L 3



腰椎 L 3 前面

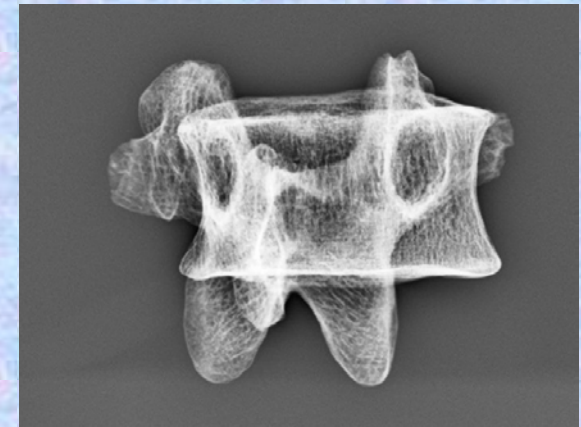
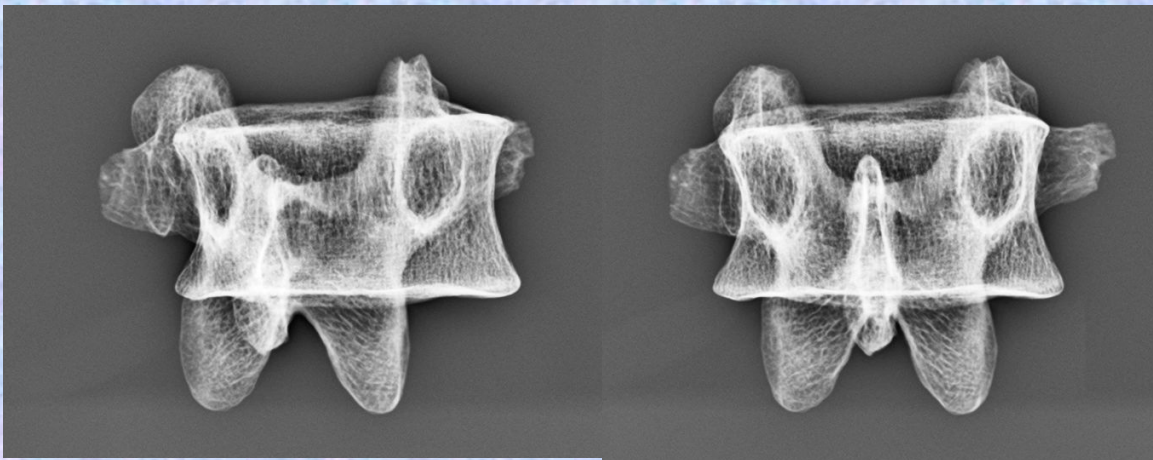
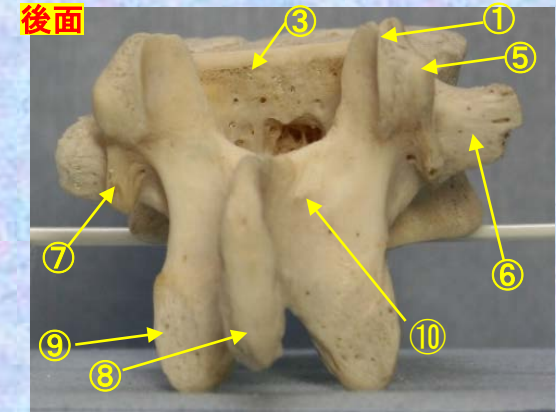
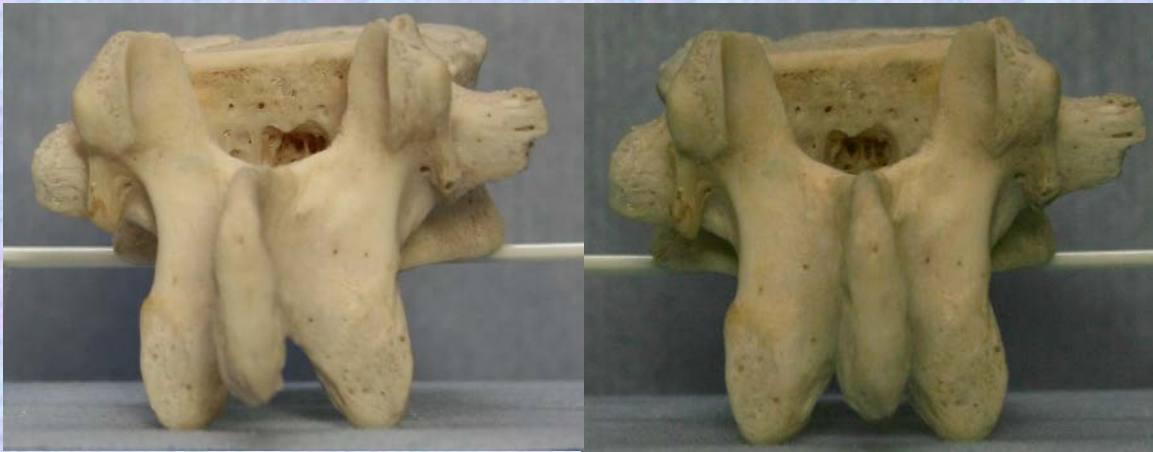

- | | |
|-----------------------------------|-----------------------------------|
| ①上関節突起 superior articular process | ⑧棘突起 spinous process |
| ②上椎切痕 superior vertebral notch | ⑨下関節突起 inferior articular process |
| ③椎体 transverse process | ⑩椎弓板 lamina |
| ④下椎切痕 inferior vertebral notch | ⑪椎孔 vertebral foramen |
| ⑤乳頭突起 mamillary process | ⑫椎弓根 pedicle |
| ⑥肋骨突起(横突起) transverse process | |
| ⑦副突起 accessory process | |

(注) 肋骨突起⑥の後ろの副突起⑦と乳頭突起⑤は、横突起の遺残を形成している。

腰椎の横突起は本来、この部の肋骨に相当するもので肋骨突起⑥といい、本来の横突起は上関節突起の外側から後方に向かう小さな隆起として残っており、乳頭突起⑤とよぶ。また、肋骨突起の根部の後面には下方に向かう小突起があり、副突起⑦というのが、これも本来の横突起の一部が変形したもの

腰椎 L 3 後面

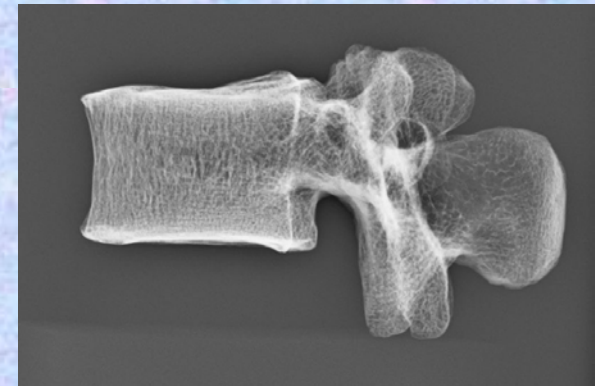
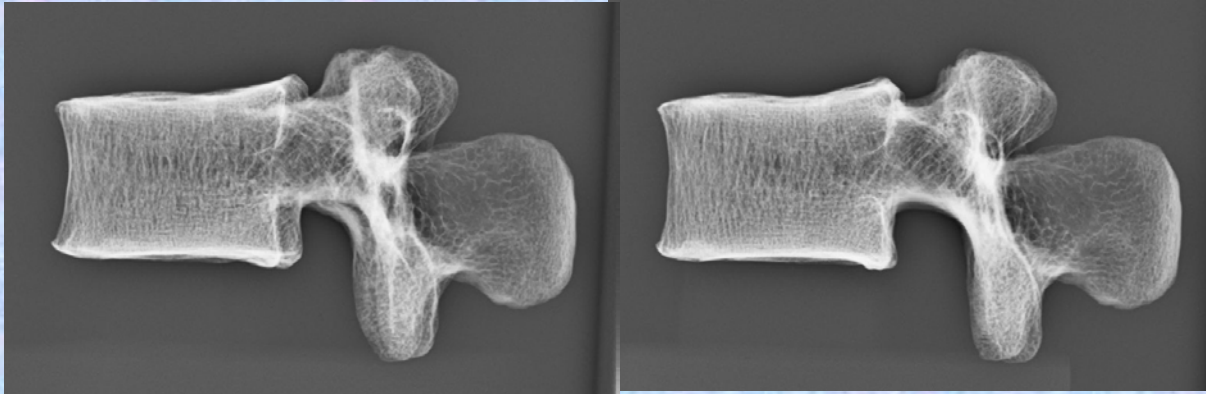



- | | |
|-----------------------------------|-----------------------------------|
| ①上関節突起 superior articular process | ⑧棘突起 spinous process |
| ②上椎切痕 superior vertebral notch | ⑨下関節突起 inferior articular process |
| ③椎体 transverse process | ⑩椎弓板 lamina |
| ④下椎切痕 inferior vertebral notch | ⑪椎孔 vertebral foramen |
| ⑤乳頭突起 mamillary process | ⑫椎弓根 pedicle |
| ⑥肋骨突起(横突起) transverse process | |
| ⑦副突起 accessory process | |

(注) 肋骨突起⑥の後ろの副突起⑦と乳頭突起⑤は、横突起の遺残を形成している。

腰椎の横突起は本来、この部の肋骨に相当するもので肋骨突起⑥といい、本来の横突起は上関節突起の外側から後方に向かう小さな隆起として残っており、乳頭突起⑤とよぶ。また、肋骨突起の根部の後面には下方に向かう小突起があり、副突起⑦というのが、これも本来の横突起の一部が変形したもの

腰椎 L 3 側面

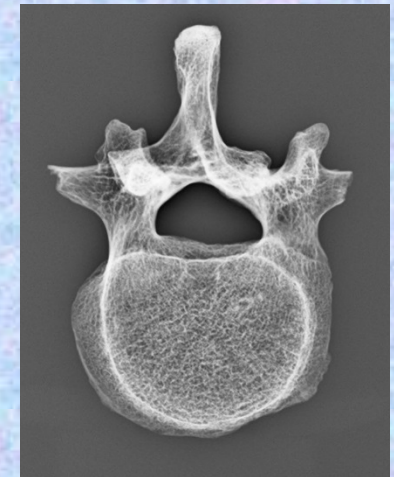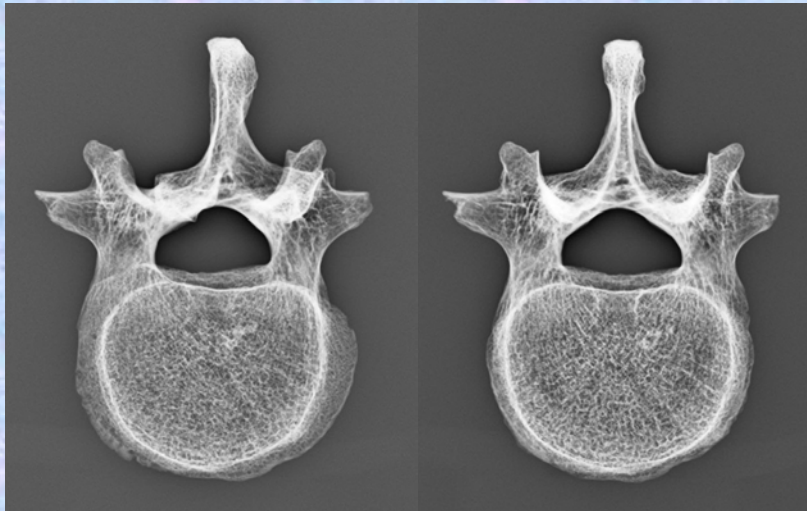
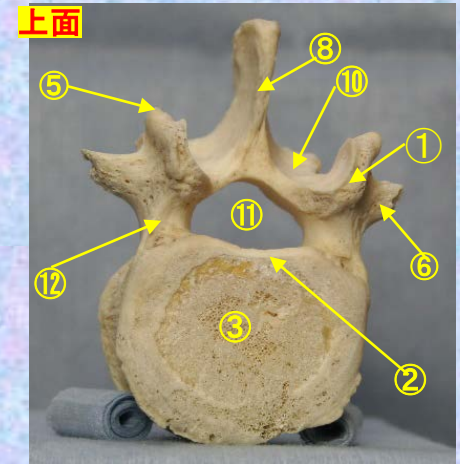

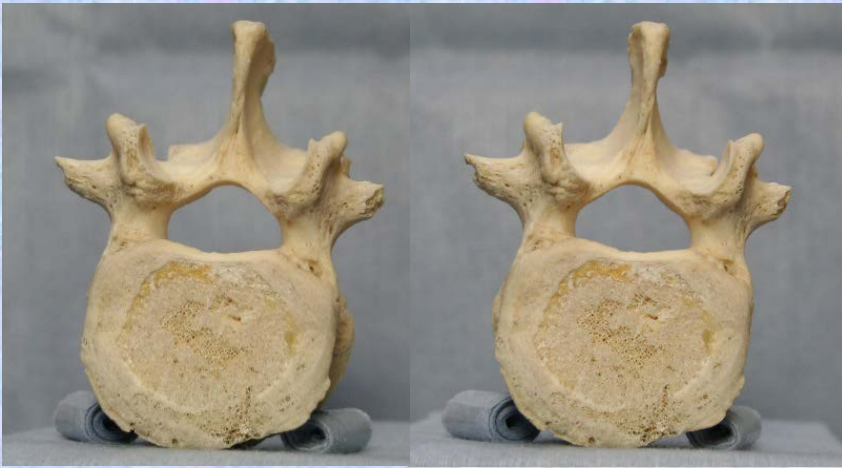
- | | |
|-----------------------------------|-----------------------------------|
| ①上関節突起 superior articular process | ⑧棘突起 spinous process |
| ②上椎切痕 superior vertebral notch | ⑨下関節突起 inferior articular process |
| ③椎体 transverse process | ⑩椎弓板 lamina |
| ④下椎切痕 inferior vertebral notch | ⑪椎孔 vertebral foramen |
| ⑤乳頭突起 mamillary process | ⑫椎弓根 pedicle |
| ⑥肋骨突起(横突起) transverse process | |
| ⑦副突起 accessory process | |

(注) 肋骨突起⑥の後ろの副突起⑦と乳頭突起⑤は、横突起の遺残を形成している。

腰椎の横突起は本来、この部の肋骨に相当するもので肋骨突起⑥といい、本来の横突起は上関節突起の外側から後方に向かう小さな隆起として残っており、乳頭突起⑤とよぶ。また、肋骨突起の根部の後面には下方に向かう小突起があり、副突起⑦というのが、これも本来の横突起の一部が変形したもの

腰椎 L 3 上面

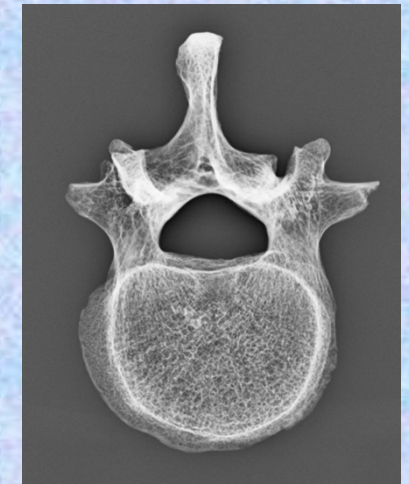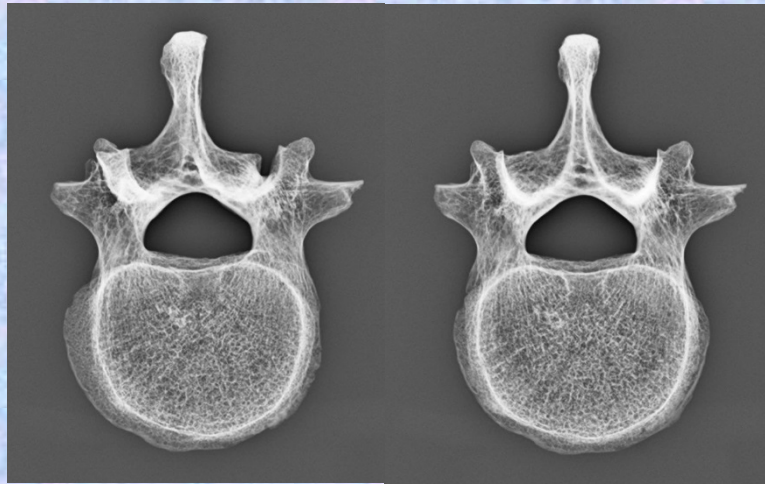
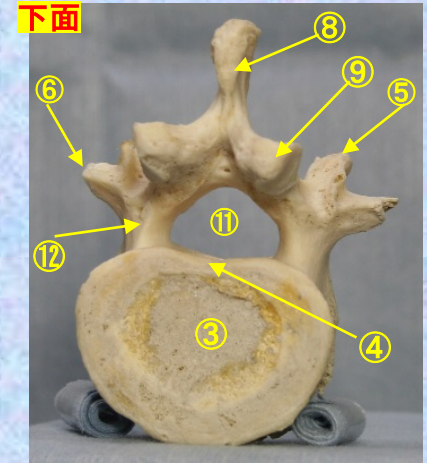

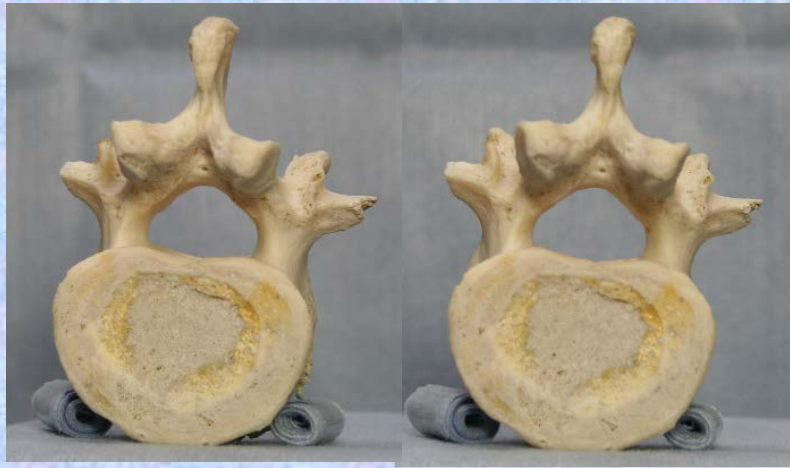
- | | |
|-----------------------------------|-----------------------------------|
| ①上関節突起 superior articular process | ⑧棘突起 spinous process |
| ②上椎切痕 superior vertebral notch | ⑨下関節突起 inferior articular process |
| ③椎体 transverse process | ⑩椎弓板 lamina |
| ④下椎切痕 inferior vertebral notch | ⑪椎孔 vertebral foramen |
| ⑤乳頭突起 mamillary process | ⑫椎弓根 pedicle |
| ⑥肋骨突起(横突起) transverse process | |
| ⑦副突起 accessory process | |

(注) 肋骨突起⑥の後ろの副突起⑦と乳頭突起⑤は、横突起の遺残を形成している。

腰椎の横突起は本来、この部の肋骨に相当するもので肋骨突起⑥といい、本来の横突起は上関節突起の外側から後方に向かう小さな隆起として残っており、乳頭突起⑤とよぶ。また、肋骨突起の根部の後面には下方に向かう小突起があり、副突起⑦というのが、これも本来の横突起の一部が変形したもの

腰椎 L 3 下面



- | | |
|-----------------------------------|-----------------------------------|
| ①上関節突起 superior articular process | ⑧棘突起 spinous process |
| ②上椎切痕 superior vertebral notch | ⑨下関節突起 inferior articular process |
| ③椎体 transverse process | ⑩椎弓板 lamina |
| ④下椎切痕 inferior vertebral notch | ⑪椎孔 vertebral foramen |
| ⑤乳頭突起 mamillary process | ⑫椎弓根 pedicle |
| ⑥肋骨突起(横突起) transverse process | |
| ⑦副突起 accessory process | |

(注) 肋骨突起⑥の後ろの副突起⑦と乳頭突起⑤は、横突起の遺残を形成している。

腰椎の横突起は本来、この部の肋骨に相当するもので肋骨突起⑥といい、本来の横突起は上関節突起の外側から後方に向かう小さな隆起として残っており、乳頭突起⑤とよぶ。また、肋骨突起の根部の後面には下方に向かう小突起があり、副突起⑦というのが、これも本来の横突起の一部が変形したもの

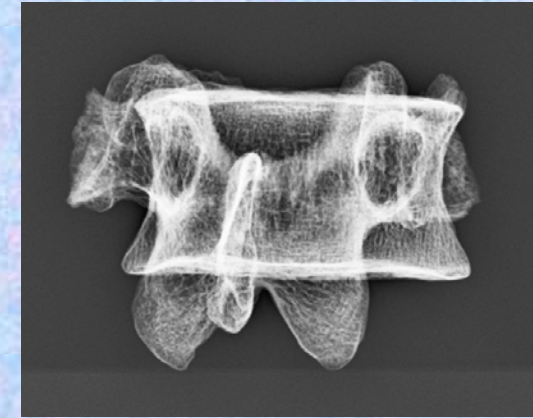
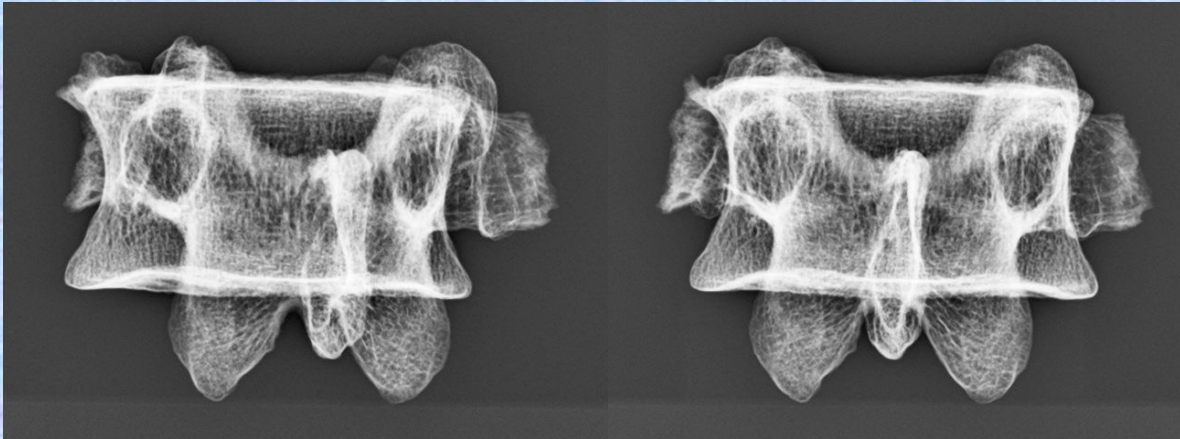
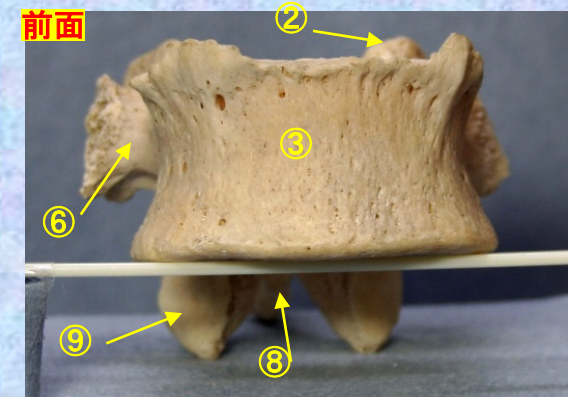
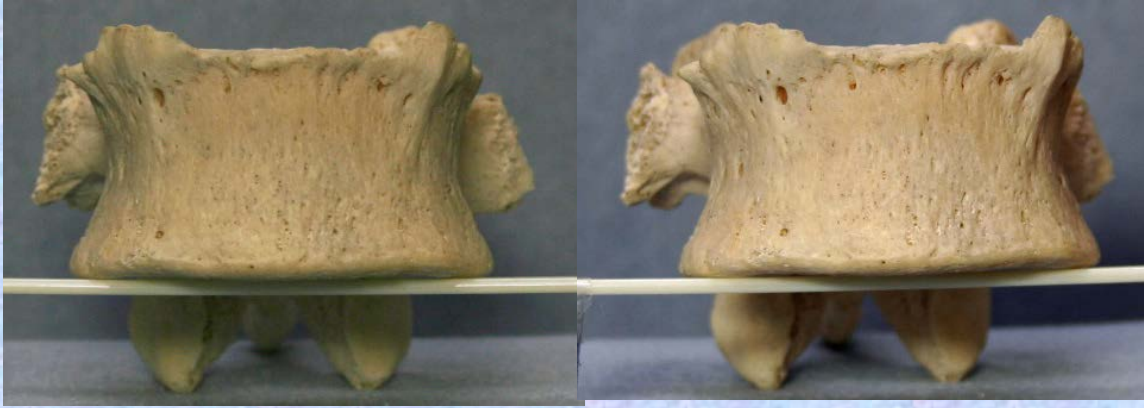第4腰椎

Lumbar vertebra 4

L 4



腰椎 L 4 前面

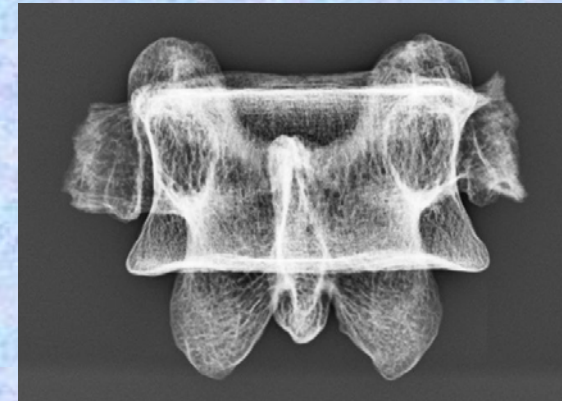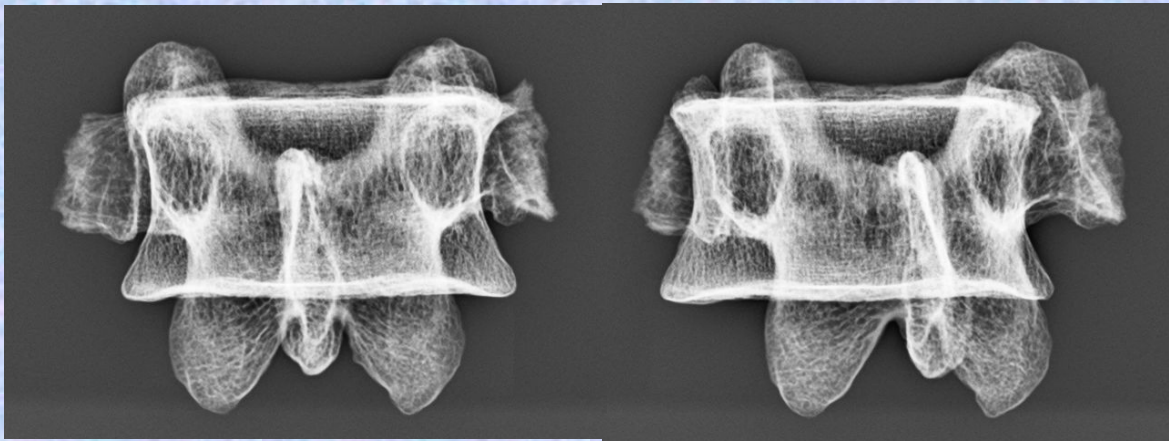
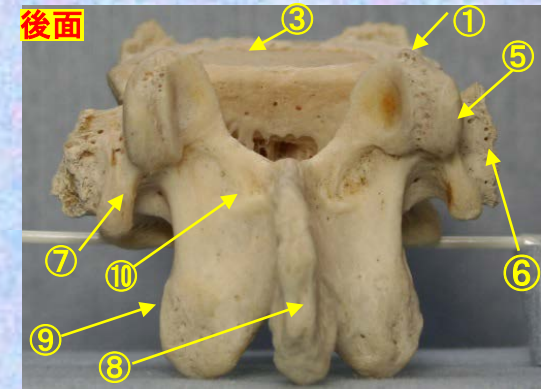

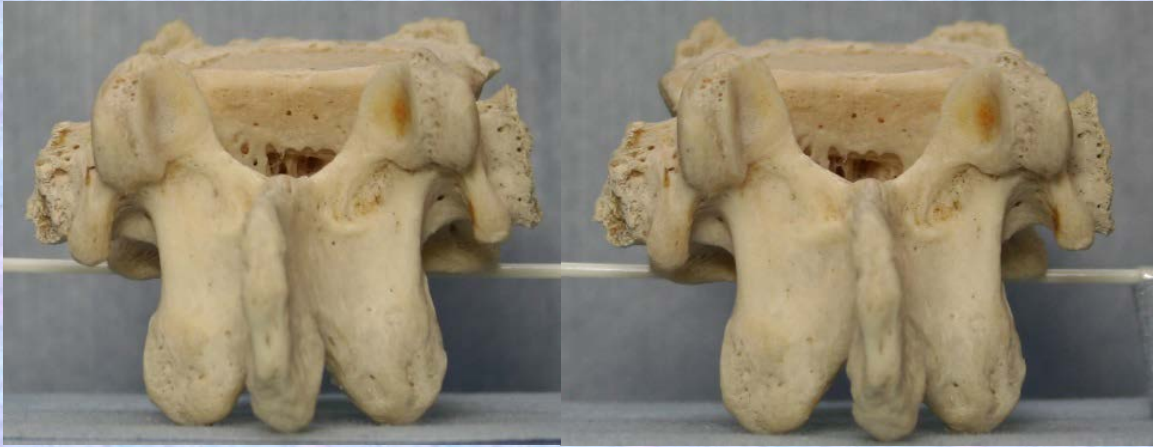
- | | |
|-----------------------------------|-----------------------------------|
| ①上関節突起 superior articular process | ⑧棘突起 spinous process |
| ②上椎切痕 superior vertebral notch | ⑨下関節突起 inferior articular process |
| ③椎体 transverse process | ⑩椎弓板 lamina |
| ④下椎切痕 inferior vertebral notch | ⑪椎孔 vertebral foramen |
| ⑤乳頭突起 mamillary process | ⑫椎弓根 pedicle |
| ⑥肋骨突起(横突起) transverse process | |
| ⑦副突起 accessory process | |

(注) 肋骨突起⑥の後ろの副突起⑦と乳頭突起⑤は、横突起の遺残を形成している。

腰椎の横突起は本来、この部の肋骨に相当するもので肋骨突起⑥といい、本来の横突起は上関節突起の外側から後方に向かう小さな隆起として残っており、乳頭突起⑤とよぶ。また、肋骨突起の根部の後面には下方に向かう小突起があり、副突起⑦というのが、これも本来の横突起の一部が変形したもの

腰椎 L 4 後面

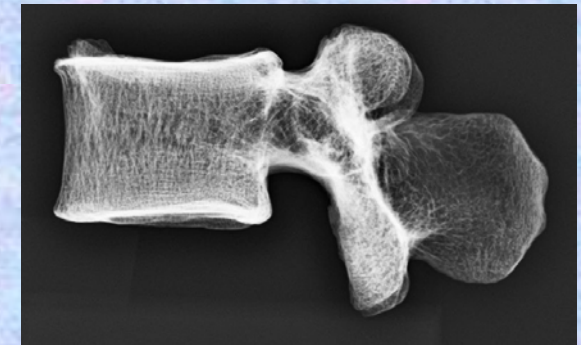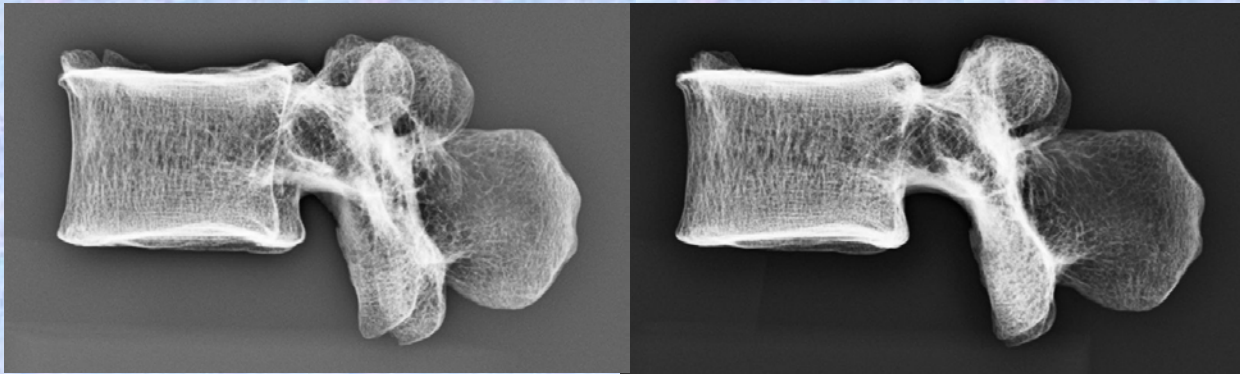
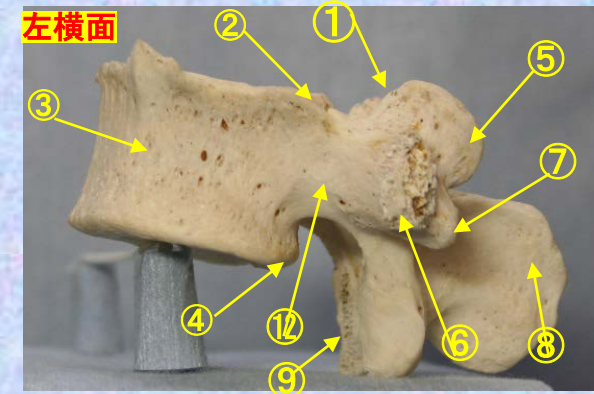


- | | |
|-----------------------------------|-----------------------------------|
| ①上関節突起 superior articular process | ⑧棘突起 spinous process |
| ②上椎切痕 superior vertebral notch | ⑨下関節突起 inferior articular process |
| ③椎体 transverse process | ⑩椎弓板 lamina |
| ④下椎切痕 inferior vertebral notch | ⑪椎孔 vertebral foramen |
| ⑤乳頭突起 mamillary process | ⑫椎弓根 pedicle |
| ⑥肋骨突起(横突起) transverse process | |
| ⑦副突起 accessory process | |

(注) 肋骨突起⑥の後ろの副突起⑦と乳頭突起⑤は、横突起の遺残を形成している。

腰椎の横突起は本来、この部の肋骨に相当するもので肋骨突起⑥といい、本来の横突起は上関節突起の外側から後方に向かう小さな隆起として残っており、乳頭突起⑤とよぶ。また、肋骨突起の根部の後面には下方に向かう小突起があり、副突起⑦というのが、これも本来の横突起の一部が変形したもの

腰椎 L 4 側面

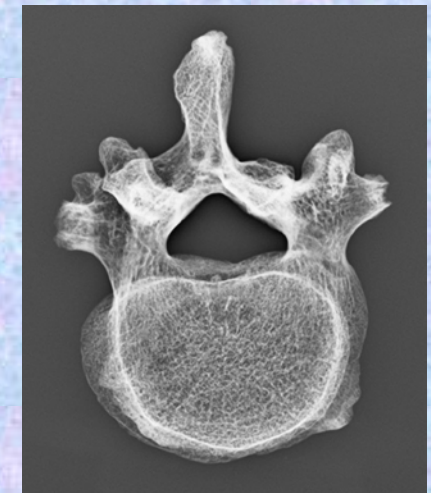
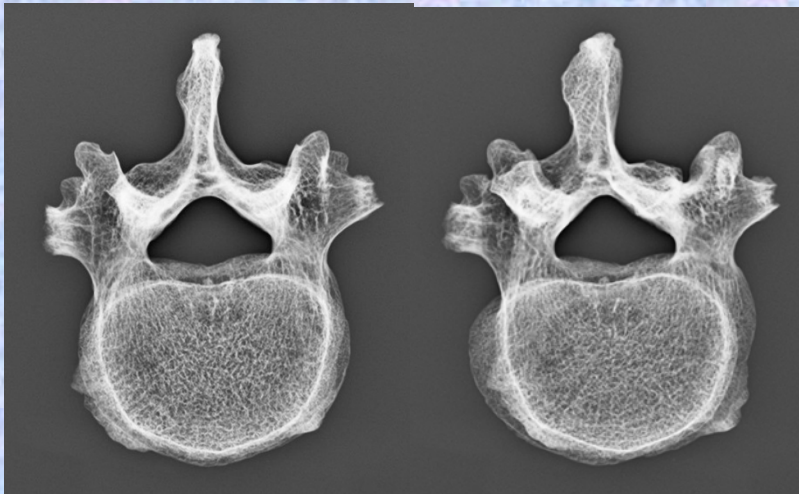
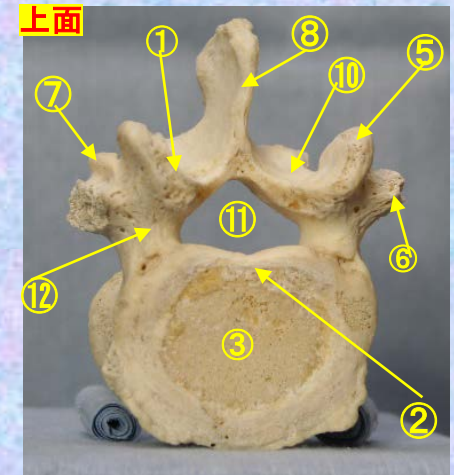
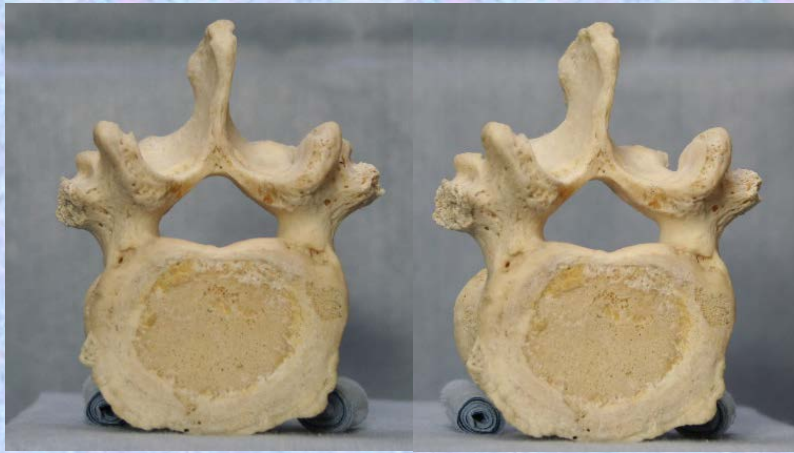

- | | |
|-----------------------------------|-----------------------------------|
| ①上関節突起 superior articular process | ⑧棘突起 spinous process |
| ②上椎切痕 superior vertebral notch | ⑨下関節突起 inferior articular process |
| ③椎体 transverse process | ⑩椎弓板 lamina |
| ④下椎切痕 inferior vertebral notch | ⑪椎孔 vertebral foramen |
| ⑤乳頭突起 mamillary process | ⑫椎弓根 pedicle |
| ⑥肋骨突起(横突起) transverse process | |
| ⑦副突起 accessory process | |

(注) 肋骨突起⑥の後ろの副突起⑦と乳頭突起⑤は、横突起の遺残を形成している。

腰椎の横突起は本来、この部の肋骨に相当するもので肋骨突起⑥といい、本来の横突起は上関節突起の外側から後方に向かう小さな隆起として残っており、乳頭突起⑤とよぶ。また、肋骨突起の根部の後面には下方に向かう小突起があり、副突起⑦というのが、これも本来の横突起の一部が変形したもの

腰椎 L 4 上面

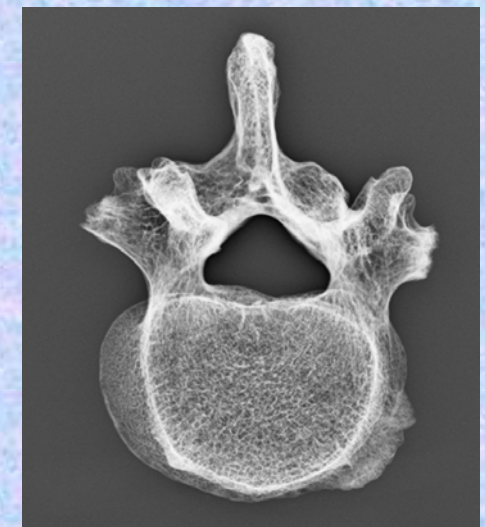
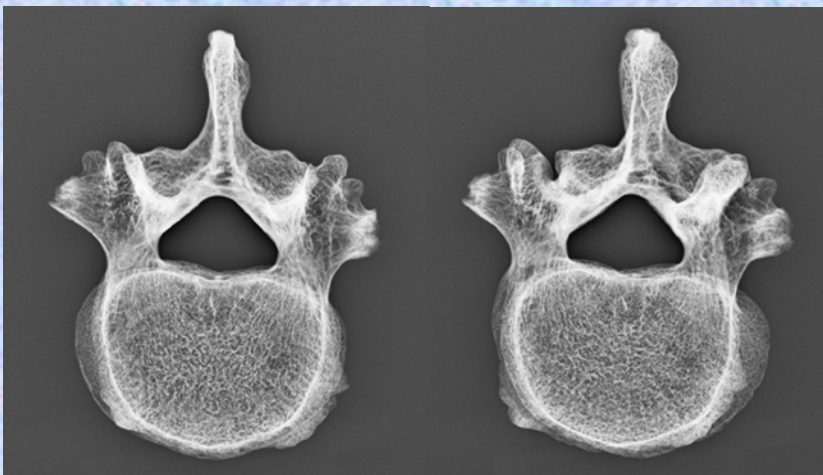
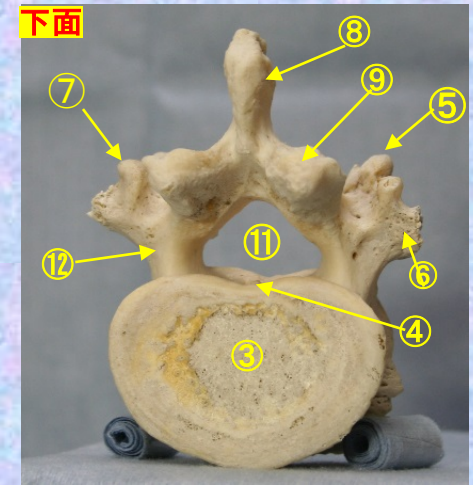
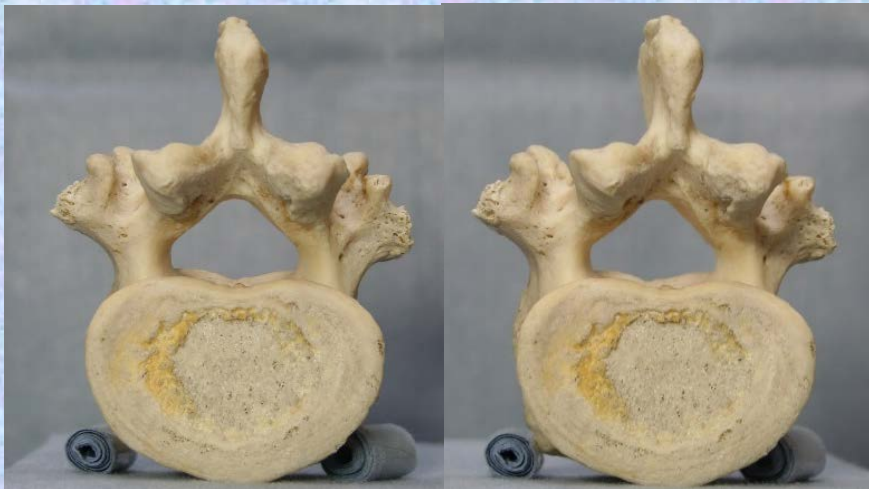

- | | |
|-----------------------------------|-----------------------------------|
| ①上関節突起 superior articular process | ⑧棘突起 spinous process |
| ②上椎切痕 superior vertebral notch | ⑨下関節突起 inferior articular process |
| ③椎体 transverse process | ⑩椎弓板 lamina |
| ④下椎切痕 inferior vertebral notch | ⑪椎孔 vertebral foramen |
| ⑤乳頭突起 mamillary process | ⑫椎弓根 pedicle |
| ⑥肋骨突起(横突起) transverse process | |
| ⑦副突起 accessory process | |

(注) 肋骨突起⑥の後ろの副突起⑦と乳頭突起⑤は、横突起の遺残を形成している。

腰椎の横突起は本来、この部の肋骨に相当するもので肋骨突起⑥といい、本来の横突起は上関節突起の外側から後方に向かう小さな隆起として残っており、乳頭突起⑤とよぶ。また、肋骨突起の根部の後面には下方に向かう小突起があり、副突起⑦というのが、これも本来の横突起の一部が変形したもの

腰椎 L 4 下面



- | | |
|-----------------------------------|-----------------------------------|
| ①上関節突起 superior articular process | ⑧棘突起 spinous process |
| ②上椎切痕 superior vertebral notch | ⑨下関節突起 inferior articular process |
| ③椎体 transverse process | ⑩椎弓板 lamina |
| ④下椎切痕 inferior vertebral notch | ⑪椎孔 vertebral foramen |
| ⑤乳頭突起 mamillary process | ⑫椎弓根 pedicle |
| ⑥肋骨突起(横突起) transverse process | |
| ⑦副突起 accessory process | |

(注) 肋骨突起⑥の後ろの副突起⑦と乳頭突起⑤は、横突起の遺残を形成している。

腰椎の横突起は本来、この部の肋骨に相当するもので肋骨突起⑥といい、本来の横突起は上関節突起の外側から後方に向かう小さな隆起として残っており、乳頭突起⑤とよぶ。また、肋骨突起の根部の後面には下方に向かう小突起があり、副突起⑦というのが、これも本来の横突起の一部が変形したもの

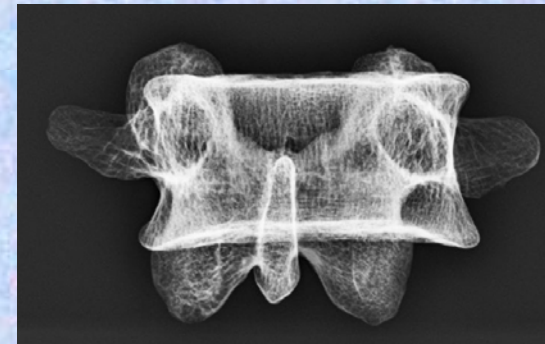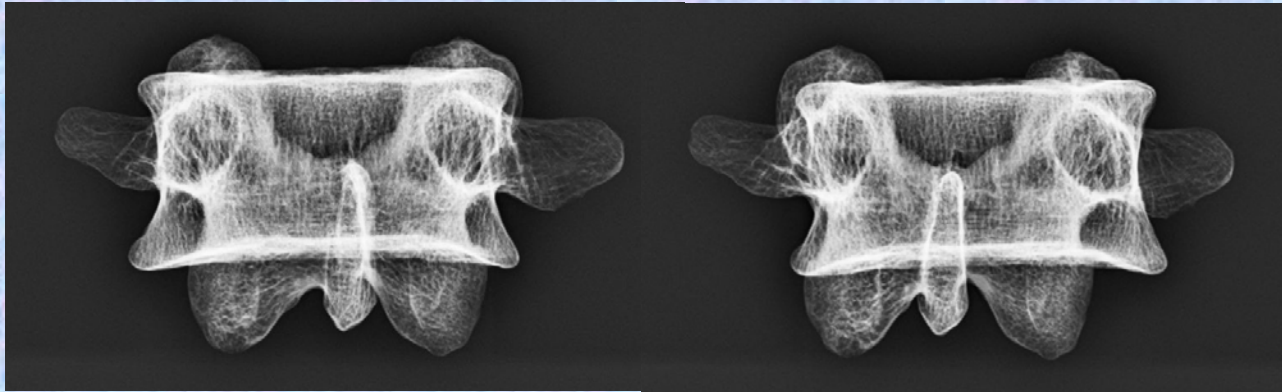

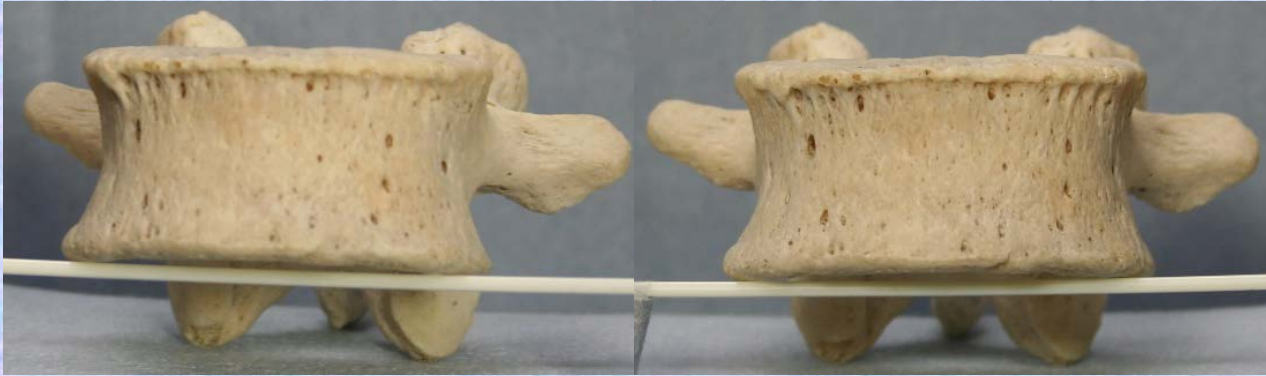第5腰椎

Lumbar vertebra 5

L 5



腰椎 L 5 前面

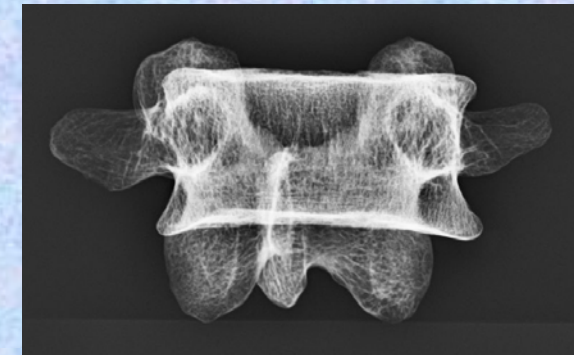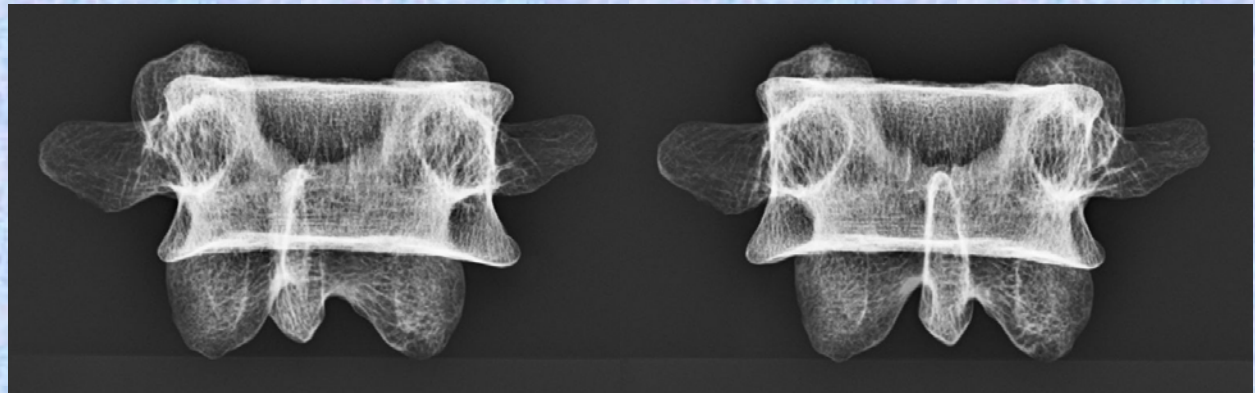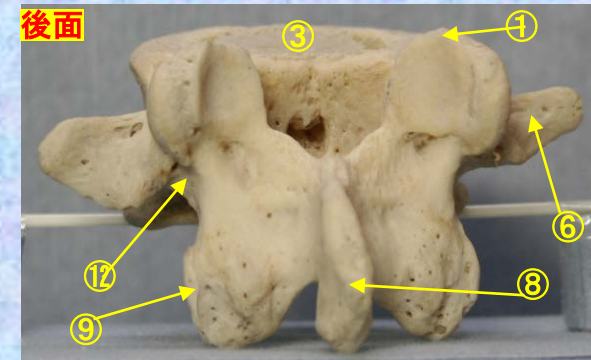


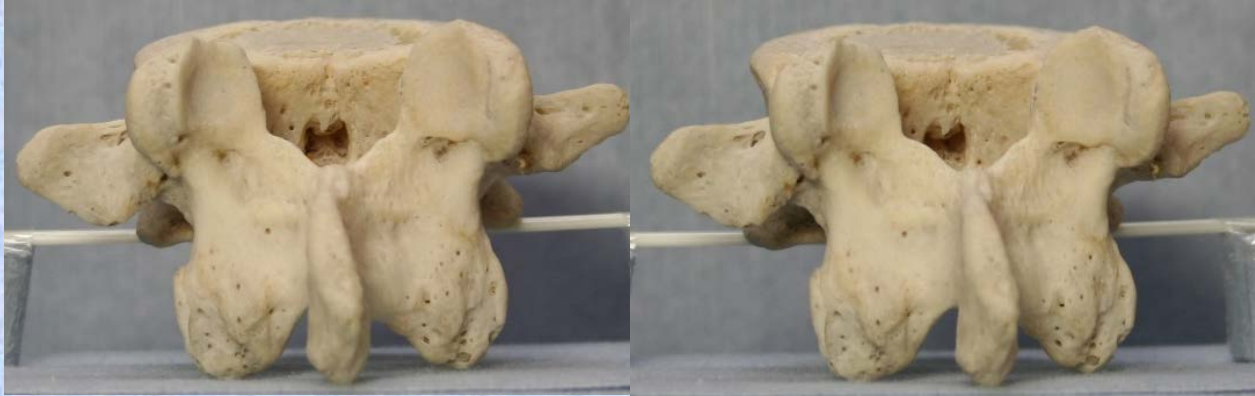- | | |
|-----------------------------------|-----------------------------------|
| ①上関節突起 superior articular process | ⑧棘突起 spinous process |
| ②上椎切痕 superior vertebral notch | ⑨下関節突起 inferior articular process |
| ③椎体 transverse process | ⑩椎弓板 lamina |
| ④下椎切痕 inferior vertebral notch | ⑪椎孔 vertebral foramen |
| ⑤乳頭突起 mamillary process | ⑫椎弓根 pedicle |
| ⑥肋骨突起(横突起) transverse process | |
| ⑦副突起 accessory process | |

(注) 肋骨突起⑥の後ろの副突起⑦と乳頭突起⑤は、横突起の遺残を形成している。

腰椎の横突起は本来、この部の肋骨に相当するもので肋骨突起⑥といい、本来の横突起は上関節突起の外側から後方に向かう小さな隆起として残っており、乳頭突起⑤とよぶ。また、肋骨突起の根部の後面には下方に向かう小突起があり、副突起⑦というのが、これも本来の横突起の一部が変形したもの

腰椎 L 5 後面

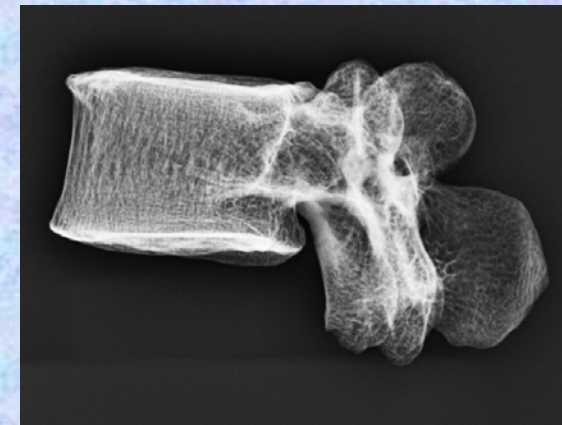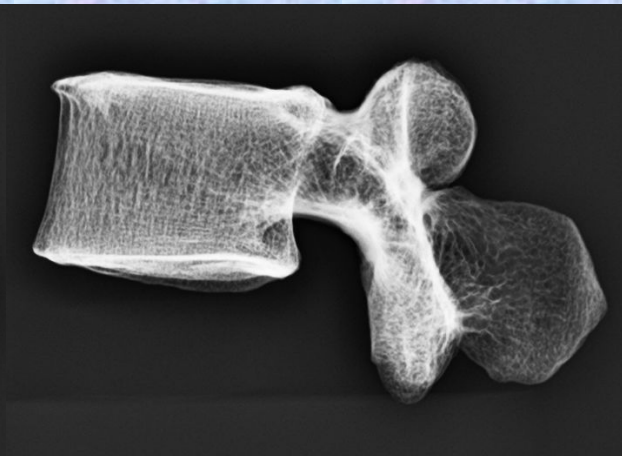
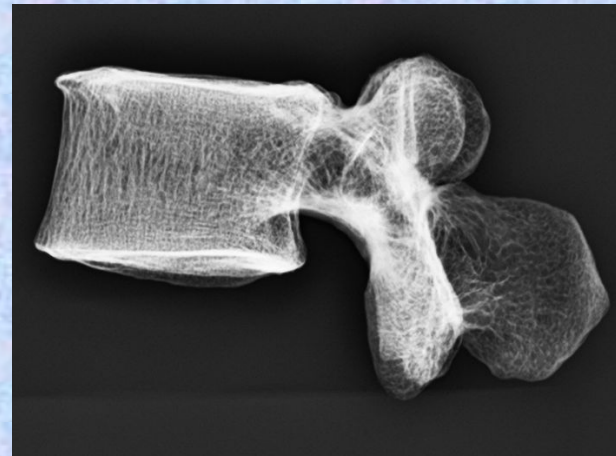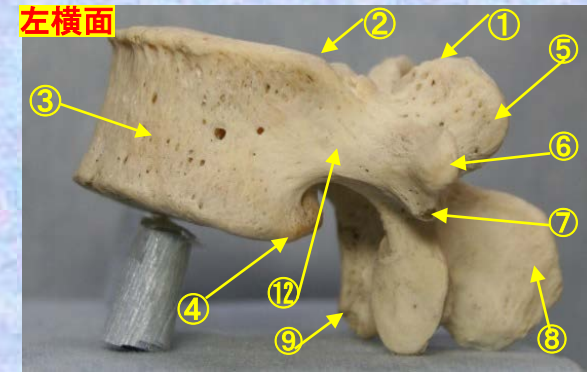


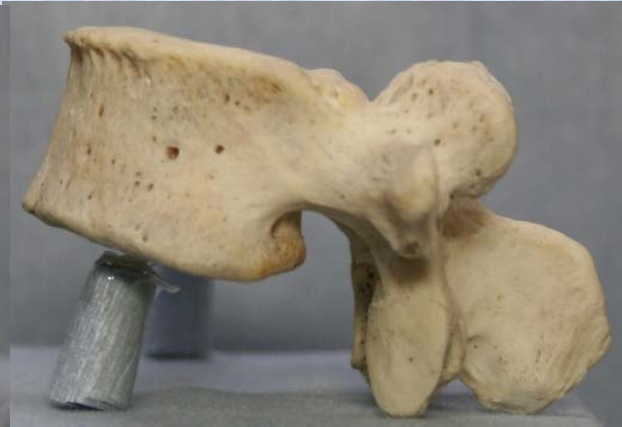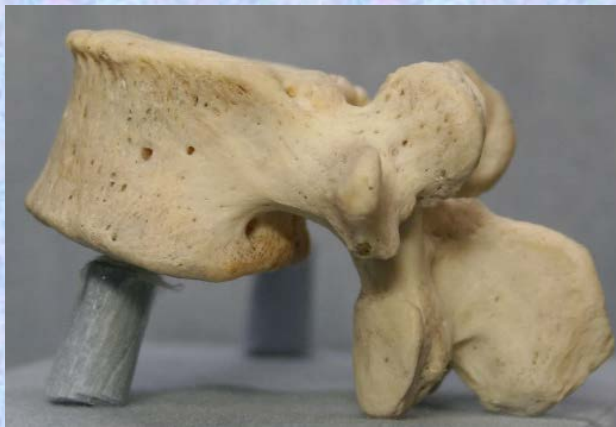- | | |
|-----------------------------------|-----------------------------------|
| ①上関節突起 superior articular process | ⑧棘突起 spinous process |
| ②上椎切痕 superior vertebral notch | ⑨下関節突起 inferior articular process |
| ③椎体 transverse process | ⑩椎弓板 lamina |
| ④下椎切痕 inferior vertebral notch | ⑪椎孔 vertebral foramen |
| ⑤乳頭突起 mamillary process | ⑫椎弓根 pedicle |
| ⑥肋骨突起(横突起) transverse process | |
| ⑦副突起 accessory process | |

(注) 肋骨突起⑥の後ろの副突起⑦と乳頭突起⑤は、横突起の遺残を形成している。

腰椎の横突起は本来、この部の肋骨に相当するもので肋骨突起⑥といい、本来の横突起は上関節突起の外側から後方に向かう小さな隆起として残っており、乳頭突起⑤とよぶ。また、肋骨突起の根部の後面には下方に向かう小突起があり、副突起⑦というのが、これも本来の横突起の一部が変形したもの

腰椎 L 5 側面

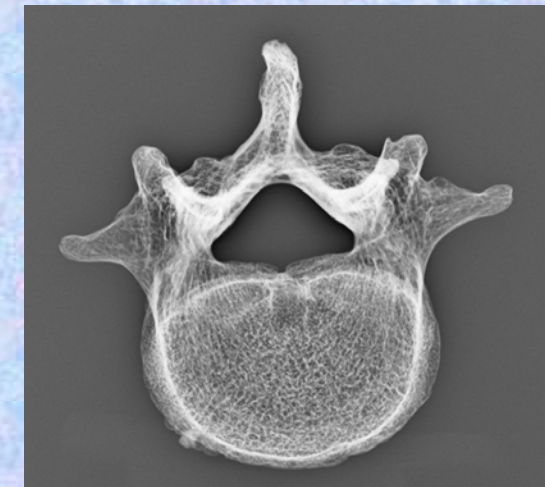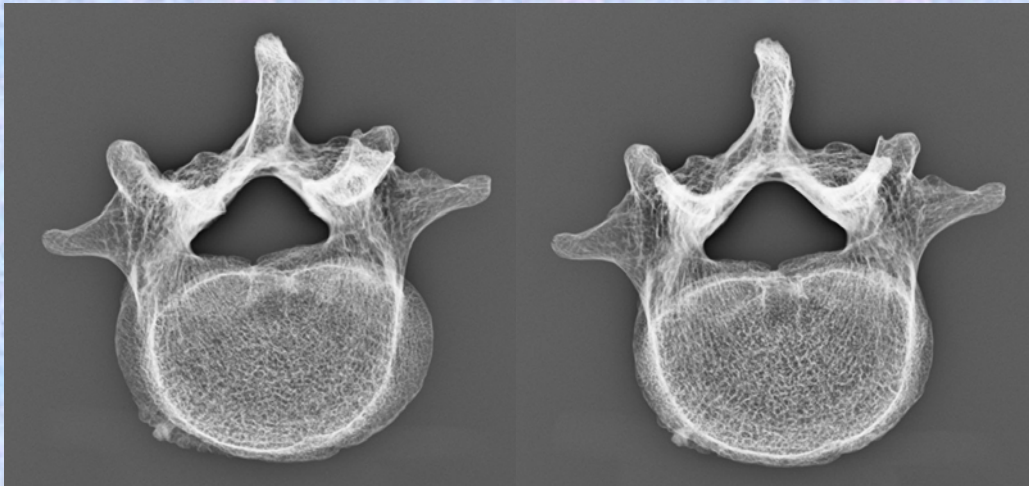
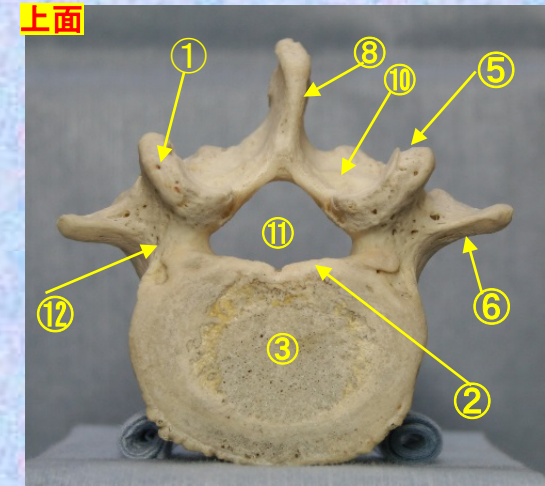

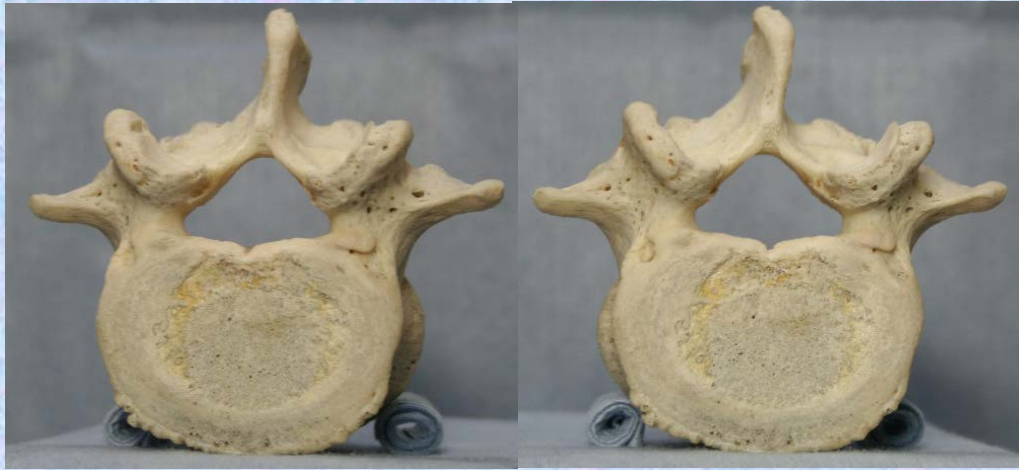
- | | |
|-----------------------------------|-----------------------------------|
| ①上関節突起 superior articular process | ⑧棘突起 spinous process |
| ②上椎切痕 superior vertebral notch | ⑨下関節突起 inferior articular process |
| ③椎体 transverse process | ⑩椎弓板 lamina |
| ④下椎切痕 inferior vertebral notch | ⑪椎孔 vertebral foramen |
| ⑤乳頭突起 mamillary process | ⑫椎弓根 pedicle |
| ⑥肋骨突起(横突起) transverse process | |
| ⑦副突起 accessory process | |

(注) 肋骨突起⑥の後ろの副突起⑦と乳頭突起⑤は、横突起の遺残を形成している。

腰椎の横突起は本来、この部の肋骨に相当するもので肋骨突起⑥といい、本来の横突起は上関節突起の外側から後方に向かう小さな隆起として残っており、乳頭突起⑤とよぶ。また、肋骨突起の根部の後面には下方に向かう小突起があり、副突起⑦というのが、これも本来の横突起の一部が変形したもの

腰椎 L 5 上面

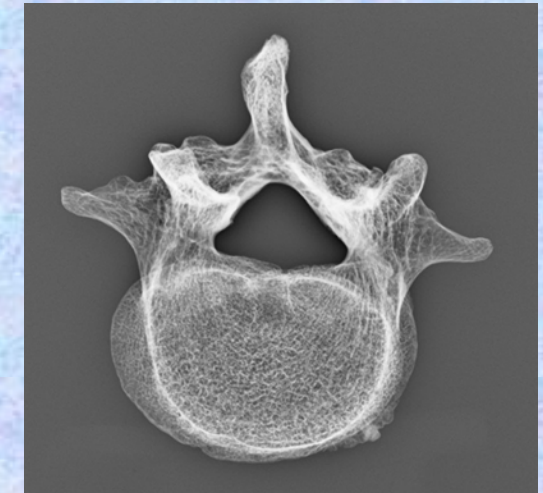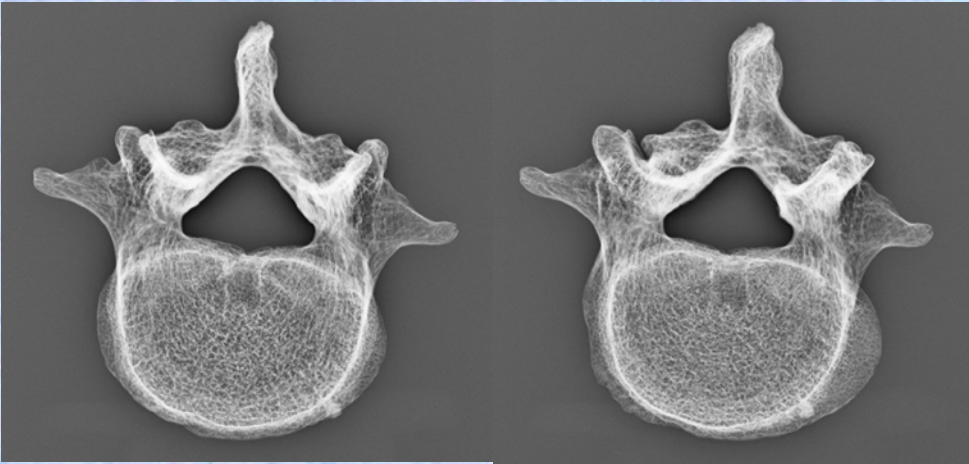
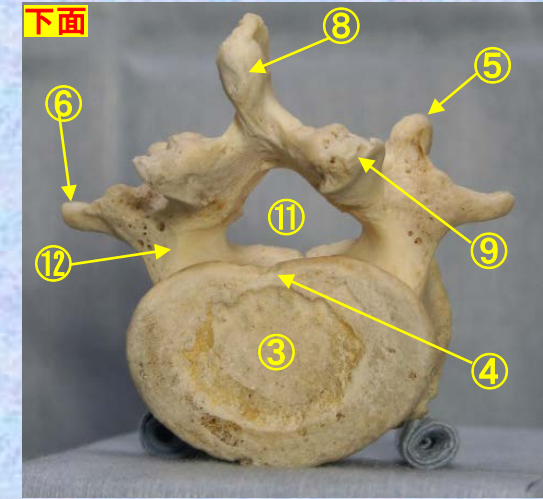

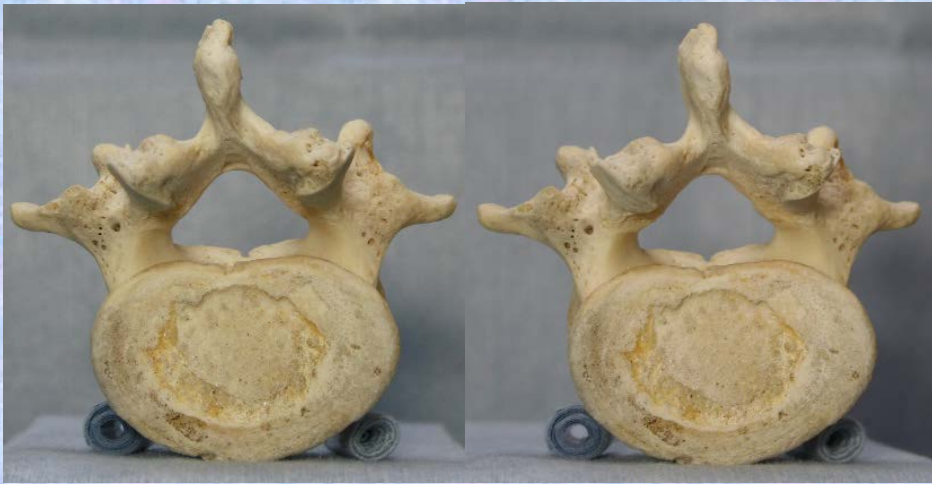
- | | |
|-----------------------------------|-----------------------------------|
| ①上関節突起 superior articular process | ⑧棘突起 spinous process |
| ②上椎切痕 superior vertebral notch | ⑨下関節突起 inferior articular process |
| ③椎体 transverse process | ⑩椎弓板 lamina |
| ④下椎切痕 inferior vertebral notch | ⑪椎孔 vertebral foramen |
| ⑤乳頭突起 mamillary process | ⑫椎弓根 pedicle |
| ⑥肋骨突起(横突起) transverse process | |
| ⑦副突起 accessory process | |

(注) 肋骨突起⑥の後ろの副突起⑦と乳頭突起⑤は、横突起の遺残を形成している。

腰椎の横突起は本来、この部の肋骨に相当するもので肋骨突起⑥といい、本来の横突起は上関節突起の外側から後方に向かう小さな隆起として残っており、乳頭突起⑤とよぶ。また、肋骨突起の根部の後面には下方に向かう小突起があり、副突起⑦というのが、これも本来の横突起の一部が変形したものである。

腰椎 L 5 下面

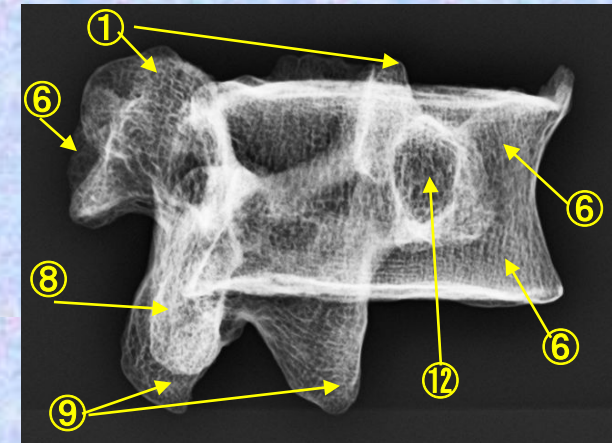
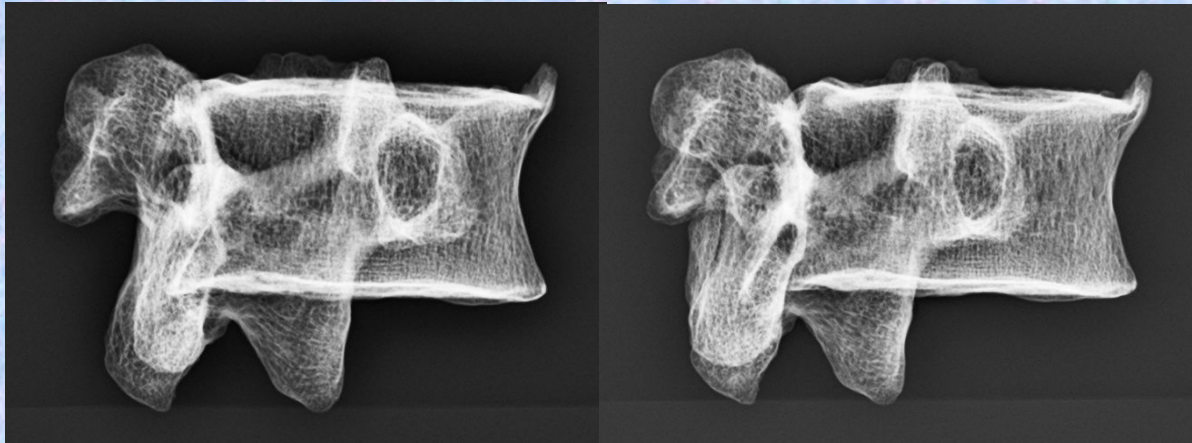
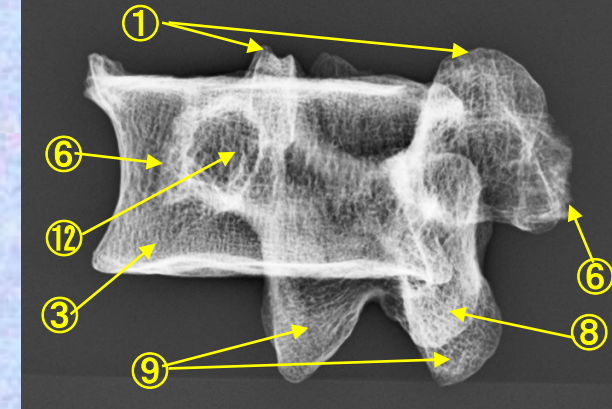
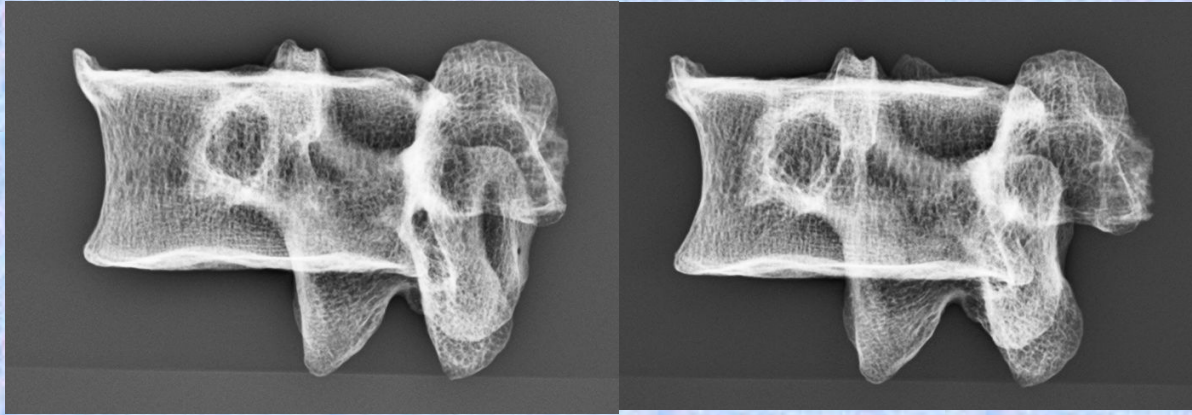


- | | |
|-----------------------------------|-----------------------------------|
| ①上関節突起 superior articular process | ⑧棘突起 spinous process |
| ②上椎切痕 superior vertebral notch | ⑨下関節突起 inferior articular process |
| ③椎体 transverse process | ⑩椎弓板 lamina |
| ④下椎切痕 inferior vertebral notch | ⑪椎孔 vertebral foramen |
| ⑤乳頭突起 mamillary process | ⑫椎弓根 pedicle |
| ⑥肋骨突起(横突起) transverse process | |
| ⑦副突起 accessory process | |

(注) 肋骨突起⑥の後ろの副突起⑦と乳頭突起⑤は、横突起の遺残を形成している。

腰椎の横突起は本来、この部の肋骨に相当するもので肋骨突起⑥といい、本来の横突起は上関節突起の外側から後方に向かう小さな隆起として残っており、乳頭突起⑤とよぶ。また、肋骨突起の根部の後面には下方に向かう小突起があり、副突起⑦というのが、これも本来の横突起の一部が変形したもの

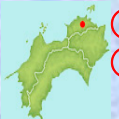L4 スコッチテリア(Scotch Terrier)



- ①上関節突起 superior articular process
- ②上椎切痕 superior vertebral notch
- ③椎体 transverse process
- ④下椎切痕 inferior vertebral notch
- ⑤乳頭突起 mamillary process
- ⑥肋骨突起(横突起) transverse process
- ⑦副突起 accessory process

- ⑧棘突起 spinous process
- ⑨下関節突起 inferior articular process
- ⑩椎弓板 lamina
- ⑪椎孔 vertebral foramen
- ⑫椎弓根pedicle

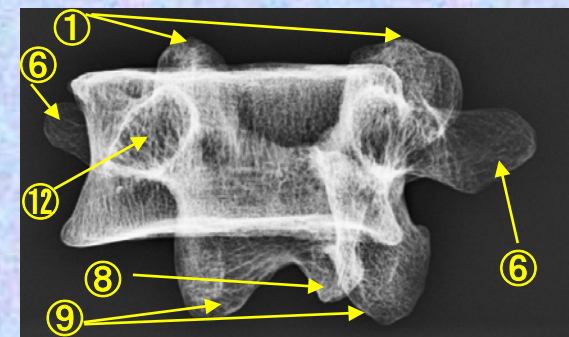
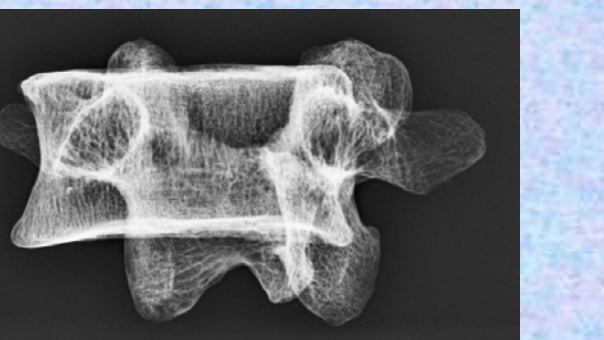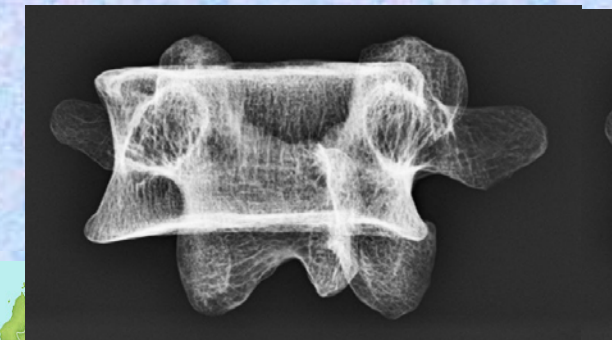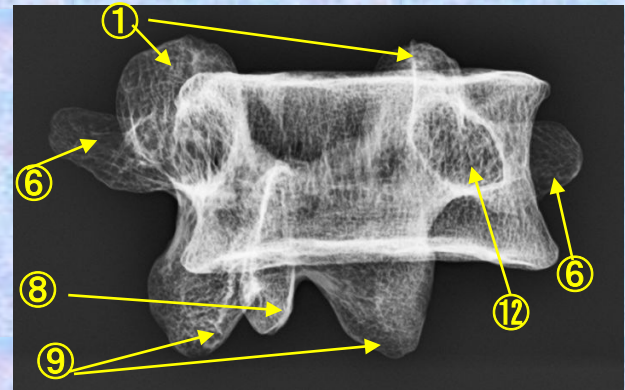
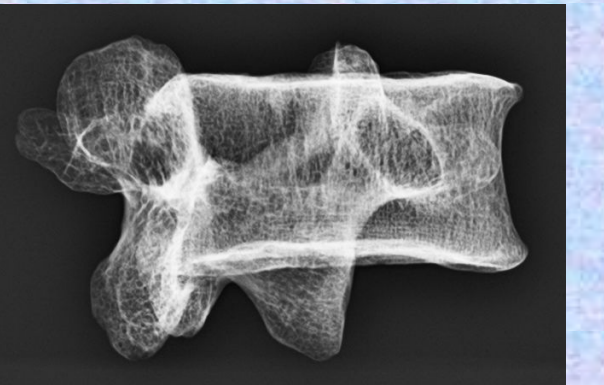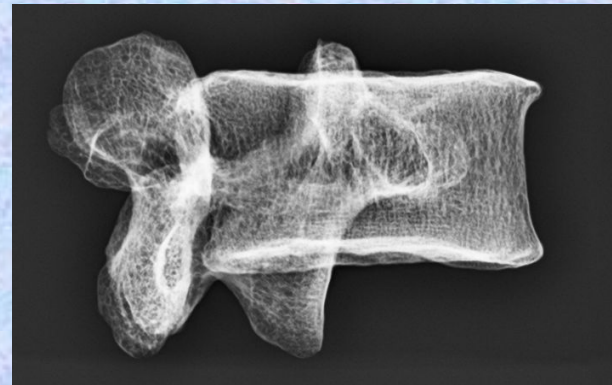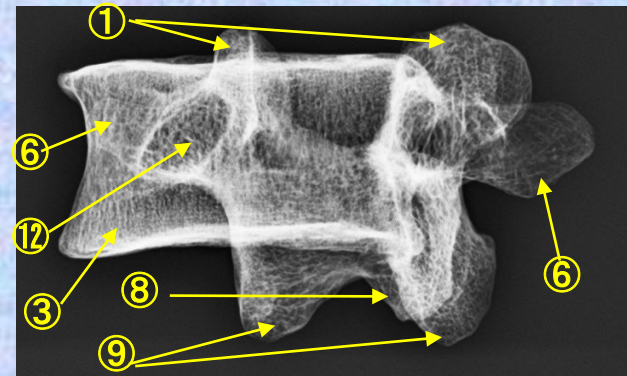
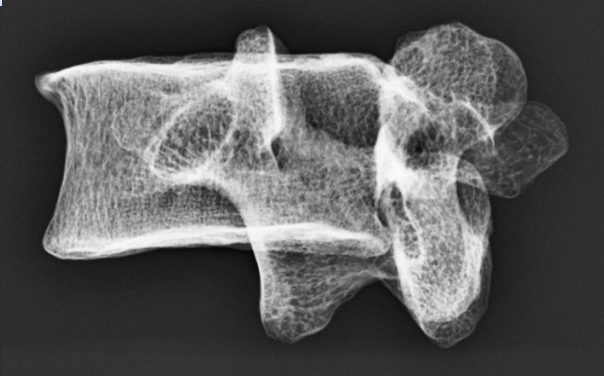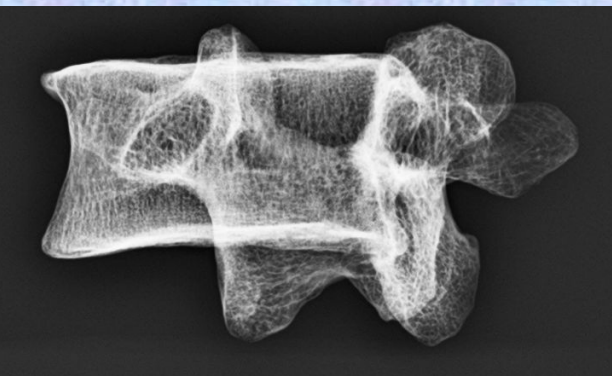(注) 肋骨突起⑥の後ろの副突起⑦と乳頭突起⑤は、横突起の遺残を形成している。



L5 スコッチテリア (Scotch Terrier)

- ①上関節突起 superior articular process
- ③椎体 transverse process
- ⑥肋骨突起(横突起) transverse process

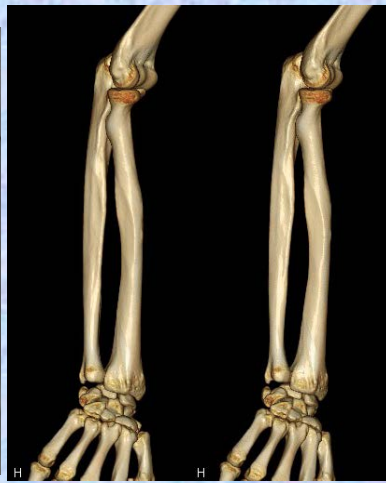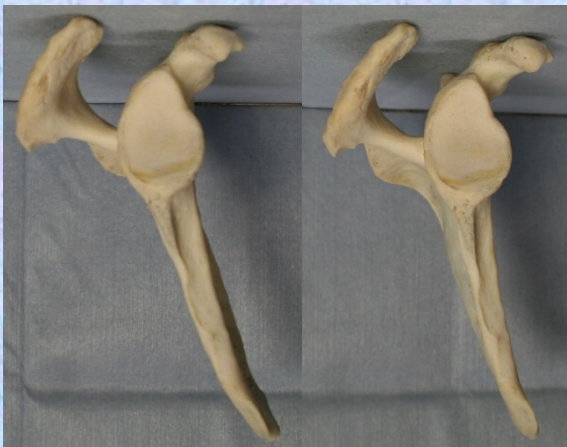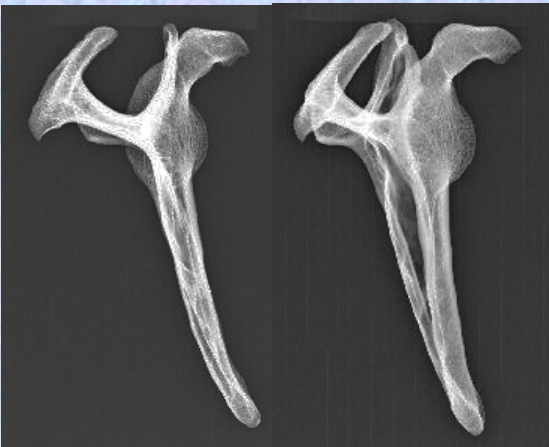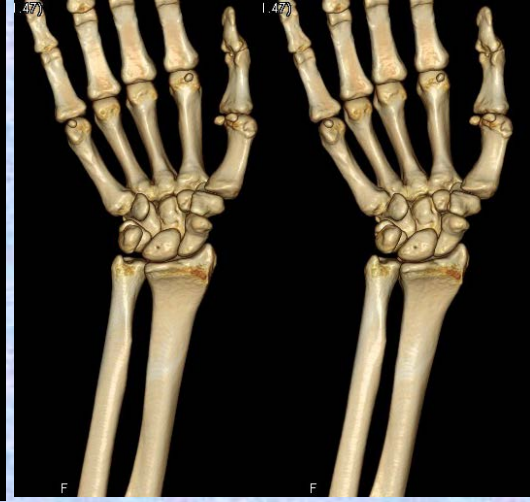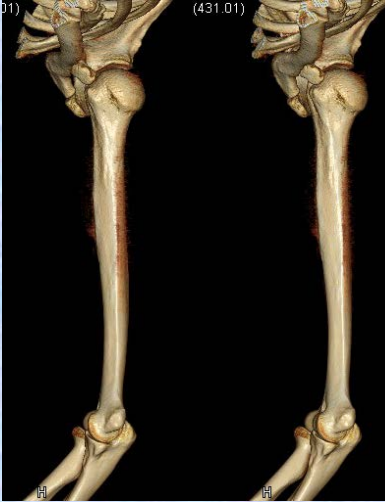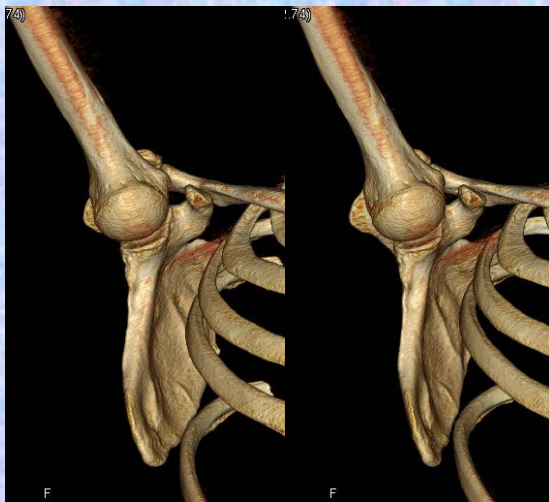- ⑧棘突起 spinous process
- ⑨下関節突起 inferior articular process
- ⑫椎弓根pedicle



骨標本X線ステレオ解剖図

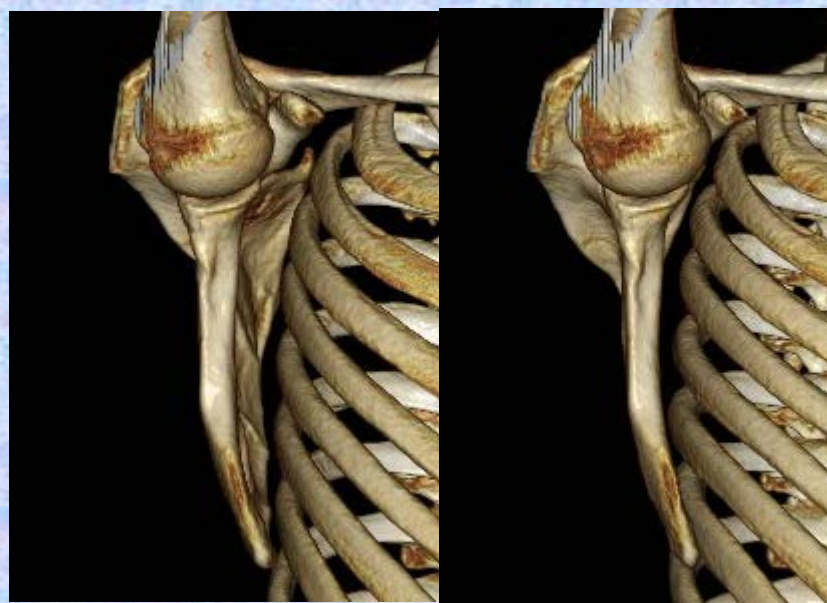
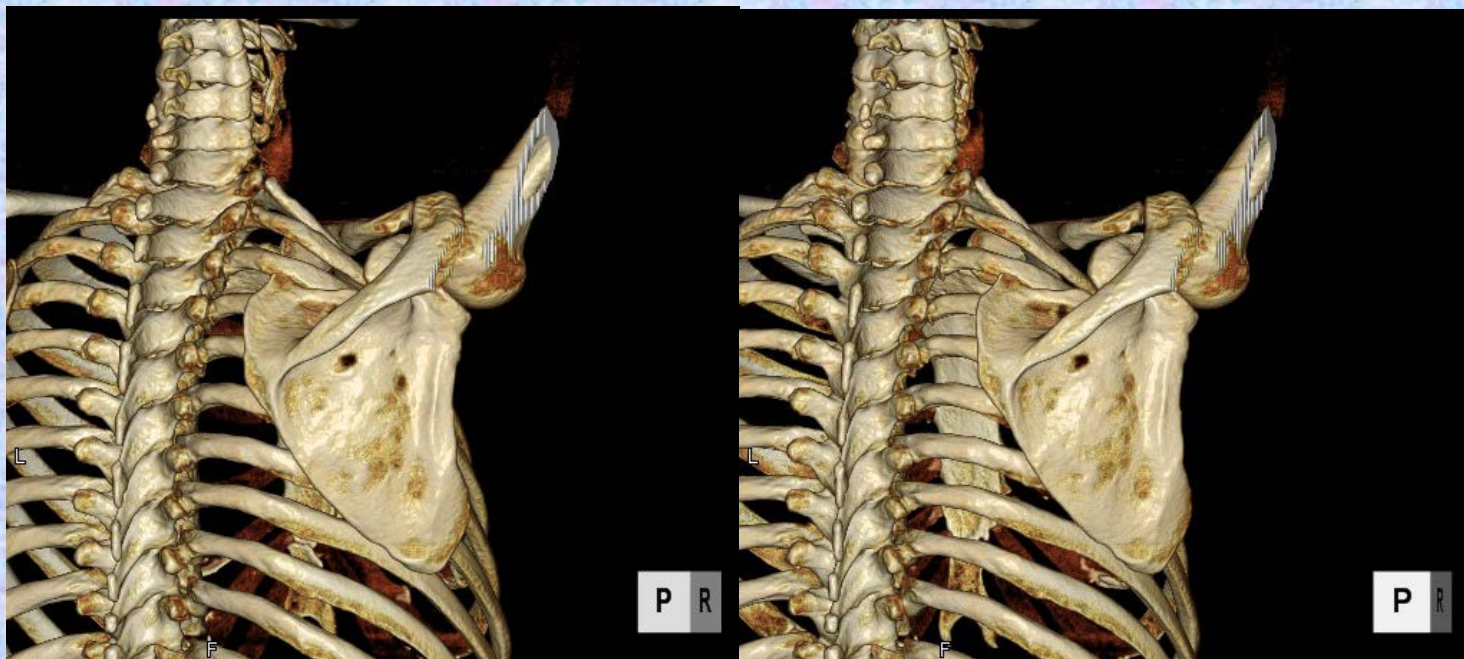
上肢

上肢



監修 香川大学医学部 組織細胞生物学 教授 荒木 伸一
 作成 香川大学医学部附属病院 放射線部 勢川 博雄 2014.9





上肢

Upper limb



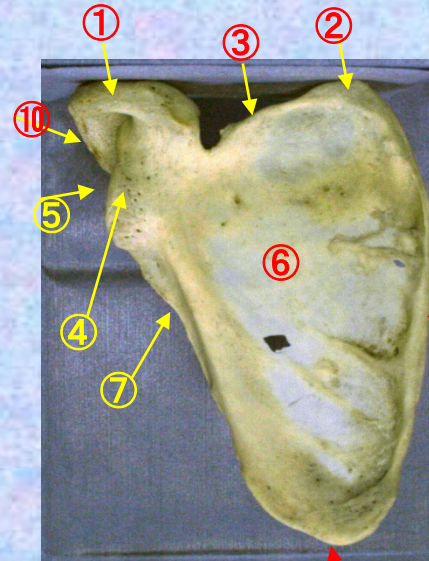
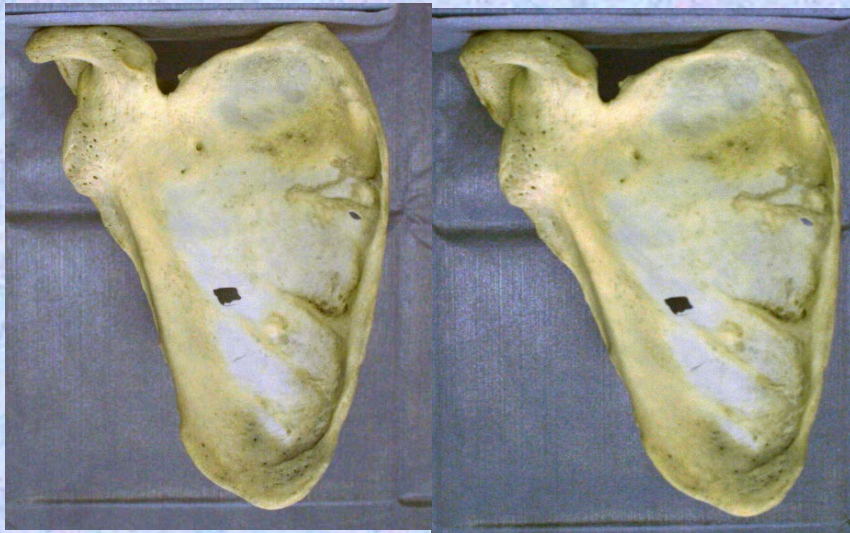肩甲骨

Scapula

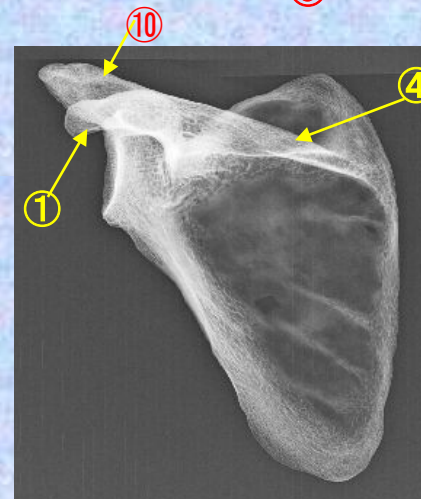
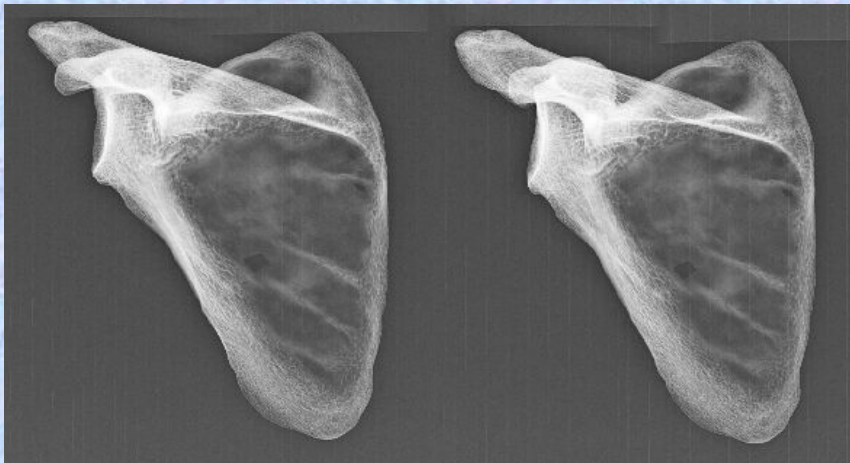


肩甲骨 Scapula 内側面

内側面 (Scapula medial view)



- ① 烏口突起 coracoid process
- ② 上角 Superior angle
- ③ 上縁 superior border
- ④ 肩甲頸 neck
- ⑤ 関節窩の縁 margin of glenoid cavity
- ⑥ 肩甲下窩 subscapular fossa
- ⑦ 外側縁 lateral border
- ⑧ 内側縁 medial border
- ⑨ 下角 inferior angle
- ⑩ 肩峰 acromion

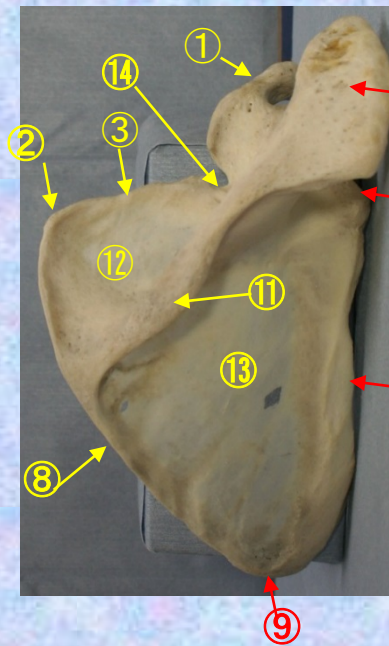
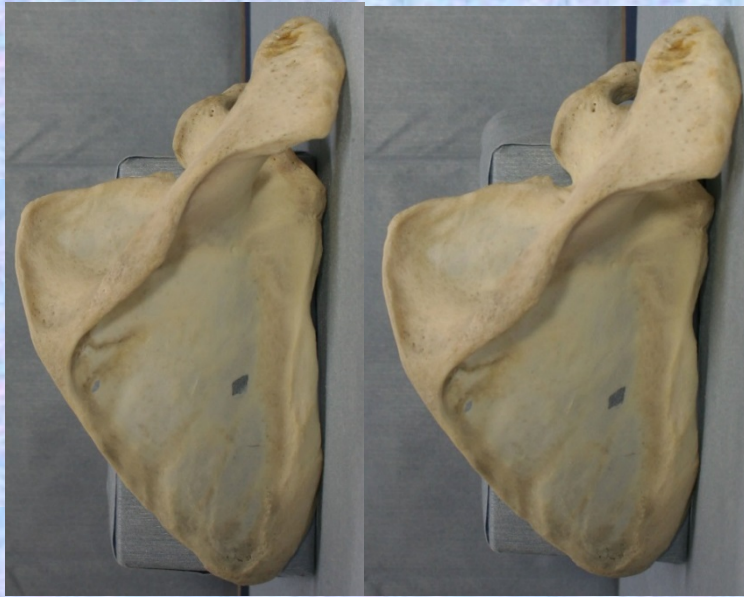


- ⑪ 肩甲棘 spine
- ⑫ 棘上窩 Supraspinous fossa
- ⑬ 棘下窩 Infraspinous fossa
- ⑭ 肩甲切痕 suprascapular notch

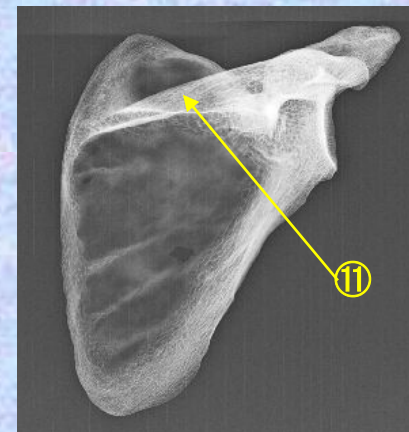
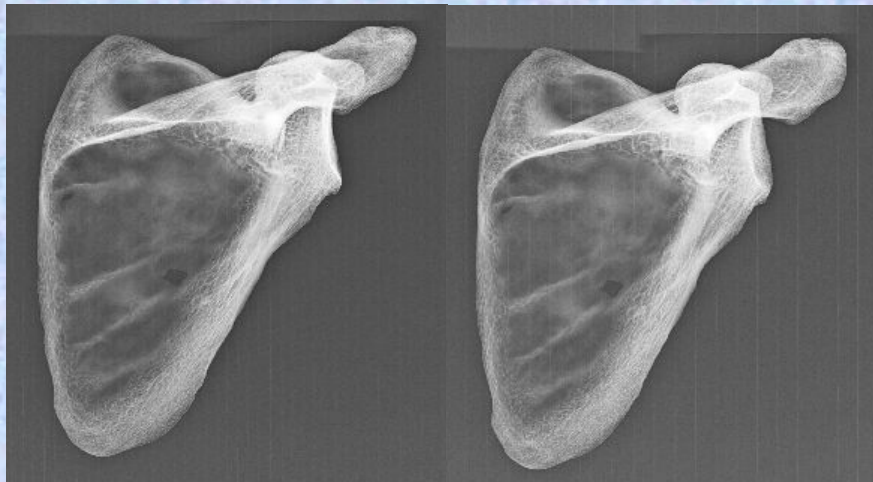


肩甲骨 Scapula 外側面

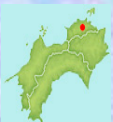外側面 (Scapula lateral view)



- ① 烏口突起 coracoid process
- ② 上角 Superior angle
- ③ 上縁 superior border
- ④ 肩甲頸 neck
- ⑤ 関節窩の縁 margin of
glenoid cavity
- ⑥ 肩甲下窩 subscapular fossa
- ⑦ 外側縁 lateral border
- ⑧ 内側縁 medial border
- ⑨ 下角 inferior angle
- ⑩ 肩峰 acromion

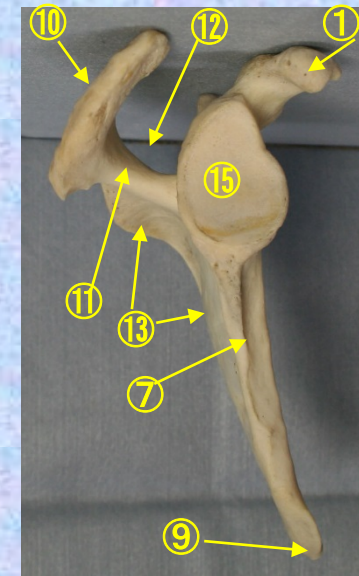
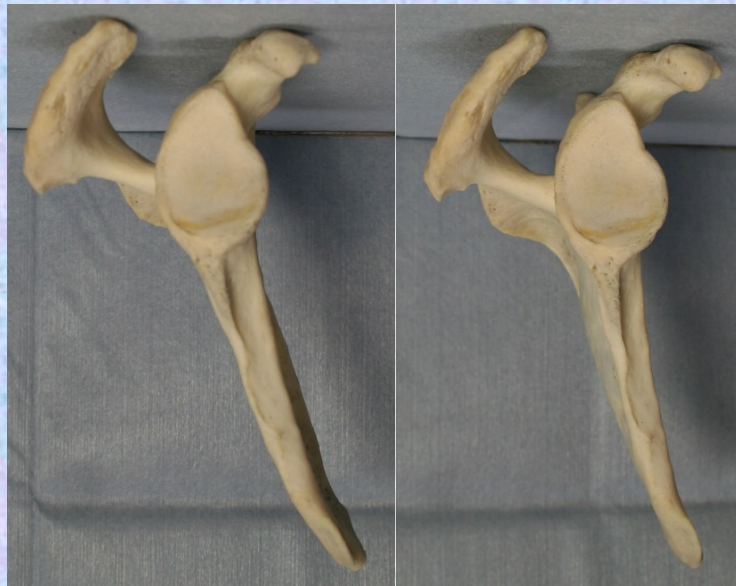
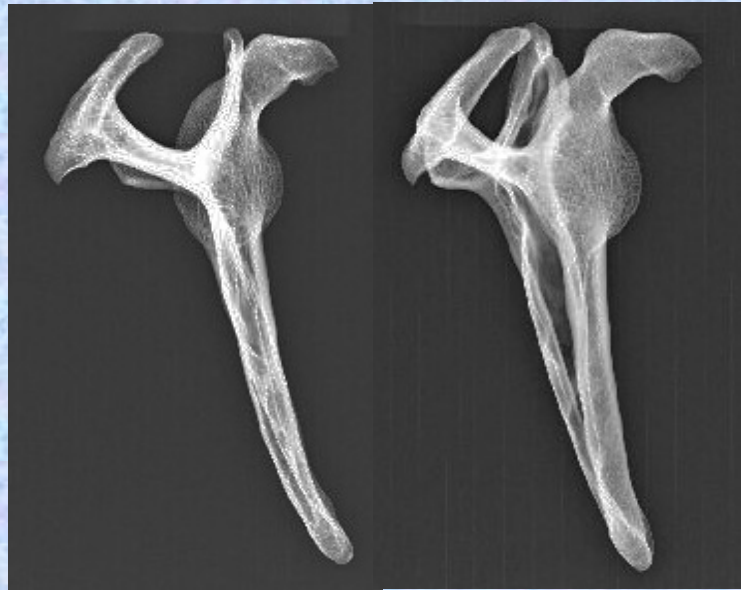
- ⑪ 肩甲棘 spine
- ⑫ 棘上窩 Supraspinous fossa
- ⑬ 棘下窩 Infraspinous fossa
- ⑭ 肩甲切痕
suprascapular notch



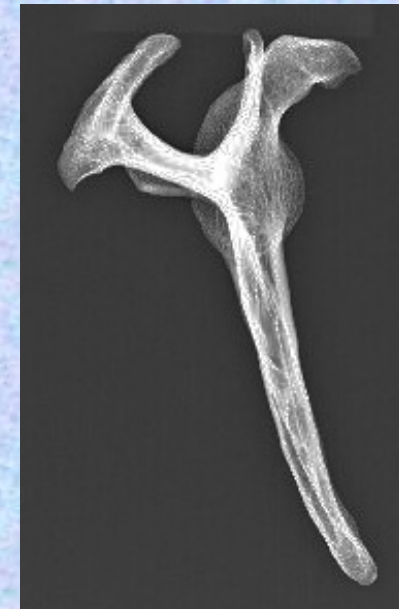肩甲骨 Scapula 軸位

軸位 (Scapula axial Y view)



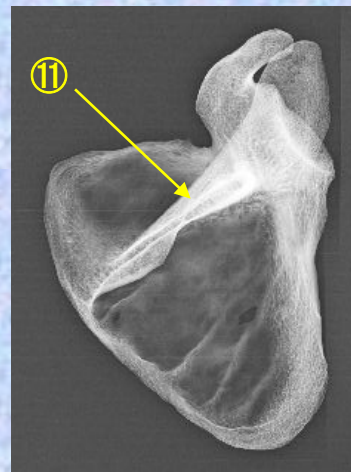
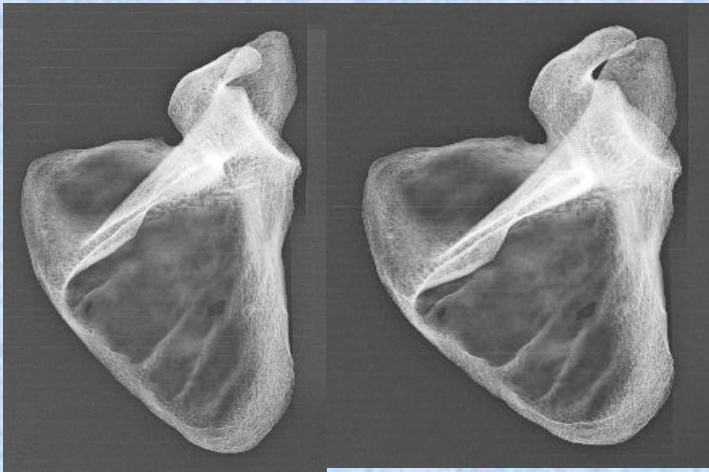
- ① 烏口突起 coracoid process
- ② 上角 Superior angle
- ③ 上縁 superior border
- ④ 肩甲頸 neck
- ⑤ 関節窩の縁 margin of glenoid cavity
- ⑥ 肩甲下窩 subscapular fossa
- ⑦ 外側縁 lateral border
- ⑧ 内側縁 medial border
- ⑨ 下角 inferior angle

- ⑩ 肩峰 acromion
- ⑪ 肩甲棘 spine
- ⑫ 棘上窩 Supraspinous fossa
- ⑬ 棘下窩 Infraspinous fossa
- ⑭ 肩甲切痕 suprascapular notch
- ⑮ 関節窩 glenoid cavity
- ⑯ 上腕骨頭 head of humerus
- ⑰ 結節間溝 groove for radial nerve

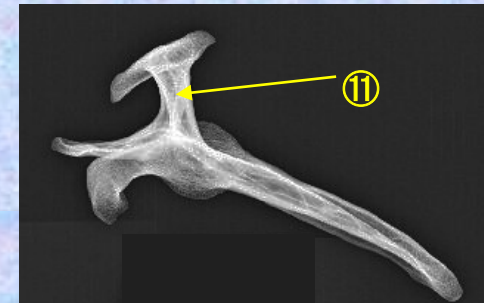
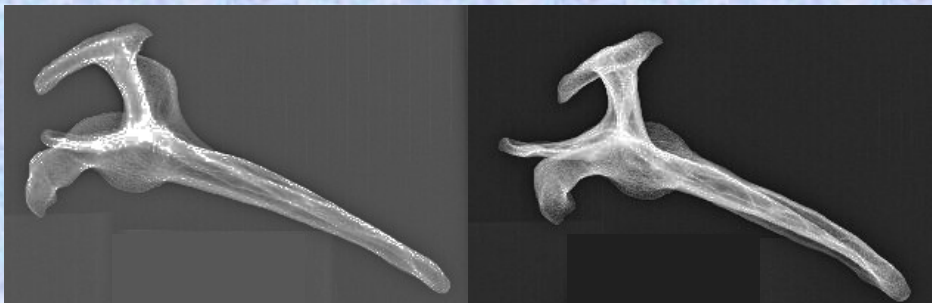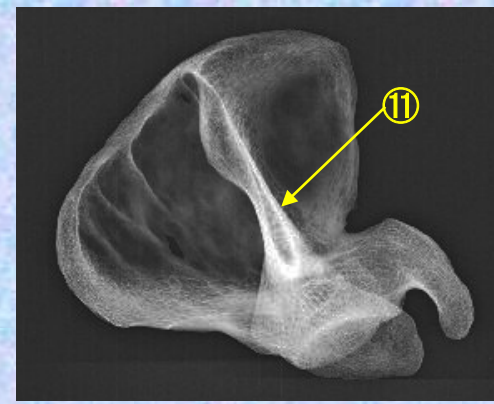


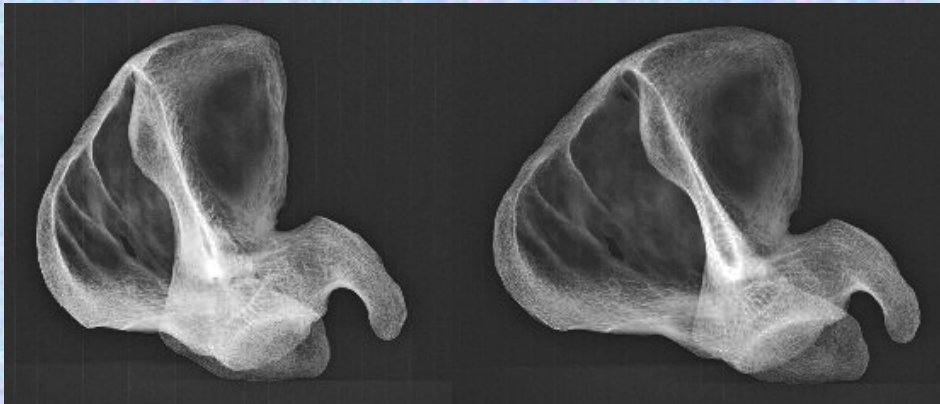肩甲骨棘 Spine of Scapula

軸位 (Spine of Scapula axial view)

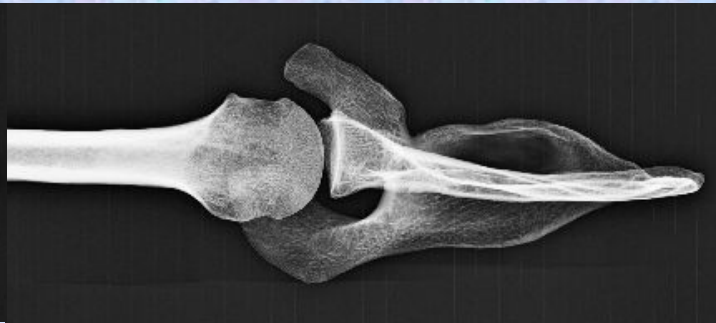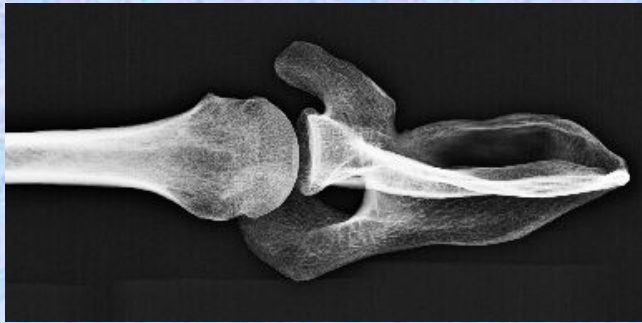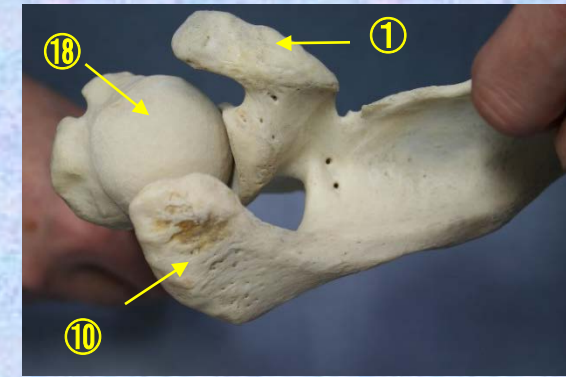


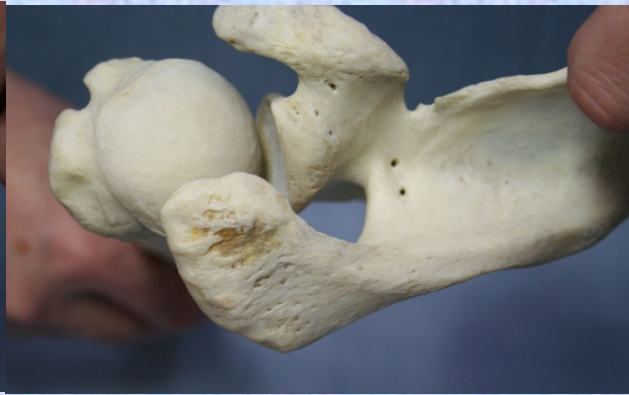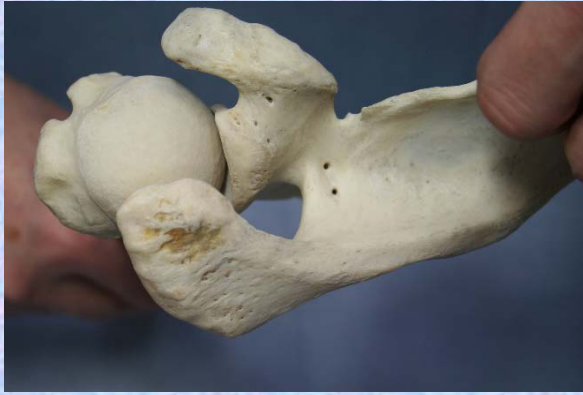- ① 烏口突起 coracoid process
- ② 上角 Superior angle
- ③ 上縁 superior border
- ④ 肩甲頸 neck
- ⑤ 関節窩の縁 margin of
glenoid cavity
- ⑥ 肩甲下窩 subscapular fossa
- ⑦ 外側縁 lateral border
- ⑧ 内側縁 medial border
- ⑨ 下角 inferior angle
- ⑩ 肩峰 acromion
- ⑪ 肩甲骨棘 spine



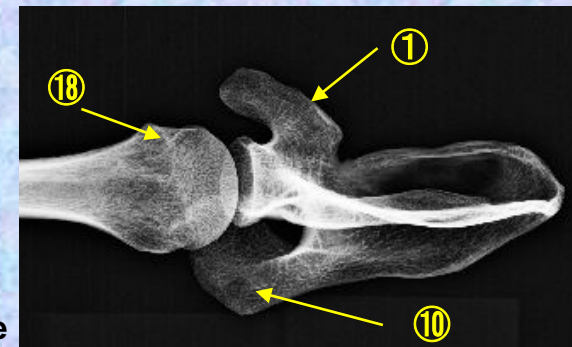
肩関節 shoulder joint 軸位

軸位 (shoulder joint axial view)



- ① 烏口突起 coracoid process
- ② 上角 Superior angle
- ③ 上縁 superior border
- ④ 肩甲頸 neck
- ⑤ 関節窩の縁 margin of glenoid cavity
- ⑥ 肩甲下窩 subscapular fossa
- ⑦ 外側縁 lateral border
- ⑧ 内側縁 medial border
- ⑨ 下角 inferior angle

- ⑩ 肩峰 acromion
- ⑪ 肩甲棘 spine
- ⑫ 棘上窩 Supraspinous fossa
- ⑬ 棘下窩 Infraspinous fossa
- ⑭ 肩甲切痕 suprascapular notch
- ⑮ 関節窩 glenoid cavity
- ⑯ 上腕骨頭 head of humerus
- ⑰ 結節間溝 groove for radial nerve
- ⑱ 上腕骨頭 head of humerus




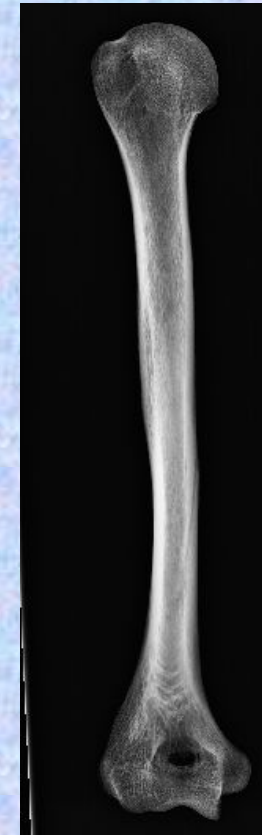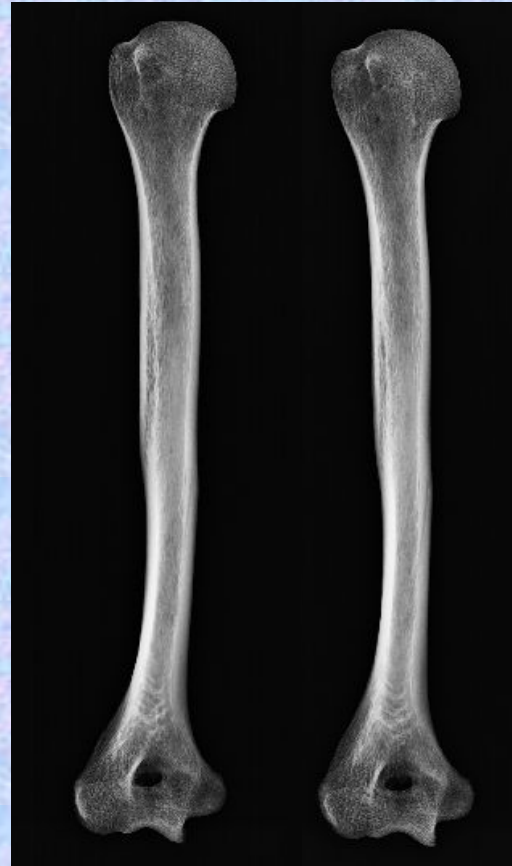
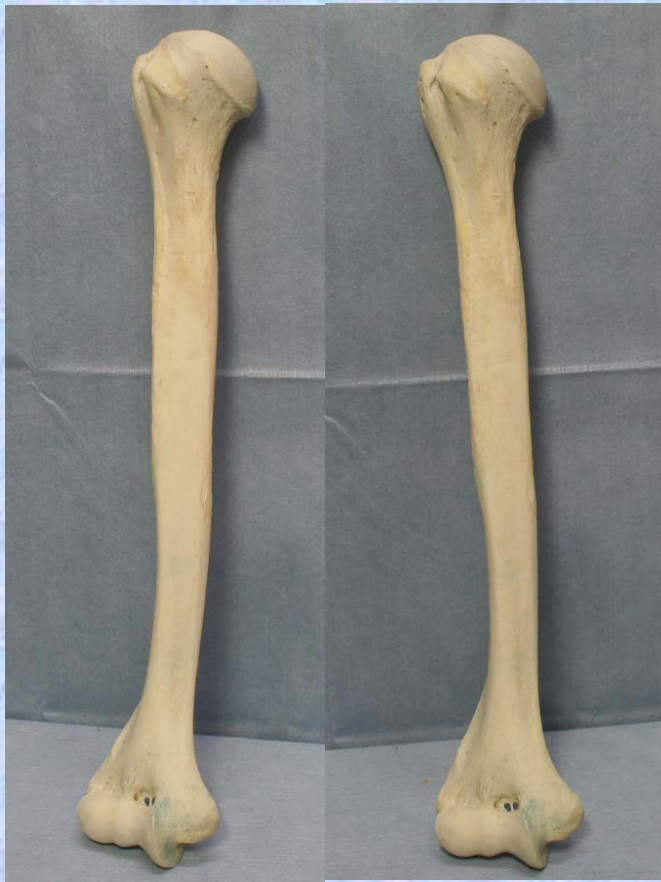上腕骨

humerus



上腕骨 humerus 前面

前面 (Humerus anterior view)



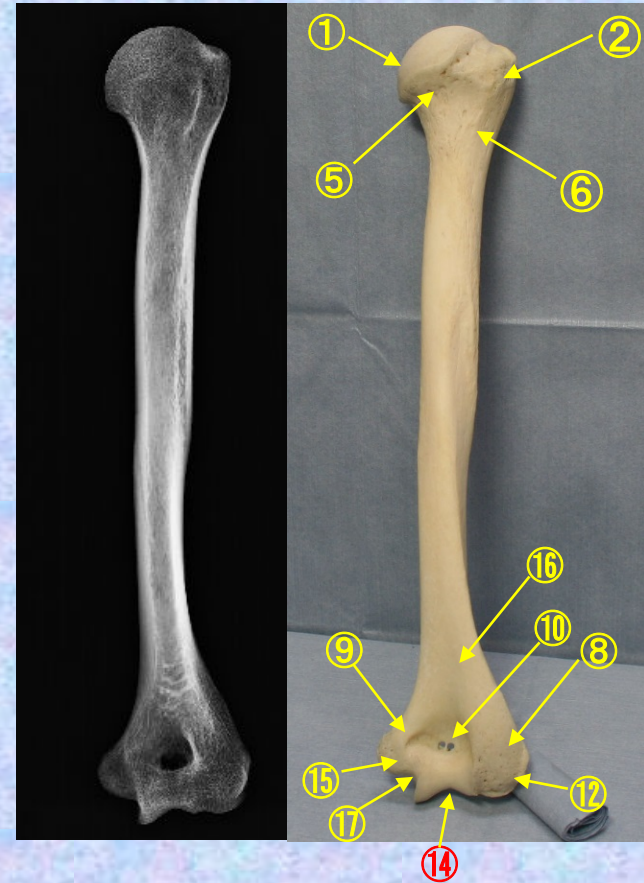
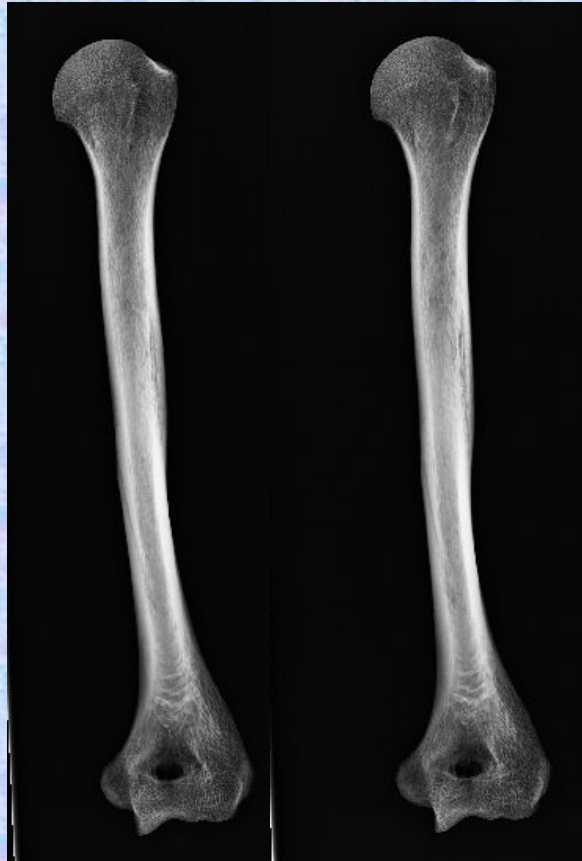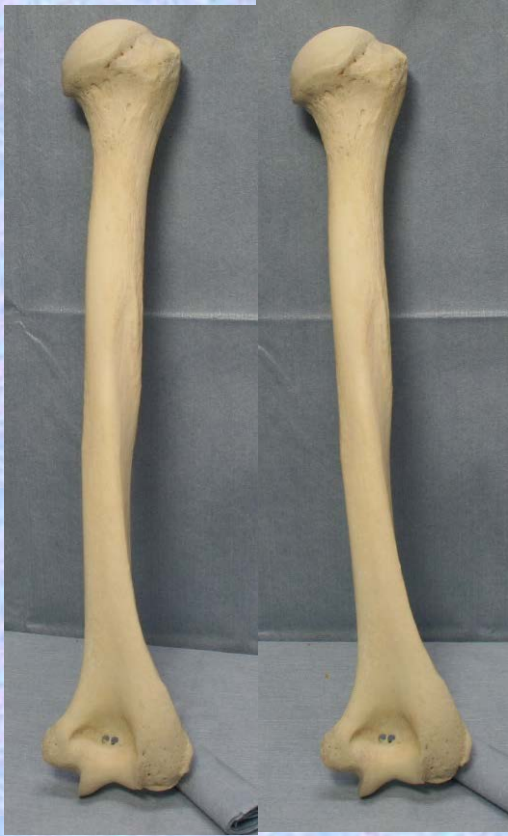- ① 上腕骨頭 head of humerus
- ② 大結節 greater tubercle
- ③ 小結節 lesser tubercle
- ④ 結節間溝 intertuberuclar groove
- ⑤ 解剖頸 anatomical neck
- ⑥ 外科頸 surgical neck
- ⑦ 前面 anterior surface
- ⑧ 外側顆上縁 lateral supracodylar ridge
- ⑨ 内側顆上縁 medial supracodylar ridge

- ⑩ 肘頭窩 olecranon fossa
- ⑪ 鉤(こう)突窩 coronoid fossa
- ⑫ 外側上顆 lateral epicydyle
- ⑬ 上腕骨小頭 capitulum
- ⑭ 上腕骨滑車 torochlea
- ⑮ 内側上顆 medial epicondyle
- ⑯ 後面 posterior surface
- ⑰ 尺骨神経溝 groove for ulnar nerve



上腕骨 humerus 後面

後面 (Humerus posterior view)



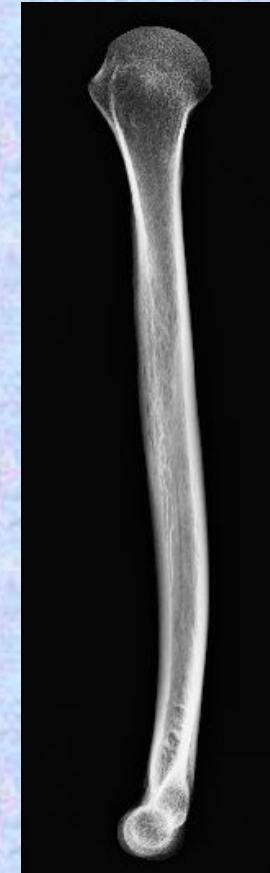
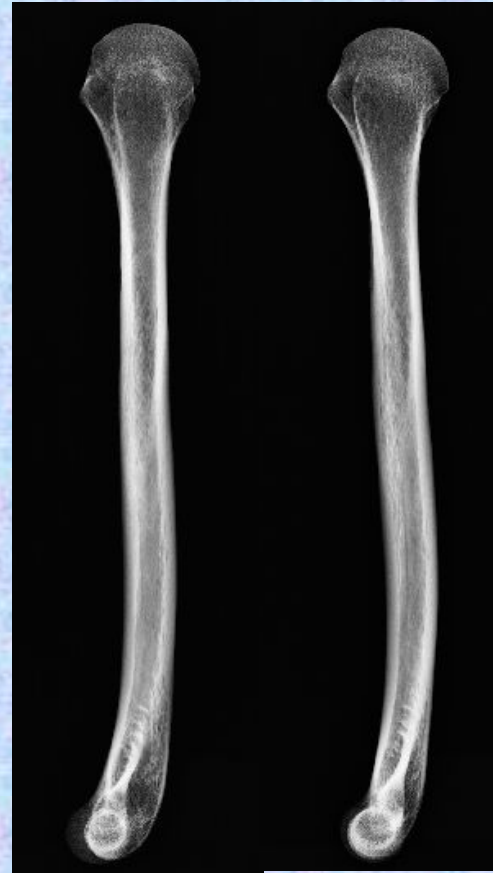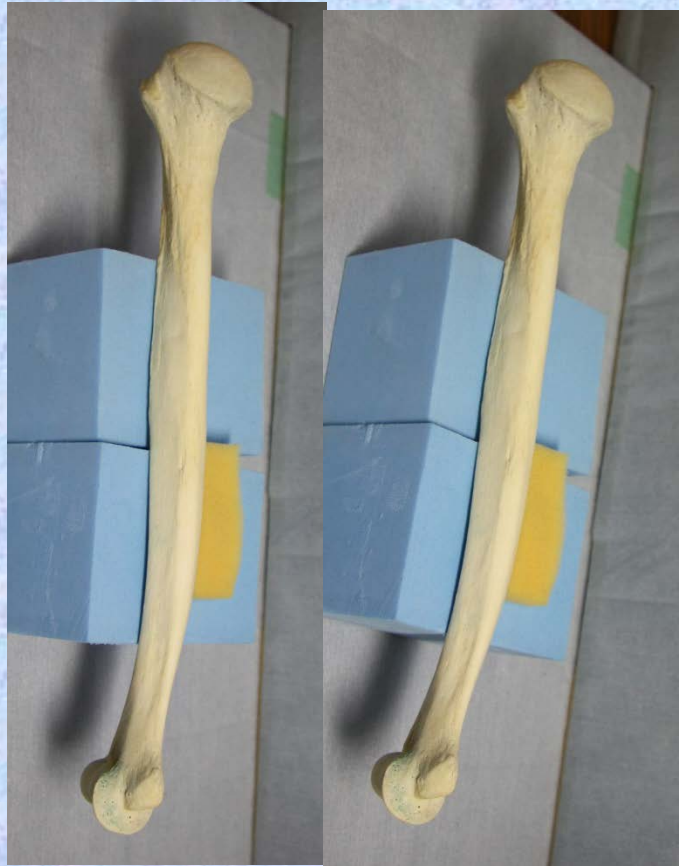
- ① 上腕骨頭 head of humerus
- ② 大結節 greater tubercle
- ③ 小結節 lesser tubercle
- ④ 結節間溝 intertubercular groove
- ⑤ 解剖頸 anatomical neck
- ⑥ 外科頸 surgical neck
- ⑦ 前面 anterior surface
- ⑧ 外側顆上緣 lateral supracondylar ridge
- ⑨ 內側顆上緣 medial supracondylar ridge

- ⑩ 肘頭窩 olecranon fossa
- ⑪ 鉤(こう)突窩 coronoid fossa
- ⑫ 外側上顆 lateral epicondyle
- ⑬ 上腕骨小頭 capitulum
- ⑭ 上腕骨滑車 trochlea
- ⑮ 內側上顆 medial epicondyle
- ⑯ 後面 posterior surface
- ⑰ 尺骨神經溝 groove for ulnar nerve



上腕骨 Humerus 側面

側面 (Humerus lateral view)



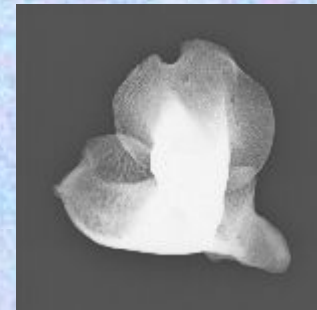
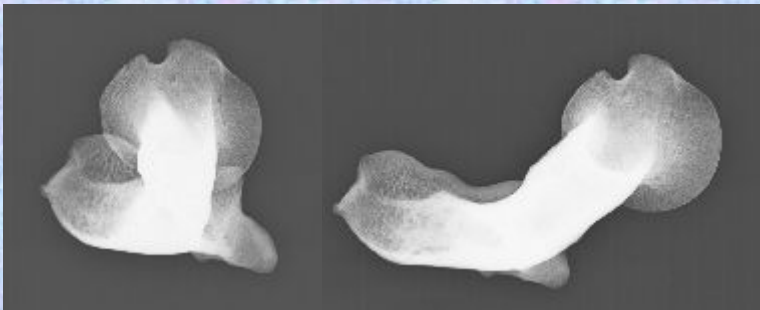
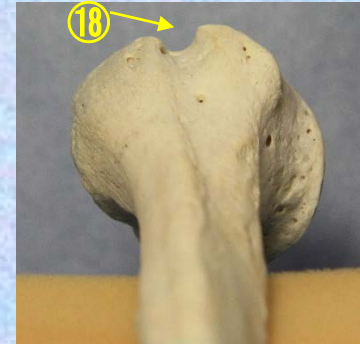
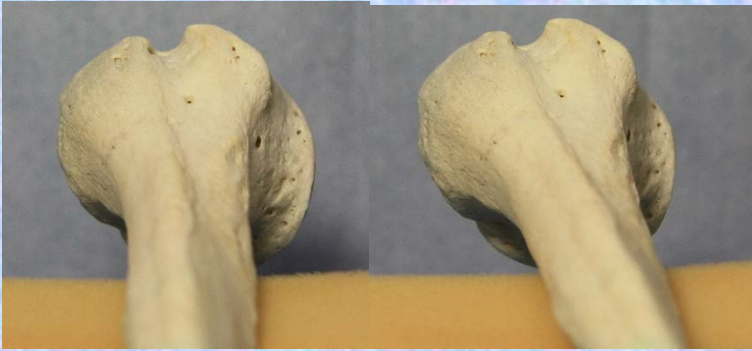- ① 上腕骨頭 head of humerus
- ② 大結節 greater tubercle
- ③ 小結節 lesser tubercle
- ④ 結節間溝 intertuberuclar groove
- ⑤ 解剖頸 anatomical neck
- ⑥ 外科頸 surgical neck
- ⑦ 前面 anterior surface
- ⑧ 外側顆上縁 lateral supracodylar ridge
- ⑨ 内側顆上縁 medial supracodylar ridge

- ⑩ 肘頭窩 olecranon fossa
- ⑪ 鉤(こう)突窩 coronoid fossa
- ⑫ 外側上顆 lateral epicodyle
- ⑬ 上腕骨小頭 capitulum
- ⑭ 上腕骨滑車 torochlea
- ⑮ 内側上顆 medial epicondyle
- ⑯ 後面 posterior surface



結節間溝 (上腕二頭筋溝)

intertubercular groove (groove of biceps brachii muscle)

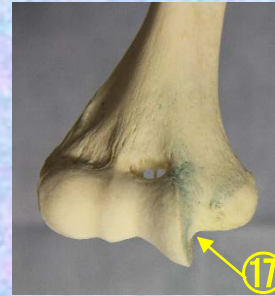
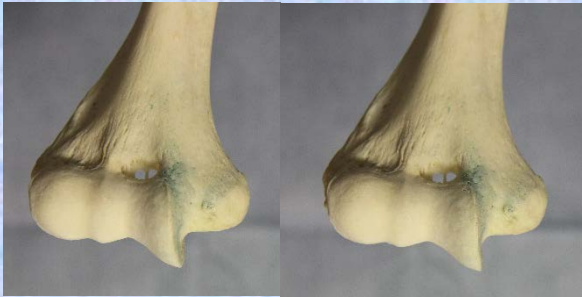
⑱ 上腕二頭筋溝 groove of biceps brachii muscle (結節間溝)

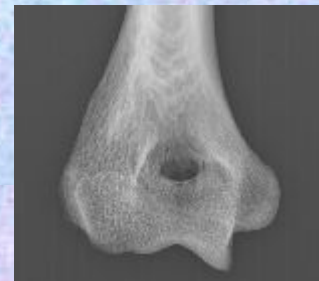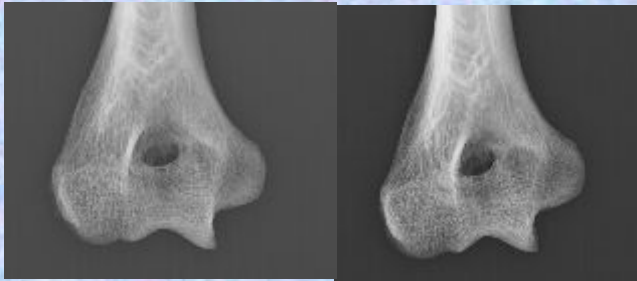


尺骨神經溝 groove for ulnar nerve

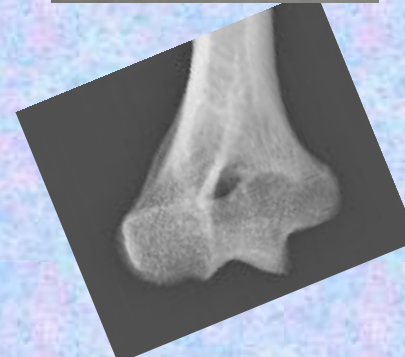
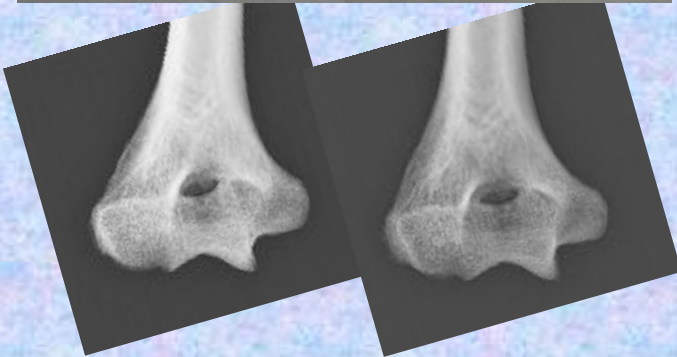
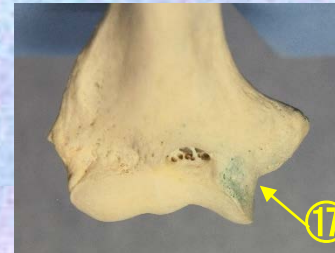
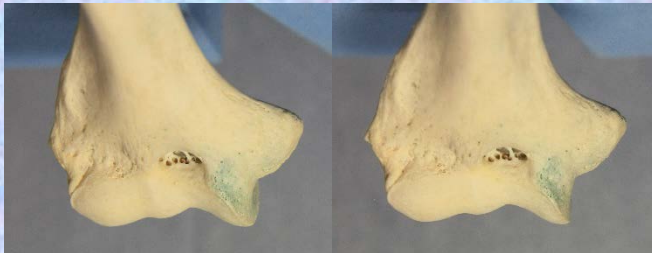
背側面



⑰ 尺骨神經溝
groove for ulnar nerve



腹側面

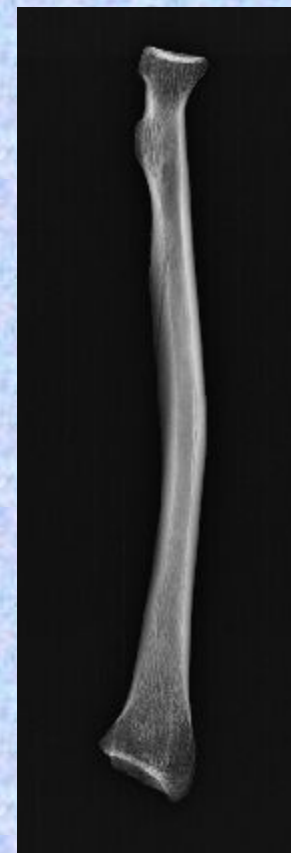
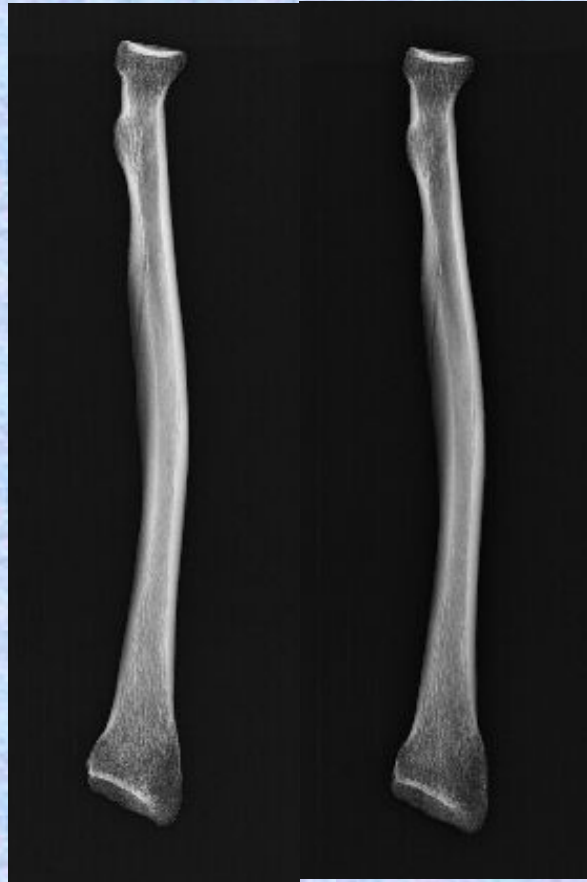
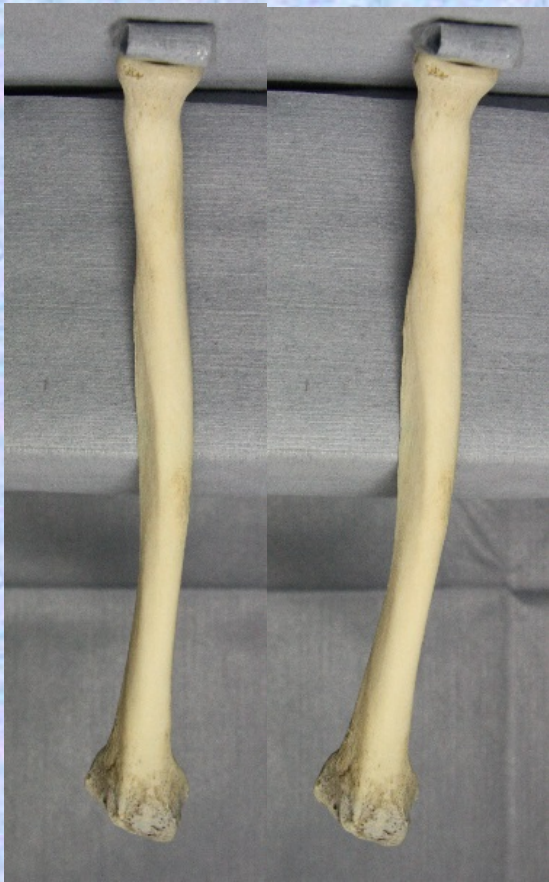
橈骨 radius



橈骨 radius 手背側

手背側 (Radius dorsum of hand)



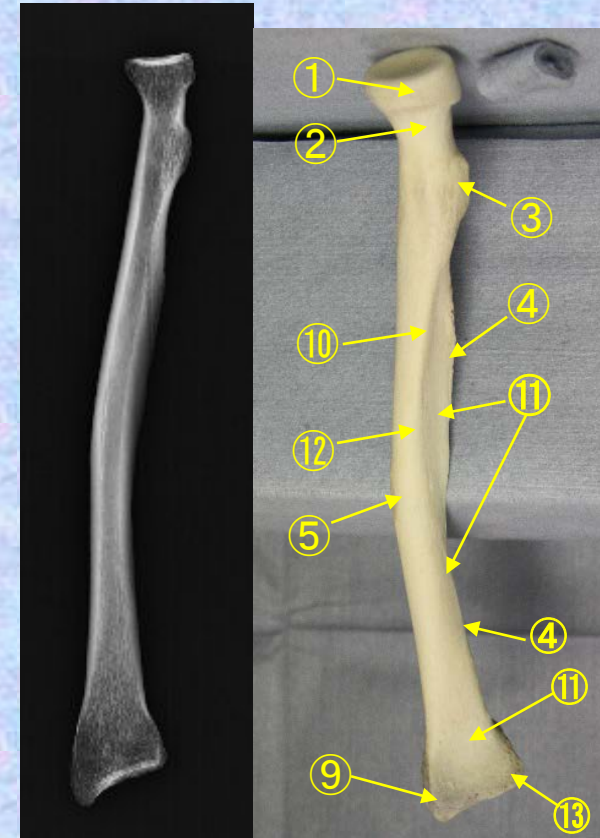
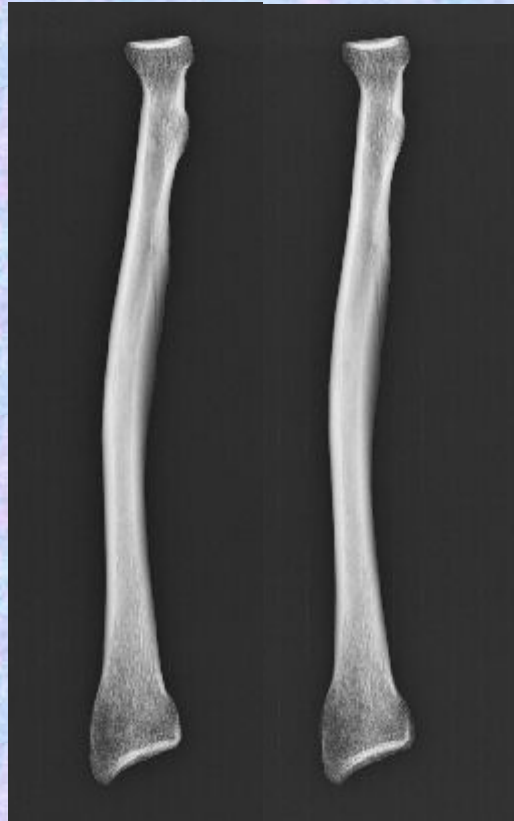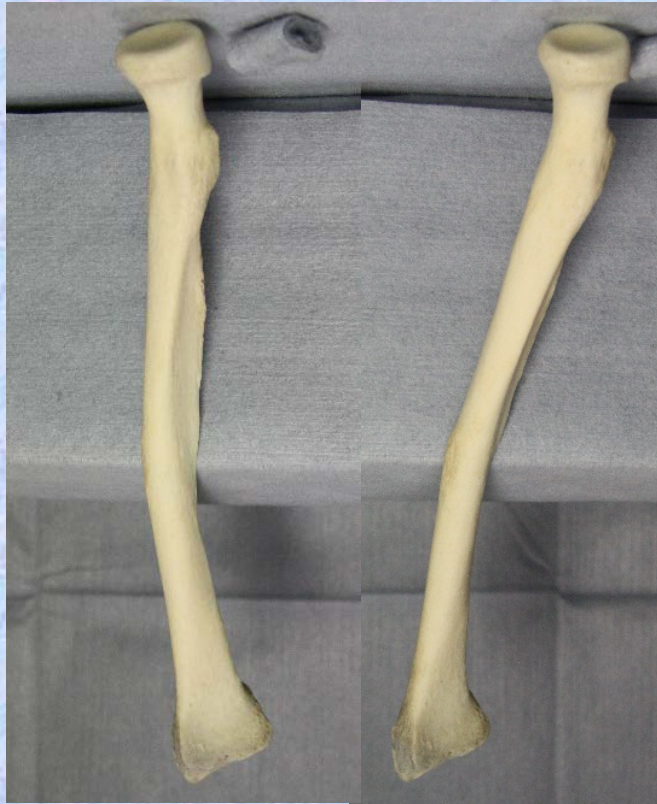- ① 橈骨頭 head of radius
- ② 橈骨頸 neck of radius
- ③ 橈骨粗面 tuberosity of radius
- ④ 骨間緣 interosseous border
- ⑤ 外側面 lateral surface
- ⑥ 後緣 posterior border
- ⑦ 後面 posterior surface

- ⑧ 背側結節 dorsal tubercle
- ⑨ 莖狀突起 styloid process
- ⑩ 前斜線 anterior oblique line
- ⑪ 前面 anterior surface
- ⑫ 前緣 anterior border
- ⑬ 尺骨切痕 ulnar notch



橈骨 radius 手掌側

手掌側 (Radius palmar view)



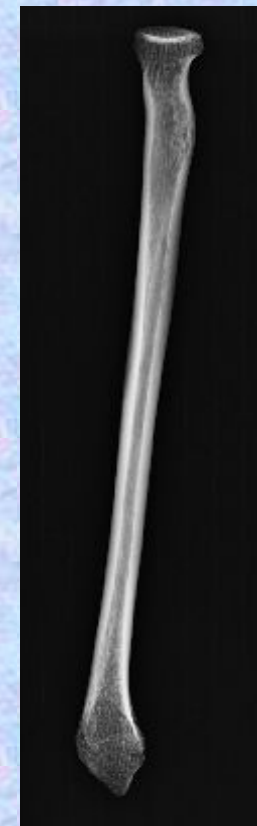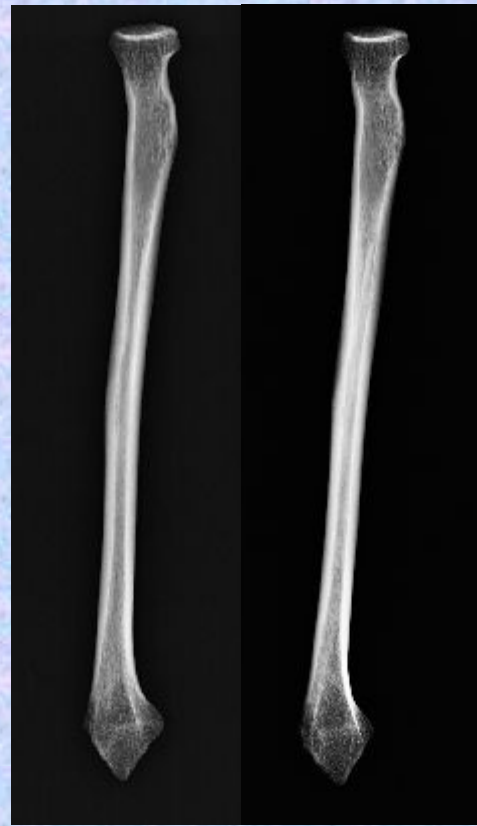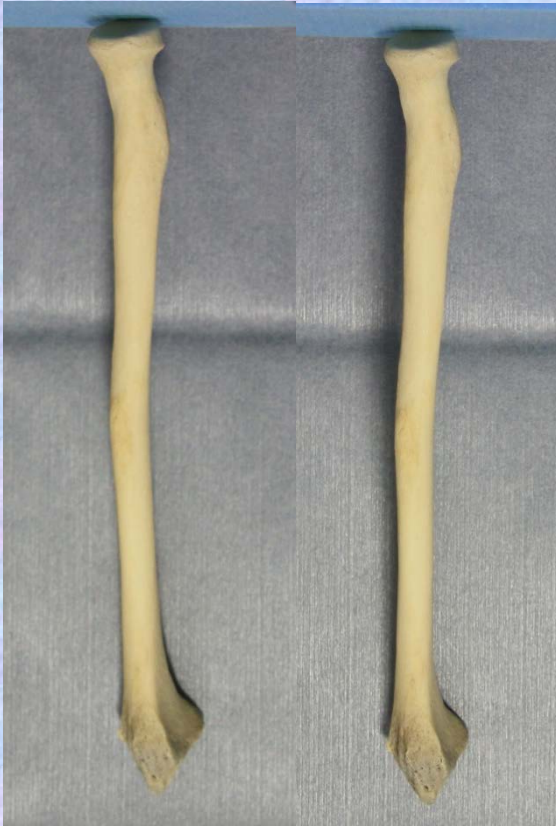- ① 橈骨頭 head of radius
- ② 橈骨頸 neck of radius
- ③ 橈骨粗面 tuberosity of radius
- ④ 骨間緣 interosseous border
- ⑤ 外側面 lateral surface
- ⑥ 後緣 posterior border
- ⑦ 後面 posterior surface

- ⑧ 背側結節 dorsal tubercle
- ⑨ 莖狀突起 styloid process
- ⑩ 前斜線 anterior oblique line
- ⑪ 前面 anterior surface
- ⑫ 前緣 anterior border
- ⑬ 尺骨切痕 ulnar notch



橈骨 radius 側面

側面 (Radius lateral view)



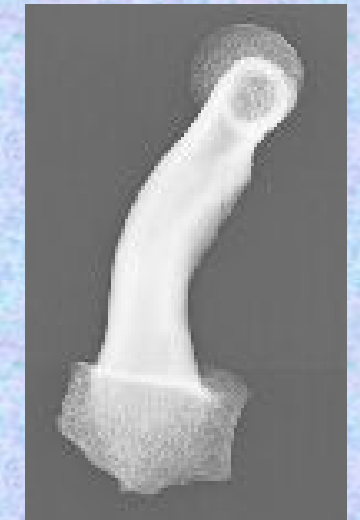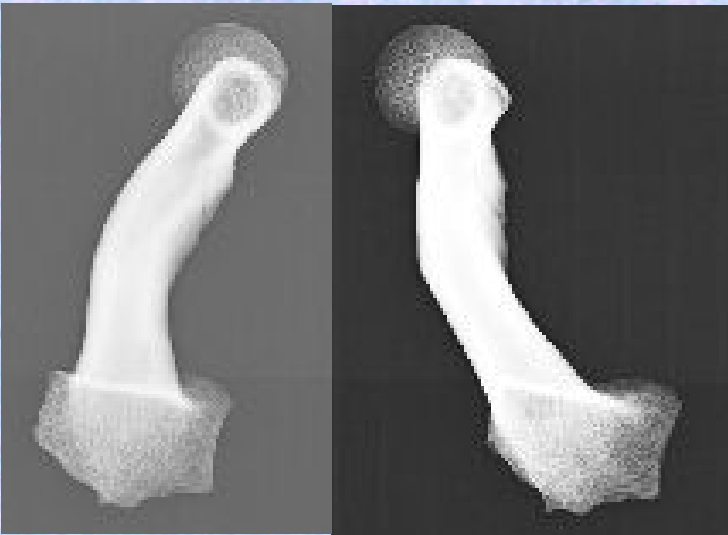
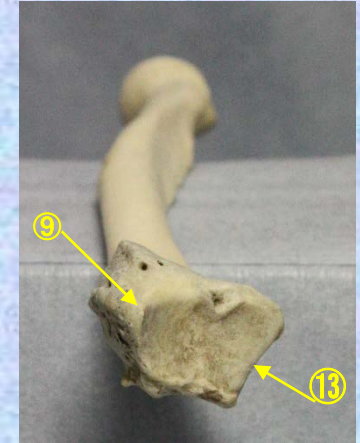
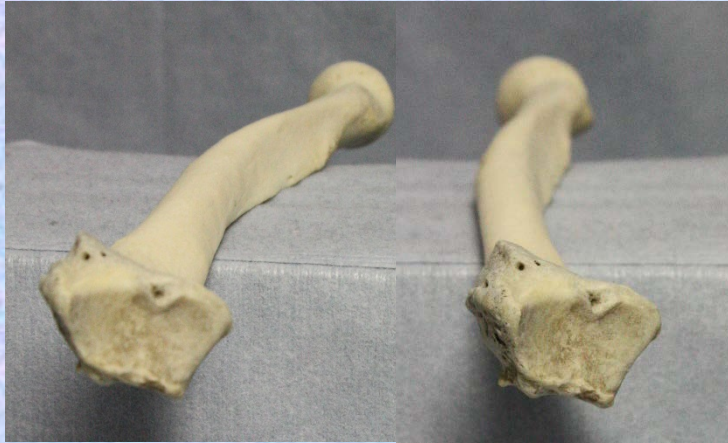- ① 橈骨頭 head of radius
- ② 橈骨頸 neck of radius
- ③ 橈骨粗面 tuberosity of radius
- ④ 骨間緣 interosseous border
- ⑤ 外側面 lateral surface
- ⑥ 後緣 posterior border
- ⑦ 後面 posterior surface

- ⑧ 背側結節 dorsal tubercle
- ⑨ 莖狀突起 styloid process
- ⑩ 前斜線 anterior oblique line
- ⑪ 前面 anterior surface
- ⑫ 前緣 anterior border
- ⑬ 尺骨切痕 ulner notch



橈骨 radius 莖狀突起側 軸面

莖狀突起側 軸面 (Radius styloid process side)


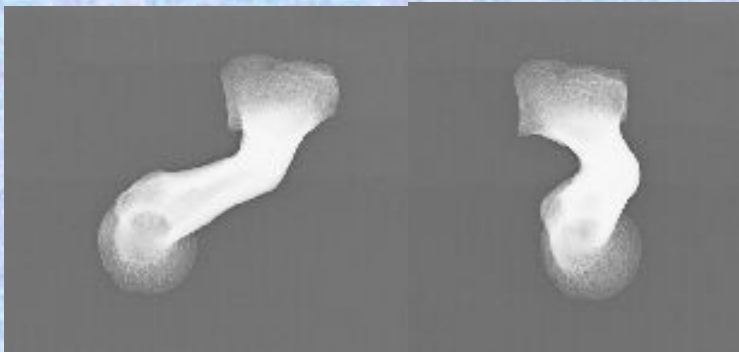
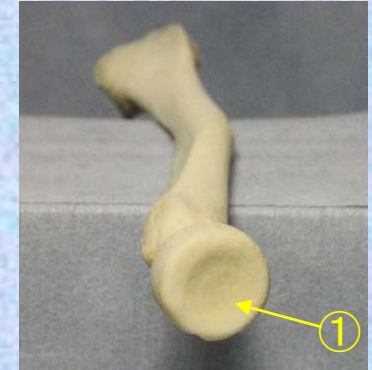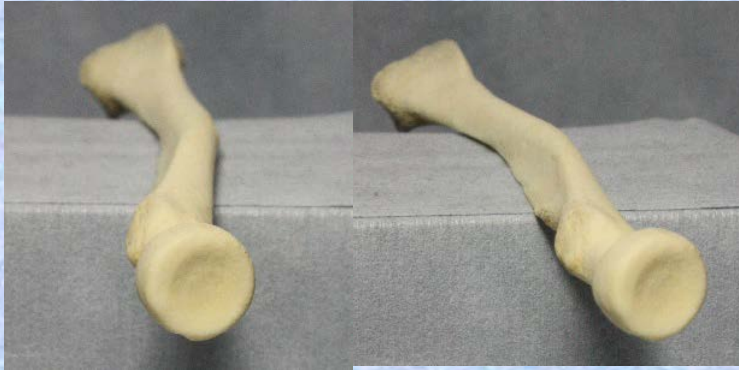


- ① 橈骨頭 head of radius
- ② 橈骨頸 neck of radius
- ③ 橈骨粗面 tuberosity of radius
- ④ 骨間緣 interosseous border
- ⑤ 外側面 lateral surface
- ⑥ 後緣 posterior border
- ⑦ 後面 posterior surface
- ⑧ 背側結節 dorsal tubercle
- ⑨ 莖狀突起 styloid process
- ⑩ 前斜線 anterior oblique line
- ⑪ 前面 anterior surface
- ⑫ 前緣 anterior border
- ⑬ 尺骨切痕 ulner notch



橈骨 radius 橈骨頭側 軸面

橈骨頭側 軸面 (Radius head of radius side)



- ① 橈骨頭 head of radius
- ② 橈骨頸 neck of radius
- ③ 橈骨粗面 tuberosity of radius
- ④ 骨間緣 interosseous border
- ⑤ 外側面 lateral surface
- ⑥ 後緣 posterior border
- ⑦ 後面 posterior surface

- ⑧ 背側結節 dorsal tubercle
- ⑨ 莖狀突起 styloid process
- ⑩ 前斜線 anterior oblique line
- ⑪ 前面 anterior surface
- ⑫ 前緣 anterior border
- ⑬ 尺骨切痕 ulner notch



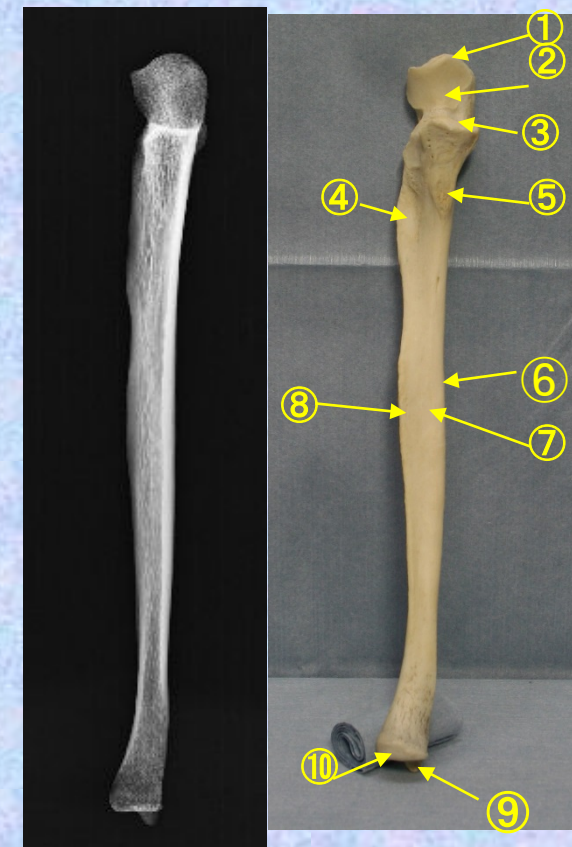
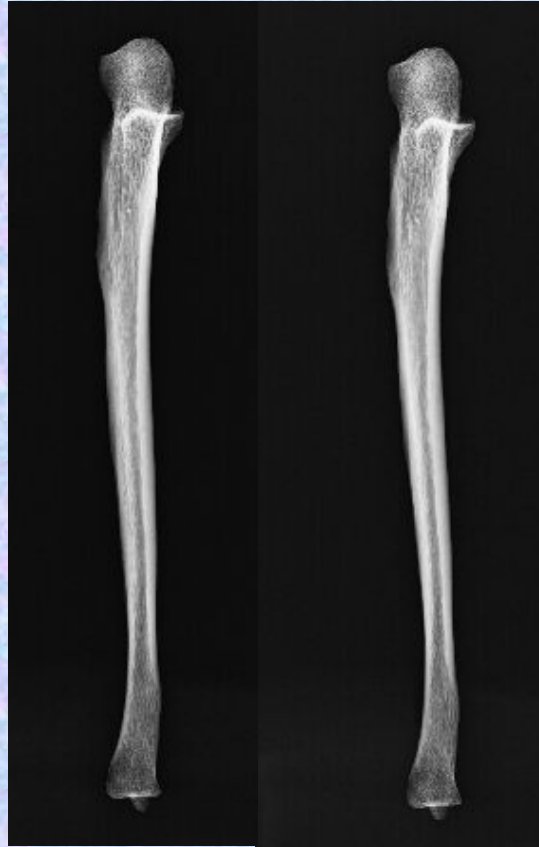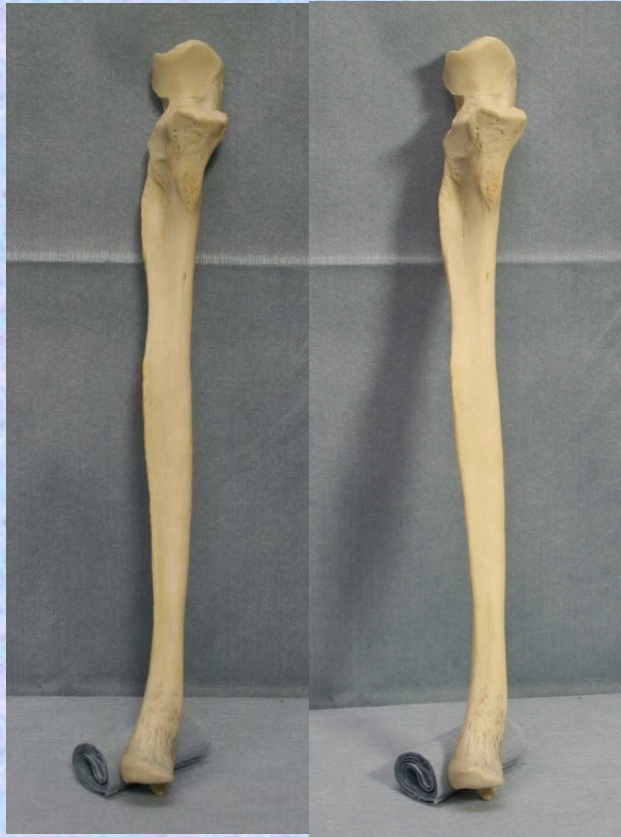尺骨

ulna



尺骨 ulna 前面

前面 (Ulna anterior view)



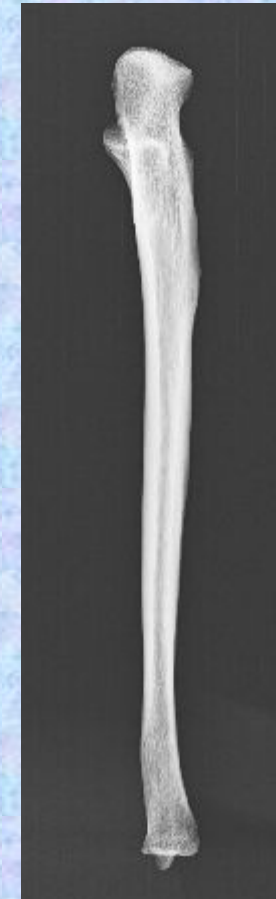
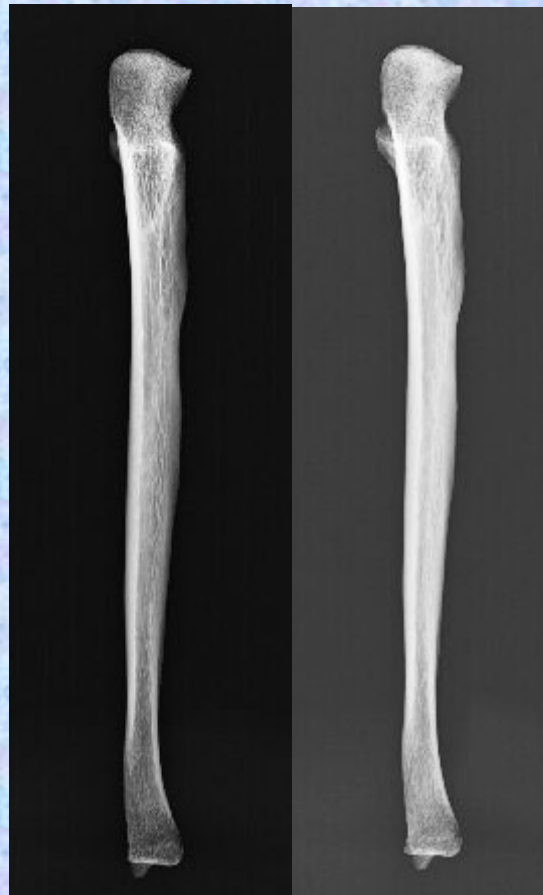- ① 肘頭 olecranon
- ② 滑車切痕 torochlear notch
- ③ 鉤(こう)状突起 coronoid process
- ④ 回外筋稜 supinator crest
- ⑤ 尺骨粗面 tuberosity of ulna
- ⑥ 前縁 anterior border
- ⑦ 前面 anterior surface
- ⑧ 骨間縁 interosseous border
- ⑨ 茎状突起 styloid process

- ⑩ 尺骨頭 head of ulna
- ⑪ 内側面 medial surface
- ⑫ 外側上顆 lateral epicondyle
- ⑬ 後縁 posterior border
- ⑭ 後面 posterior surface



尺骨 ulna 後面

後面 (Ulna posterior view)



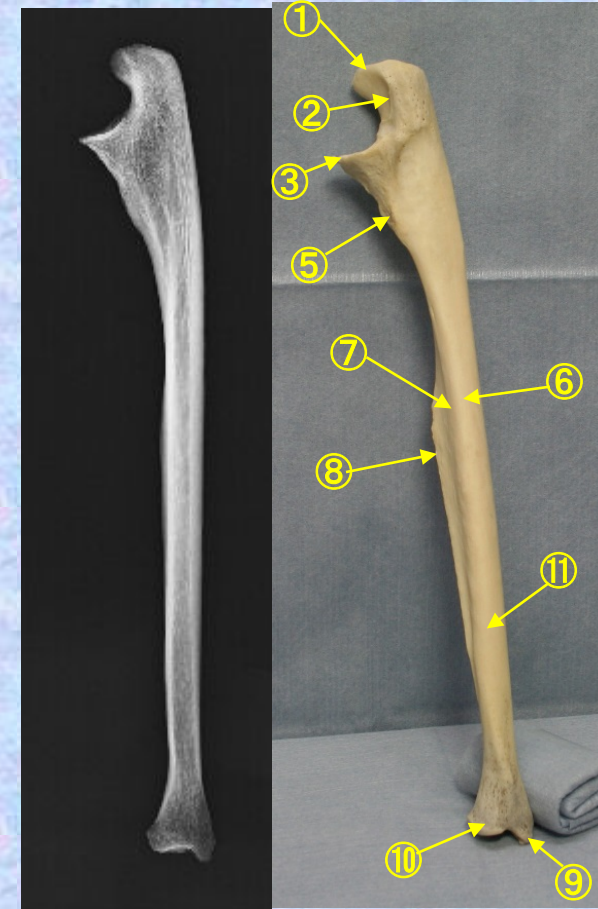
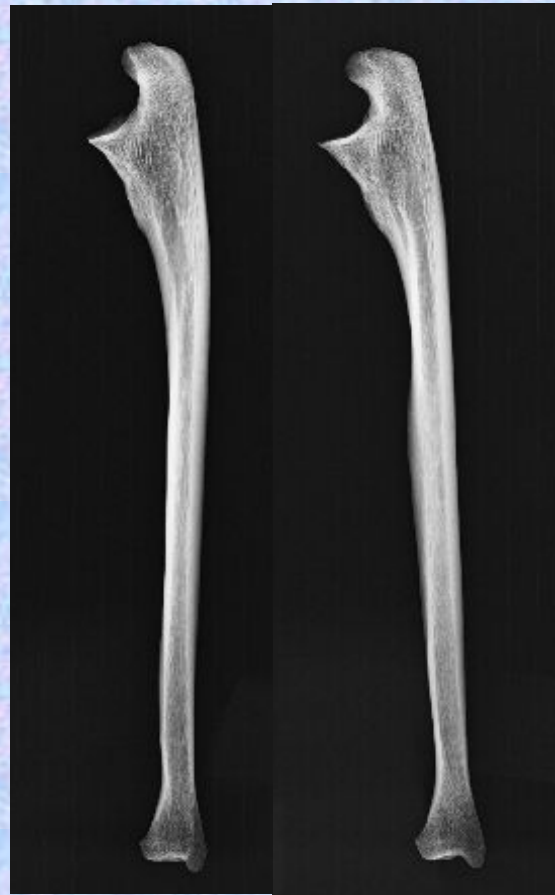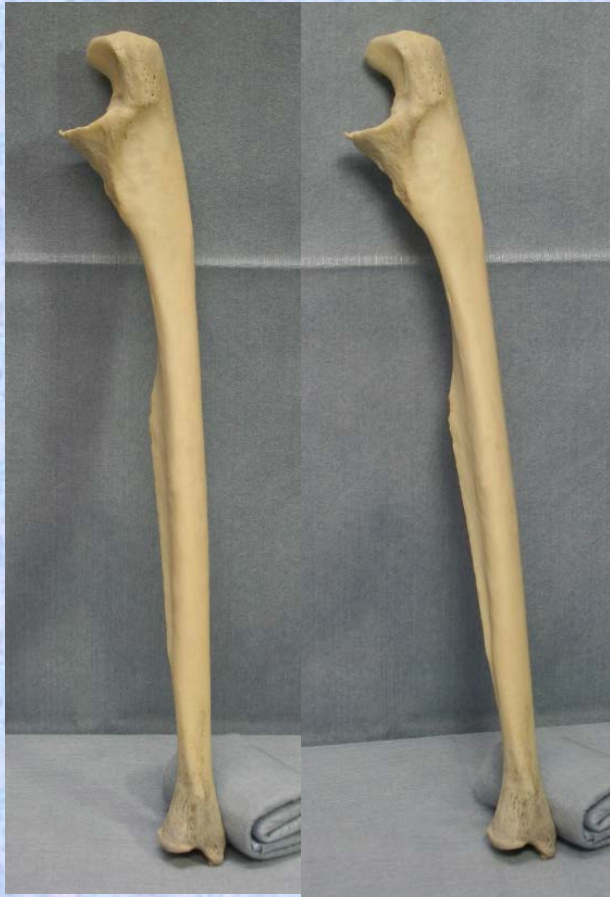- ① 肘頭 olecranon
- ② 滑車切痕 torochlear notch
- ③ 鉤 (こう) 状突起 coronoid process
- ④ 回外筋稜 supinator crest
- ⑤ 尺骨粗面 tuberosity of ulna
- ⑥ 前縁 anterior border
- ⑦ 前面 anterior surface
- ⑧ 骨間縁 interosseous border
- ⑨ 茎状突起 styloid process

- ⑩ 尺骨頭 head of ulna
- ⑪ 内側面 medial surface
- ⑫ 外側上顆 lateral epicondyle
- ⑬ 後縁 posterior border
- ⑭ 後面 posterior surface



尺骨 ulna 内側面

内側面 (Ulna medial view)



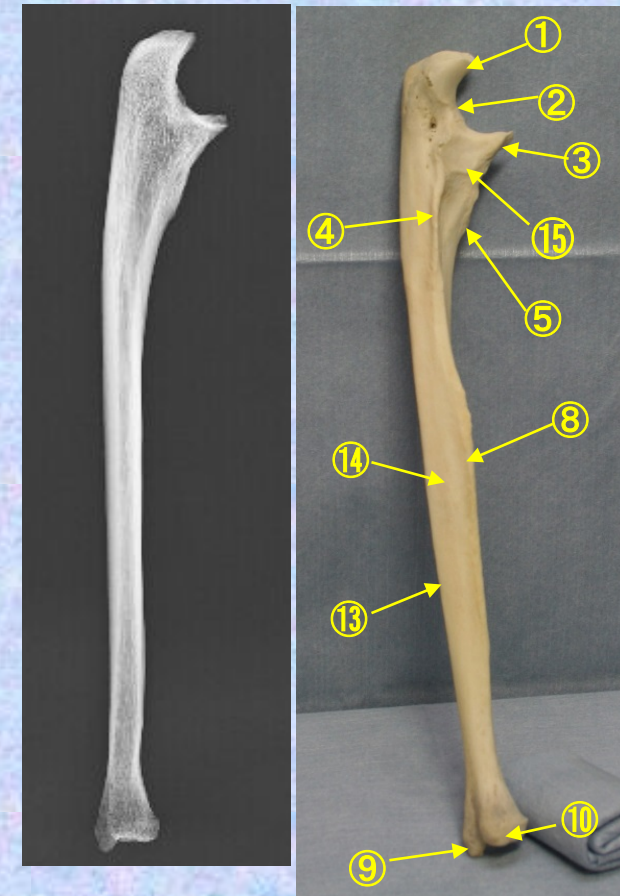
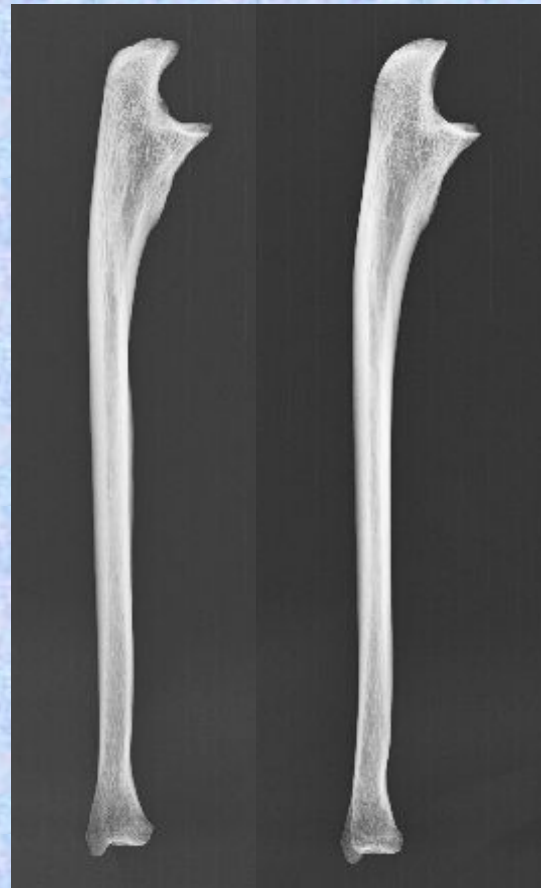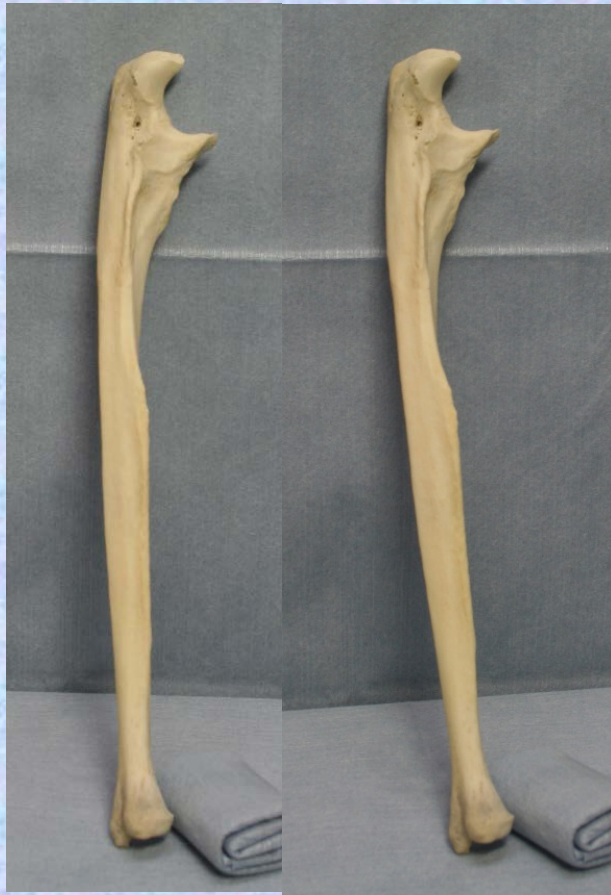- ① 肘頭 olecranon
- ② 滑車切痕 trochlear notch
- ③ 鉤(こう)状突起 coronoid process
- ④ 回外筋稜 supinator crest
- ⑤ 尺骨粗面 tuberosity of ulna
- ⑥ 前縁 anterior border
- ⑦ 前面 anterior surface
- ⑧ 骨間縁 interosseous border
- ⑨ 茎状突起 styloid process

- ⑩ 尺骨頭 head of ulna
- ⑪ 内側面 medial surface
- ⑫ 外側上顆 lateral epicondyle
- ⑬ 後縁 posterior border
- ⑭ 後面 posterior surface
- ⑮ 橈骨切痕 radial notch



尺骨 ulna 外側面

外側面 (Ulna lateral view)



- ① 肘頭 olecranon
- ② 滑車切痕 torochlear notch
- ③ 鉤(こう)状突起 coronoid process
- ④ 回外筋稜 supinator crest
- ⑤ 尺骨粗面 tuberosity of ulna
- ⑥ 前縁 anterior border
- ⑦ 前面 anterior surface
- ⑧ 骨間縁 interosseous border
- ⑨ 茎状突起 styloid process

- ⑩ 尺骨頭 head of ulna
- ⑪ 内側面 medial surface
- ⑫ 外側上顆 lateral epicondyle
- ⑬ 後縁 posterior border
- ⑭ 後面 posterior surface
- ⑮ 橈骨切痕 radial notch



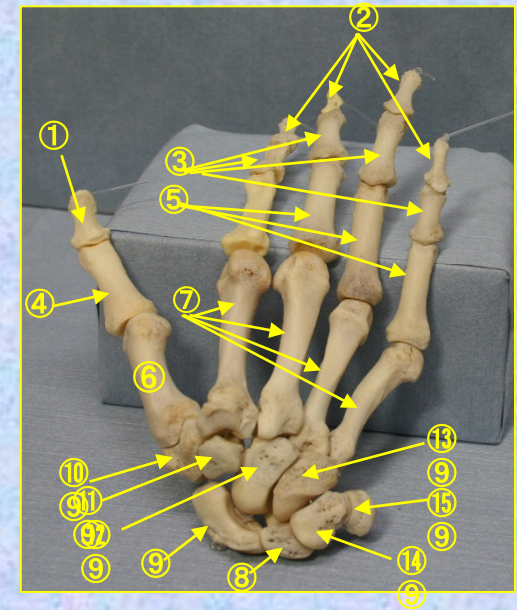
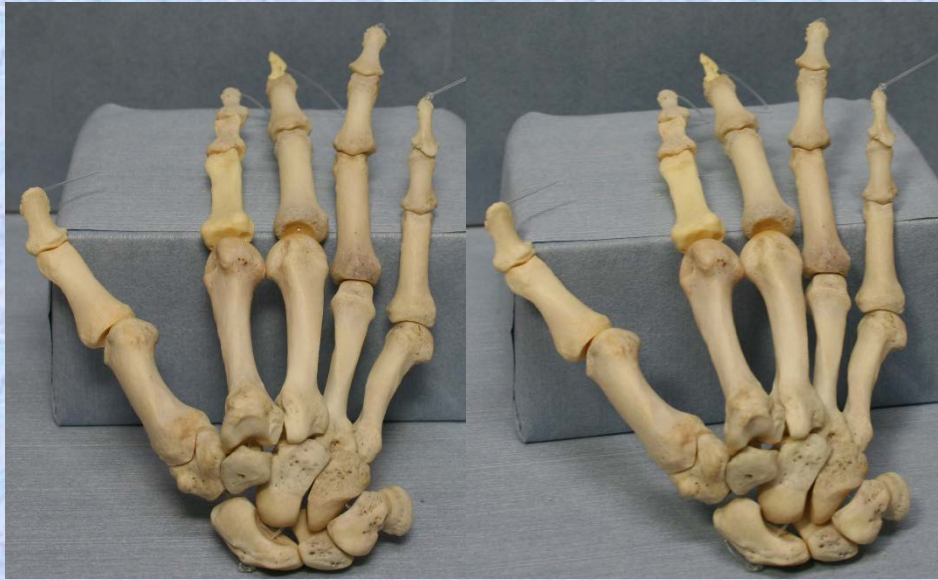手

hand

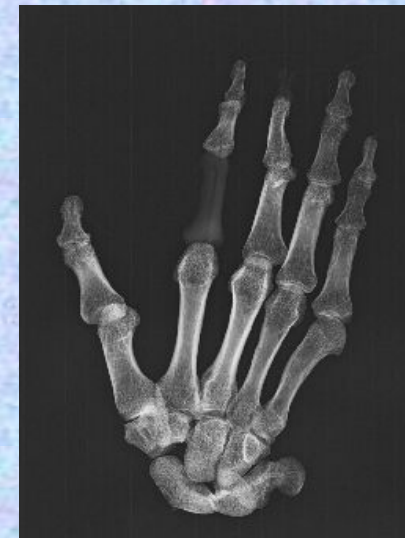
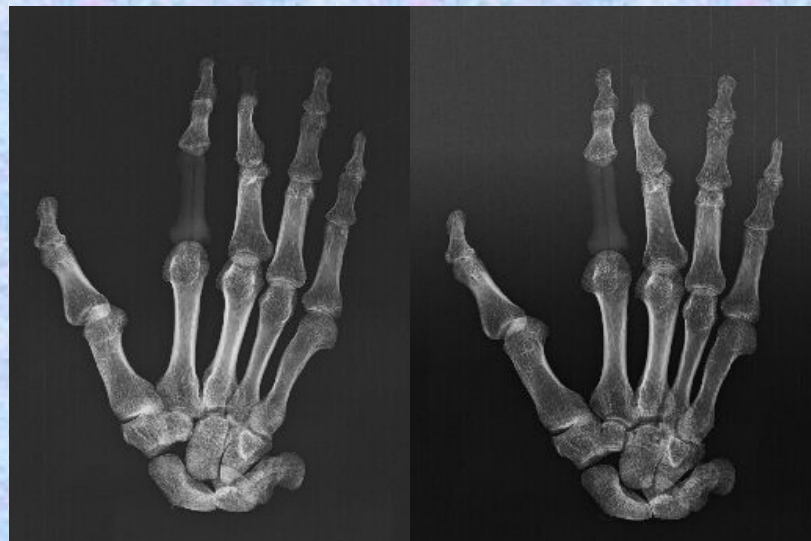
手 hand 手背面

手掌面 (Hand dorsum of hand)

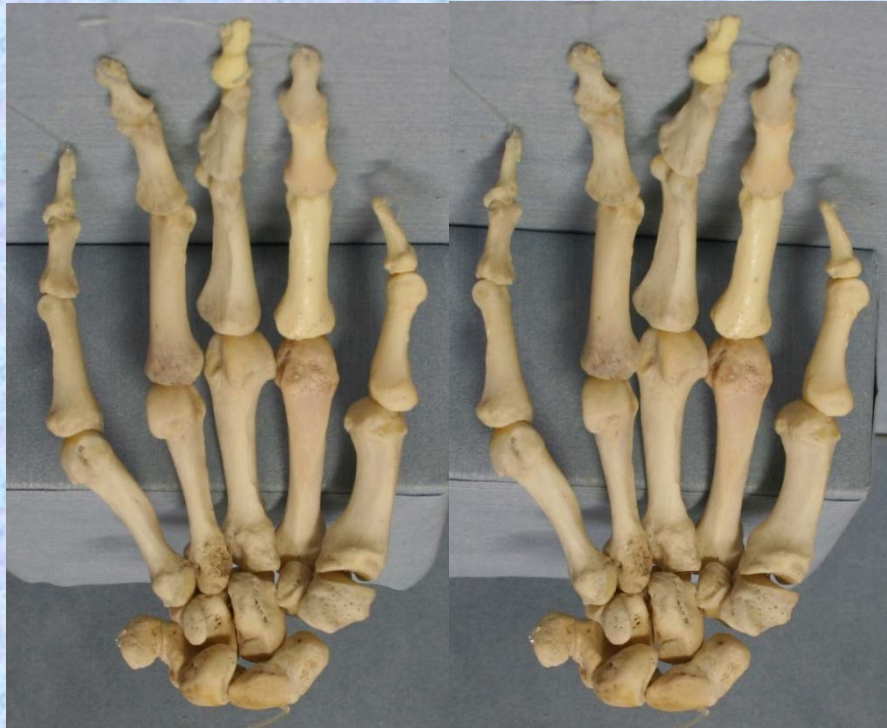

- ①末節骨(母指) distal phalanx of thumb
- ②末節骨(第2~5指) distal phalanx(2~5)
- ③中節骨(第2~5指) middle phalanx(2~5)
- ④基節骨(母指) proximal phalanx of thumb
- ⑤基節骨(第2~5指) proximal phalanx of
finger (2:index 3:middle 4:ring 5:little)
- ⑥第1中手骨の体 shaft of first metatarsal
- ⑦第2~5中手7骨の体 shaft of second
metatarsal~shaft of fifth metatarsal
- ⑧ 月状骨 lunate
- ⑨ 舟状骨 scaphoid
- ⑩ 大菱形骨 trapezium
- ⑪ 小菱形骨 trapezoid
- ⑫ 有頭骨 capitate
- ⑬ 有鉤骨 hamate
- ⑭ 三角骨 triquetral
- ⑮ 豆状骨 pisiform

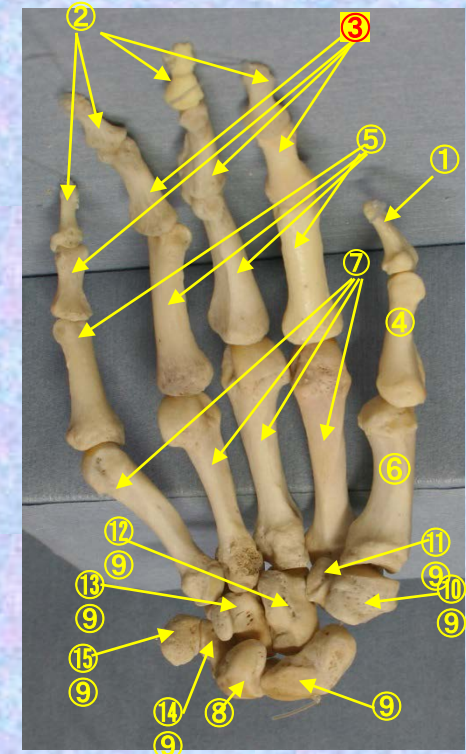


手 hand 手掌面

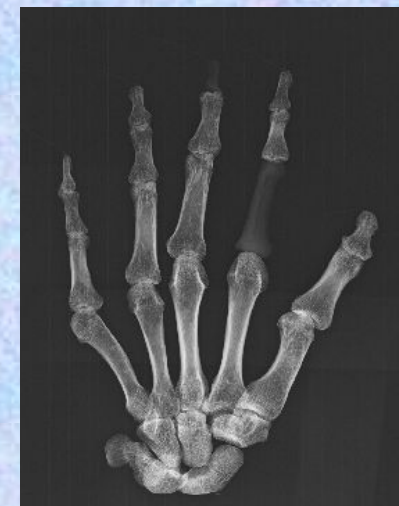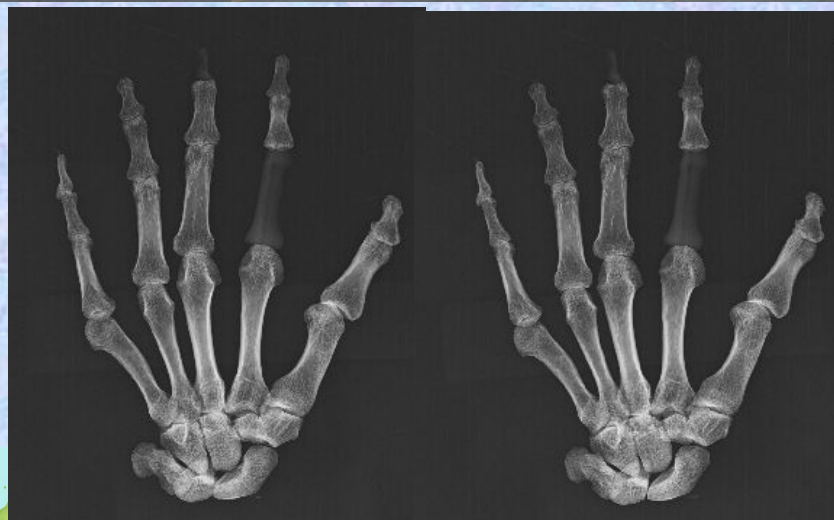手掌面 (Hand palmar view)

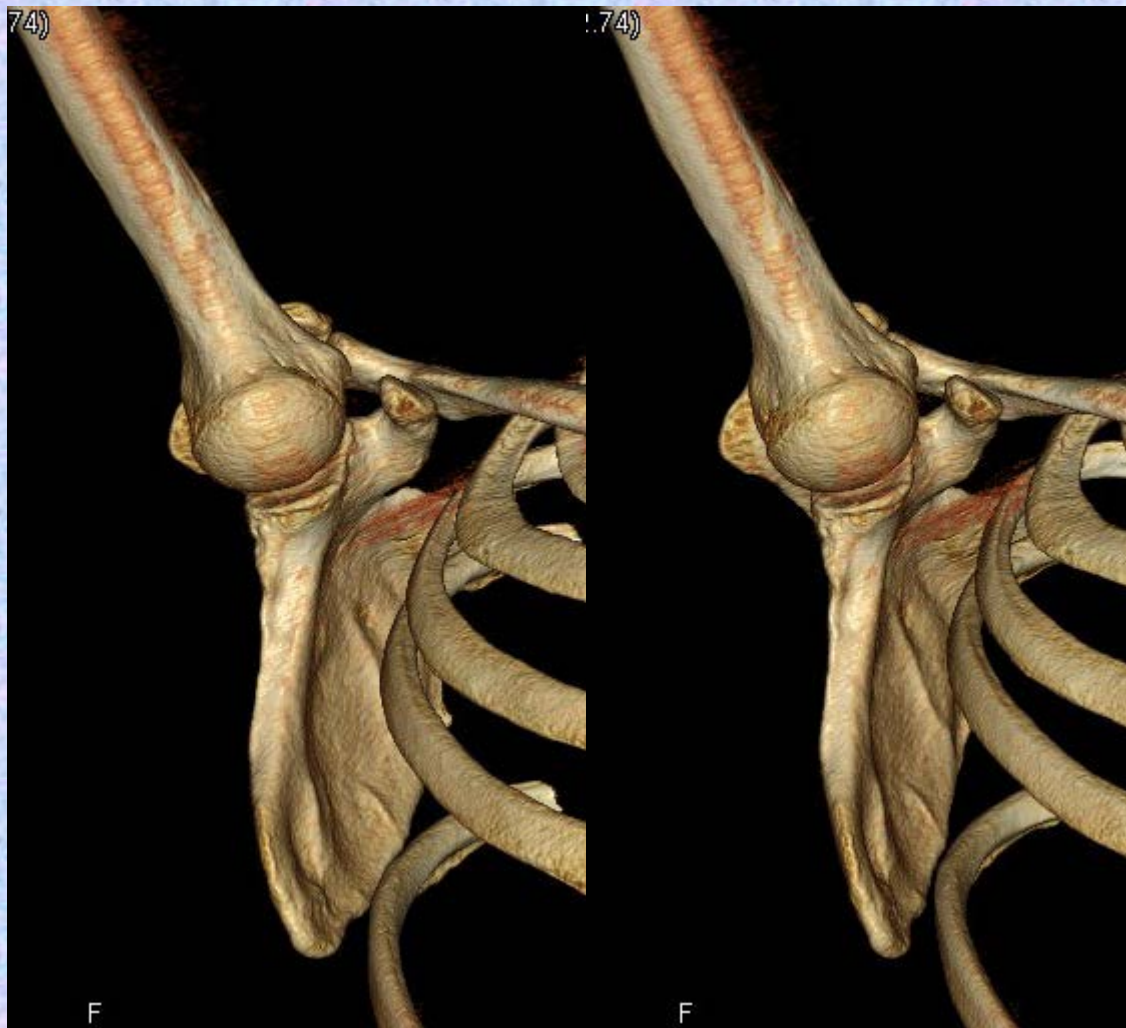


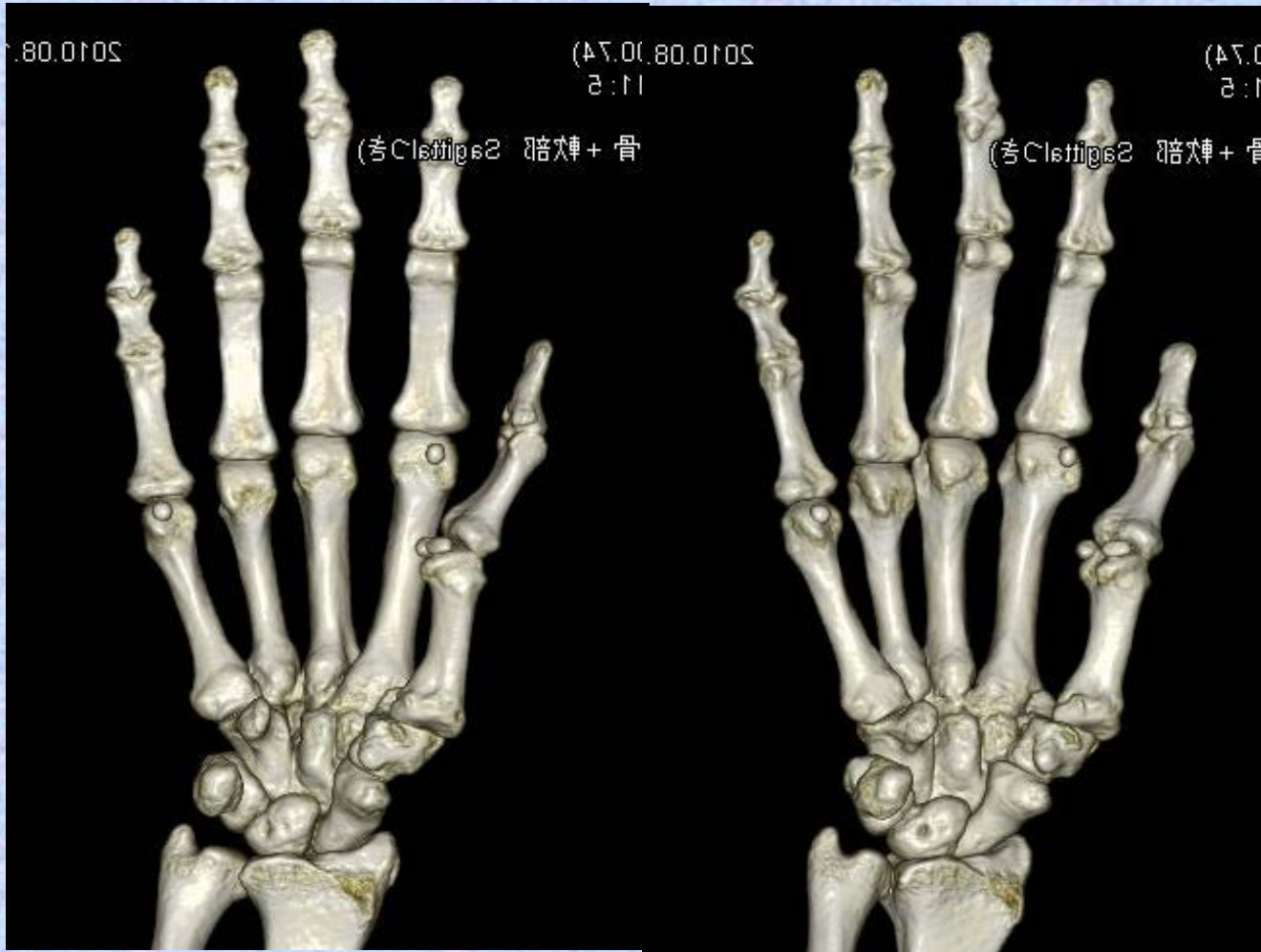- ①末節骨(母指)
distal phalanx of thumb
- ②末節骨(第2~5指)
distal phalanx(2~5)
- ③中節骨(第2~5指)
middle phalanx(2~5)
- ④基節骨(母指)
proximal phalanx of thumb
- ⑤基節骨(第2~5指)
proximal phalanx of finger
(2:index 3:middle 4:ring 5:little)
- ⑥第1中手骨の体
shaft of first metatarsal
- ⑦第2~5中手7骨の体
shaft of second
metatarsal~shaft of fifth metatarsal



- ⑧ 月状骨 lunate
- ⑨ 舟状骨 scaphoid
- ⑩ 大菱形骨 trapezium
- ⑪ 小菱形骨 trapezoid
- ⑫ 有頭骨 capitate
- ⑬ 有鉤骨 hamate
- ⑭ 三角骨 triquetral
- ⑮ 豆状骨 pisiform



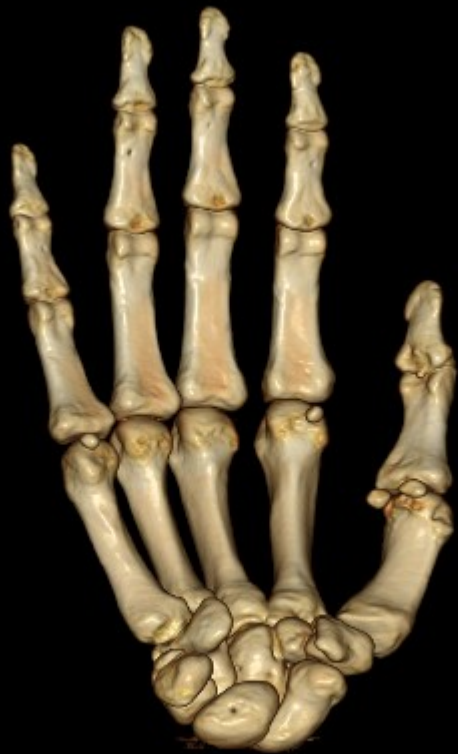



250.00mm(251.47)

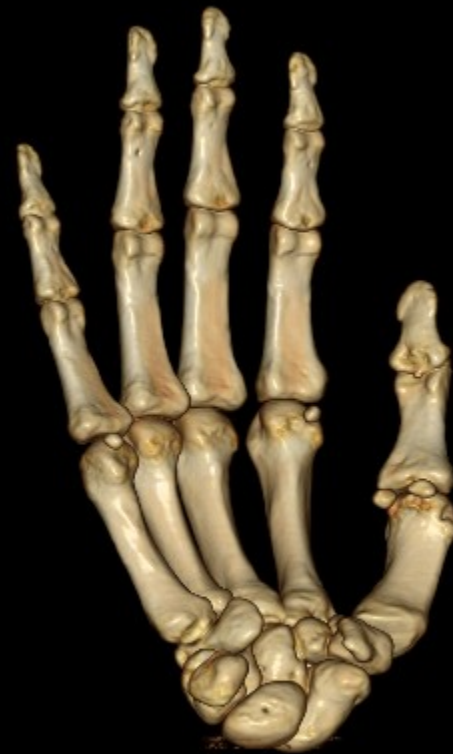250.00mm(251.47)

R



F

R



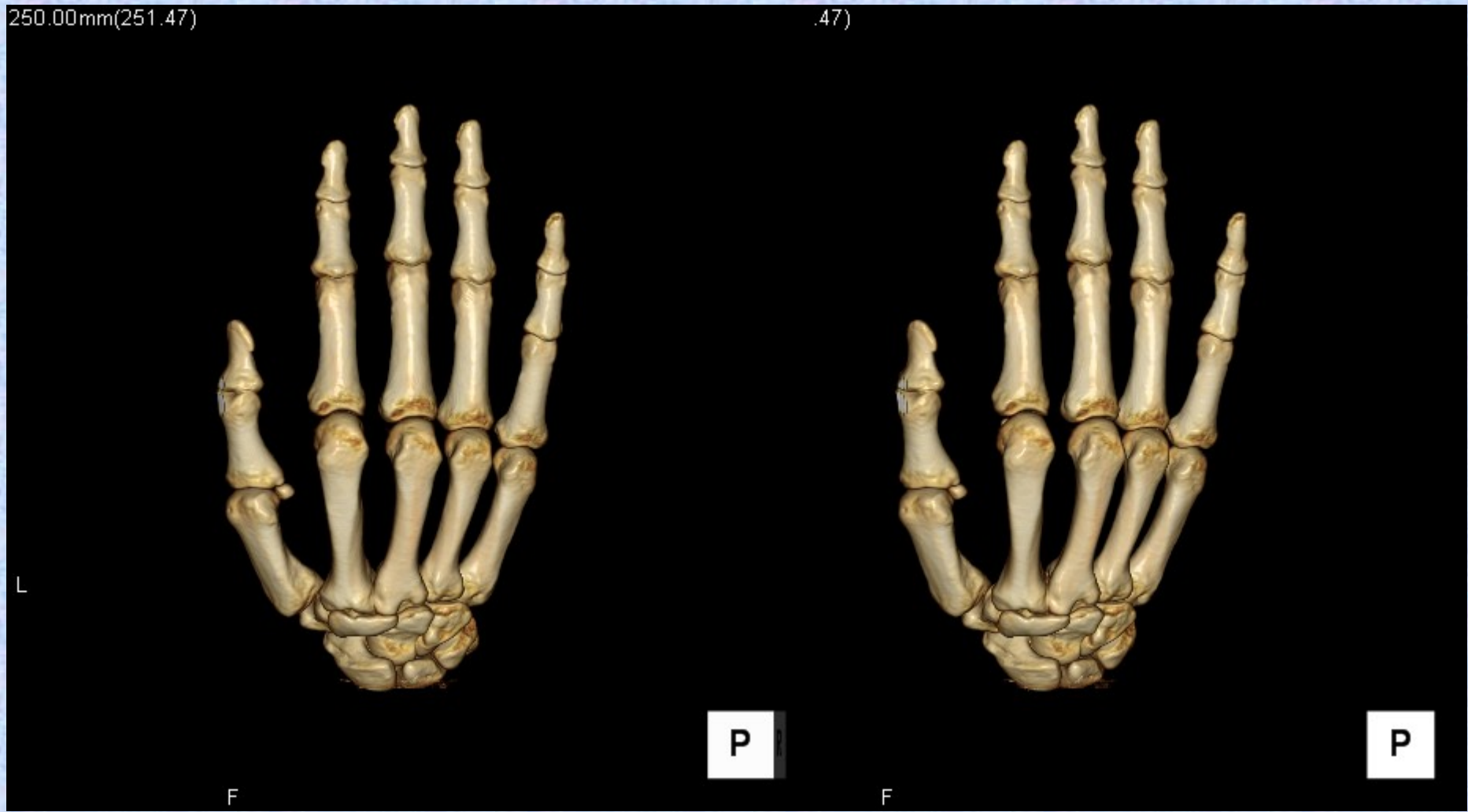
F

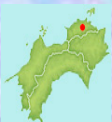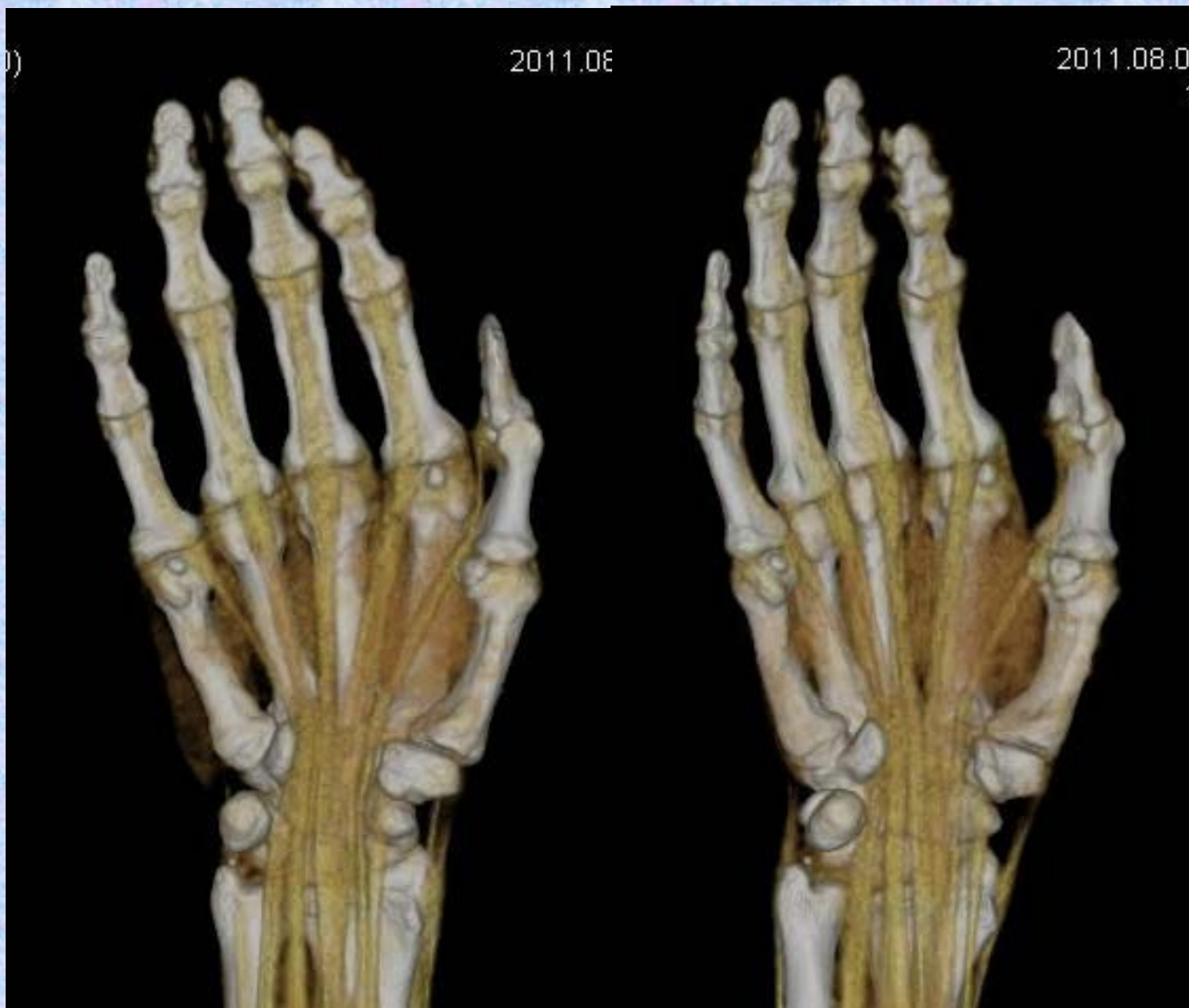A


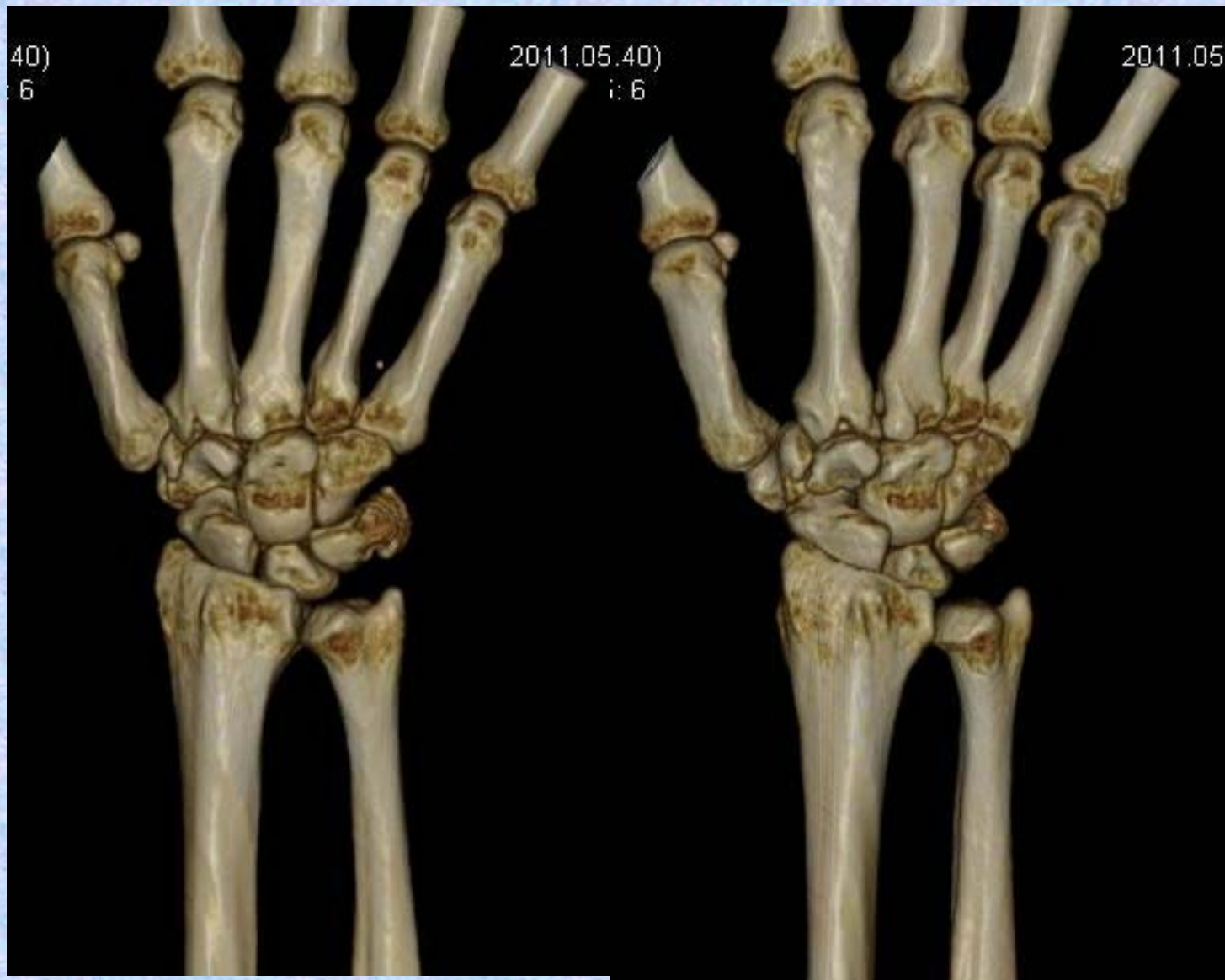
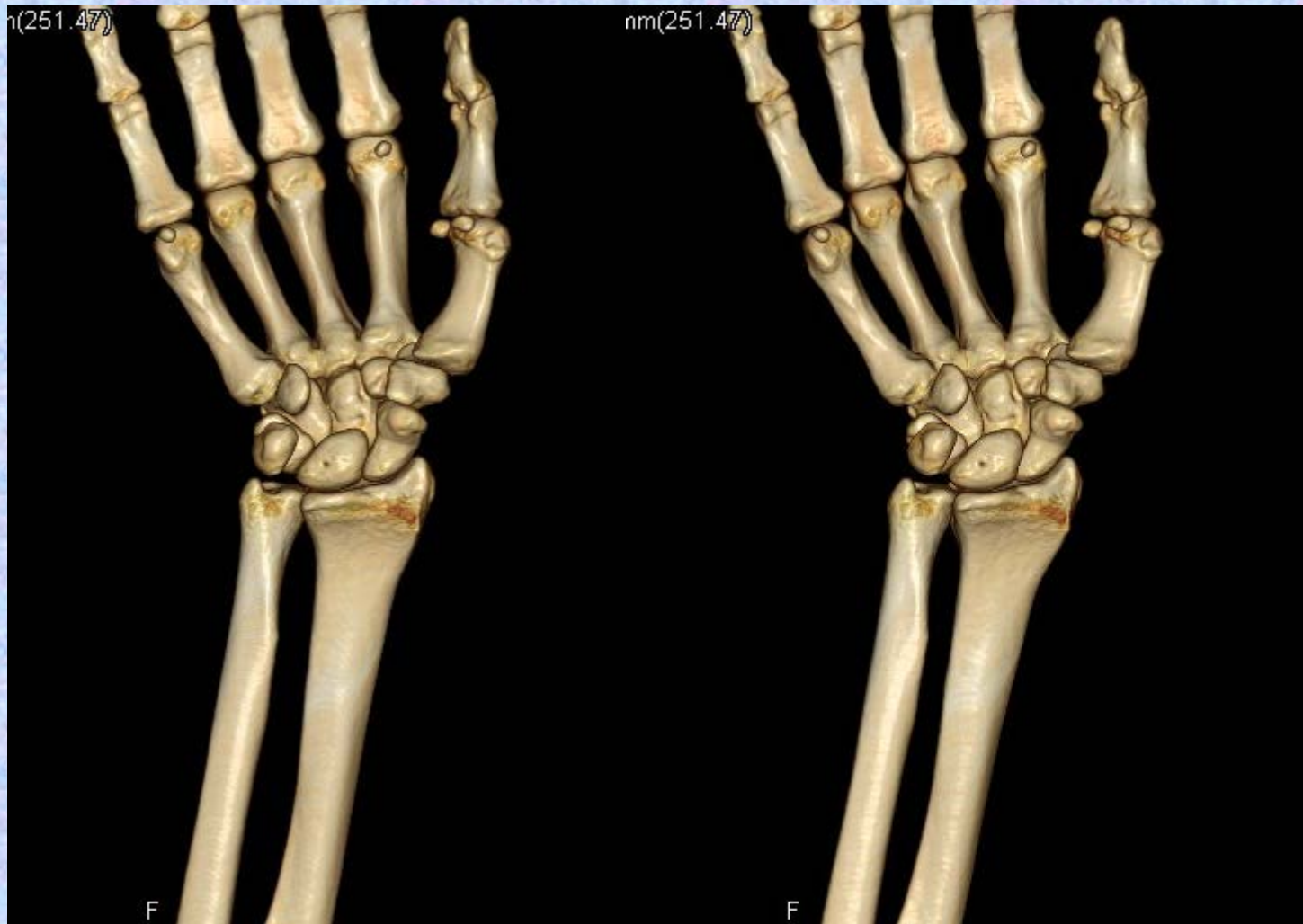
250.00mm(251.47)

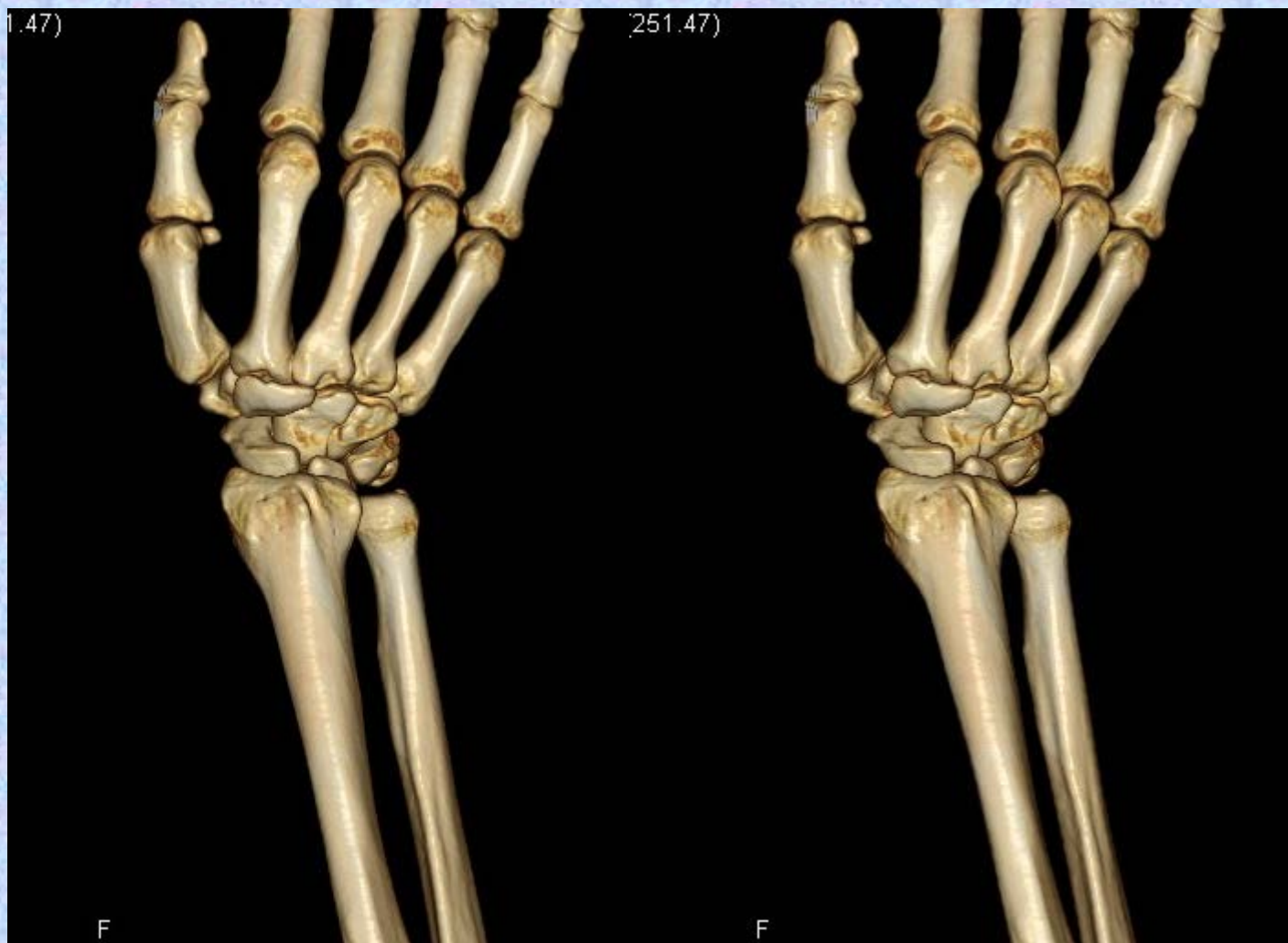
.47)


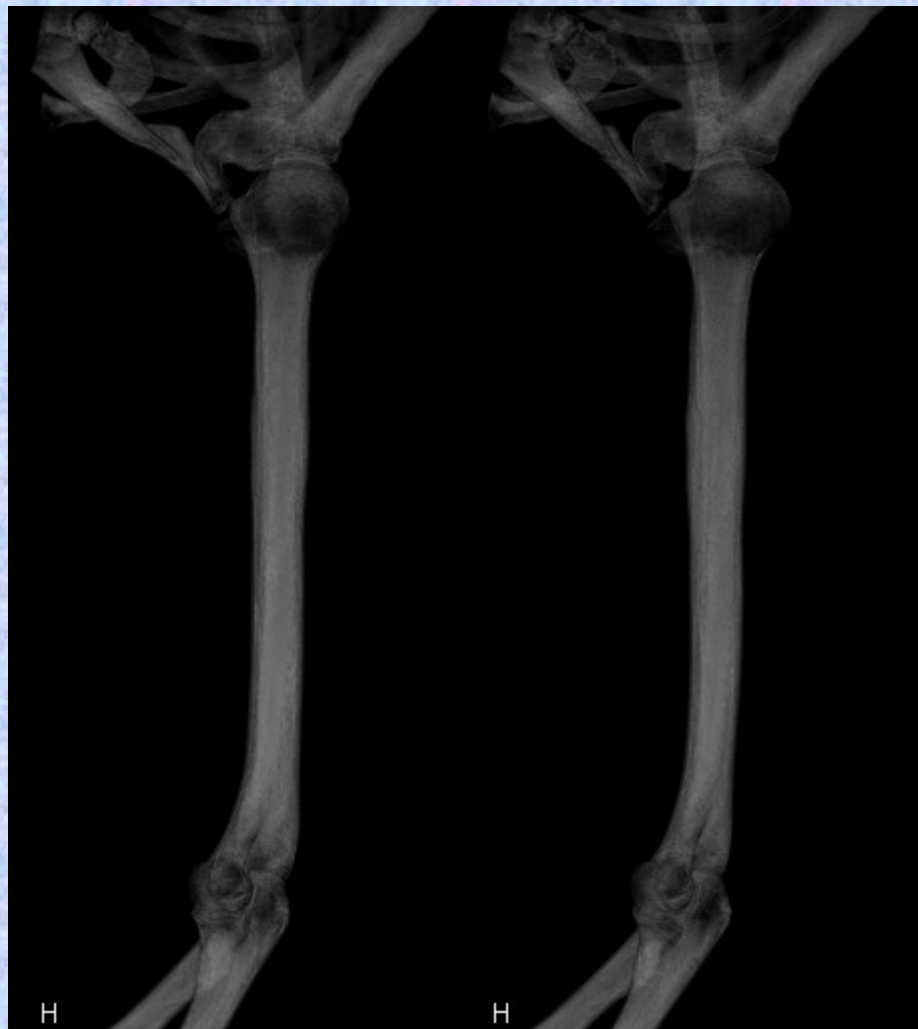
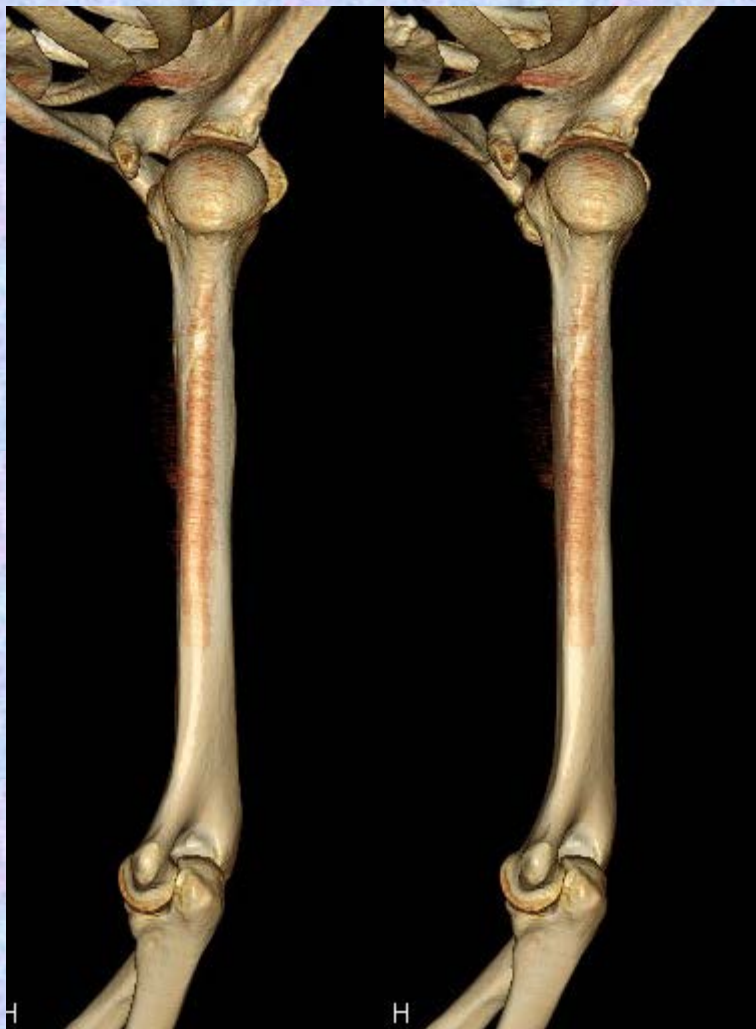



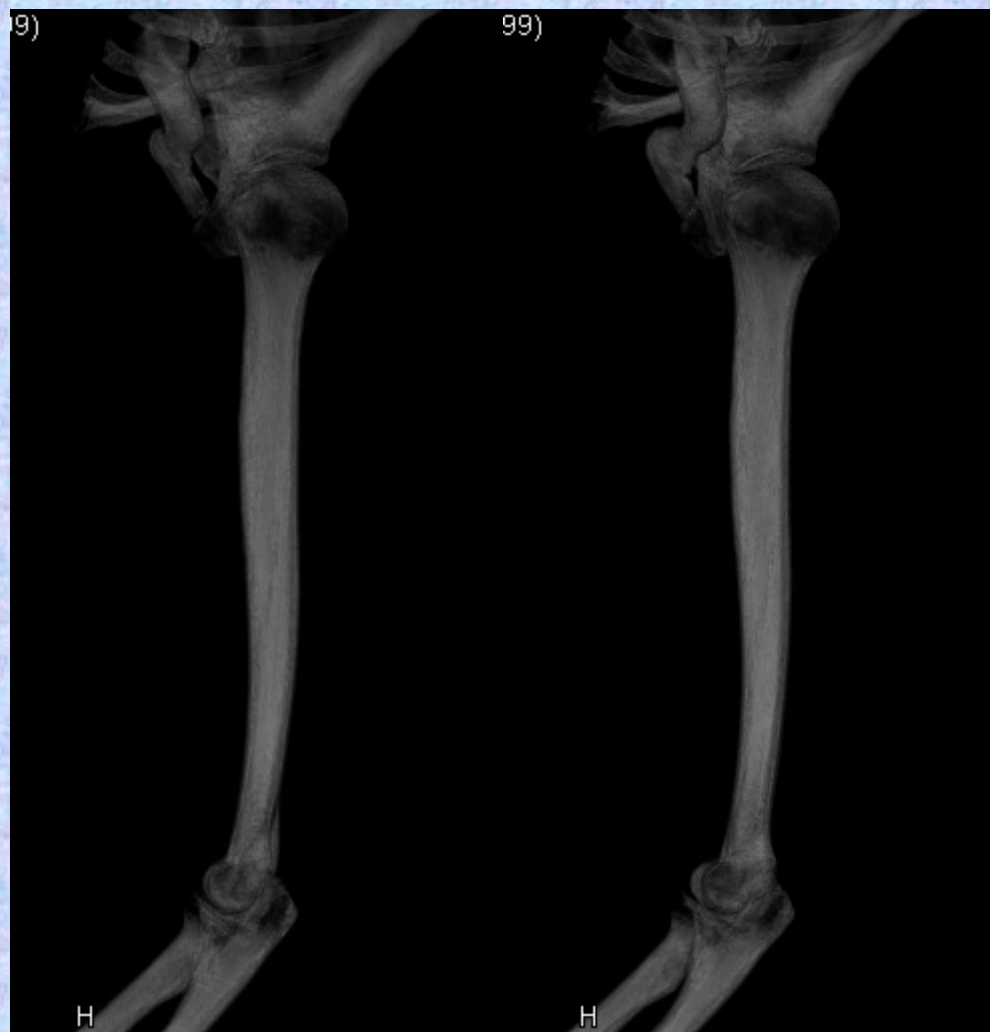
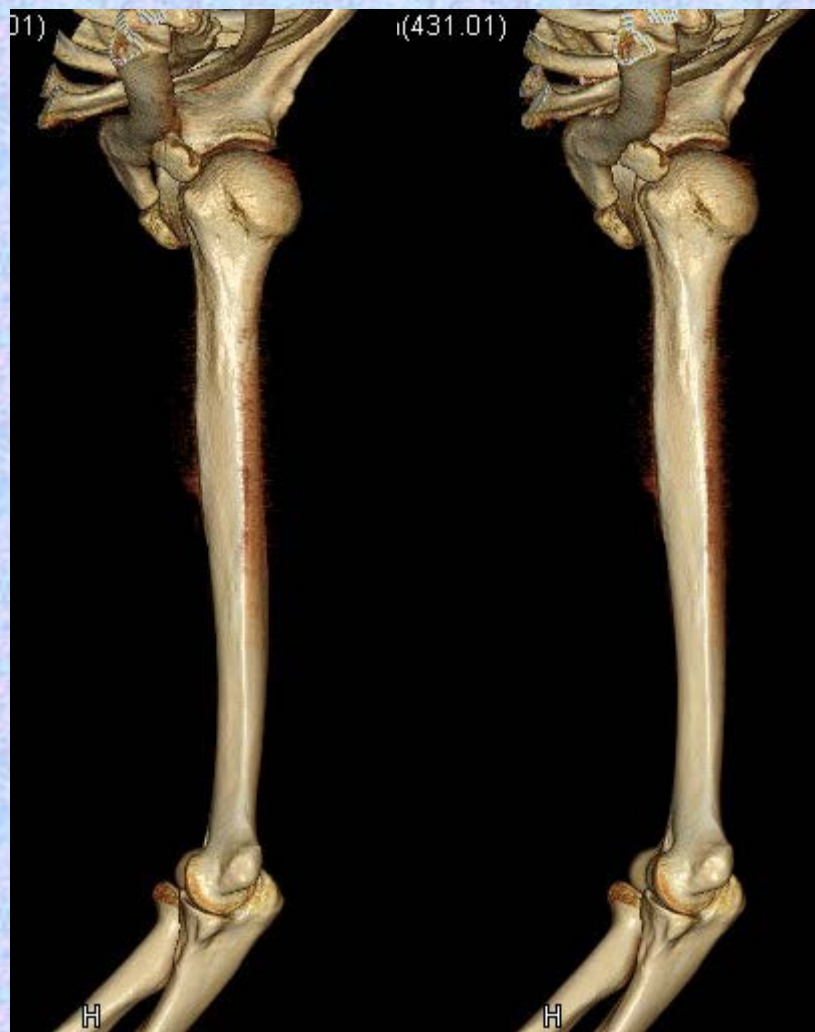



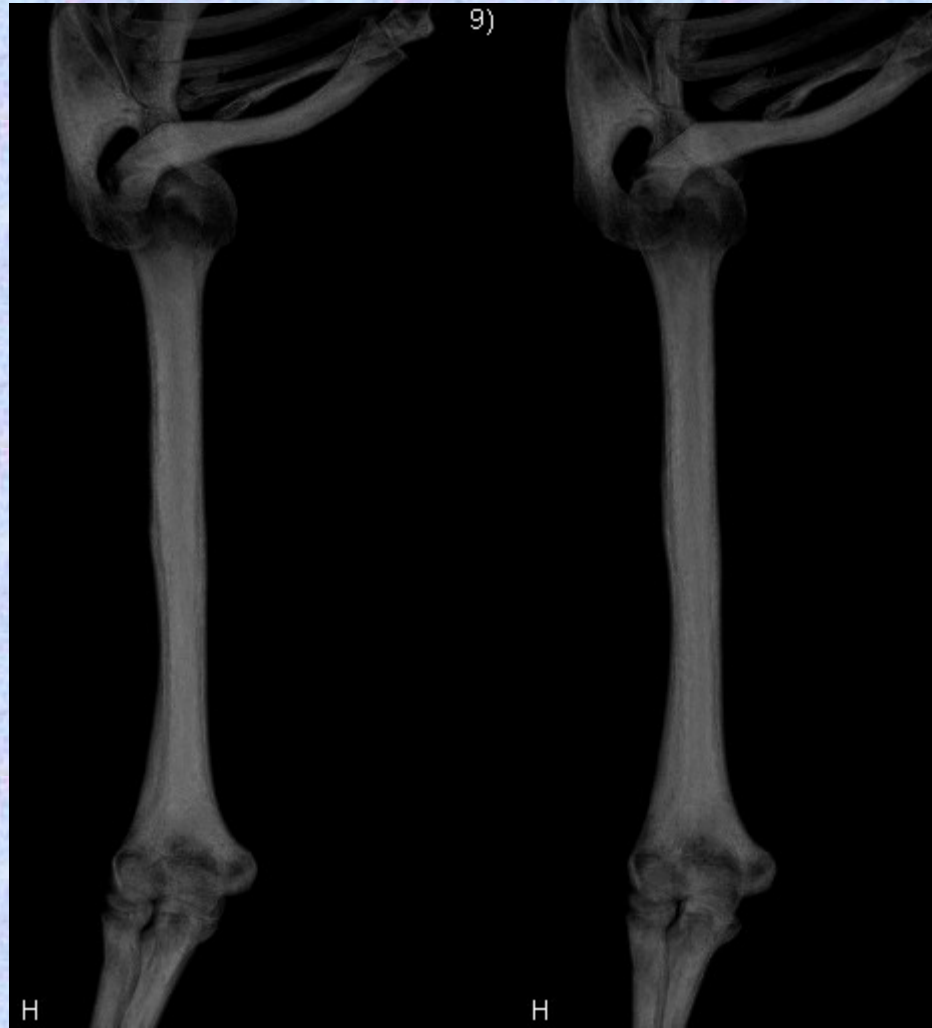
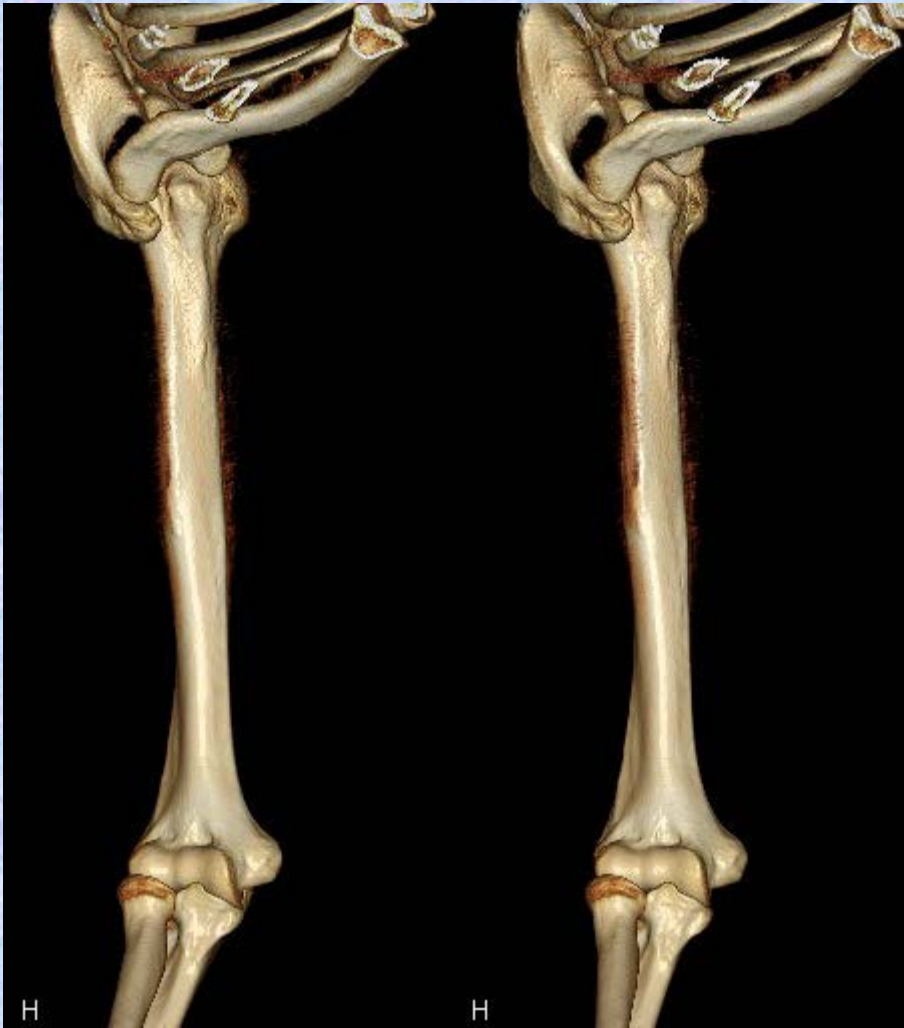



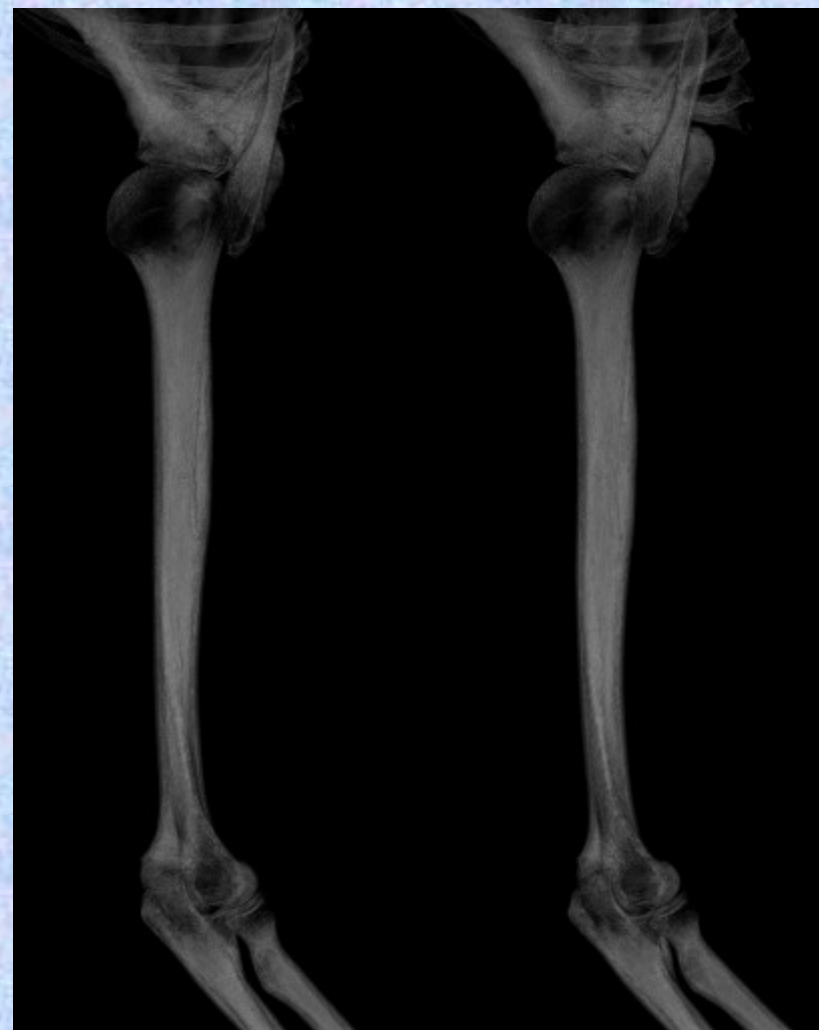
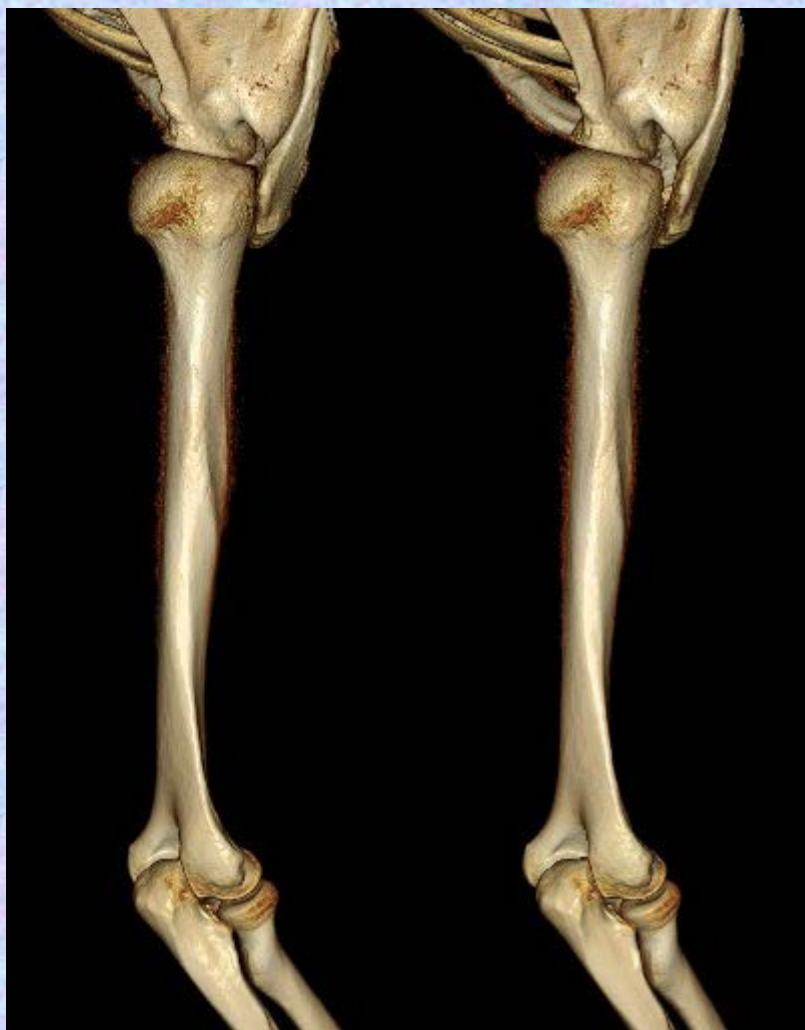



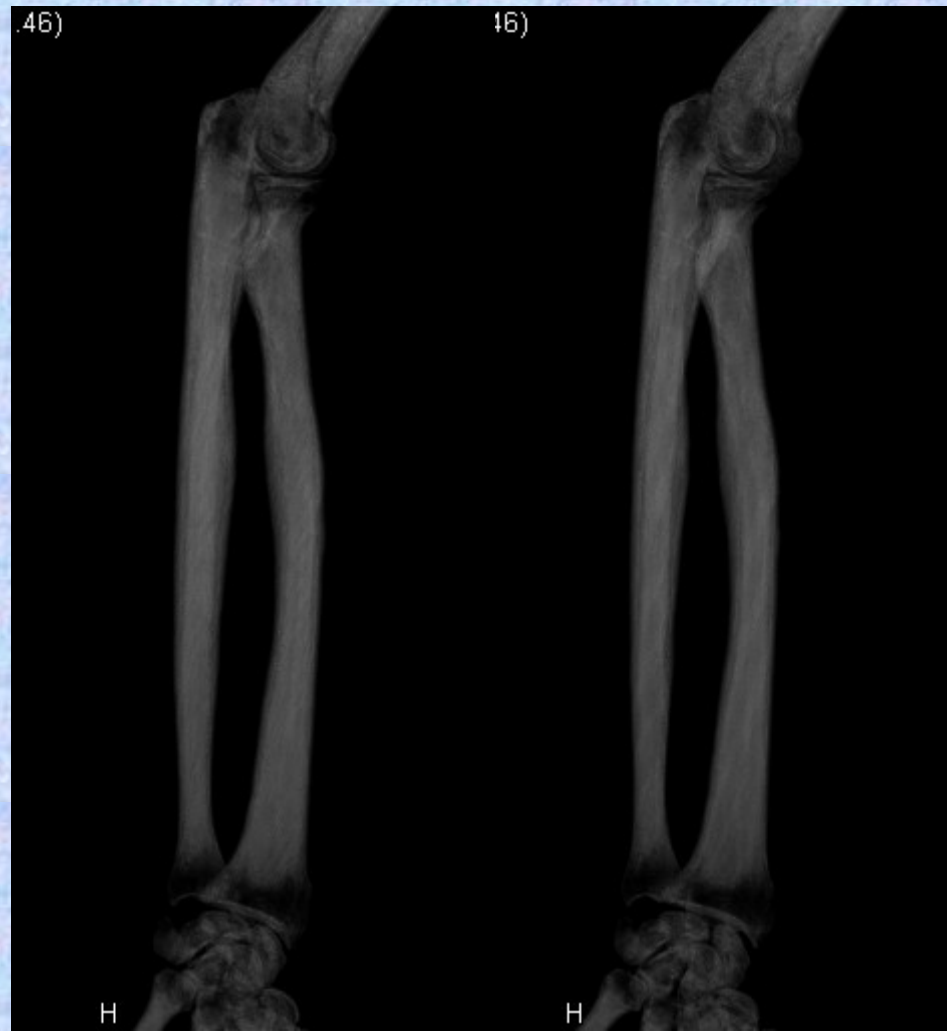
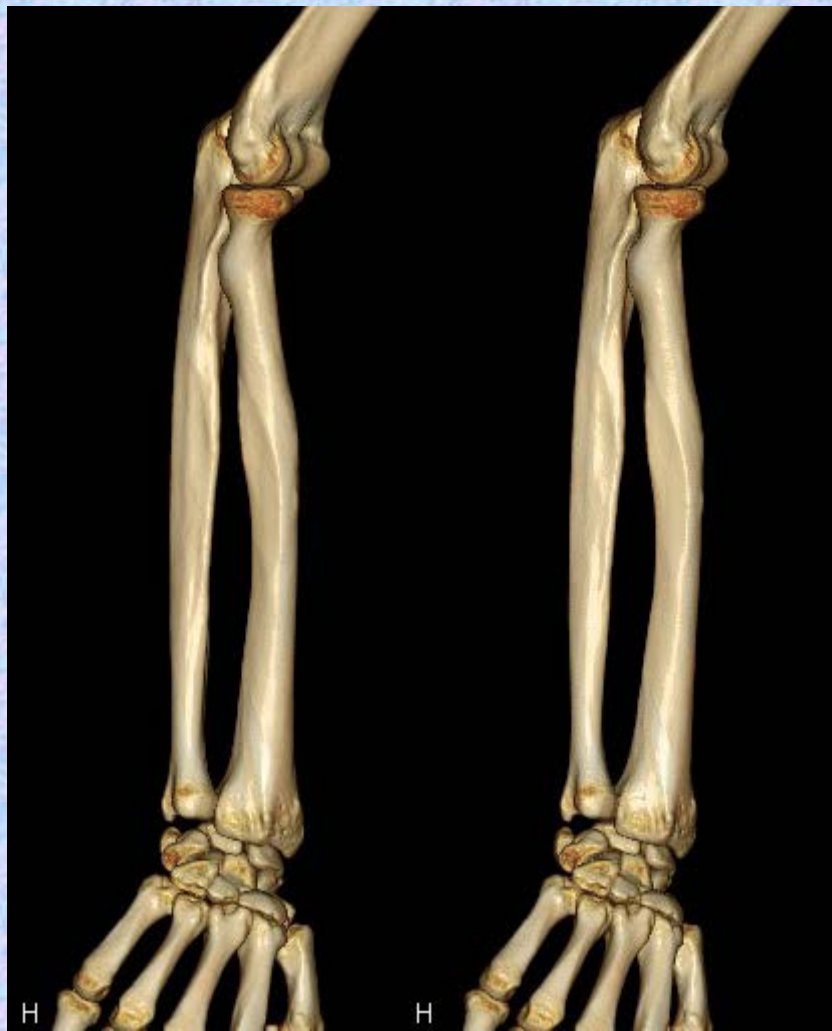

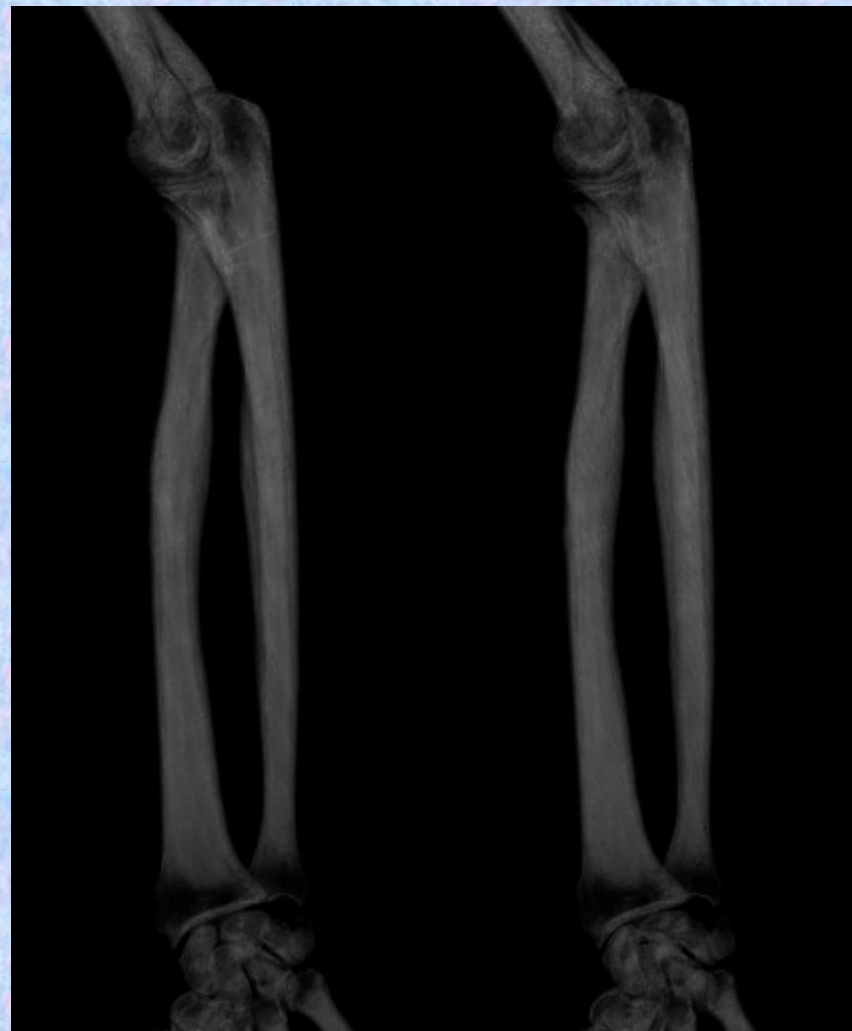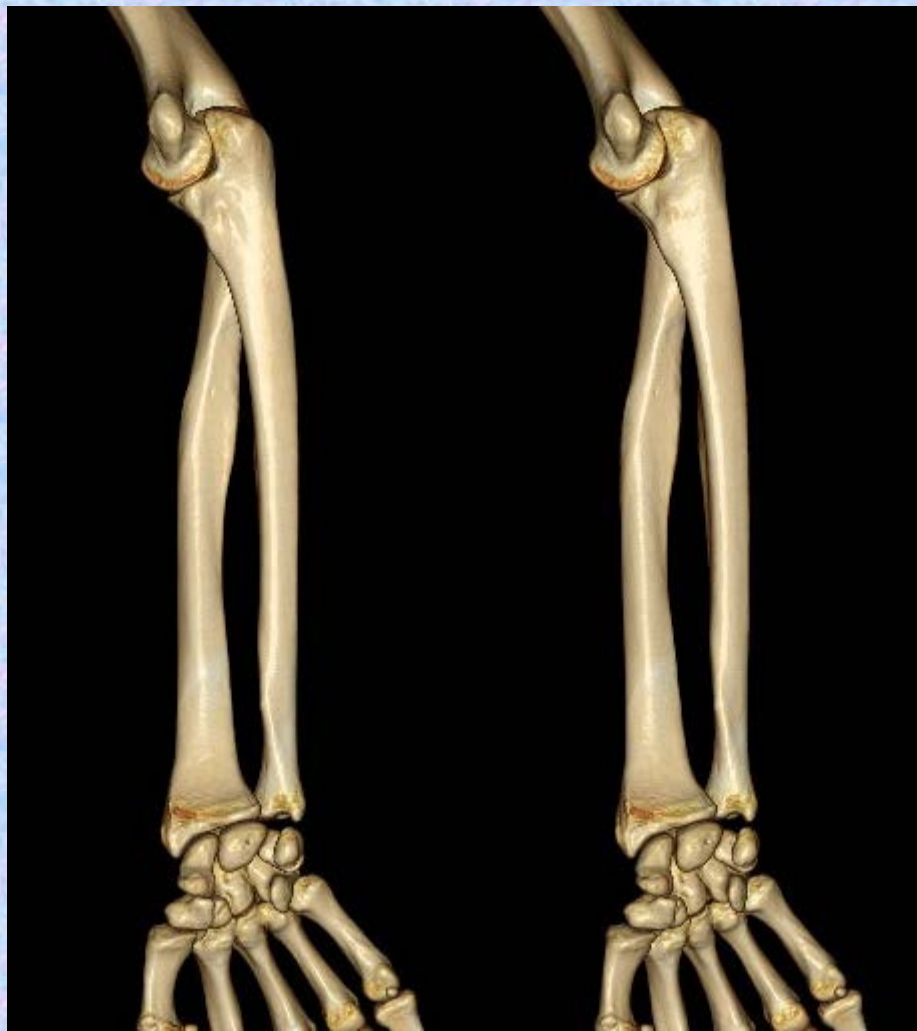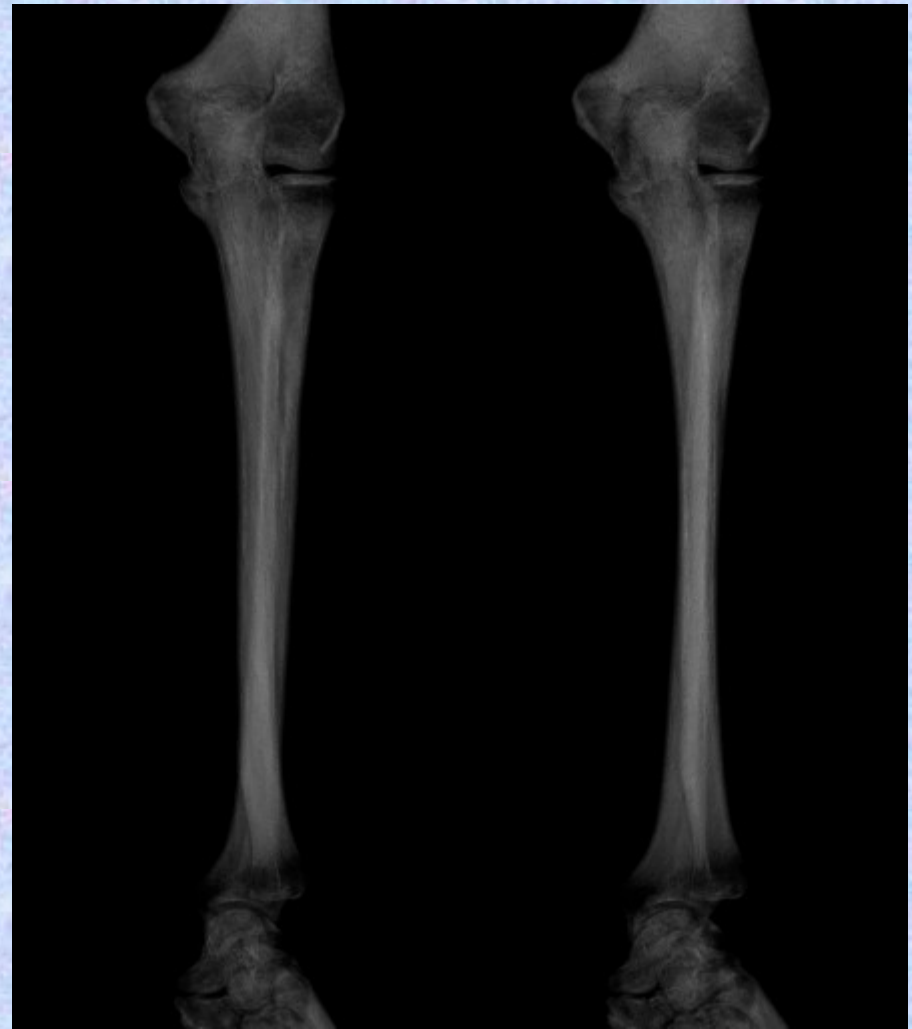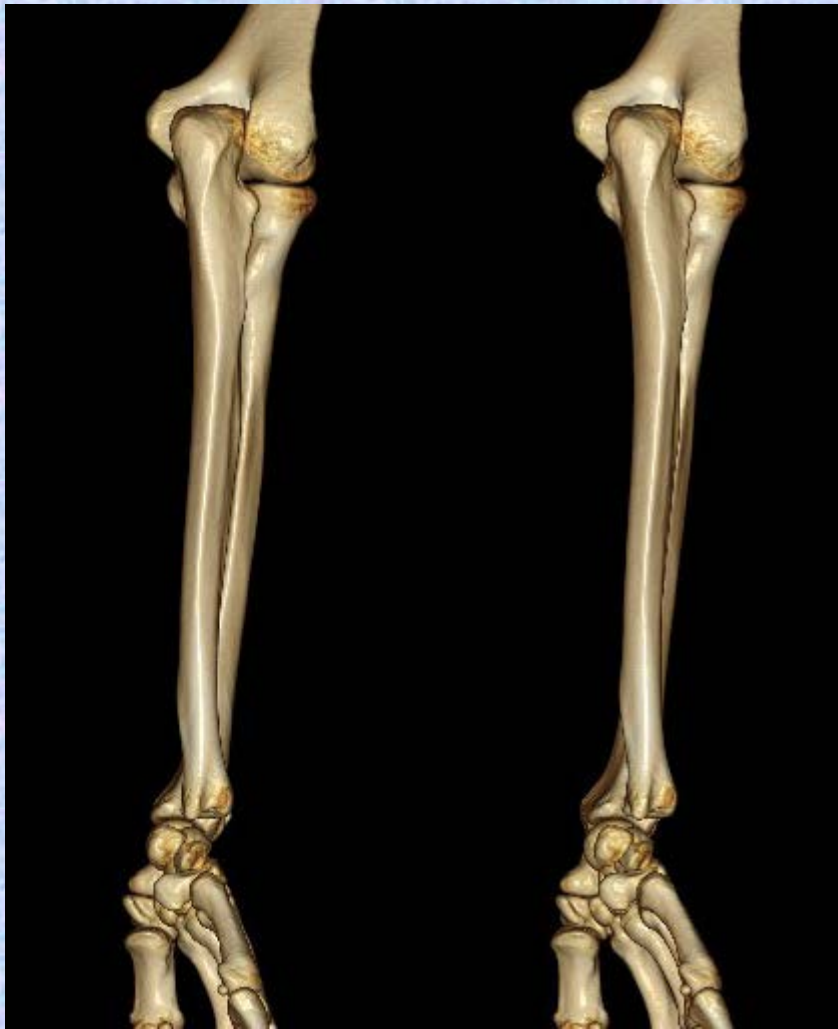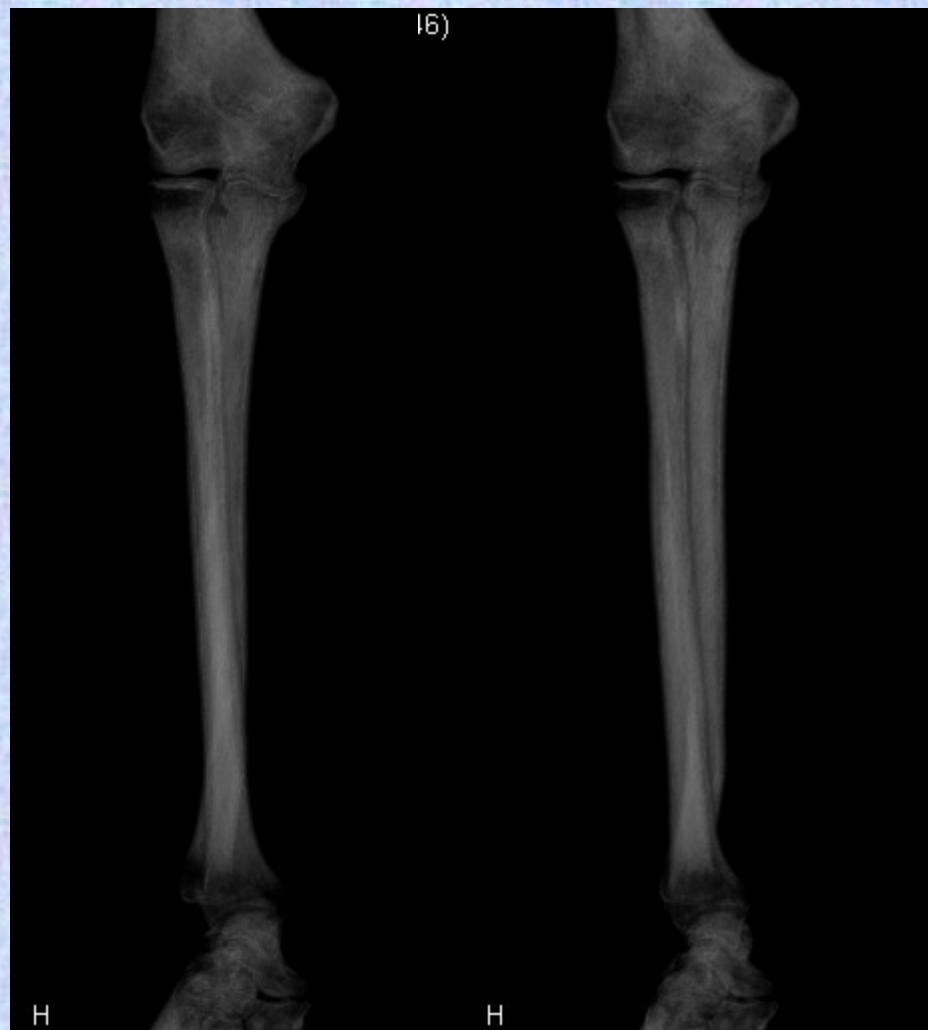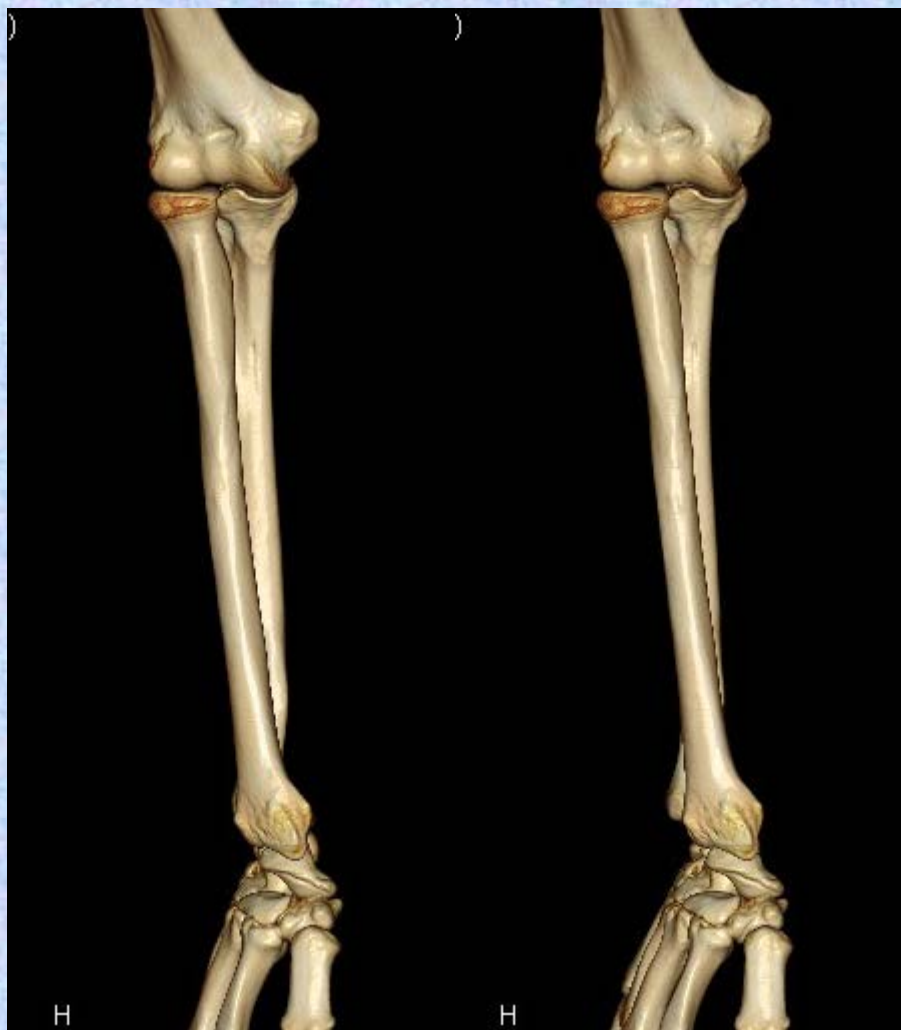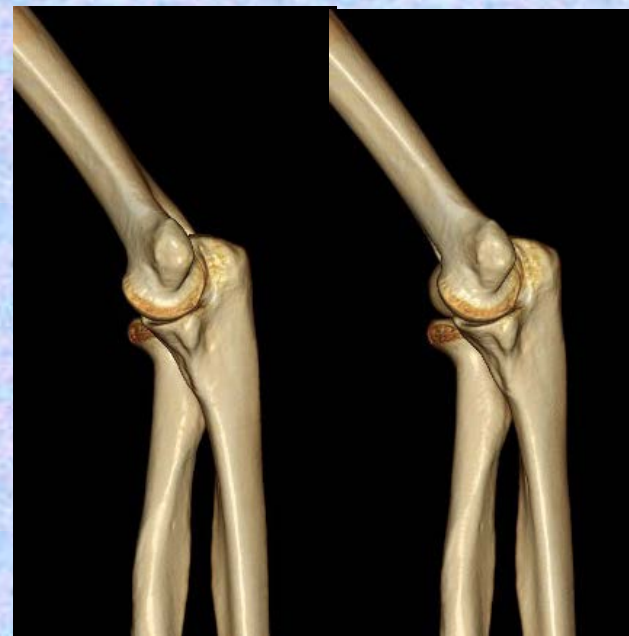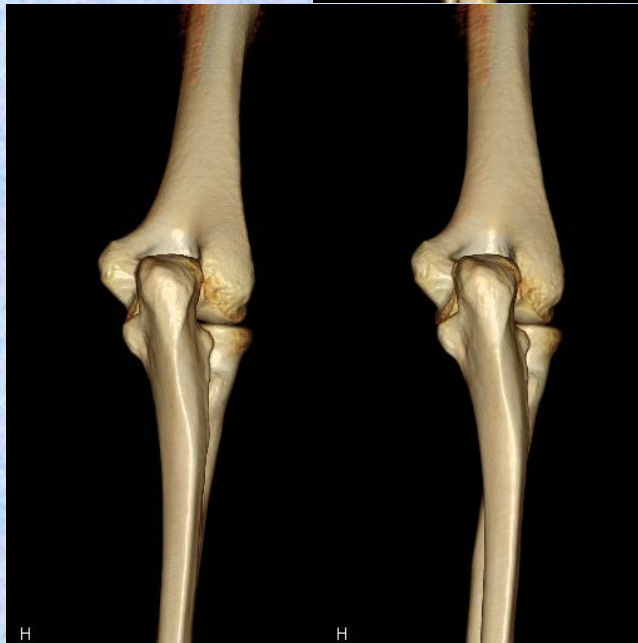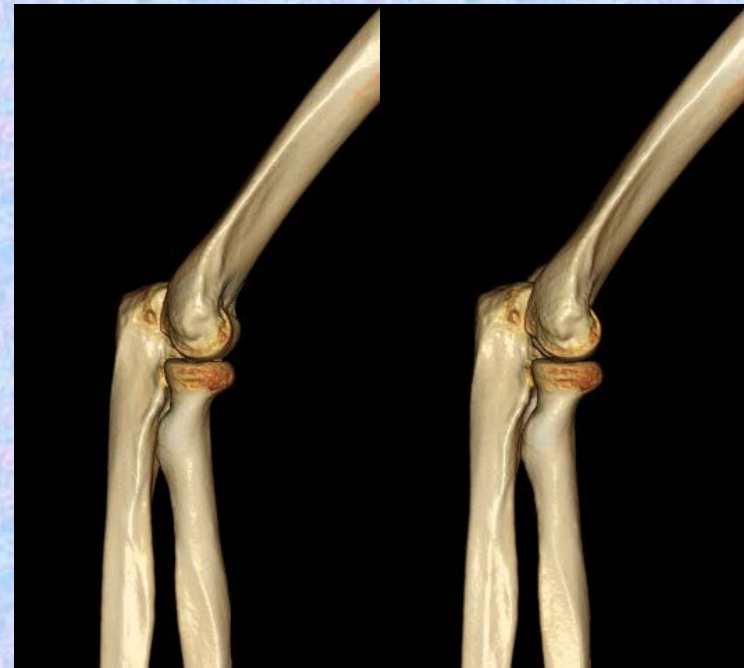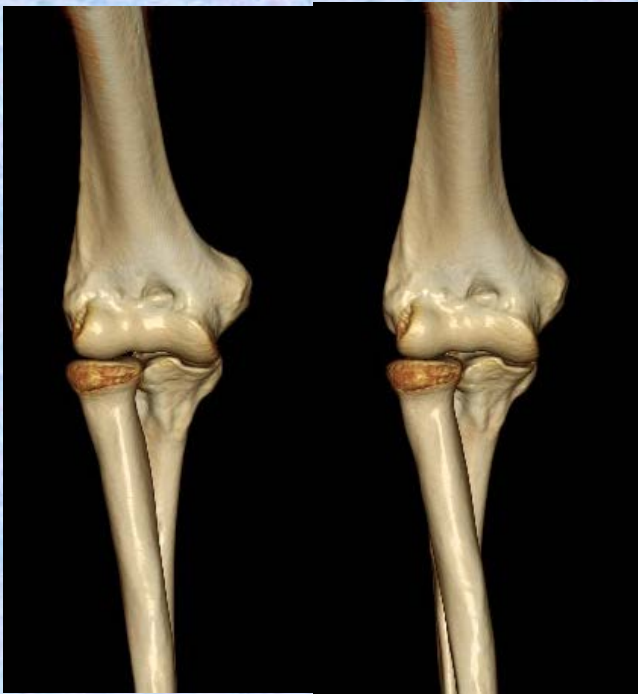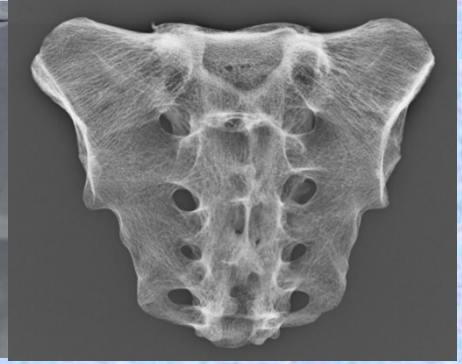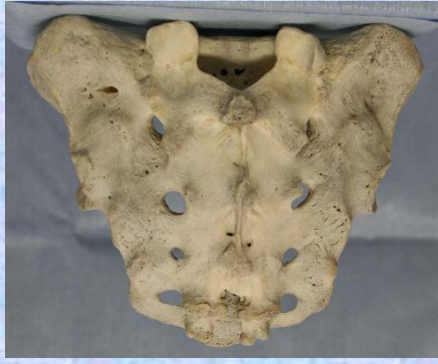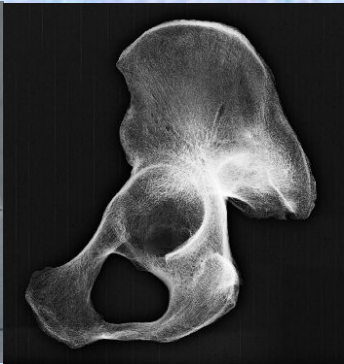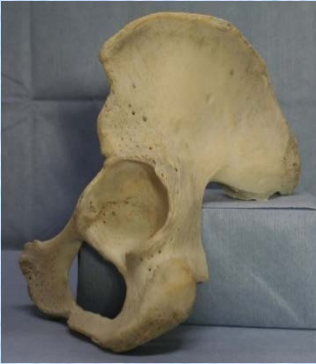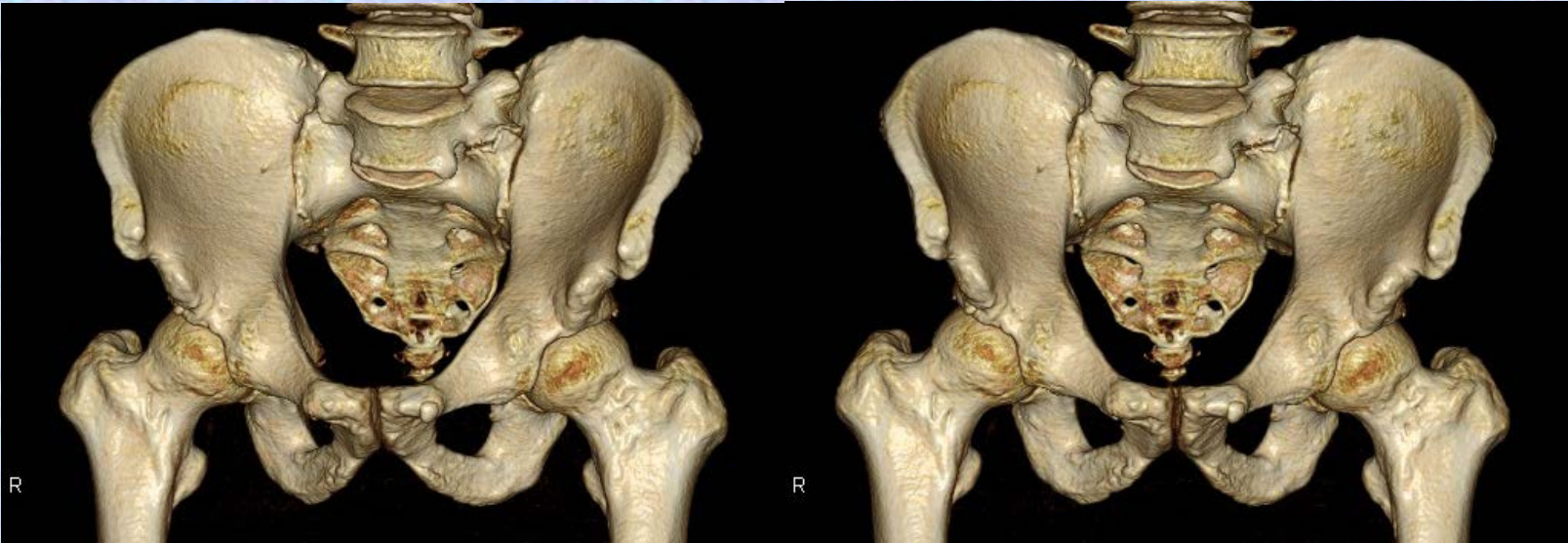




骨標本X線ステレオ解剖図

骨盤

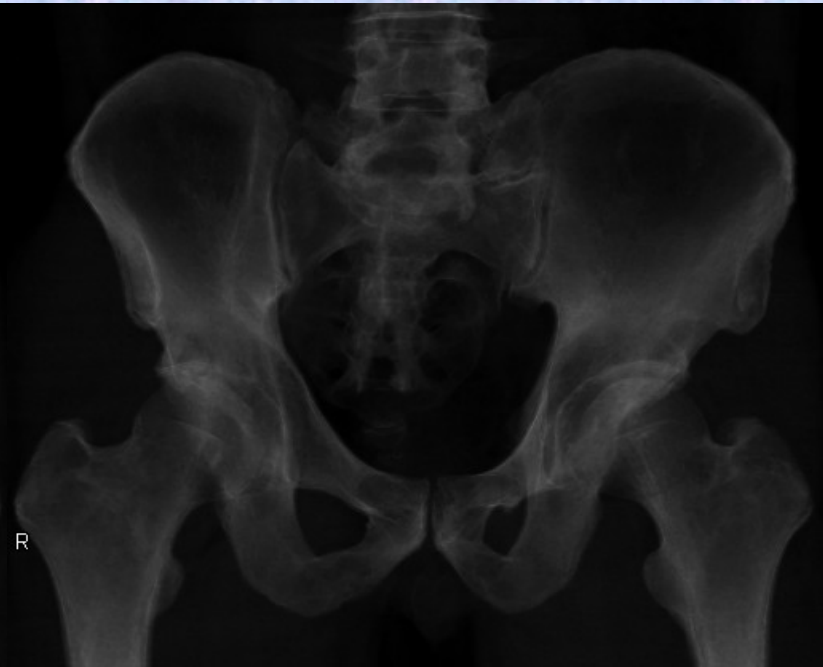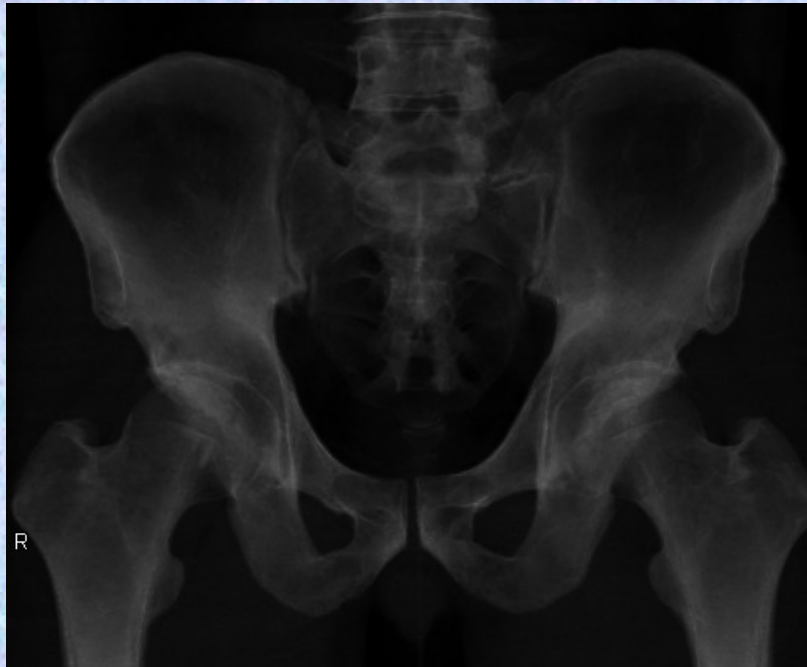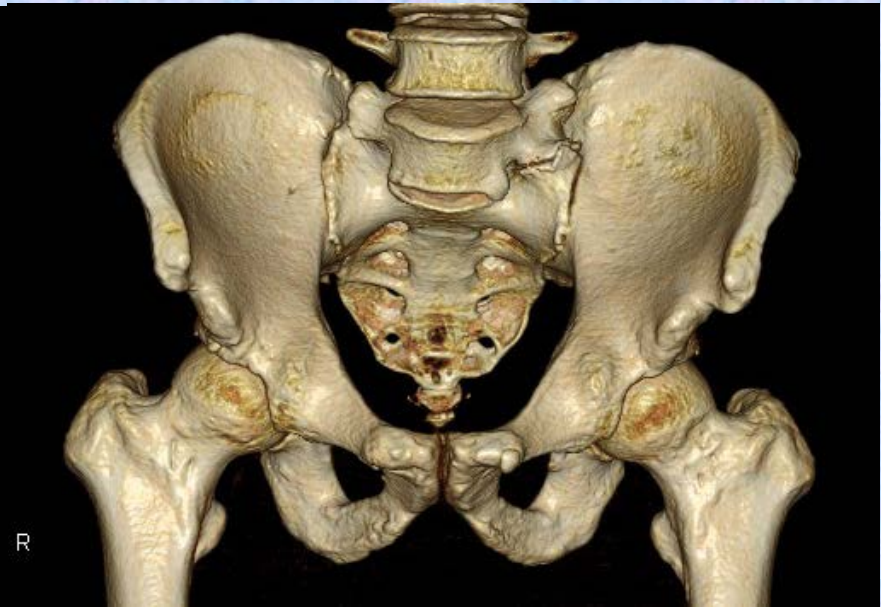
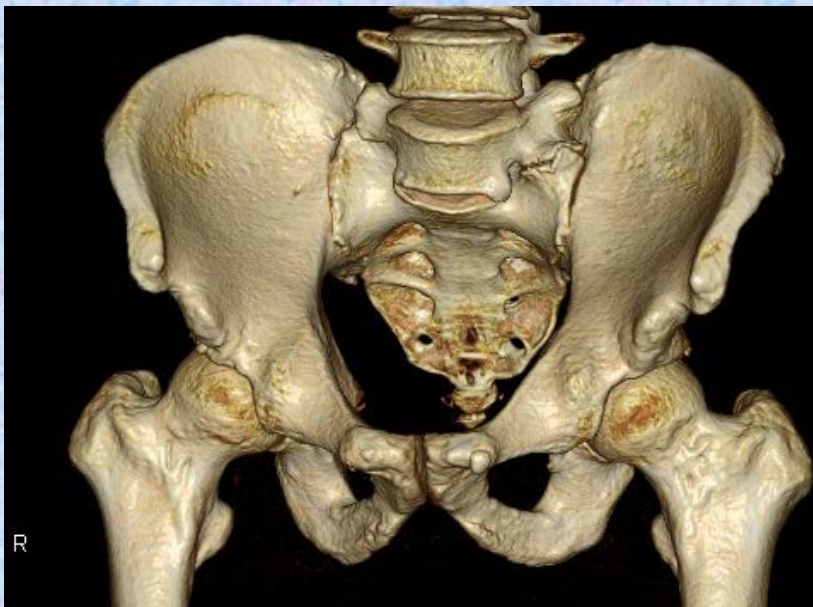骨盤



監修
作成

香川大学医学部 組織細胞生物学 教授 荒木 伸一
 香川大学医学部附属病院 放射線部 勢川 博雄 2014.9





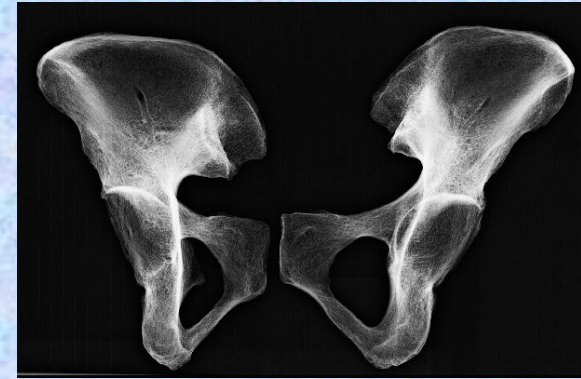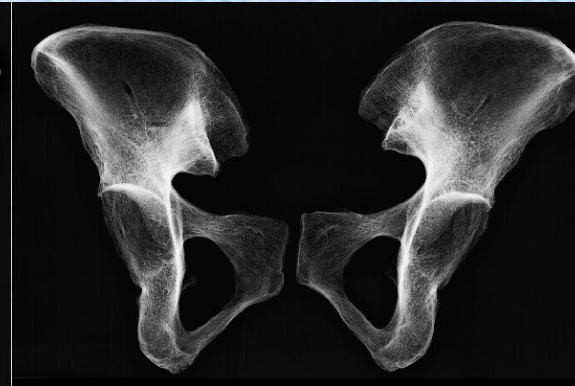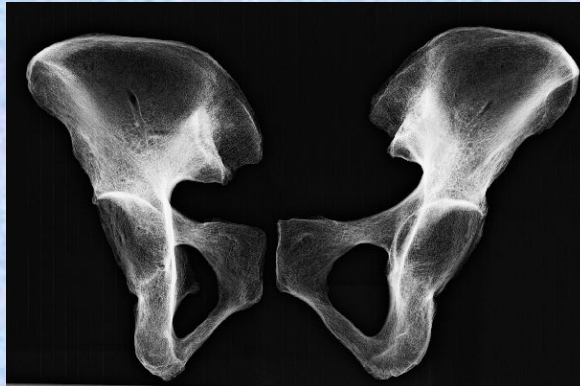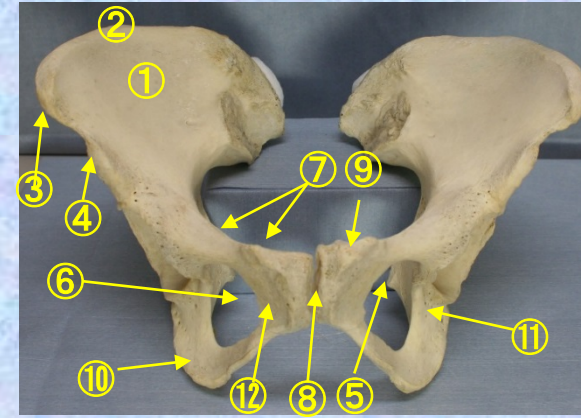
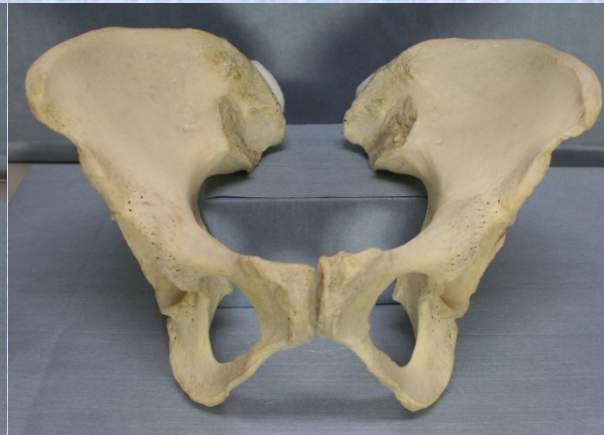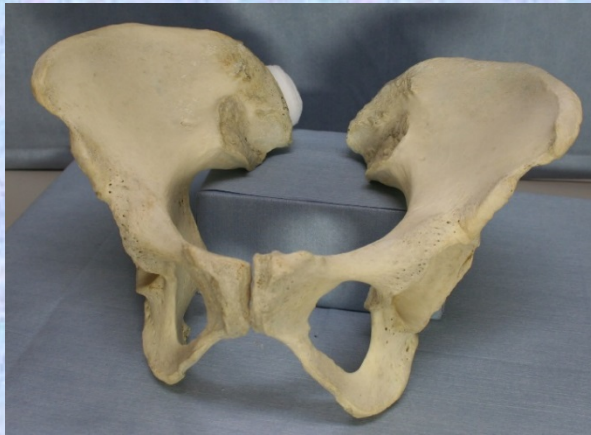骨盤

Pelvis



骨盤 Pelvis 前面

前面 (Pelvis anterior view)



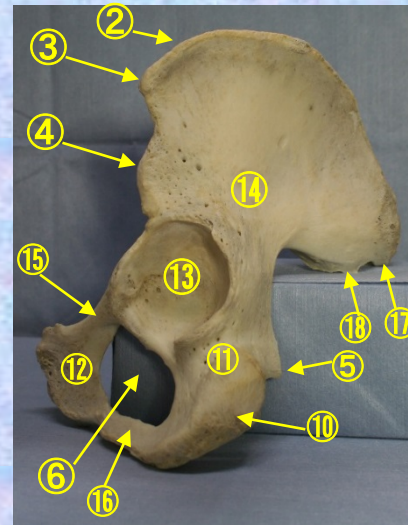
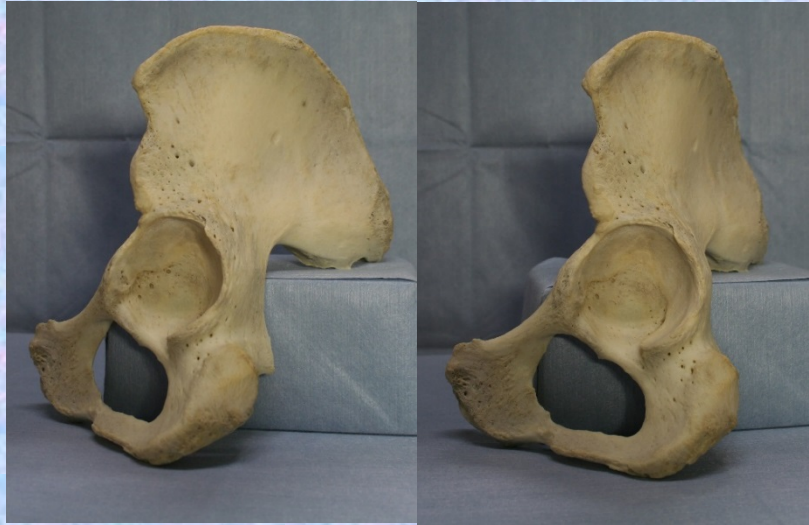- ① 腸骨窩 iliac fossa
- ② 腸骨稜 iliac crest
- ③ 上前腸骨棘 anterior superior iliac spine
- ④ 下前腸骨棘 anterior inferior iliac spine
- ⑤ 坐骨棘 ischial spine
- ⑥ 閉鎖孔 obturator foramen
- ⑦ 恥骨櫛 pecteneal line
- ⑧ 恥骨結合 pubic symphysis
- ⑨ 恥骨結節 pubic tuberosity
- ⑩ 坐骨結節 ischial tubercle

- ⑪ 坐骨体 body of ischium
- ⑫ 恥骨体 body of pubis
- ⑬ 寛骨臼 acetabulum
- ⑭ 腸骨体 body of ilium
- ⑮ 閉鎖稜 obturator crest
- ⑯ 閉鎖孔 obturator foramen
- ⑰ 坐骨枝 ramus of ischium
- ⑱ 上後腸骨棘 posterior superior iliac spine
- ⑲ 下後腸骨棘 posterior inferior iliac spine

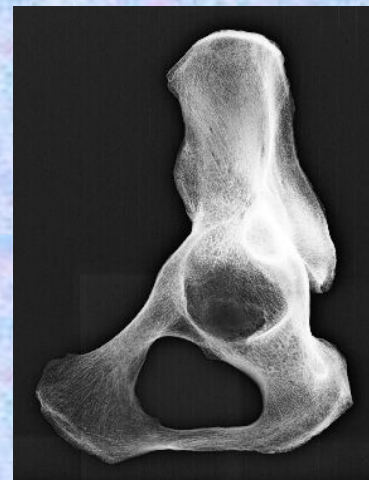
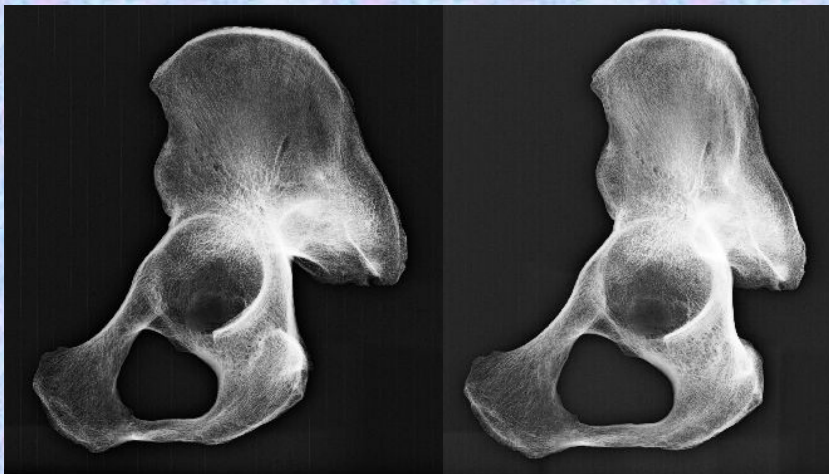
骨盤 Pelvis 斜位

斜面 (Pelvis oblique view)



- ① 腸骨窩 iliac fossa
- ② 腸骨稜 iliac crest
- ③ 上前腸骨棘 anterior superior iliac spine
- ④ 下前腸骨棘 anterior inferior iliac spine
- ⑤ 坐骨棘 ischial spine
- ⑥ 閉鎖孔 obturator foramen
- ⑦ 恥骨櫛 pecteneal line
- ⑧ 恥骨結合 pubic symphysis
- ⑨ 恥骨結節 pubic tuberosity
- ⑩ 坐骨結節 ischial tubercle

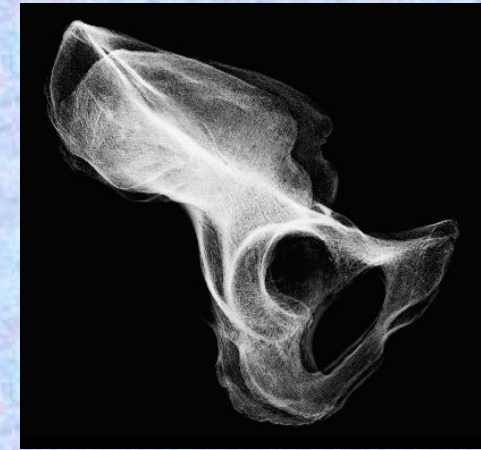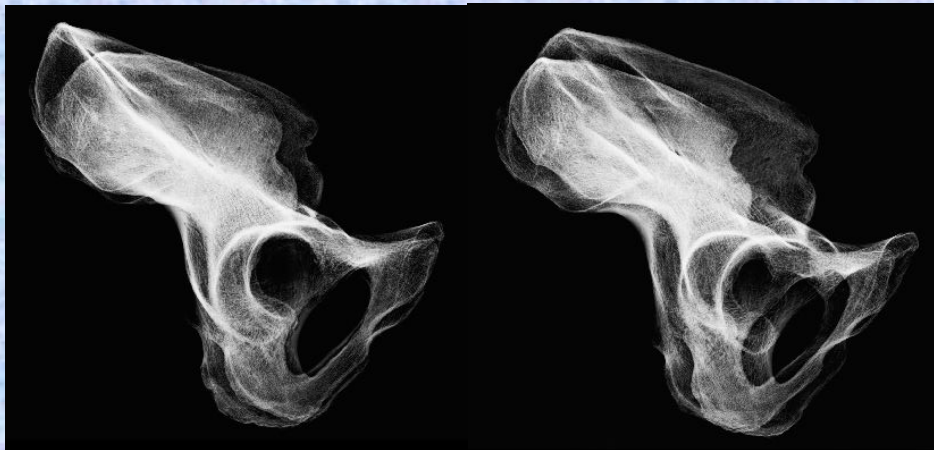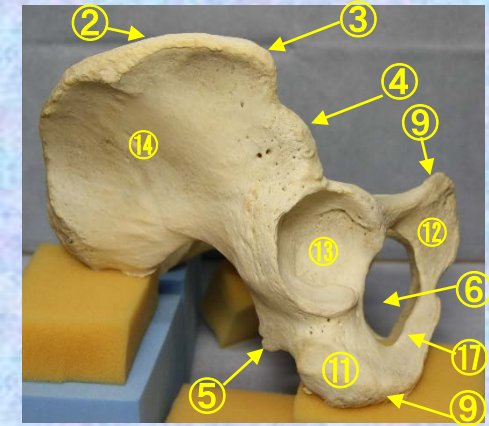


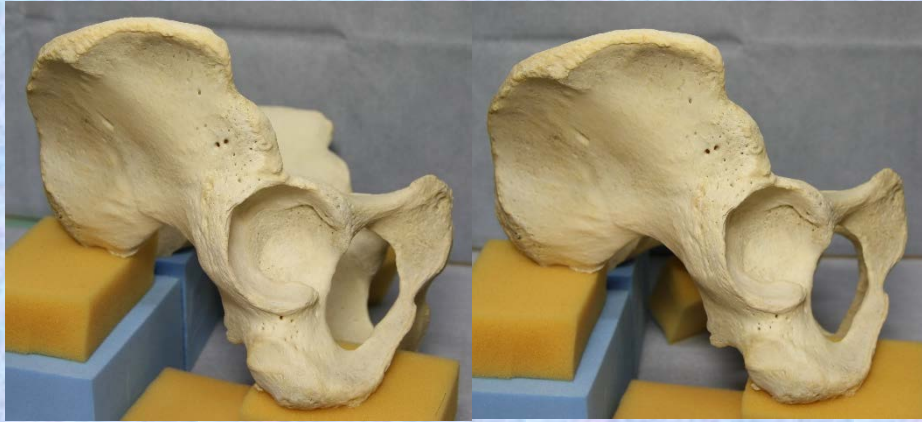- ⑪ 坐骨体 body of ischium
- ⑫ 恥骨体 body of pubis
- ⑬ 寛骨臼 acetabulum
- ⑭ 腸骨体 body of ilium
- ⑮ 閉鎖稜 obturator crest
- ⑯ 坐骨枝 ramus of ischium
- ⑰ 上後腸骨棘 posterior superior iliac spine
- ⑱ 下後腸骨棘 posterior inferior iliac spine



骨盤 Pelvis 側面

側面 (Pelvis Lateral view)



- ① 腸骨窩 iliac fossa
- ② 腸骨稜 iliac crest
- ③ 上前腸骨棘 anterior superior iliac spine
- ④ 下前腸骨棘 anterior inferior iliac spine
- ⑤ 坐骨棘 ischial spine
- ⑥ 閉鎖孔 obturator foramen
- ⑦ 恥骨櫛 pecteneal line
- ⑧ 恥骨結合 pubic symphysis
- ⑨ 恥骨結節 pubic tuberosity
- ⑩ 坐骨結節 ischial tubercle

- ⑪ 坐骨体 body of ischium
- ⑫ 恥骨体 body of pubis
- ⑬ 寛骨臼 acetabulum
- ⑭ 腸骨体 body of ilium
- ⑮ 閉鎖稜 obturator crest
- ⑯ 閉鎖孔 obturator foramen
- ⑰ 坐骨枝 ramus of ischium
- ⑱ 上後腸骨棘 posterior superior iliac spine
- ⑲ 下後腸骨棘 posterior inferior iliac spine



仙骨 Sacrum

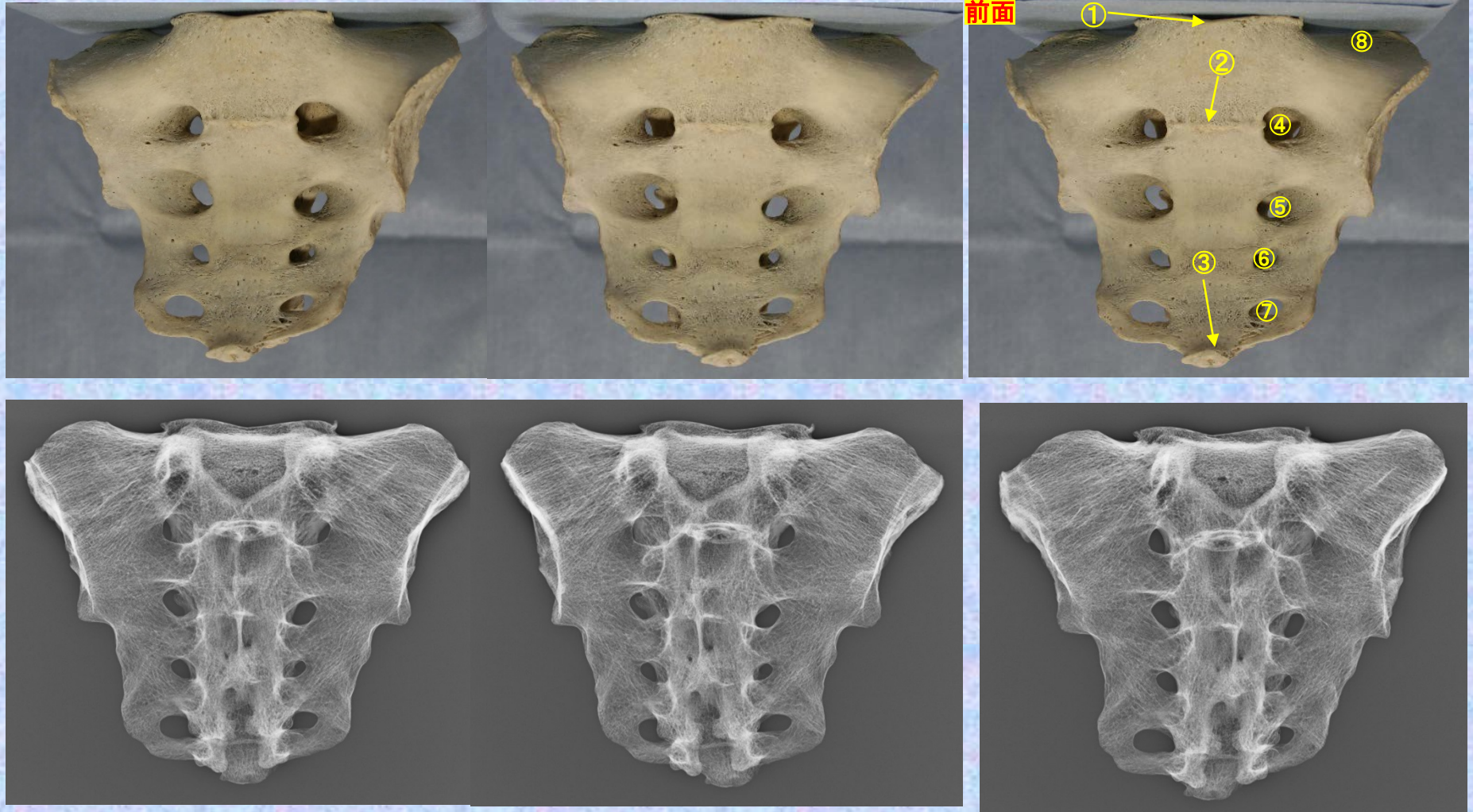
仙椎 Sacral vertebrae (複)

[S1—S5]. 仙椎(通常は5個で, 融合して仙骨をつくる脊柱分節)



仙骨 Sacrum 前面

前面 (Sacrum anterior view)



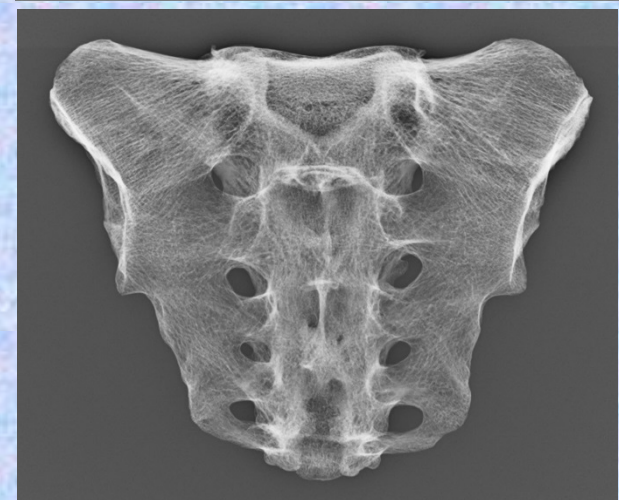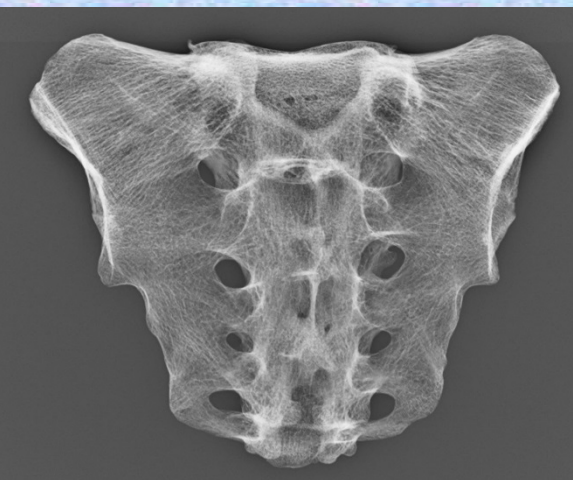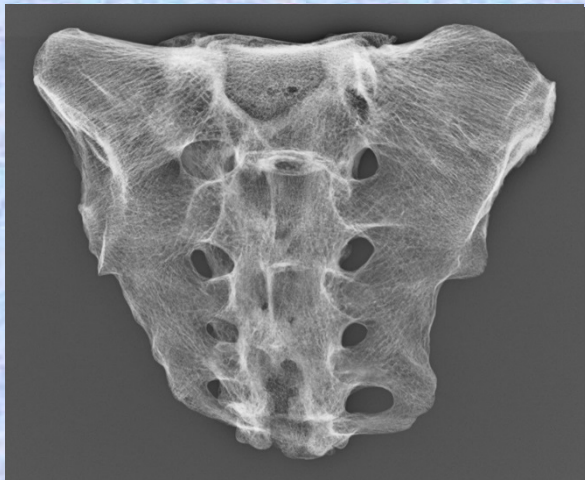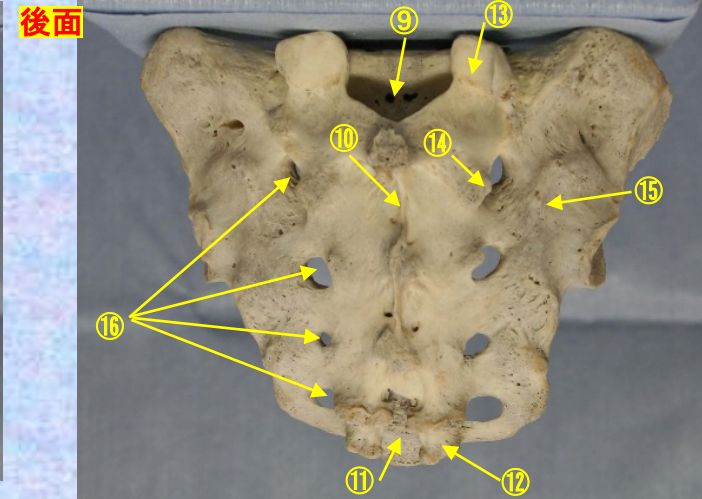
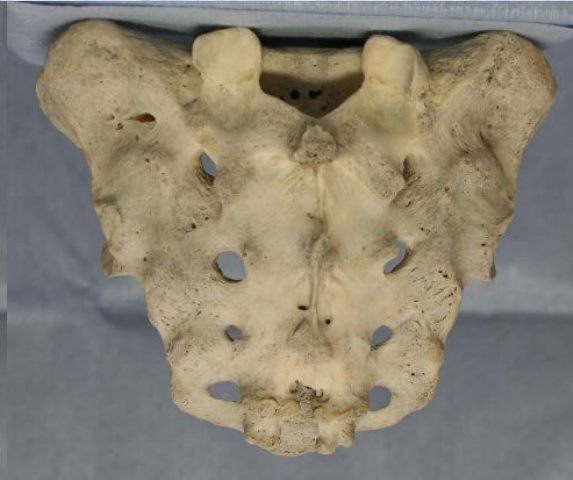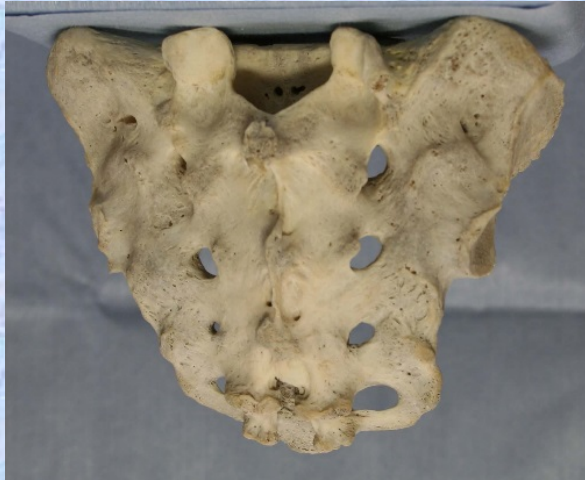- ①岬角 promontory
- ②第1、第2仙椎癒合位置(横線) site of fusion of first and second sacral vertebrae
- ③仙骨尖 facet for coccyx
- ④第1前仙骨孔first pelvic sacral foramen

- ⑤第2前仙骨孔second pelvic sacral foramen
- ⑥第3前仙骨孔third pelvic sacral foramen
- ⑦第4前仙骨孔fourth pelvic sacral foramen
- ⑧外側部上面(仙骨翼)upper surface of lateral part(ala)



仙骨 Sacrum 後面

後面 (Sacrum posterior view)



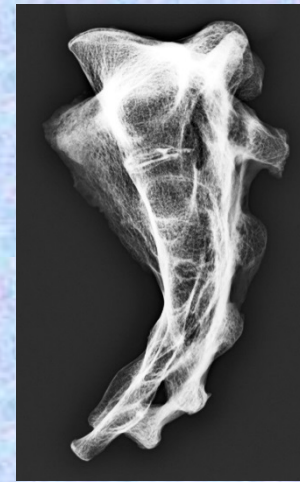
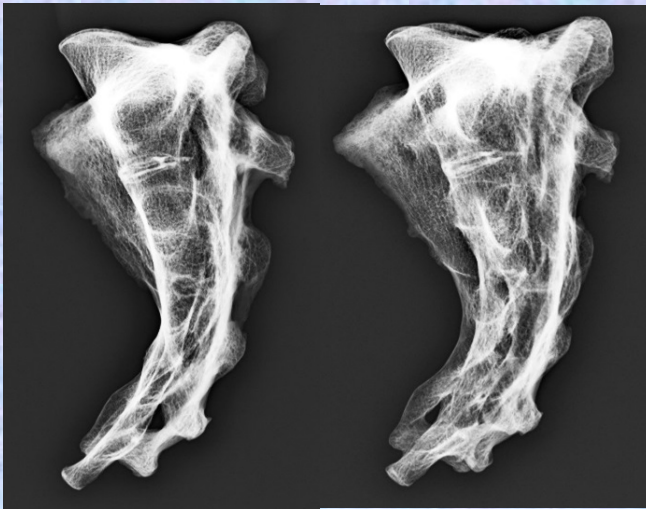
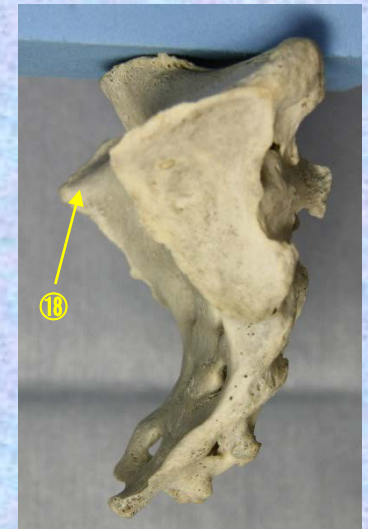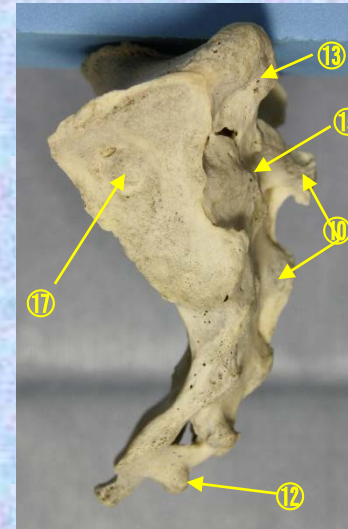
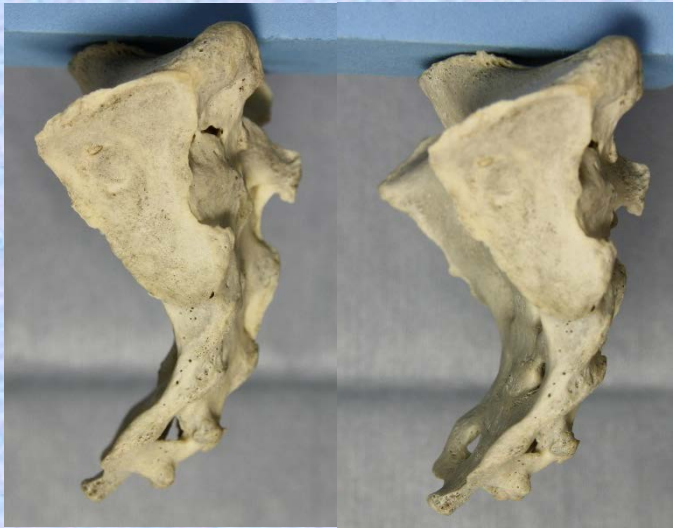- ⑨ 仙骨管 sacral canal
- ⑩ 正中仙骨稜 median sacral crest
- ⑪ 仙骨裂孔 sacral hiatus
- ⑫ 仙骨角 sacral cornu
- ⑬ 上関節突起 superior articular process

- ⑭ 中間仙骨稜 intermediate sacral crest
- ⑮ 外側仙骨稜 lateral sacral crest
- ⑯ 第1～第4後仙骨孔(上から) first～fourth dorsal sacral foramen



仙骨 Sacrum 側面

後面 (Sacrum Lateral view)



- ⑰ 耳状面 auricular surface of sacrum
⑱ 岬角 promontory

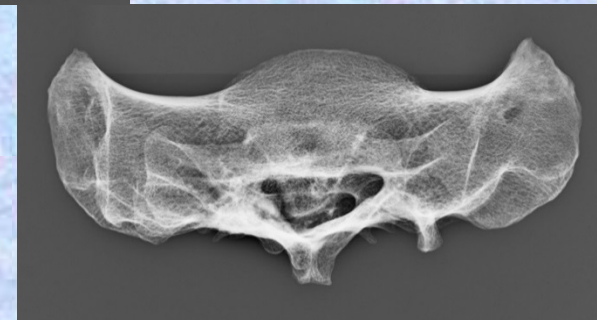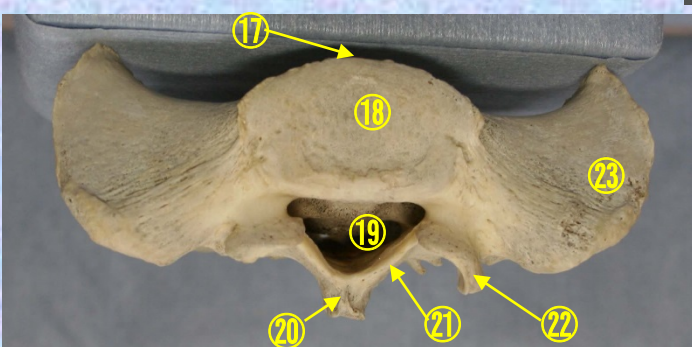
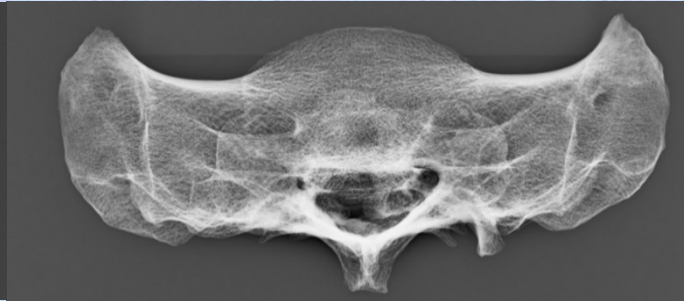
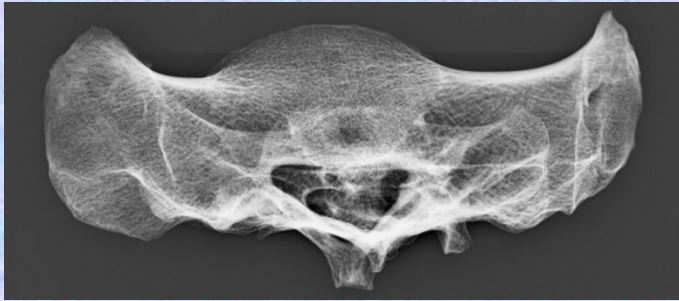
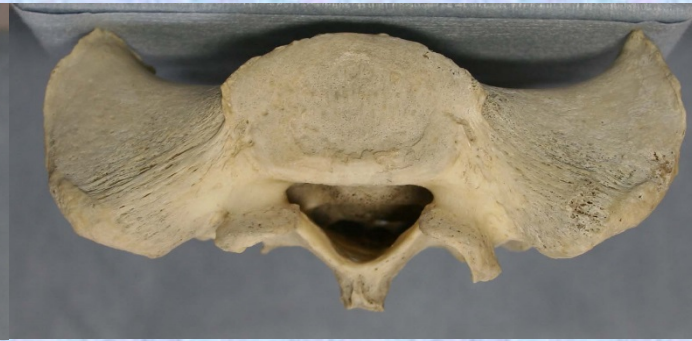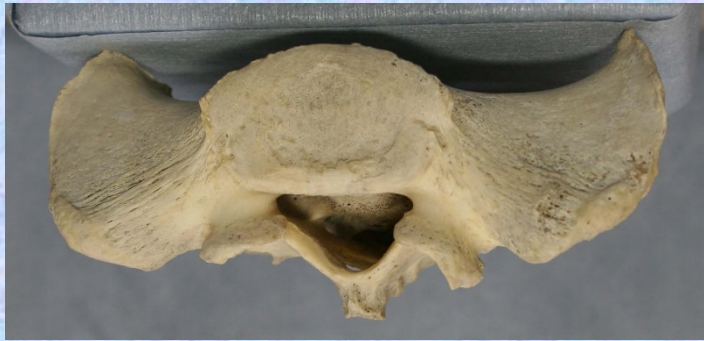
- ⑨ 仙骨管 sacral canal
⑩ 正中仙骨稜 median sacral crest
⑪ 仙骨裂孔 sacral hiatus
⑫ 仙骨角 sacral cornu
⑬ 上関節突起 superior articular process

- ⑭ 中間仙骨稜 intermediate sacral crest
⑮ 外側仙骨稜 lateral sacral crest
⑯ 第1～第4後仙骨孔(上から) first～fourth dorsal sacral foramen



仙骨 Sacrum 軸位面

軸位面 (Sacrum Axial surface)

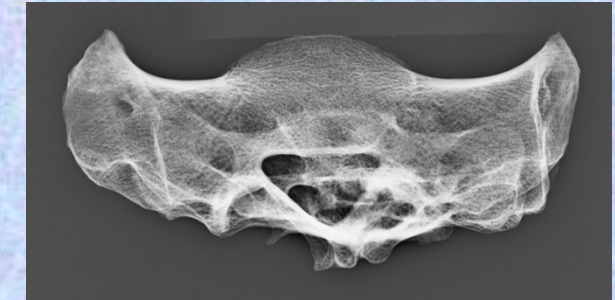
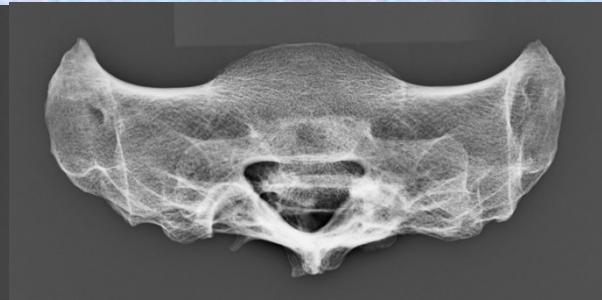
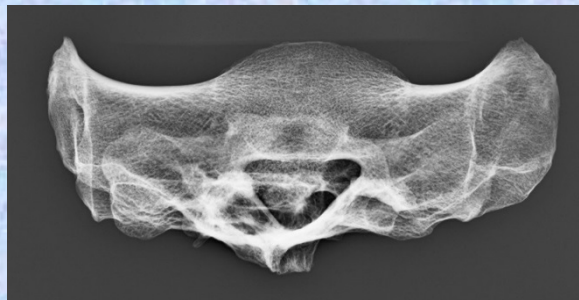
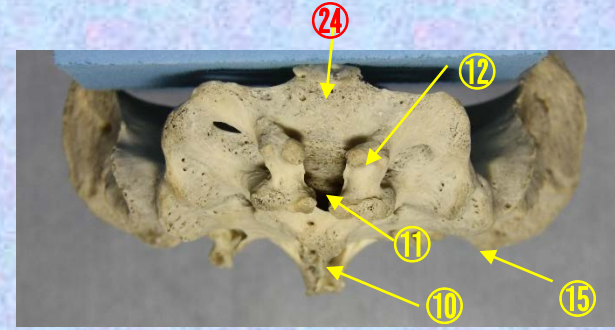
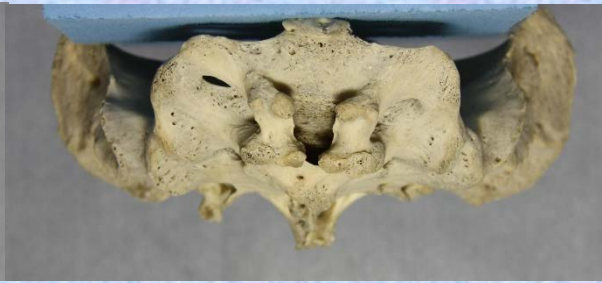
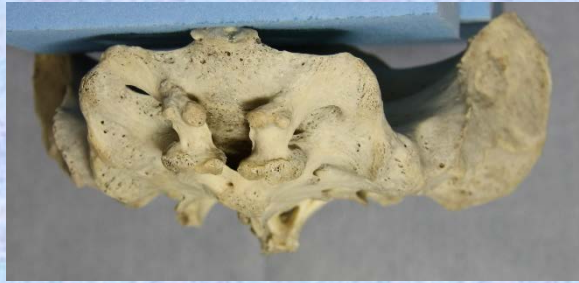
- ①⑦ 岬角 promantory
- ①⑧ 第一仙骨椎体 body of first sacral
- ①⑨ 仙骨管 sacral canal
- ②⑩ 正中仙骨稜 spinous tubercle of median sacral crest
- ②⑪ 椎弓板 lamina
- ②⑫ 上関節突起 superior articular process
- ②⑬ 外側部(仙骨翼) lateral part(ala)



仙骨 Sacrum 下面

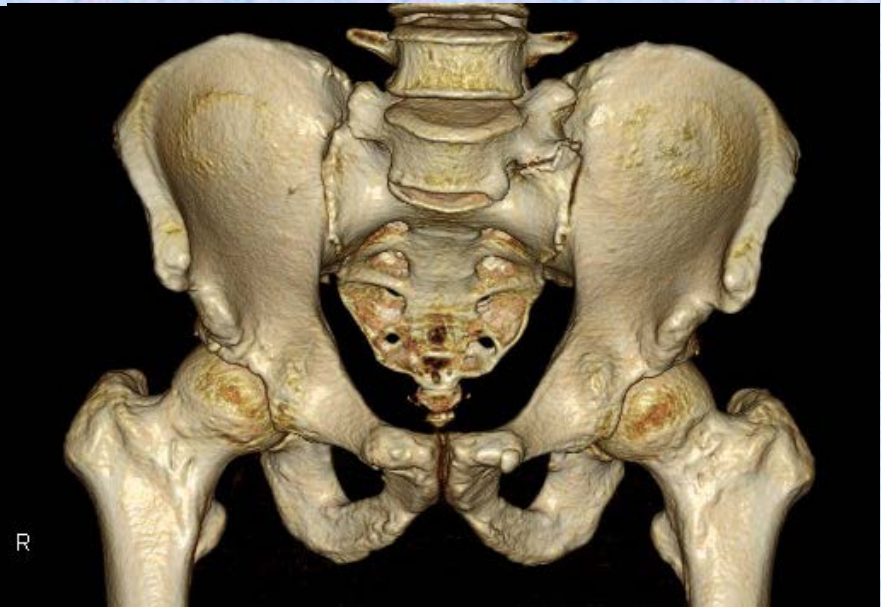
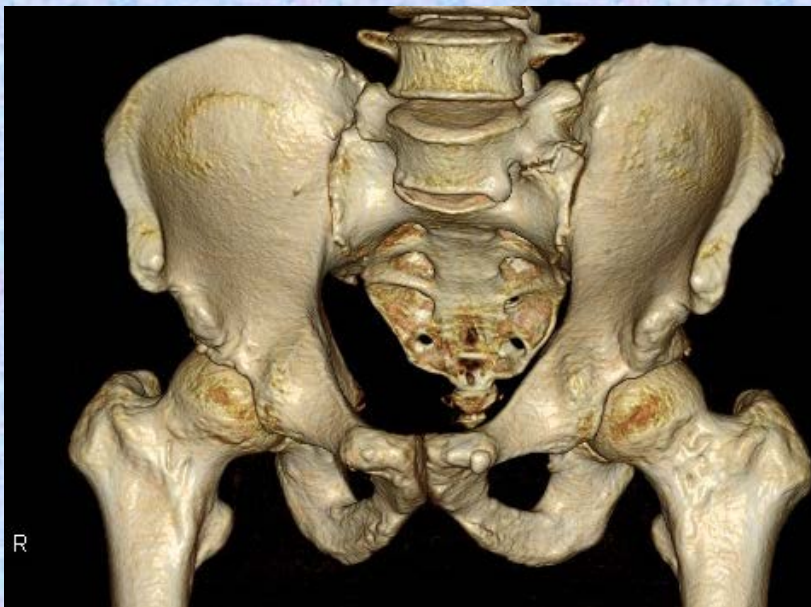仙骨 Sacrum

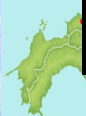
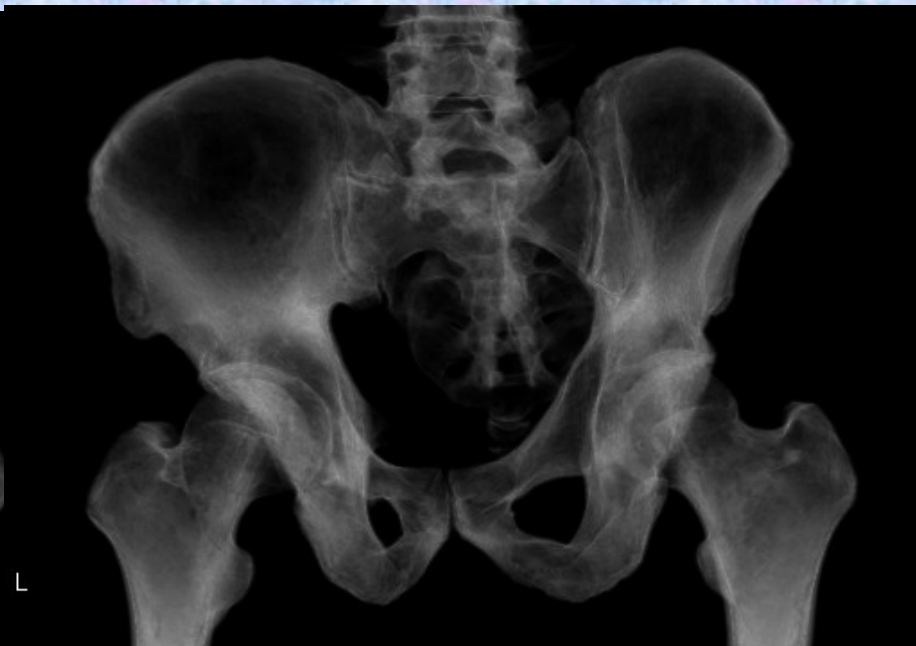
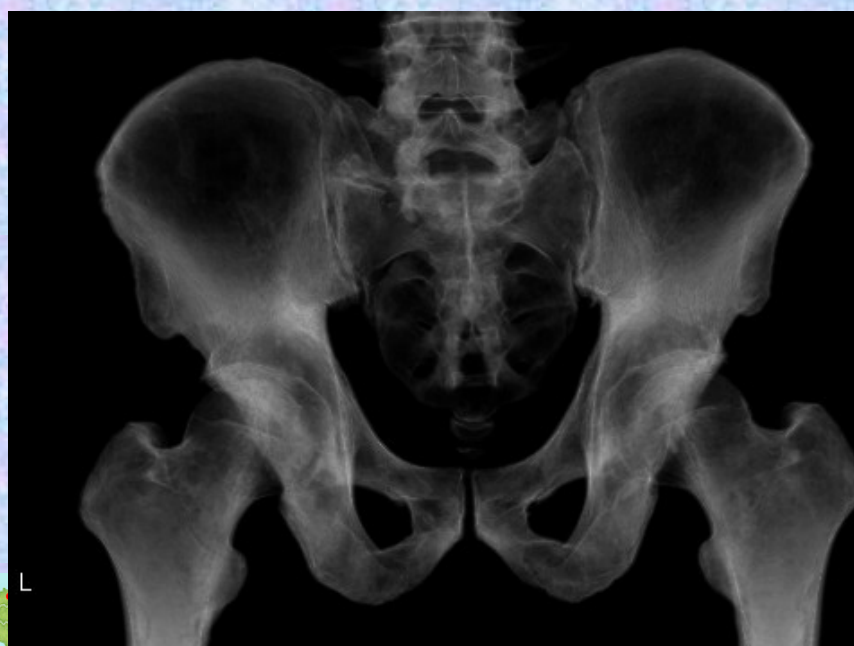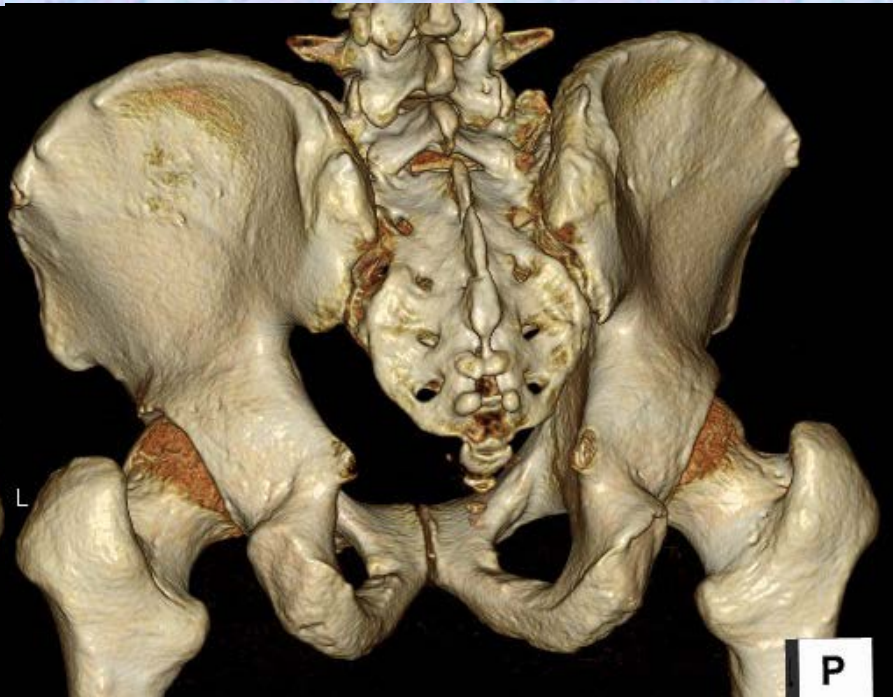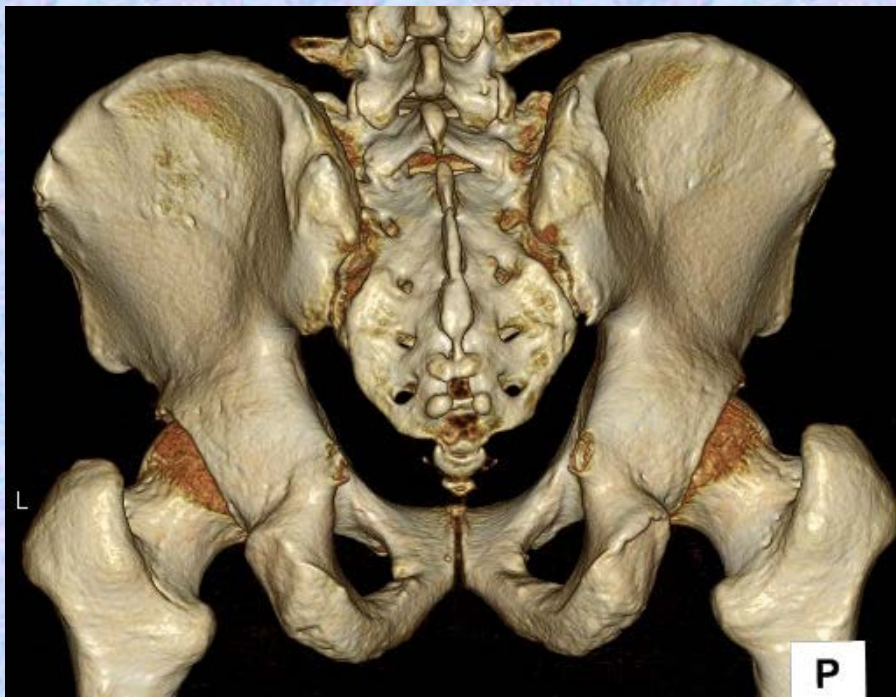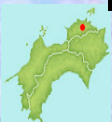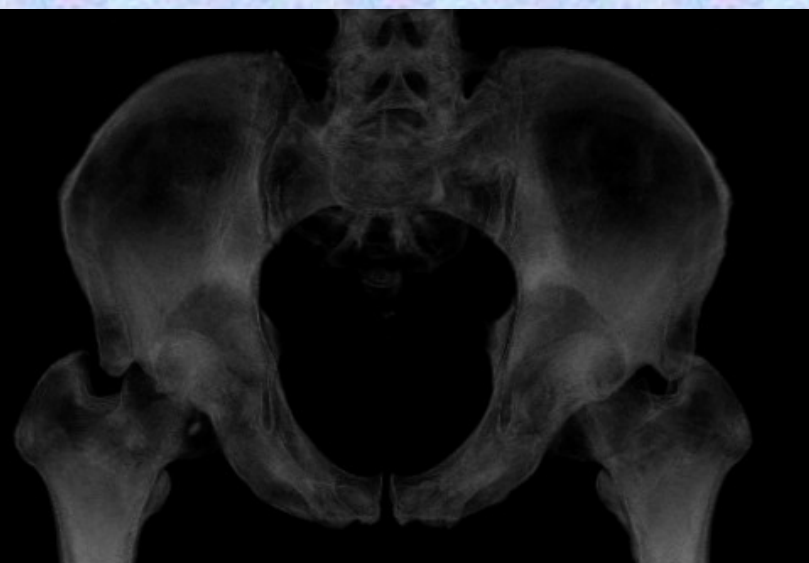
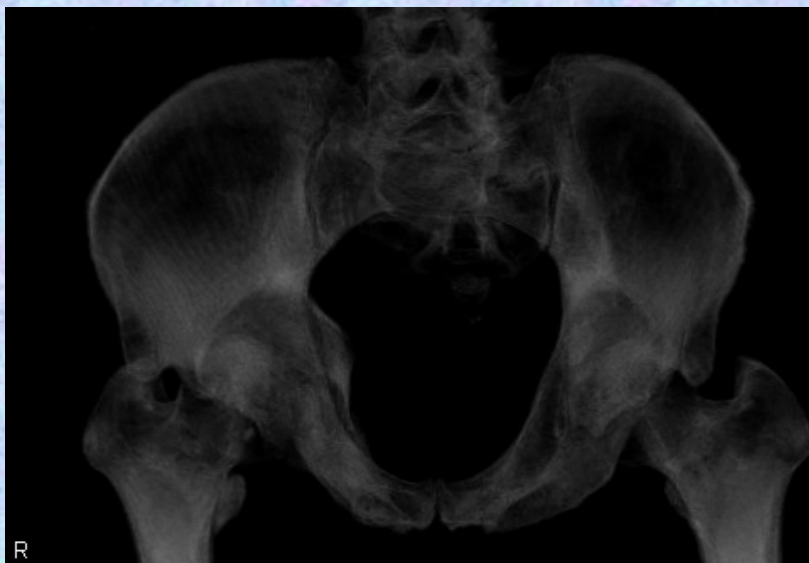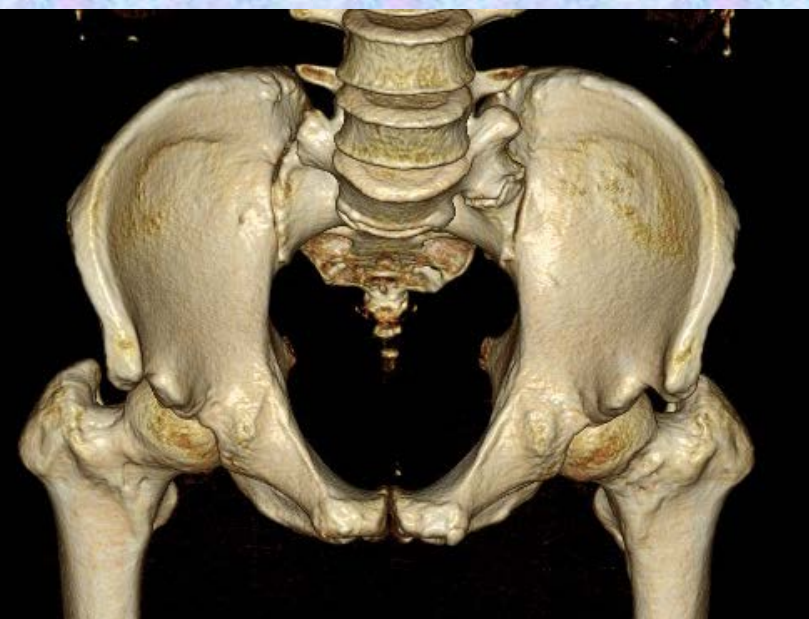
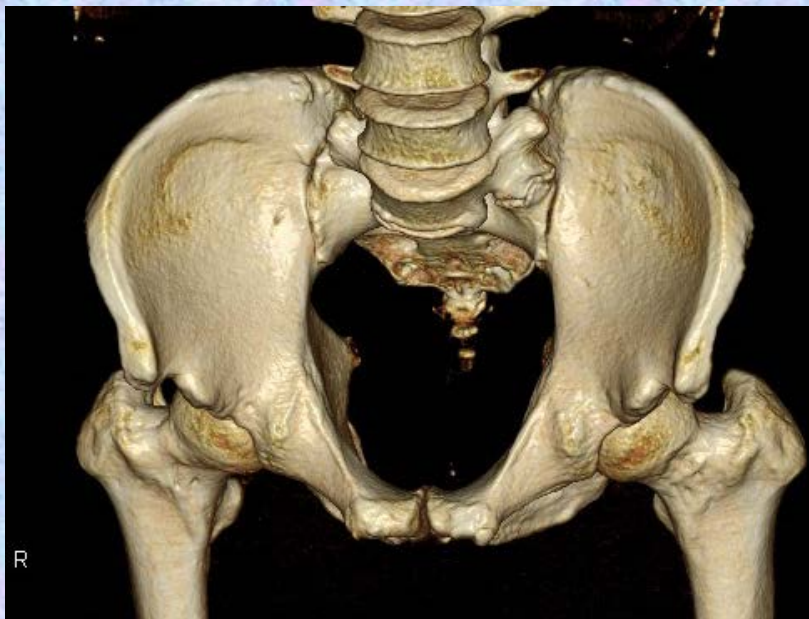
- ⑨ 仙骨管 sacral canal
- ⑩ 正中仙骨稜 median sacral crest
- ⑪ 仙骨裂孔 sacral hiatus
- ⑫ 仙骨角 sacral cornu
- ⑬ 上関節突起 superior articular process
- ⑭ 中間仙骨稜 intermediate sacral crest
- ⑮ 外側仙骨稜 lateral sacral crest
- ⑯ 第1～第4後仙骨孔(上から) first～fourth dorsal sacral foramen

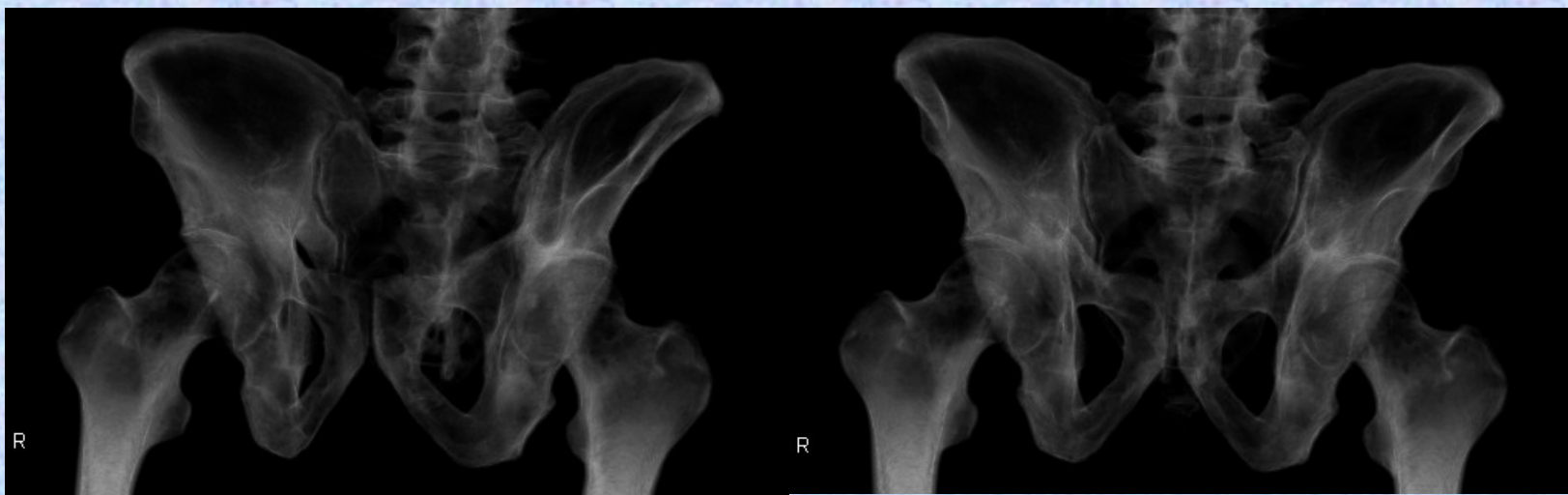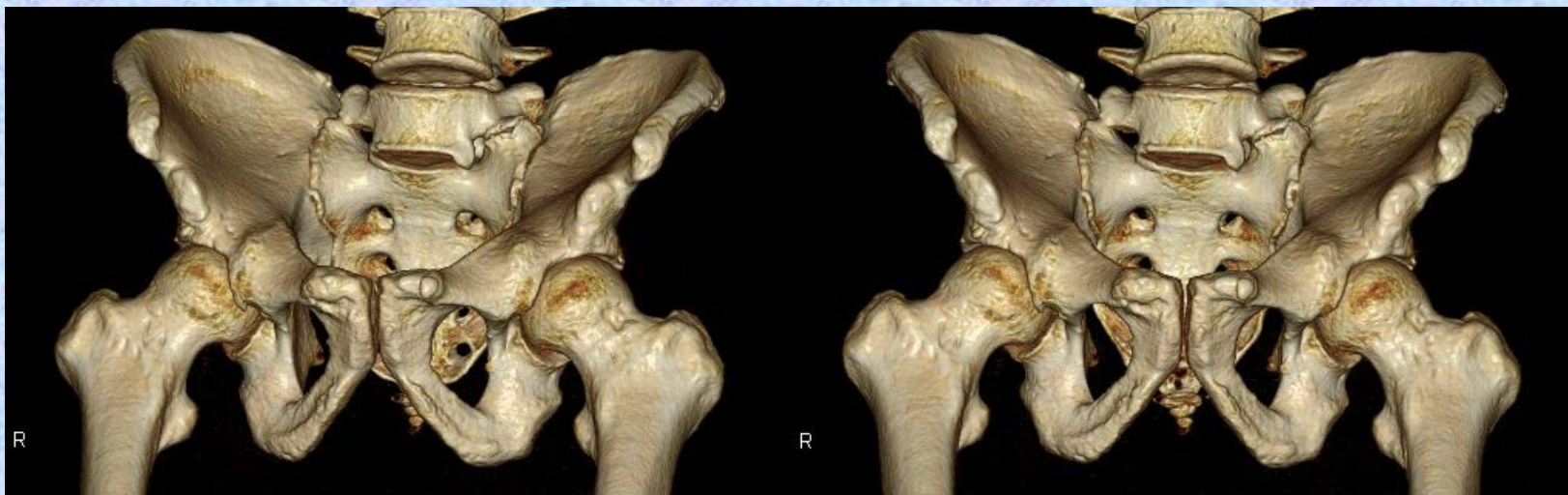- ⑰ 岬角 promantory
- ⑱ 第一仙骨椎体 body of first sacral
- ⑲ 仙骨管 sacral canal
- ⑲ 正中仙骨稜 spinous tubercle of median sacral crest
- ⑲ 椎弓板 lamina
- ⑲ 上関節突起 superior articular process
- ⑲ 外側部(仙骨翼) lateral part(ala)
- ⑲ 仙骨尖 apex of sacrum

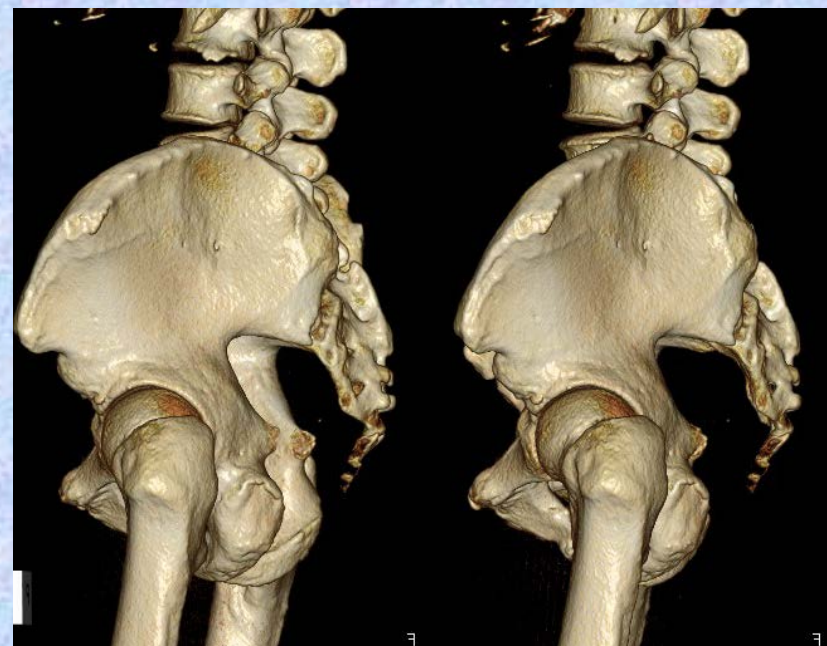
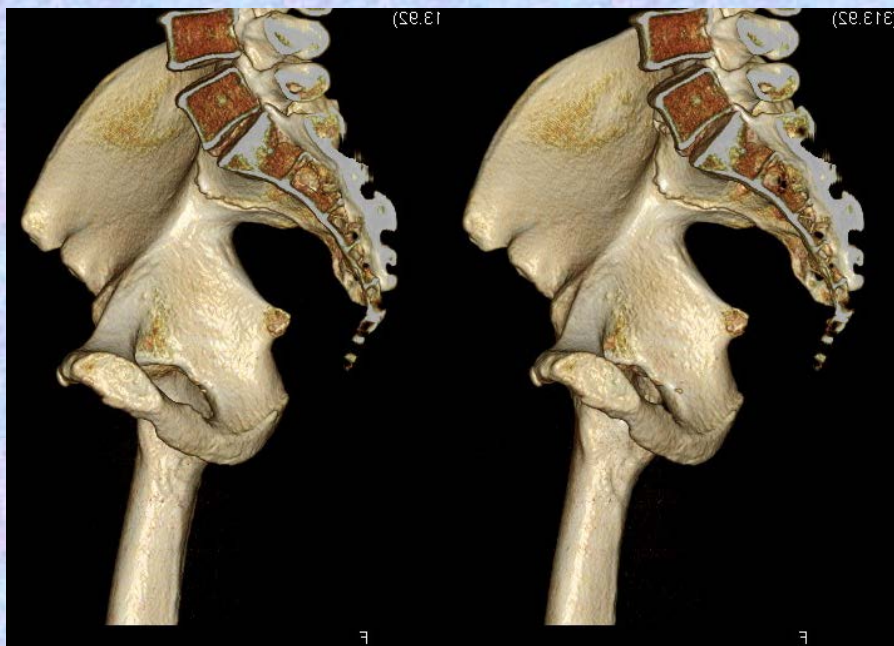








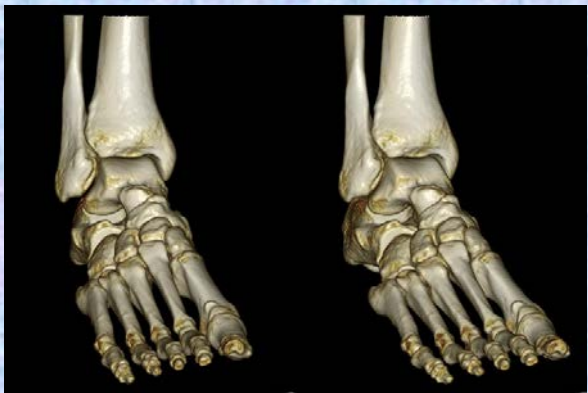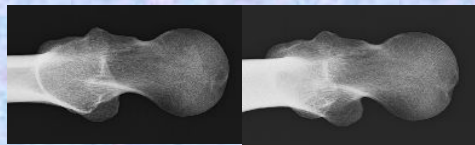


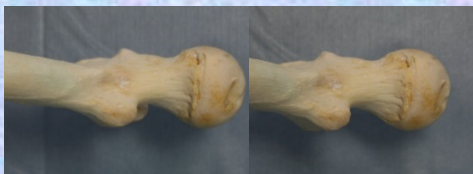
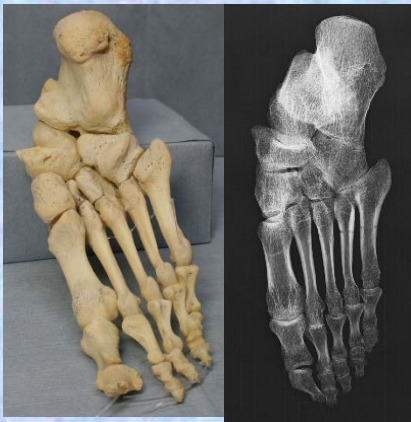
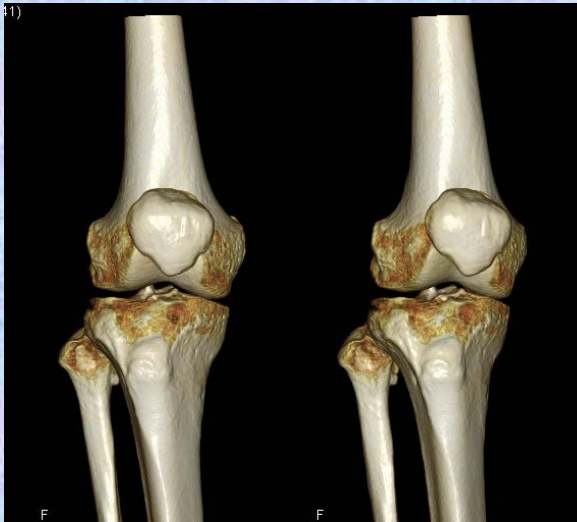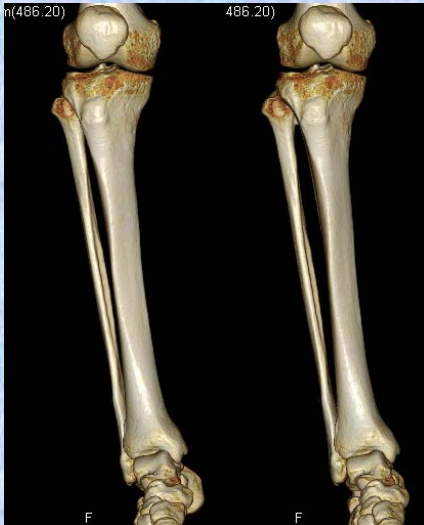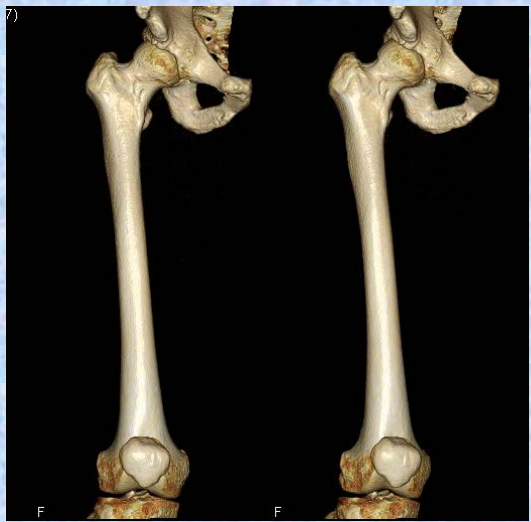骨標本X線ステレオ解剖図

下肢

下肢



監修 香川大学医学部 組織細胞生物学 教授 荒木 伸一
 作成 香川大学医学部附属病院 放射線部 勢川 博雄 2014.9



下肢

Lower limb



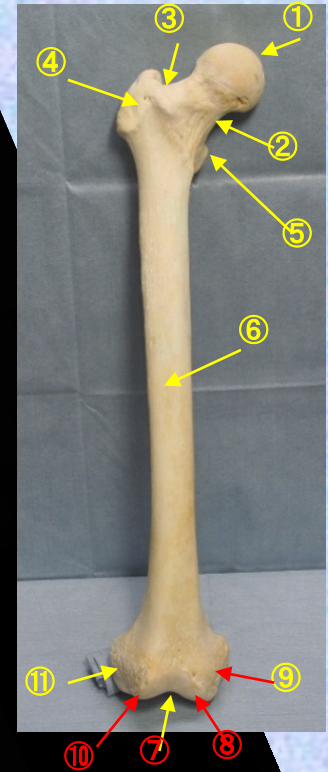
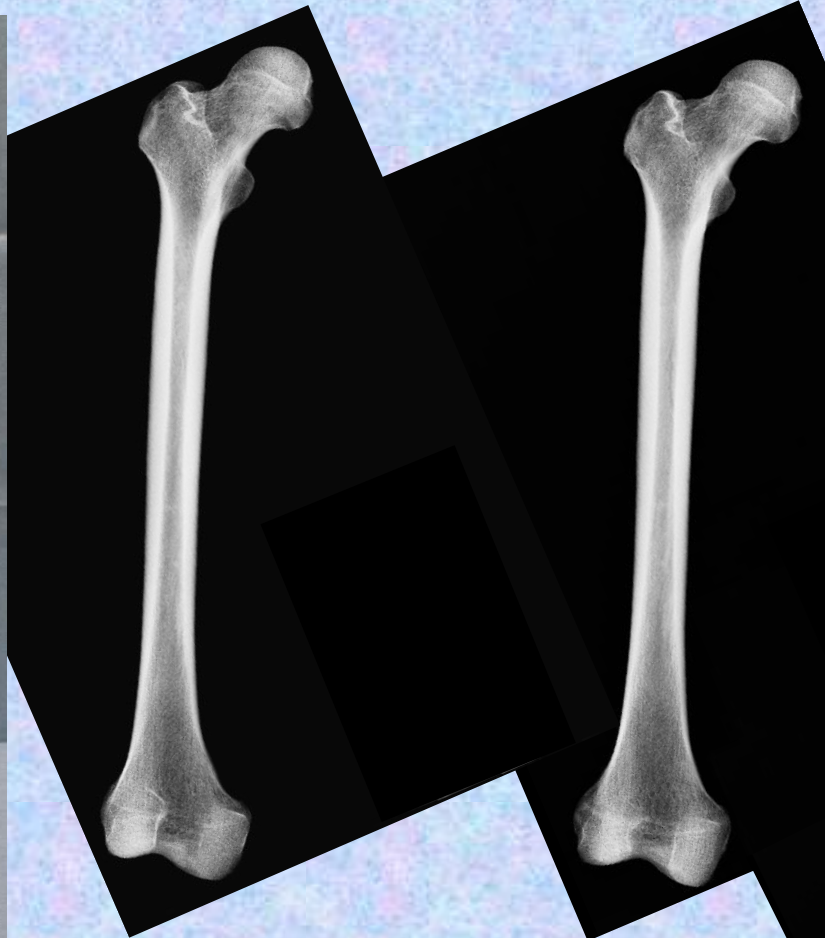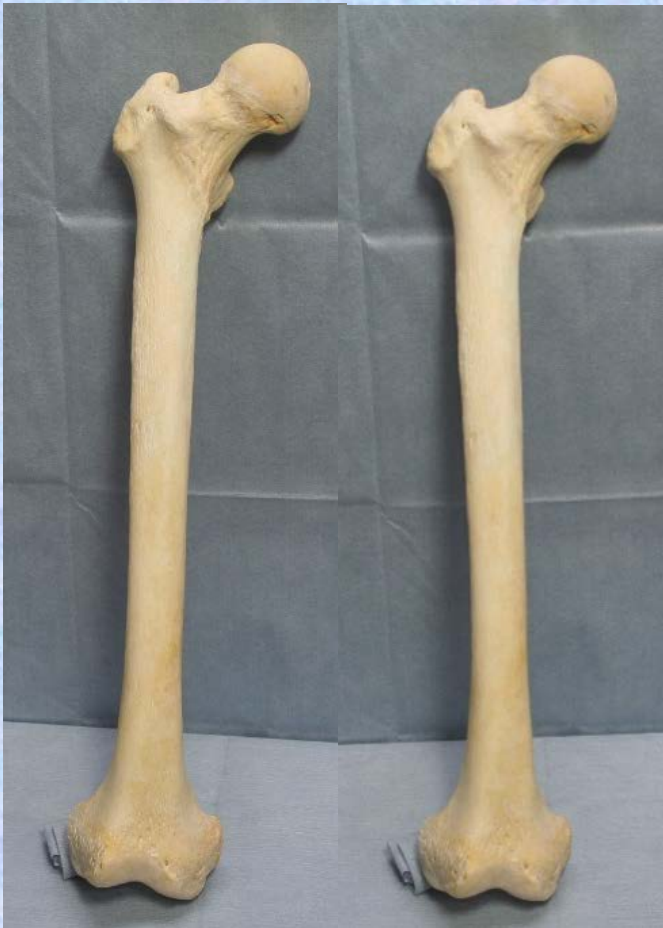大腿骨

Femur



大腿骨 Femur 前面

前面 (Femur anterior view)



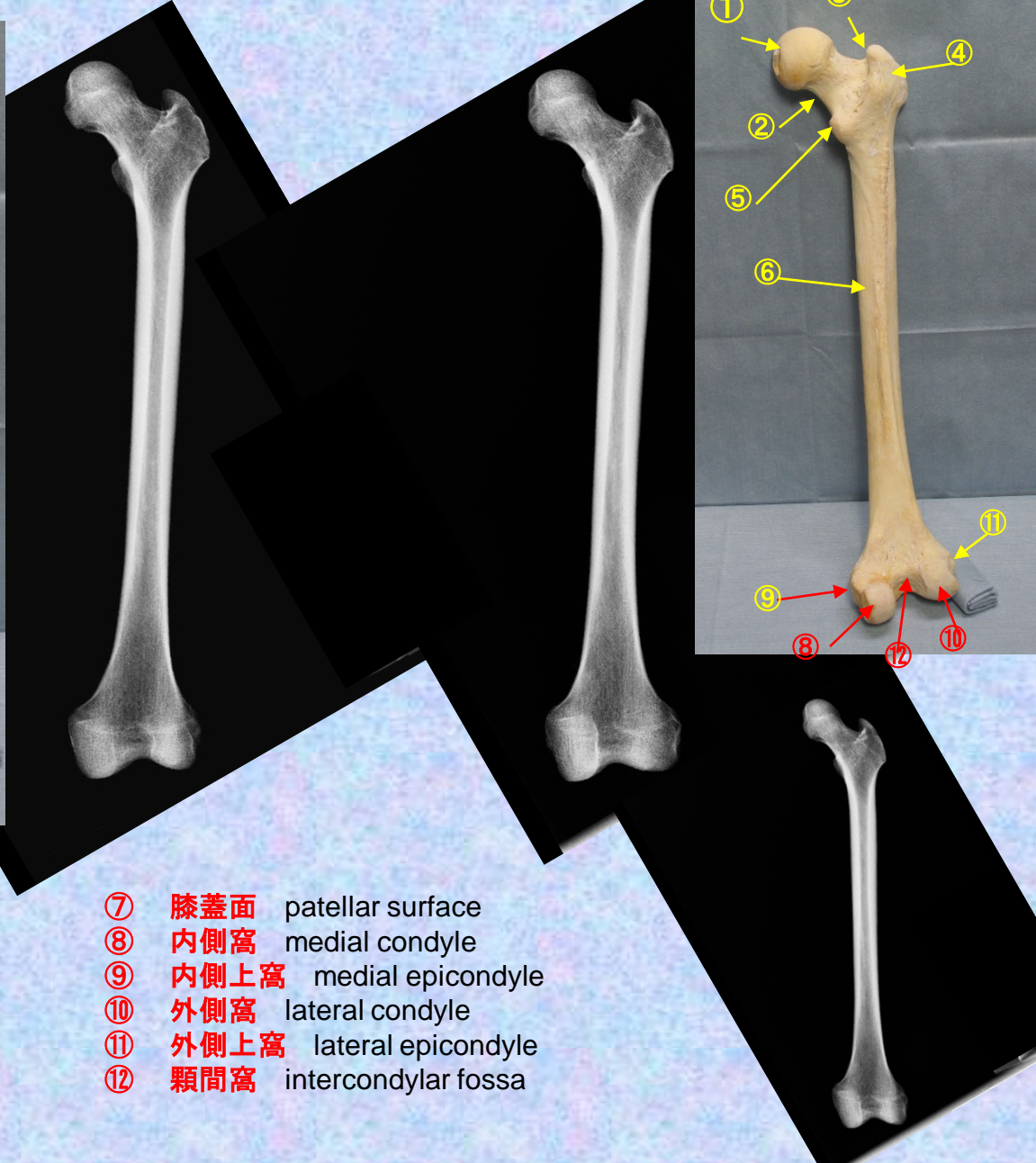
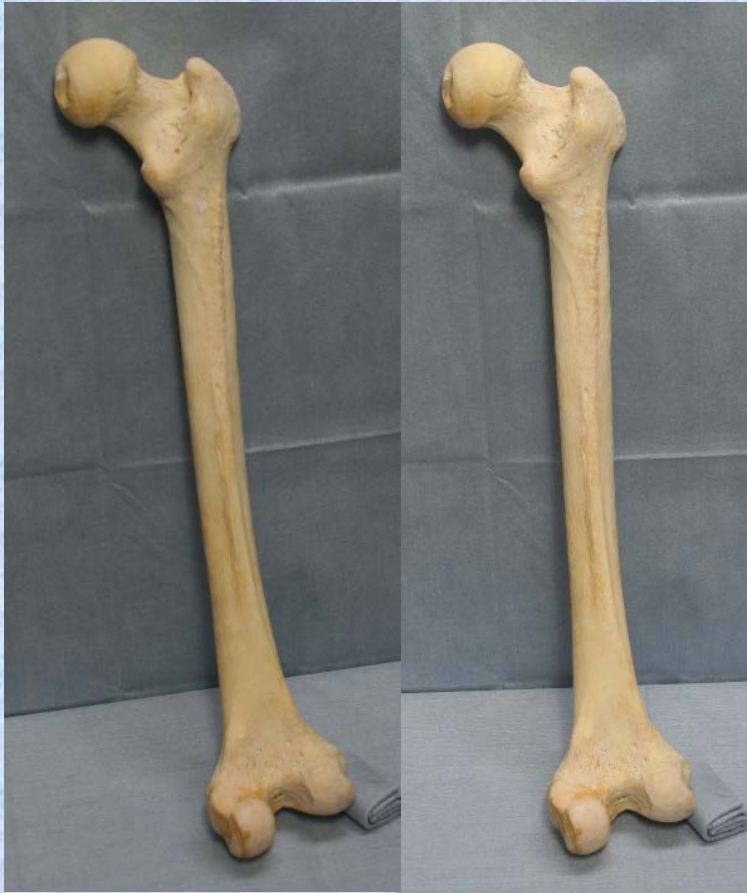- ① 大腿骨頭 head of femur
- ② 大腿骨頸 neck of femur
- ③ 轉子窩 trochanteric fossa
- ④ 大轉子 greater trochanter
- ⑤ 小轉子 lesser trochanter
- ⑥ 大腿骨体 shaft of femur

- ⑦ 膝蓋面 patellar surface
- ⑧ 內側窩 medial condyle
- ⑨ 內側上窩 medial epicondyle
- ⑩ 外側窩 lateral condyle
- ⑪ 外側上窩 lateral epicondyle
- ⑫ 顆間窩 intercondylar fossa



大腿骨 Femur 後面

後面 (Femur posterior view)



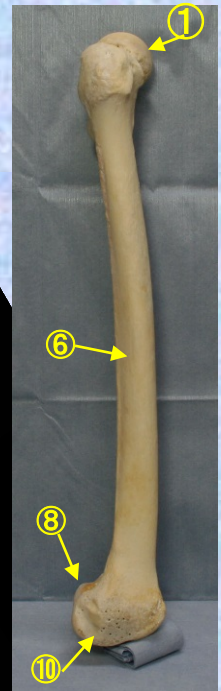
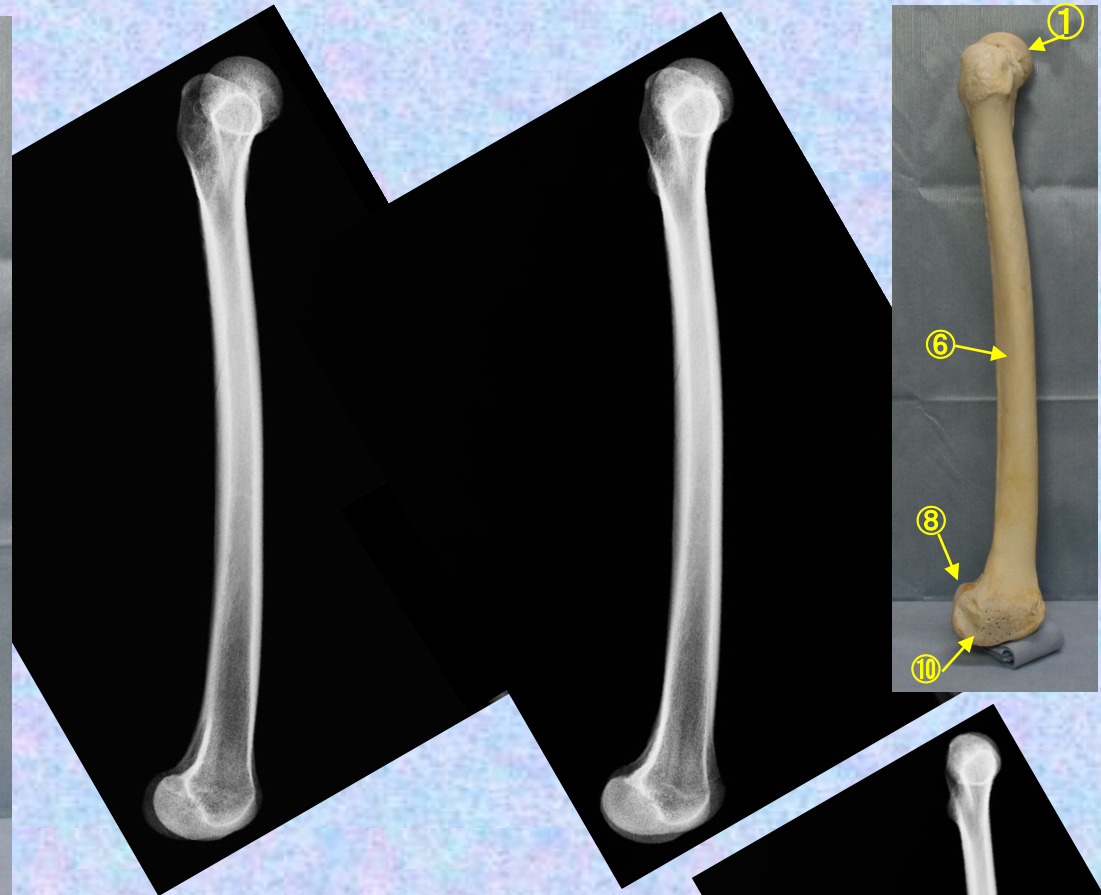
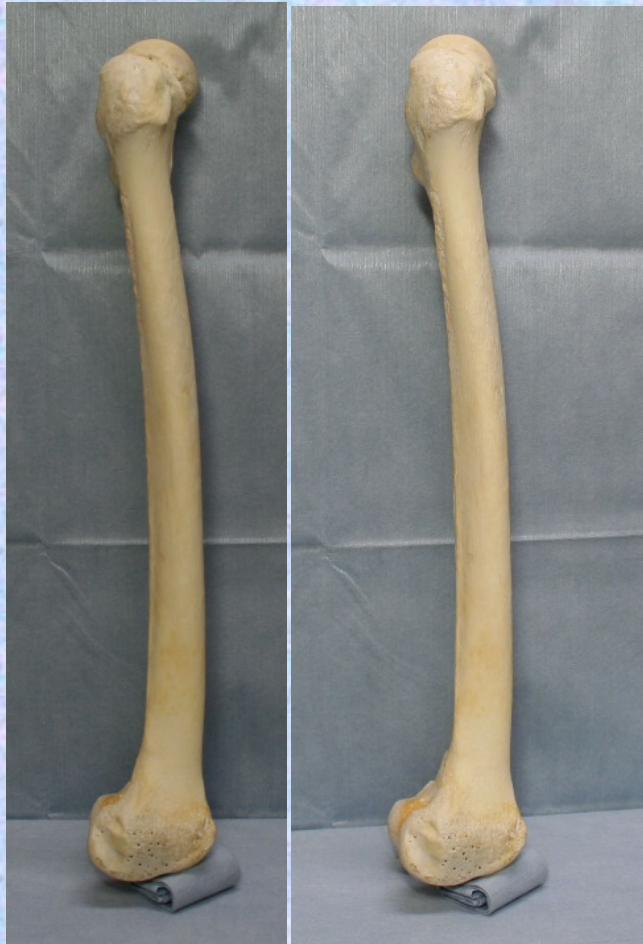- ① 大腿骨頭 head of femur
- ② 大腿骨頸 neck of femur
- ③ 轉子窩 trochanteric fossa
- ④ 大轉子 greater trochanter
- ⑤ 小轉子 lesser trochanter
- ⑥ 大腿骨體 shaft of femur

- ⑦ 膝蓋面 patellar surface
- ⑧ 內側窩 medial condyle
- ⑨ 內側上窩 medial epicondyle
- ⑩ 外側窩 lateral condyle
- ⑪ 外側上窩 lateral epicondyle
- ⑫ 顆間窩 intercondylar fossa



大腿骨 Femur 外側面

外側面 (Femur external view)



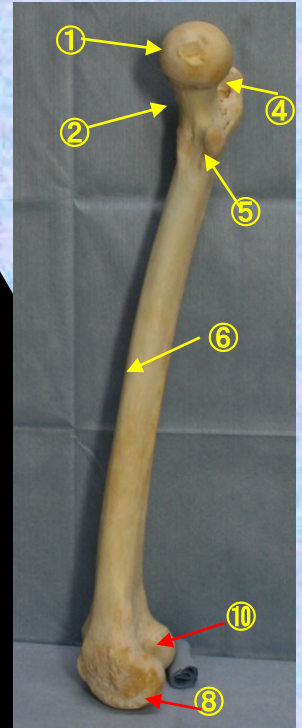
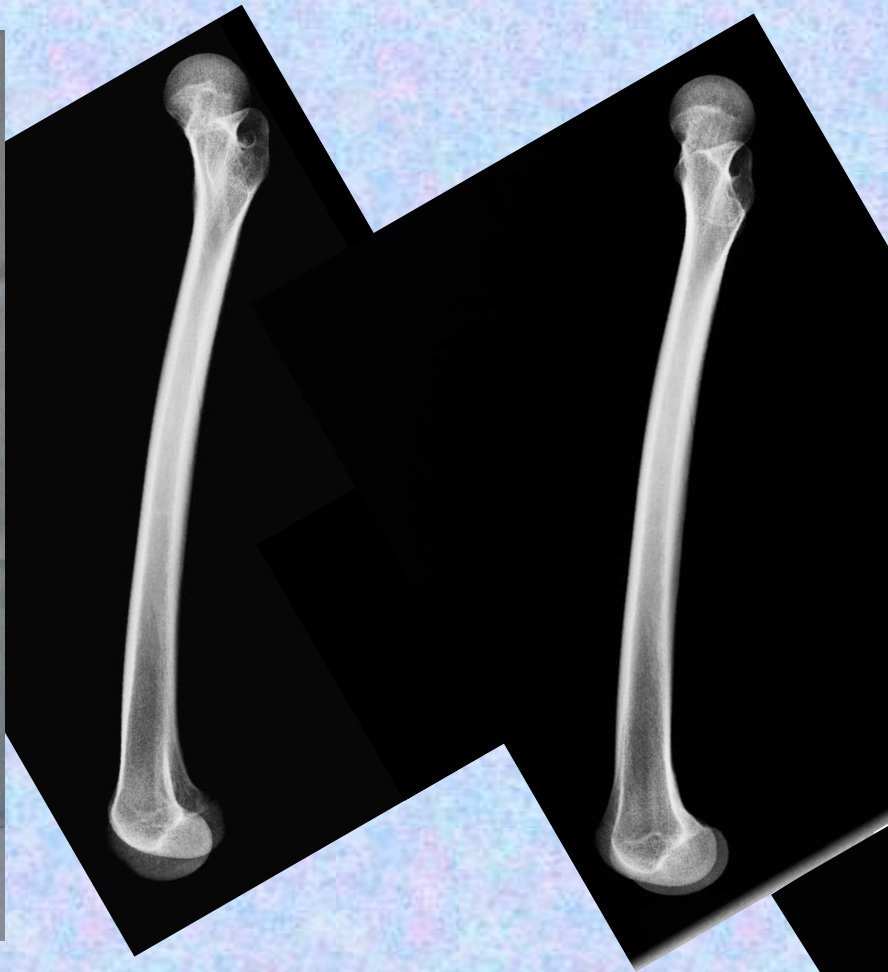
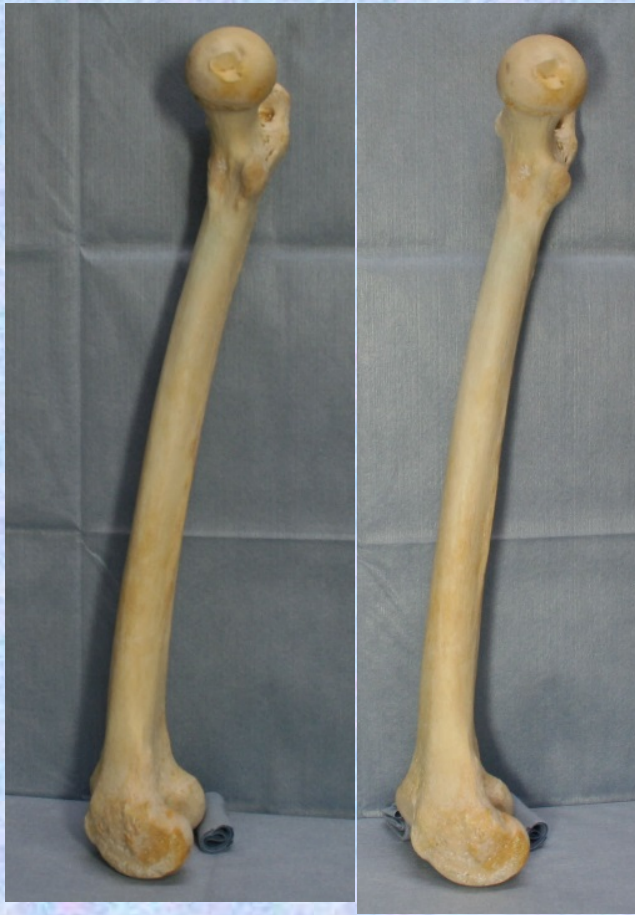- ① 大腿骨頭 head of femur
- ② 大腿骨頸 neck of femur
- ③ 轉子窩 trochanteric fossa
- ④ 大轉子 greater trochanter
- ⑤ 小轉子 lesser trochanter
- ⑥ 大腿骨體 shaft of femur

- ⑦ 膝蓋面 patellar surface
- ⑧ 內側窩 medial condyle
- ⑨ 內側上窩 medial epicondyle
- ⑩ 外側窩 lateral condyle
- ⑪ 外側上窩 lateral epicondyle
- ⑫ 顆間窩 intercondylar fossa



大腿骨 Femur 内側面

後面 (Femur interal view)



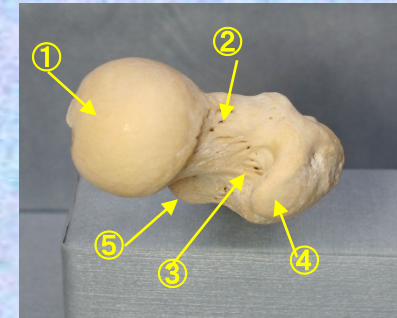
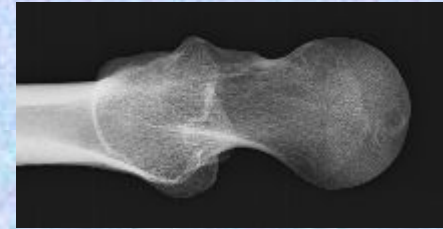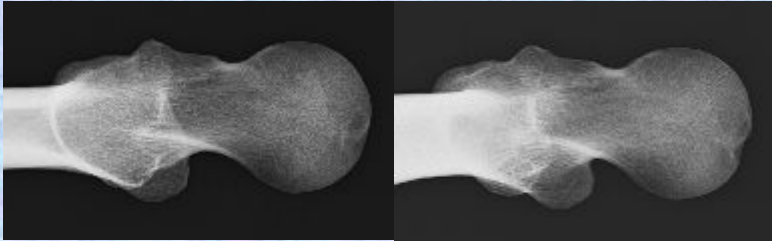
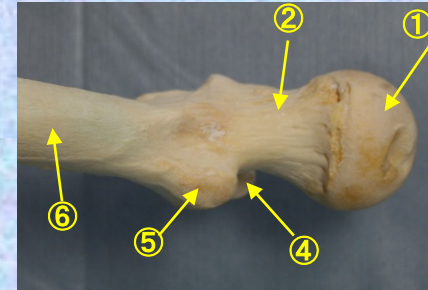
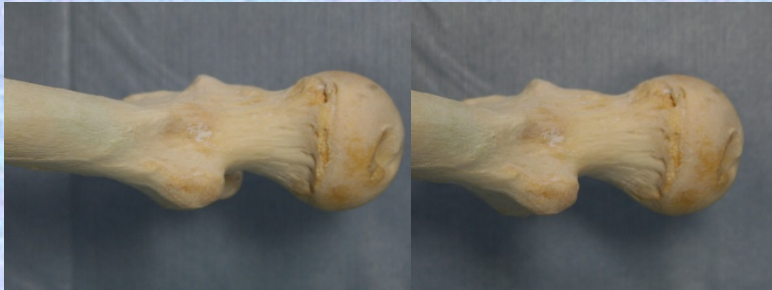- ① 大腿骨頭 head of femur
- ② 大腿骨頸 neck of femur
- ③ 転子窩 trochanteric fossa
- ④ 大転子 greater trochanter
- ⑤ 小転子 lesser trochanter
- ⑥ 大腿骨体 shaft of femur

- ⑦ 膝蓋面 patellar surface
- ⑧ 内側窩 medial condyle
- ⑨ 内側上窩 medial epicondyle
- ⑩ 外側窩 lateral condyle
- ⑪ 外側上窩 lateral epicondyle
- ⑫ 顆間窩 intercondylar fossa



大腿骨 Femur 軸位

軸位 (Femur axial view)



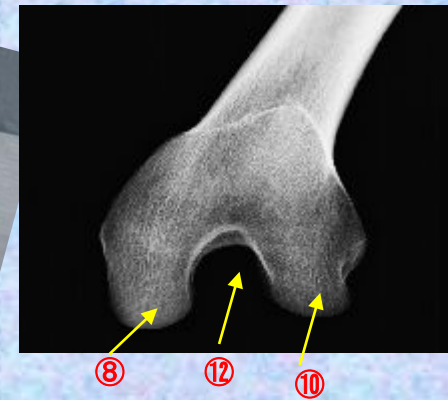
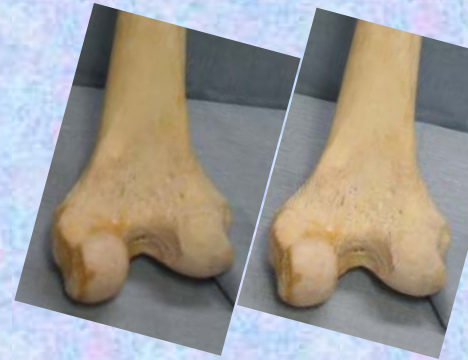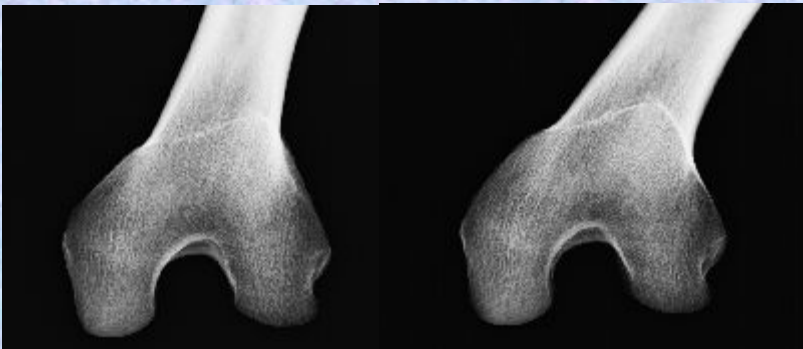
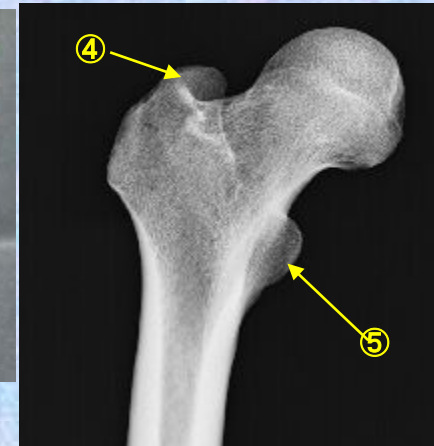
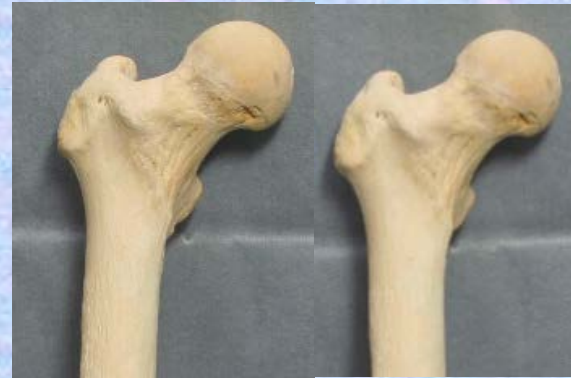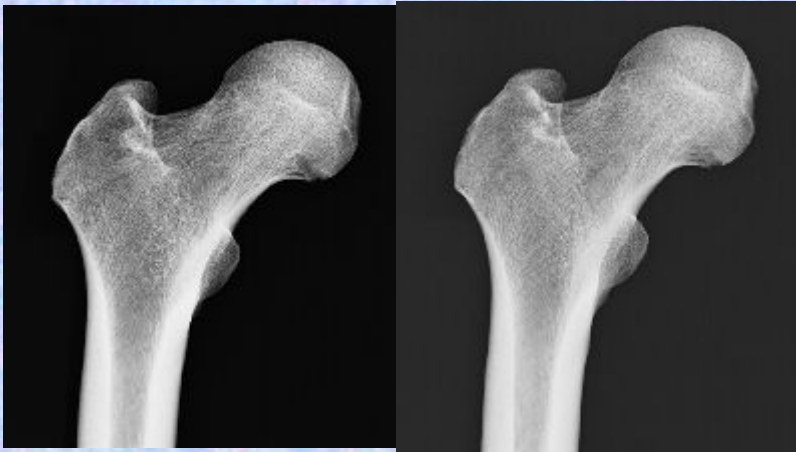- ① 大腿骨頭 head of femur
- ② 大腿骨頸 neck of femur
- ③ 轉子窩 trochanteric fossa
- ④ 大轉子 greater trochanter
- ⑤ 小轉子 lesser trochanter
- ⑥ 大腿骨體 shaft of femur

- ⑦ 膝蓋面 patellar surface
- ⑧ 內側窩 medial condyle
- ⑨ 內側上窩 medial epicondyle
- ⑩ 外側窩 lateral condyle
- ⑪ 外側上窩 lateral epicondyle
- ⑫ 顆間窩 intercondylar fossa



大腿骨 Femur 軸位

軸位 (Femur axial view)



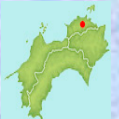- ① 大腿骨頭 head of femur
- ② 大腿骨頸 neck of femur
- ③ 轉子窩 trochanteric fossa
- ④ 大轉子 greater trochanter
- ⑤ 小轉子 lesser trochanter
- ⑥ 大腿骨體 shaft of femur

- ⑦ 膝蓋面 patellar surface
- ⑧ 內側窩 medial condyle
- ⑨ 內側上窩 medial epicondyle
- ⑩ 外側窩 lateral condyle
- ⑪ 外側上窩 lateral epicondyle
- ⑫ 顆間窩 intercondylar fossa



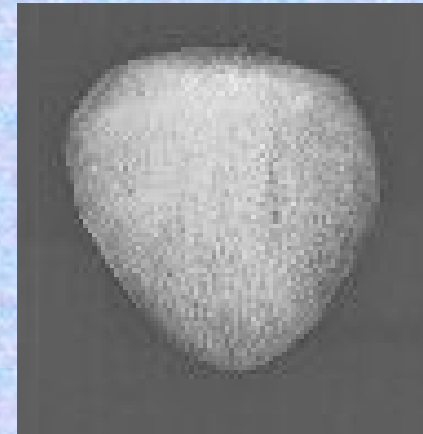
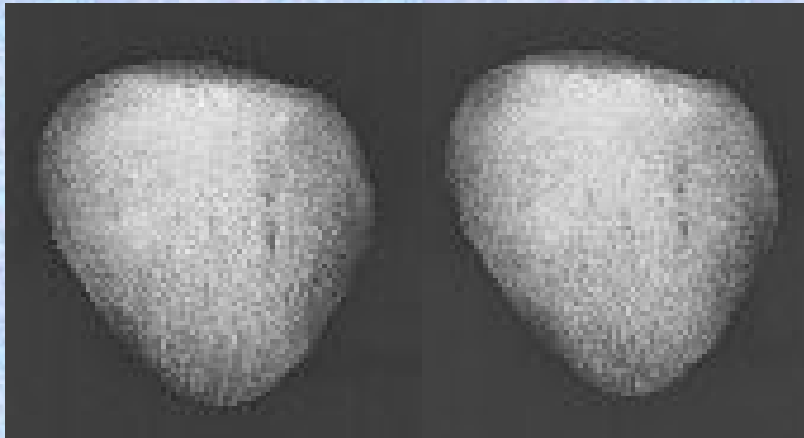
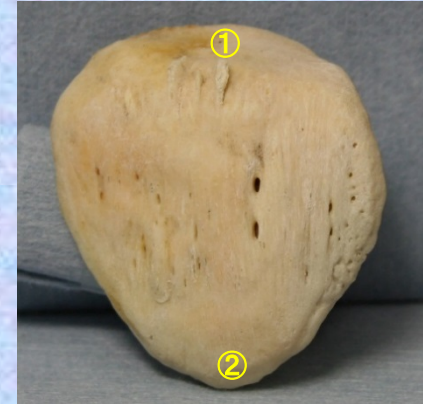
膝蓋骨

patella



膝蓋骨 patella 前面

前面 (patella anterior view)



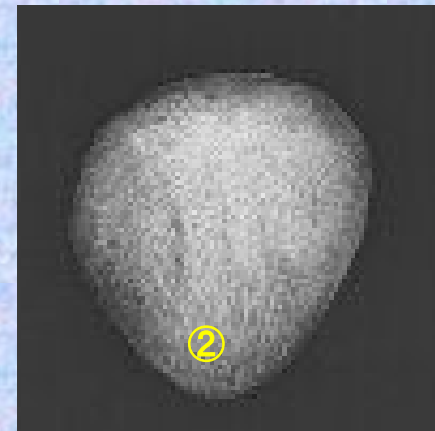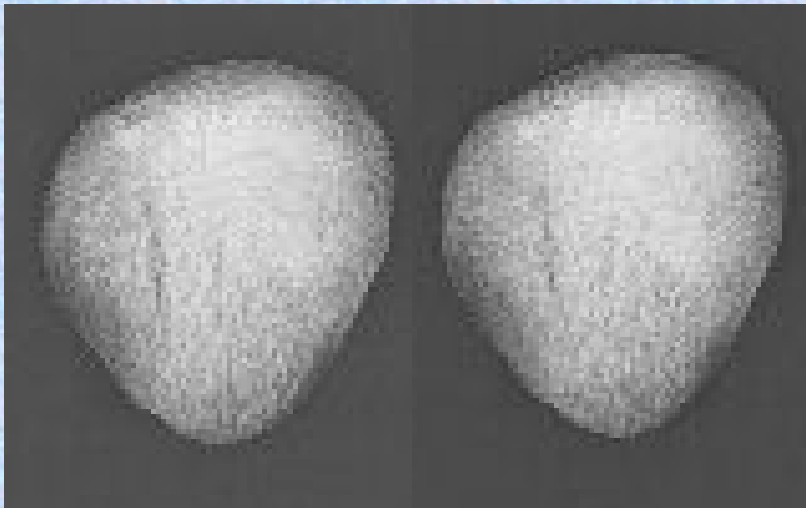
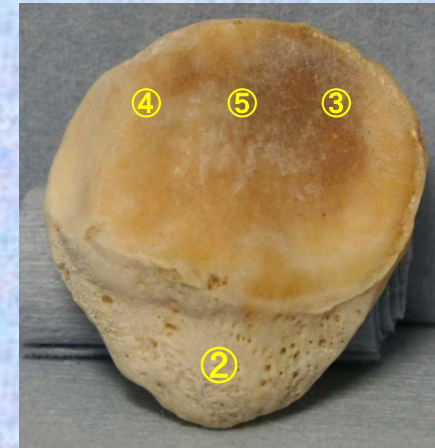
- ①膝蓋骨底 base of patella
- ②膝蓋骨尖 apex of patella
- ③大腿骨の外側に対向する facet for lateral condyle of femur
- ④前縁 anterior border

- ⑤大腿骨の内側に対向する facet for medial condyle of femur
- ⑥垂直稜 vertical ridge



膝蓋骨 patella 後面

後面 (patella posterior view)



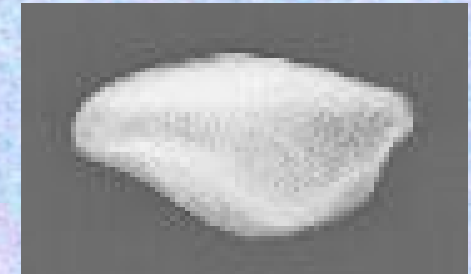
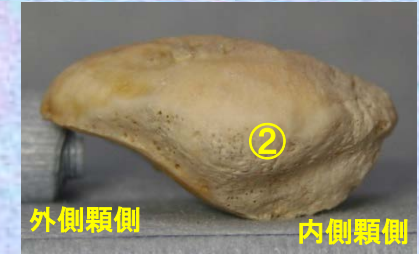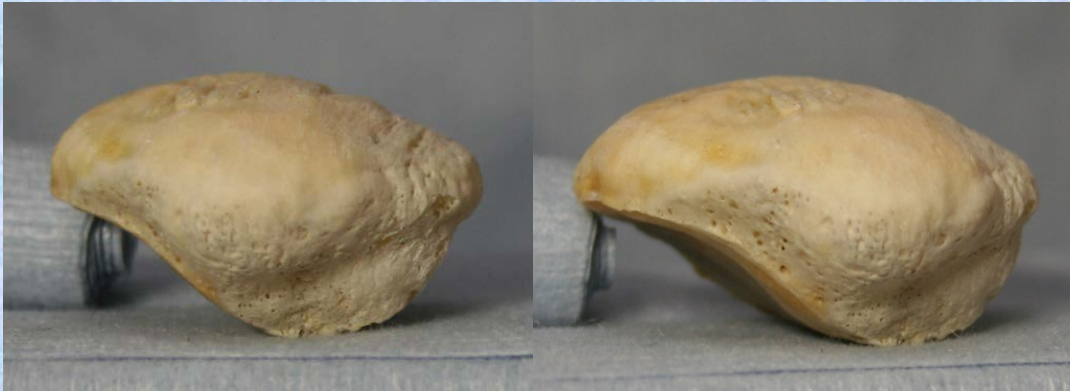- ①膝蓋骨底 base of patella
- ②膝蓋骨尖 apex of patella
- ③大腿骨の外側に対向する facet for lateral condyle of femur
- ④前縁 anterior border

- ⑤大腿骨の内側に対向する facet for medial condyle of femur
- ⑥垂直稜 vertical ridge



膝蓋骨 patella 軸位

軸位 (patella axial view)



- ①膝蓋骨底 base of patella
- ②膝蓋骨尖 apex of patella
- ③大腿骨の外側に対向する facet for lateral condyle of femur
- ④前縁 anterior border

- ⑤大腿骨の内側に対向する facet for medial condyle of femur
- ⑥垂直稜 vertical ridge




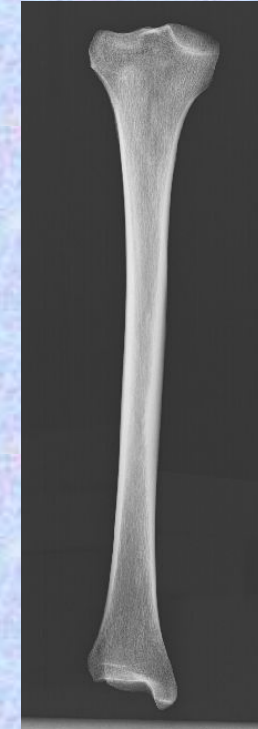
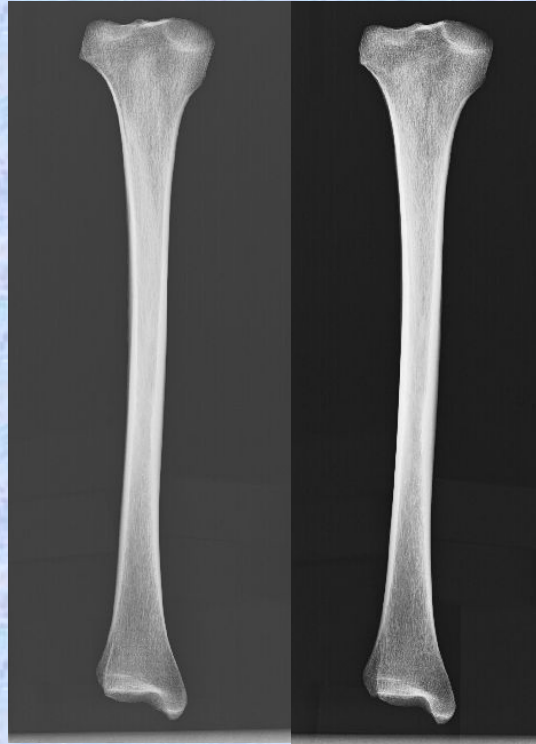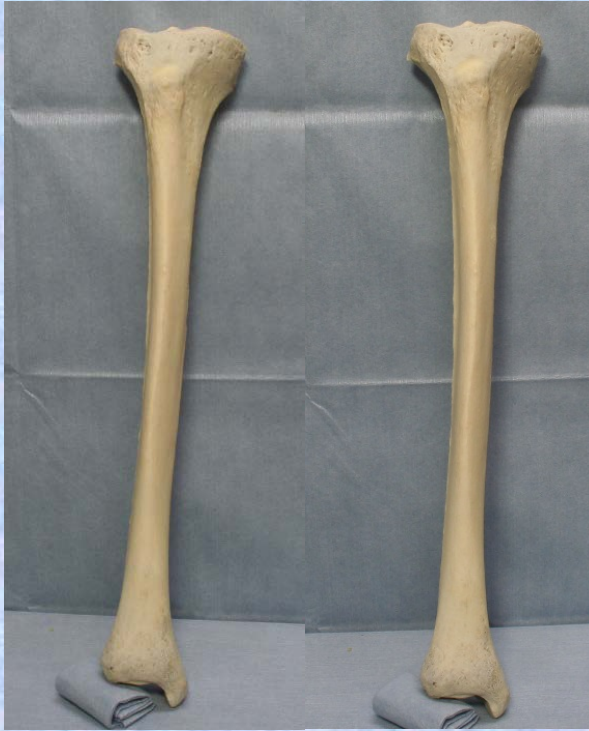
脛骨

tibia



脛骨 tibia 前面

前面 (tibia anterior view)



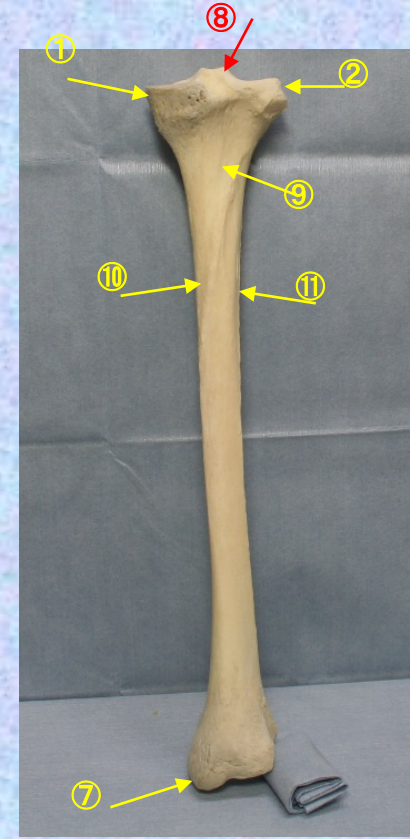
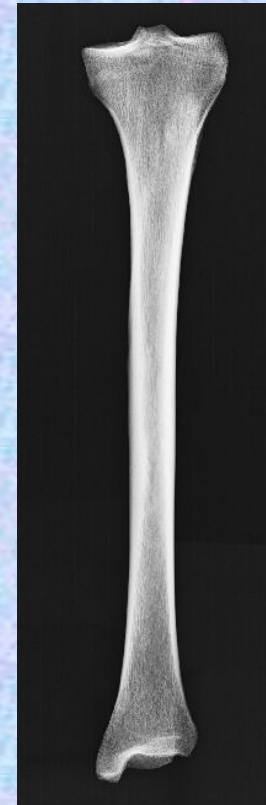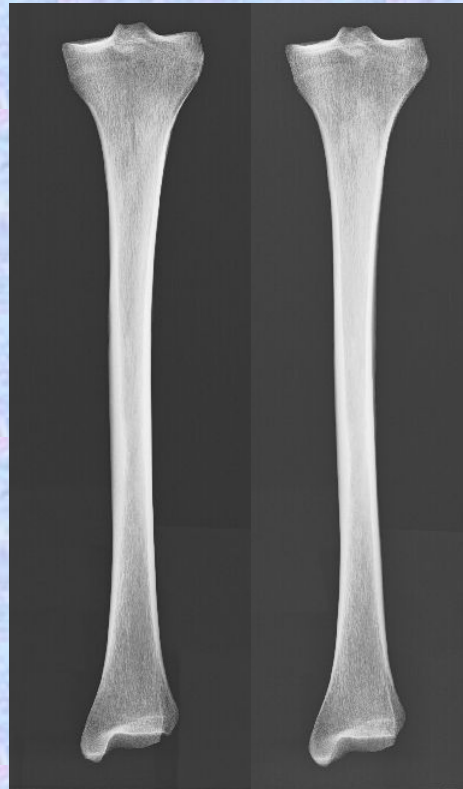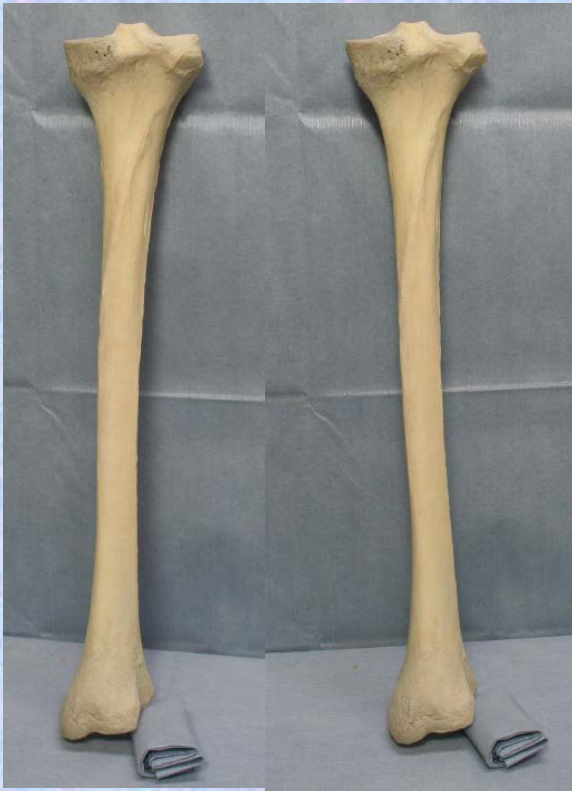- ①内側顆 medial condyle
- ②外側顆 lateral condyle
- ③脛骨粗面 tuberosity
- ④前縁 **anterior border**
- ⑤内側面 medial **surface**
- ⑥外側面 **lateral surface**
- ⑦内果 medial malleolus

- ⑧内側・外側顆間結節 tubercles of intercondylar eminence
- ⑨後面 posterior surface
- ⑩内側縁 medial border
- ⑪骨間縁 **interosseous border**
- ⑫前顆間区 anterior intercondylar area
- ⑬後顆間区 posterior intercondylar area



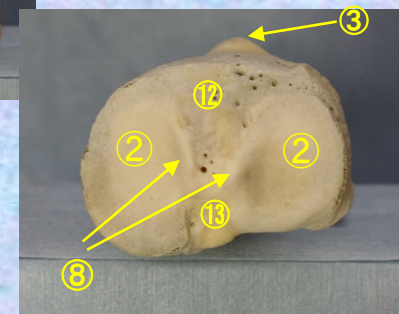
脛骨 tibia 後面

後面 (tibia posterior view)



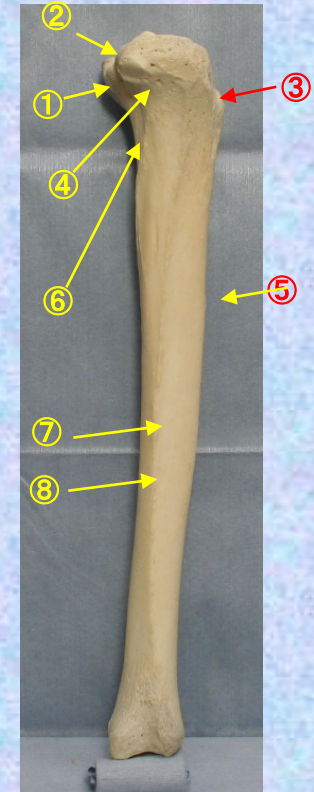
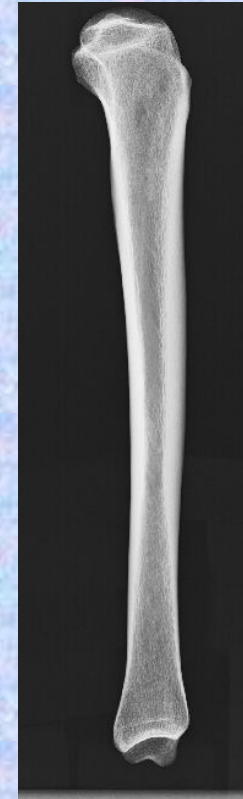
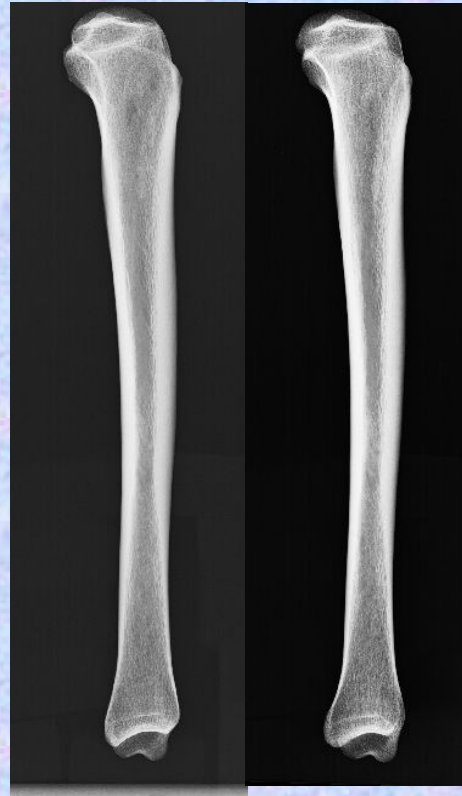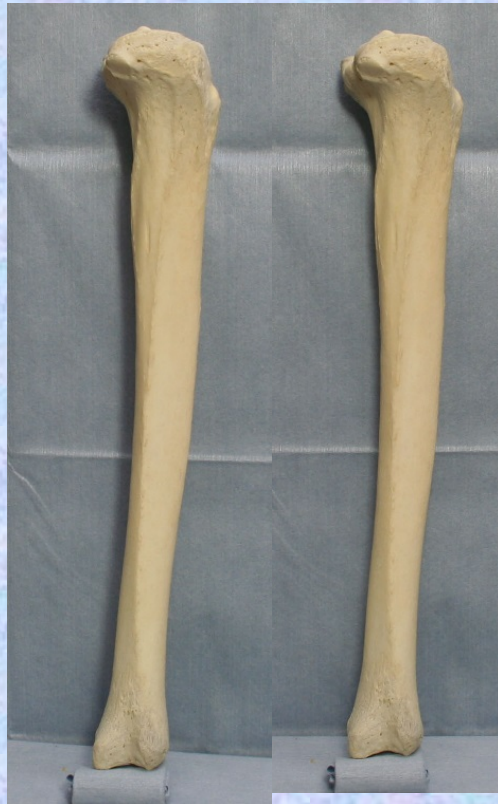- ①内側顆 medial condyle
- ②外側顆 lateral condyle
- ③脛骨粗面 tuberosity
- ④前縁 anterior border
- ⑤内側面 medial surface
- ⑥外側面 lateral surface
- ⑦内果 medial malleolus

- ⑧内側・外側顆間結節 tubercles of intercondylar eminence
- ⑨後面 posterior surface
- ⑩内側縁 medial border
- ⑪骨間縁 interosseous border
- ⑫前顆間区 anterior intercondylar area
- ⑬後顆間区 posterior intercondylar area

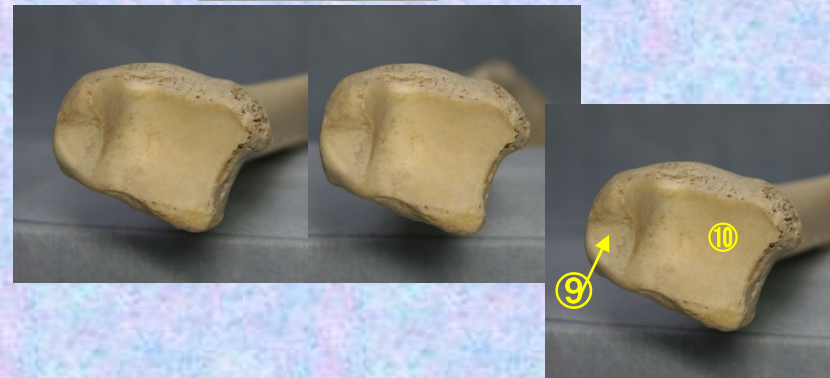


脛骨 tibia 外側面

外側面 (tibia lateral view)

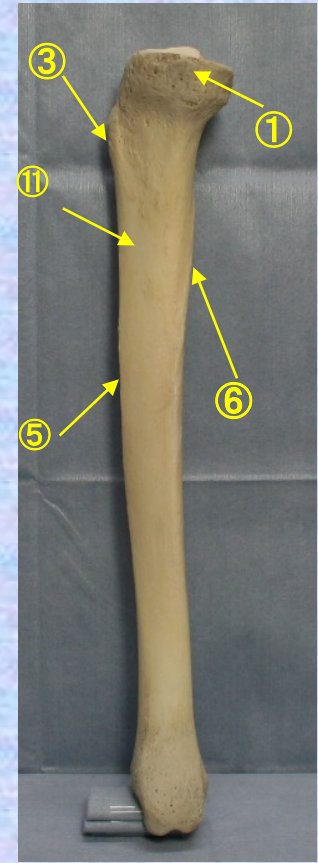
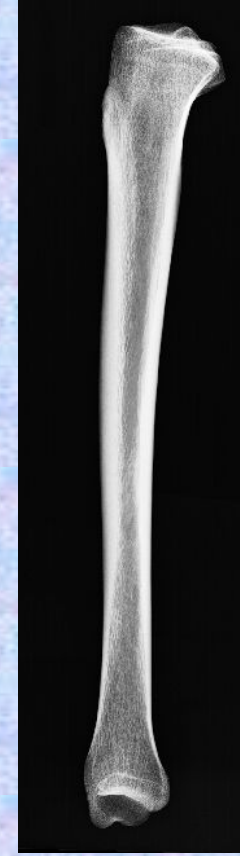
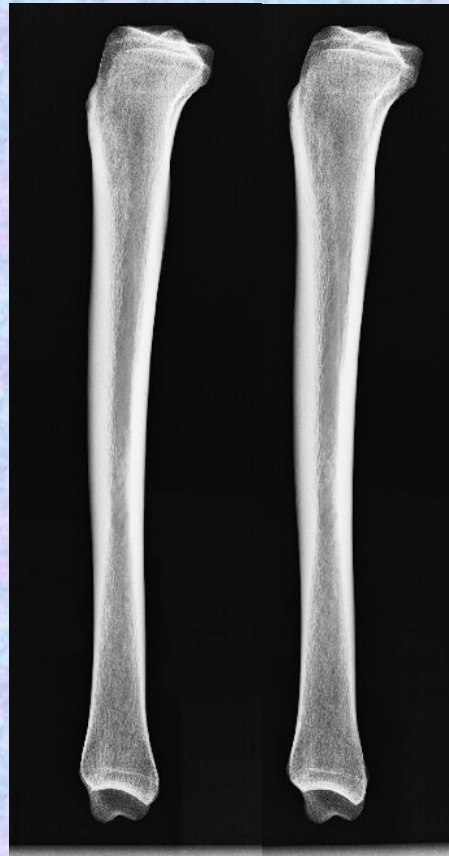
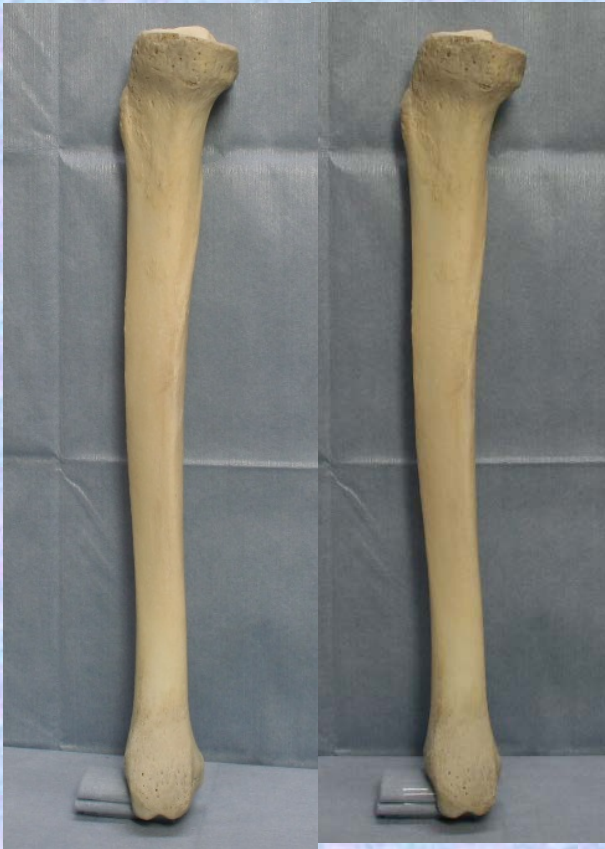
- | | | | |
|-------|-------------------------|------------|-------------------------------------|
| ①内側顆 | medial condyle | ⑧内側・外側顆間結節 | tubercles of intercondylar eminence |
| ②外側顆 | lateral condyle | ⑨後面 | posterior surface |
| ③脛骨粗面 | tuberosity | ⑩内側縁 | medial border |
| ④前縁 | anterior border | ⑪骨間縁 | interosseous border |
| ⑤内側面 | medial surface | ⑫前顆間区 | anterior intercondylar area |
| ⑥外側面 | lateral surface | ⑬後顆間区 | posterior intercondylar area |
| ⑦内臑 | medial malleolus | | |



脛骨 tibia 内側面

内側面 (tibia medial view)



- ①内側顆 medial condyle
- ②外側顆 lateral condyle
- ③脛骨粗面 tuberosity
- ④前縁 **anterior border**
- ⑤内側面 medial **surface**
- ⑥外側面 **lateral surface**
- ⑦内果 medial malleolus

- ⑧内側・外側顆間結節 tubercles of intercondylar eminence
- ⑨後面 posterior surface
- ⑩内側縁 medial border
- ⑪骨間縁 **interosseous border**
- ⑫前顆間区 anterior intercondylar area
- ⑬後顆間区 posterior intercondylar area




腓骨

fibula



右腓骨 fibula 前面

前面 (fibula anterior view)





- ① 腓骨頭尖 (茎状突起) apex of head (styloid process)
- ② 腓骨頭 head of fibula
- ③ 外果關節面 articular facet of lateral malleolus (for ankle joint)
- ④ 外果 lateral malleolus
- ⑤ 外果窩 malleolar fossa
- ⑥ ヒラメ筋線 soleal line
- ⑦ 骨間縁 interosseous border

- ⑥ 腓骨頸 neck of fibula
- ⑦ 内果稜 medial crest
- ⑧ 内果面 medial surface
- ⑨ 後面 posterior surface
- ⑩ 腓骨頭關節面 articular facet (for superior tibiofibular joint)



右腓骨 fibula 後

後面 (fibula posterior view)



① 腓骨頭尖 (茎状突起) apex of head (styloid process)

② 腓骨頭 head of fibula

③ 外果關節面 articular facet of lateral malleolus (for ankle joint)

④ 外果 lateral malleolus

⑤ 外果窩 malleolar fossa

⑥ ヒラメ筋線 soleal line

⑦ 骨間縁 interosseous border


⑥ 腓骨頸 neck of fibula

⑦ 内果稜 medial crest

⑧ 内果面 medial surface


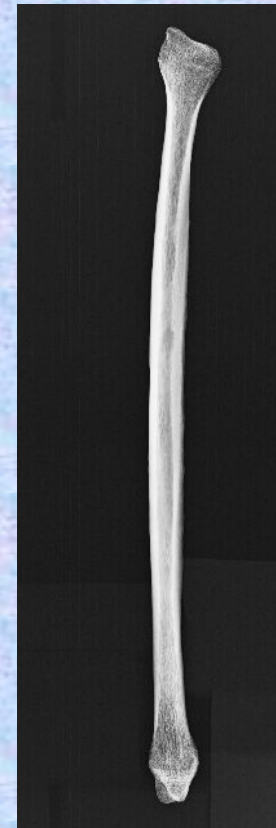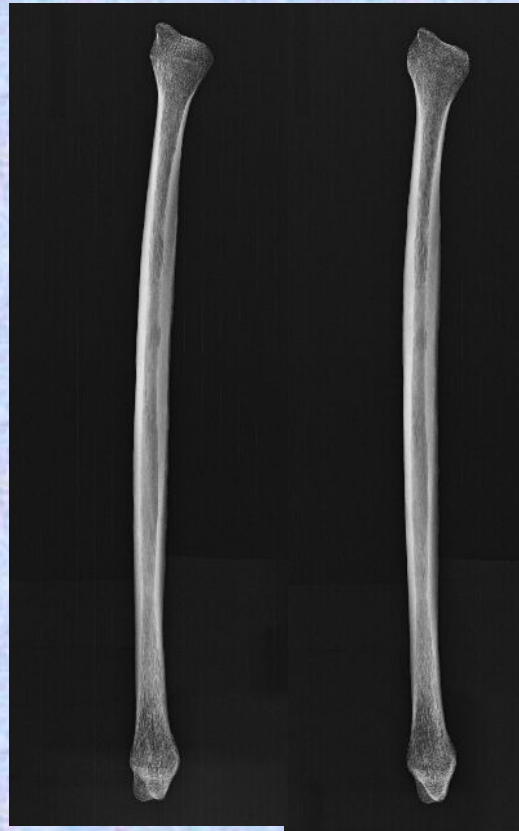

⑨ 後面 posterior surface

⑩ 腓骨頭關節面 articular facet (for superior tibiofibular joint)



右腓骨 fibula 外側面

外側面 (fibula lateral view)




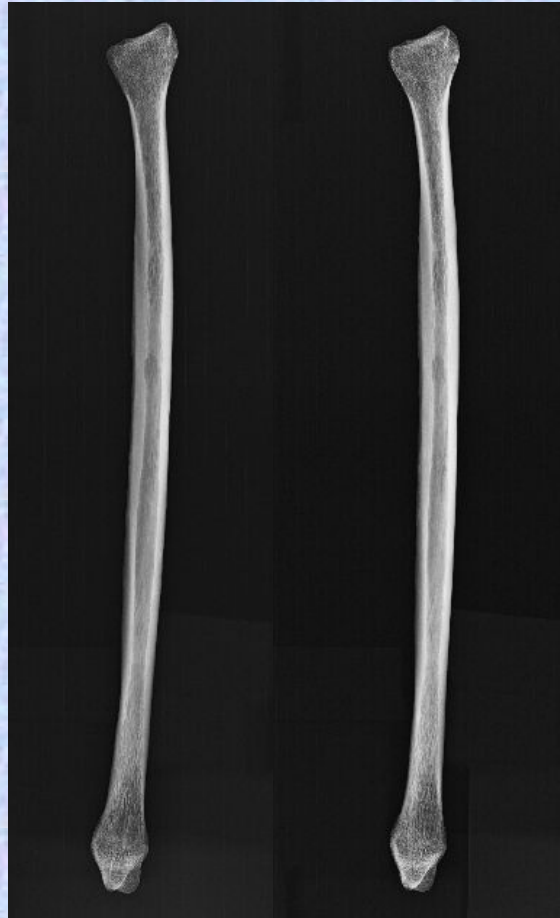
- ① 腓骨頭尖 (茎状突起) apex of head (styloid process)
- ② 腓骨頭 head of fibula
- ③ 外果關節面 articular facet of lateral malleolus (for ankle joint)
- ④ 外果 lateral malleolus
- ⑤ 外果窩 malleolar fossa
- ⑥ ヒラメ筋線 soleal line
- ⑦ 骨間縁 interosseous border

- ⑥ 腓骨頸 neck of fibula
- ⑦ 内果稜 medial crest
- ⑧ 内果面 medial surface
- ⑨ 後面 posterior surface
- ⑩ 腓骨頭關節面 articular facet (for superior tibiofibular joint)



右腓骨 fibula 内側面

内側面 (fibula medial view)



① 腓骨頭尖 (茎状突起) apex of head (styloid process)

② 腓骨頭 head of fibula

③ 外果關節面 articular facet of lateral malleolus (for ankle joint)

④ 外果 lateral malleolus

⑤ 外果窩 malleolar fossa

⑥ ヒラメ筋線 soleal line

⑦ 骨間縁 interosseous border

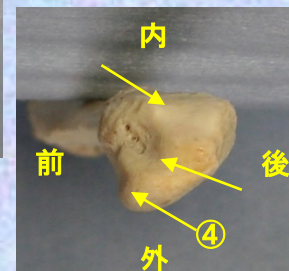
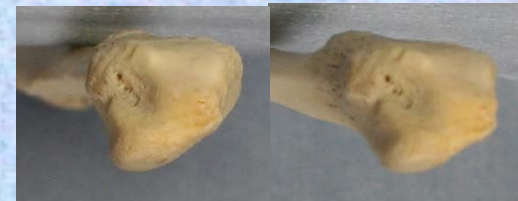⑥ 腓骨頸 neck of fibula

⑦ 内果稜 medial crest

⑧ 内果面 medial surface

⑨ 後面 posterior surface

⑩ 腓骨頭關節面 articular facet (for superior tibiofibular joint)



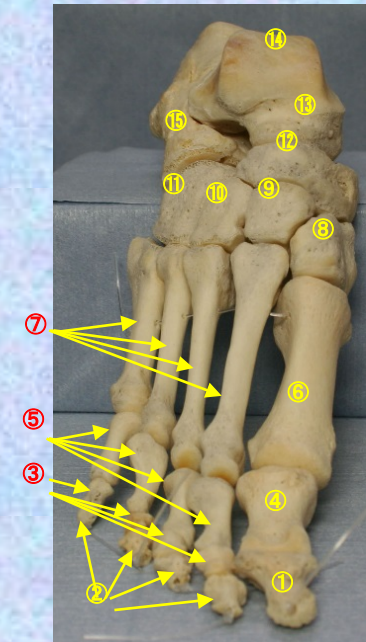
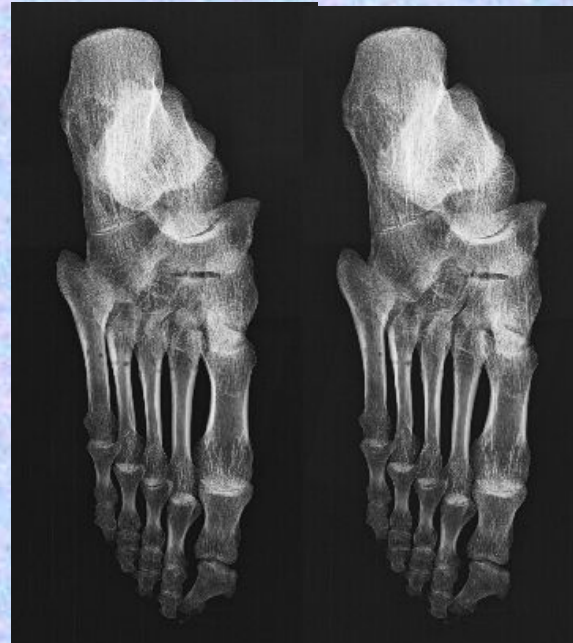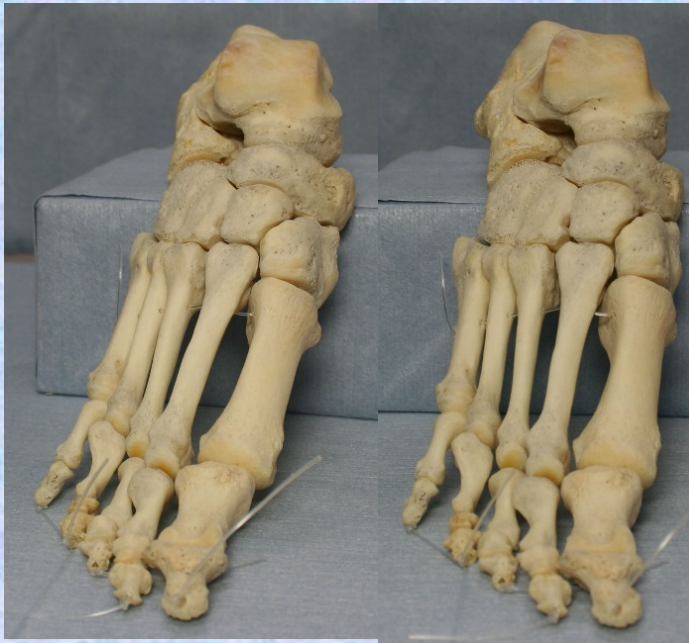足

foot



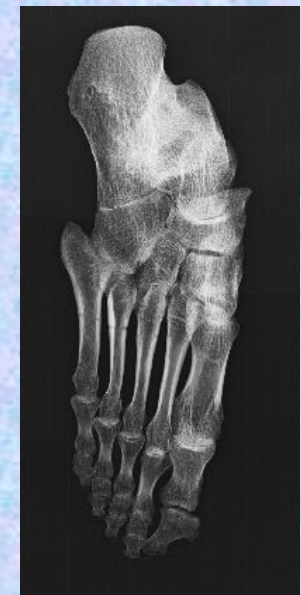右足 foot 背面

背面 (foot dorsal view)



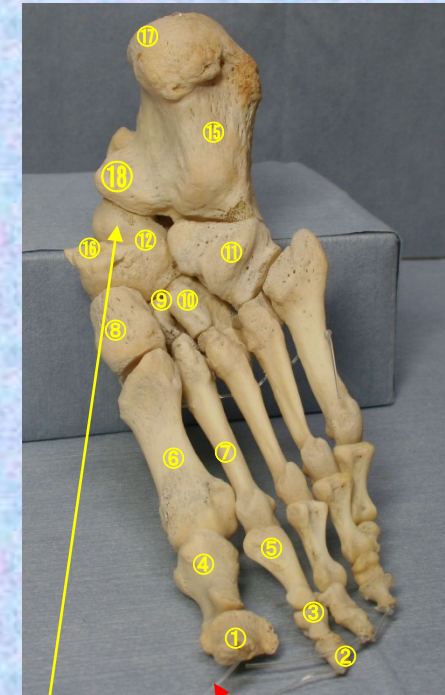
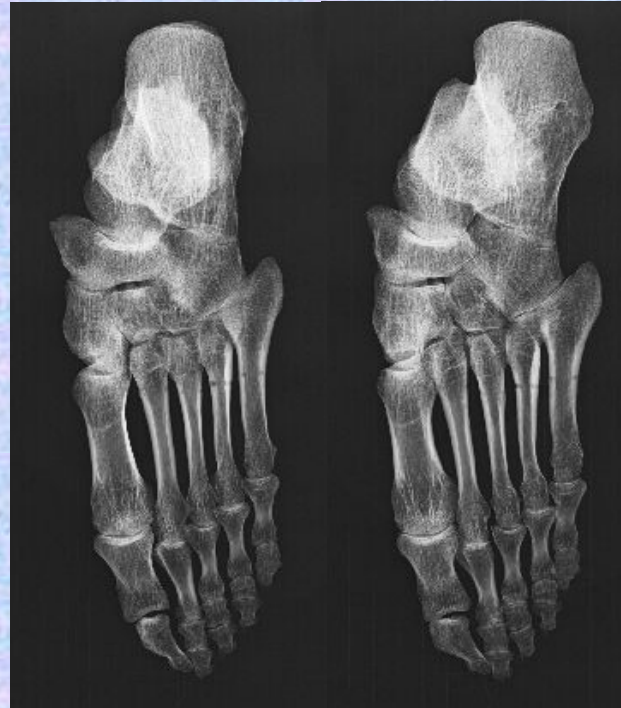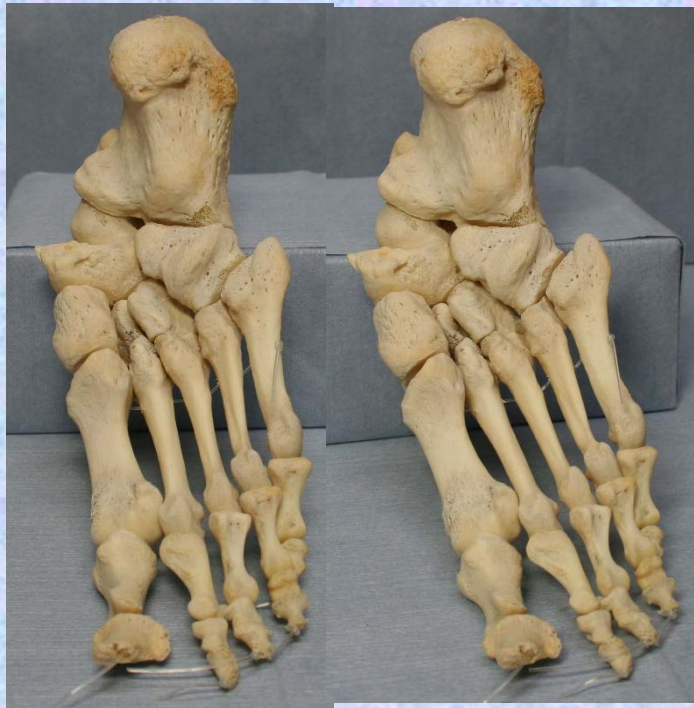- ①末節骨(母趾) distal phalanx of great toe
- ②末節骨(第2~5趾) distal phalanx(2~5)
- ③中節骨(第2~5趾) middle phalanx(2~5)
- ④基節骨(母趾) proximal phalanx of great toe
- ⑤基節骨(第2~5趾) proximal phalanx of toe(2~5:second,third,fourth,fifth)
- ⑥第1中足骨の体 shaft of first metatarsal
- ⑦第2~5中足骨の体 shaft of second metatarsal~shaft of fifth metatarsal

- ⑧ 内側楔(せつ)状骨 medial cuneiform
- ⑨ 中間楔状骨 intermediate cuneiform
- ⑩ 外側楔状骨 lateral cuneiform
- ⑪ 立方骨 cuboid
- ⑫ 舟状骨 navicular
- ⑬ 距骨 talus
- ⑭ 距骨滑車 trochlear surface of body of talus
- ⑮ 踵骨 calcaneus
- ⑯ 舟状骨粗面 tuberosity of navicular
- ⑰ 踵骨隆起内側突起 medial process of navicular
- ⑱ 踵骨の載距突起 sustentaculum tali of calcaneus



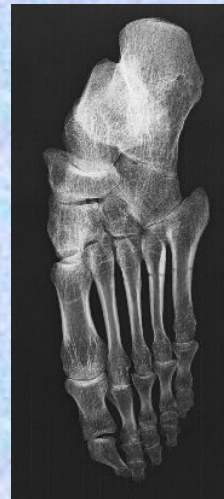右足 foot 底面

底面 (foot volar view)

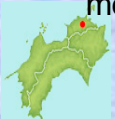

(注) 骨をナイロン糸で固定しているため、踵骨と舟状骨の間に見える距骨がみえていない

- ①末節骨(母趾) distal phalanx of great toe
- ②末節骨(第2~5趾) distal phalanx(2~5)
- ③中節骨(第2~5趾) middle phalanx(2~5)
- ④基節骨(母趾) proximal phalanx of great toe
- ⑤基節骨(第2~5趾) proximal phalanx of toe(2~5:second,third,fourth,fifth)
- ⑥第1中足骨の体 shaft of first metatarsal
- ⑦第2~5中足骨の体 shaft of second metatarsal~shaft of fifth metatarsal

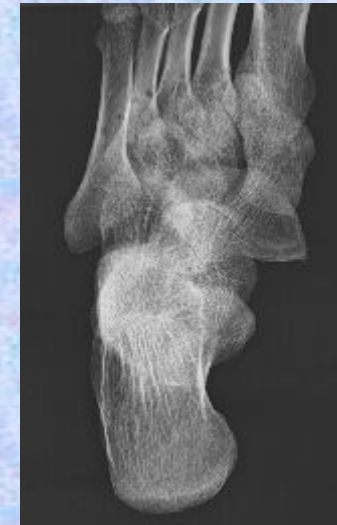
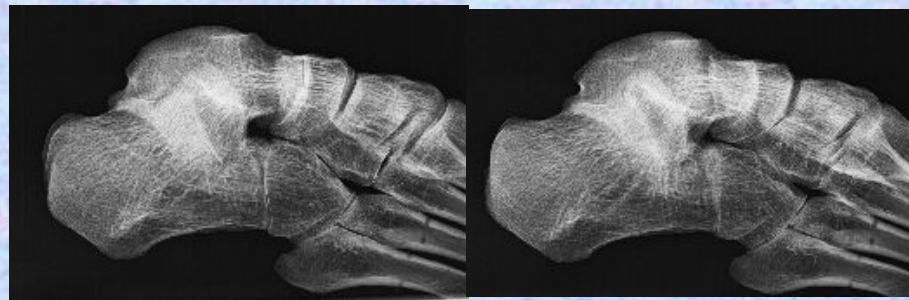
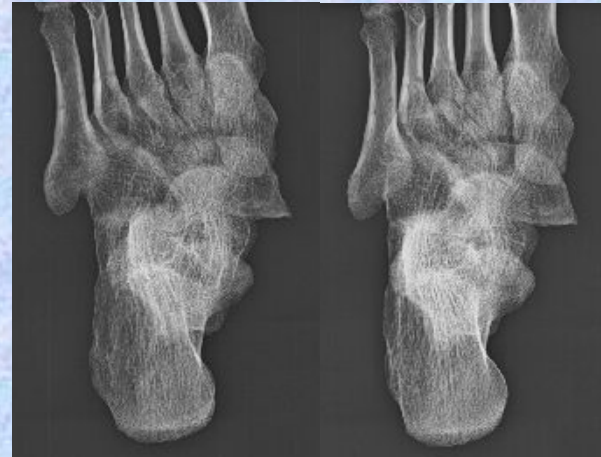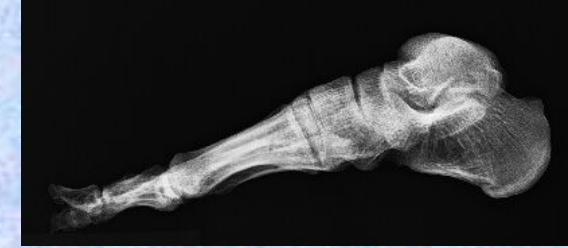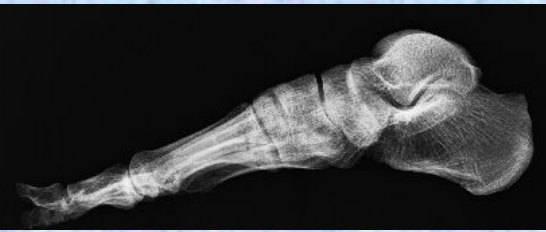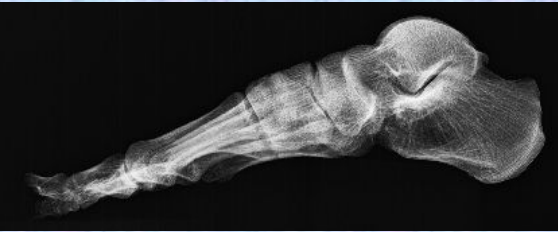- ⑧ 内側楔(せつ)状骨 medial cuneiform
- ⑨ 中間楔状骨 intermediate cuneiform
- ⑩ 外側楔状骨 lateral cuneiform
- ⑪ 立方骨 cuboid
- ⑫ 舟状骨 navicular
- ⑬ 距骨 talus
- ⑭ 距骨滑車 trochlear surface of body of talus
- ⑮ 踵骨 calcaneus
- ⑯ 舟状骨粗面 tuberosity of navicular
- ⑰ 踵骨隆起内側突起 medial process of navicular
- ⑱ 踵骨の載距突起 sustentaculum tali of calcaneus



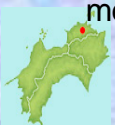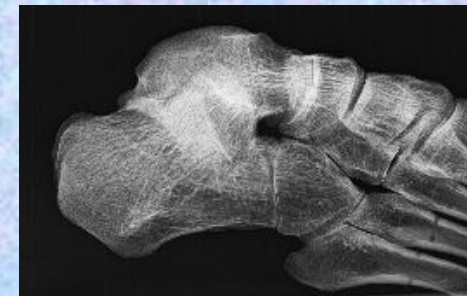右足 foot 側面

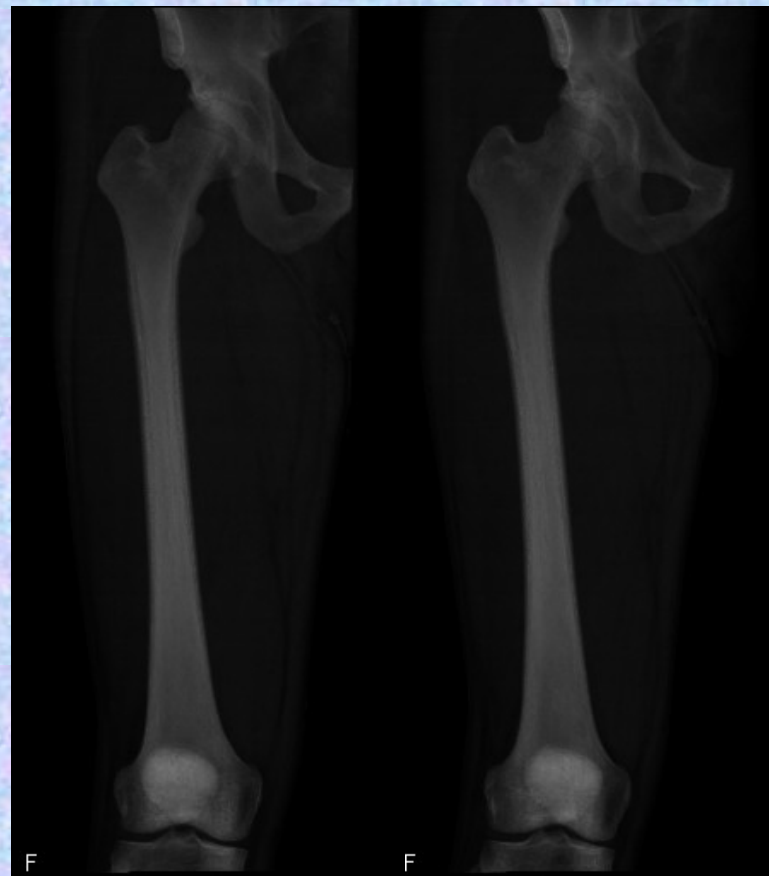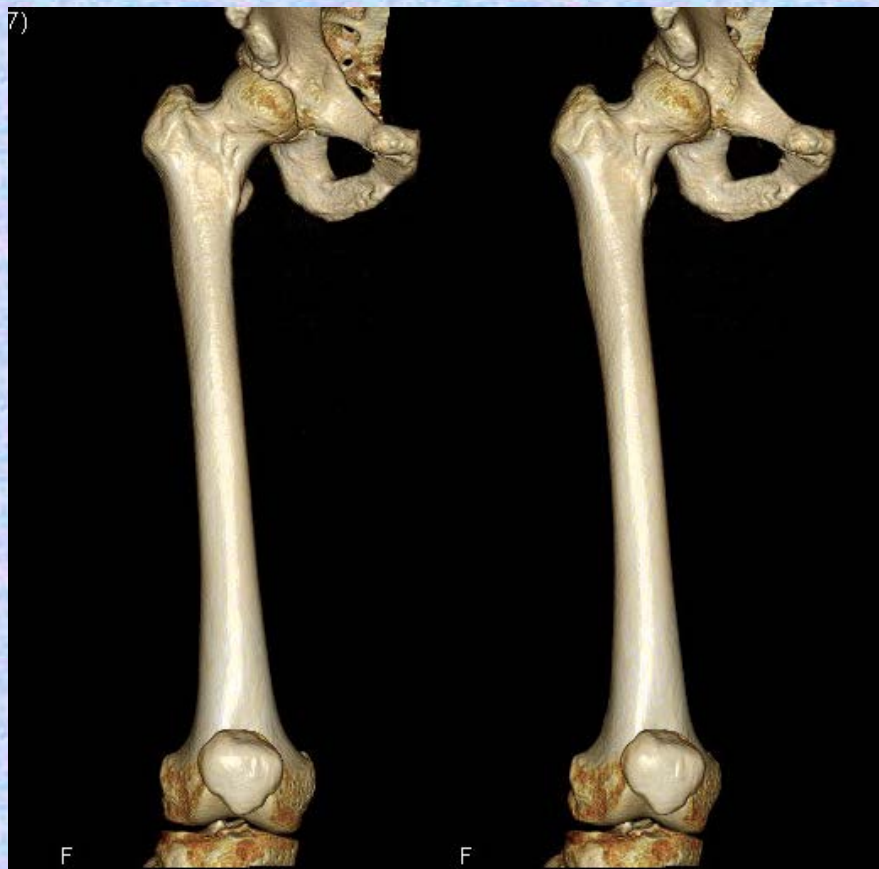側面 (foot lateral view)


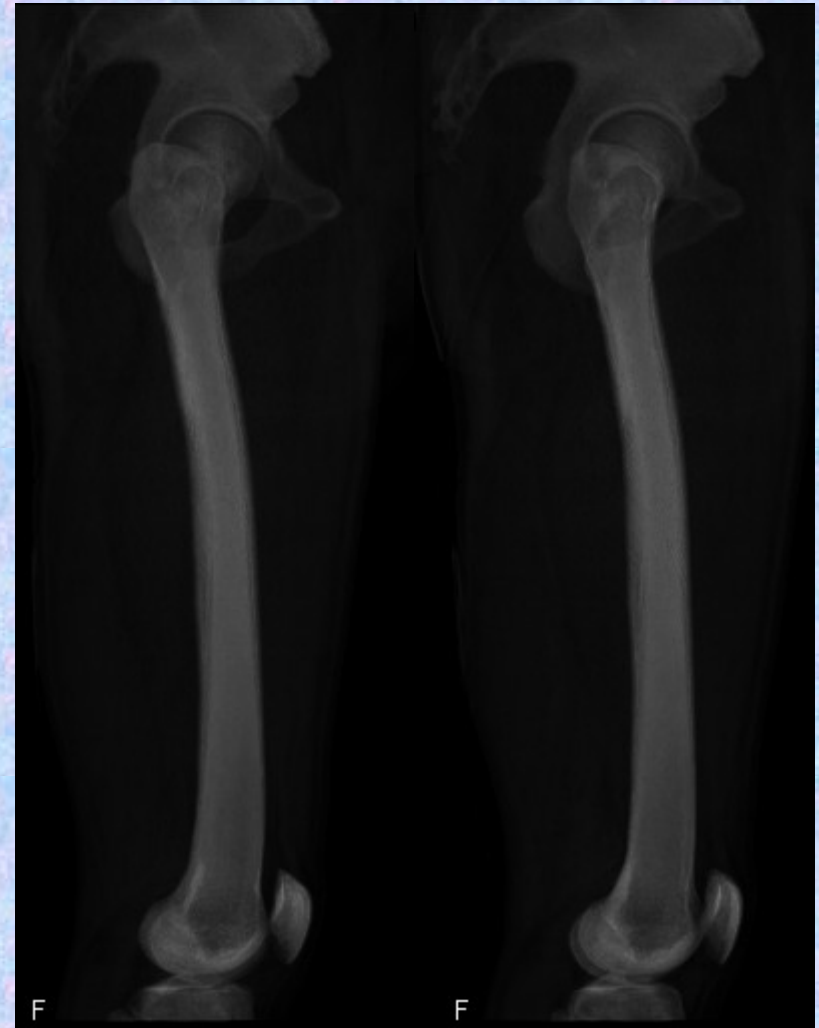
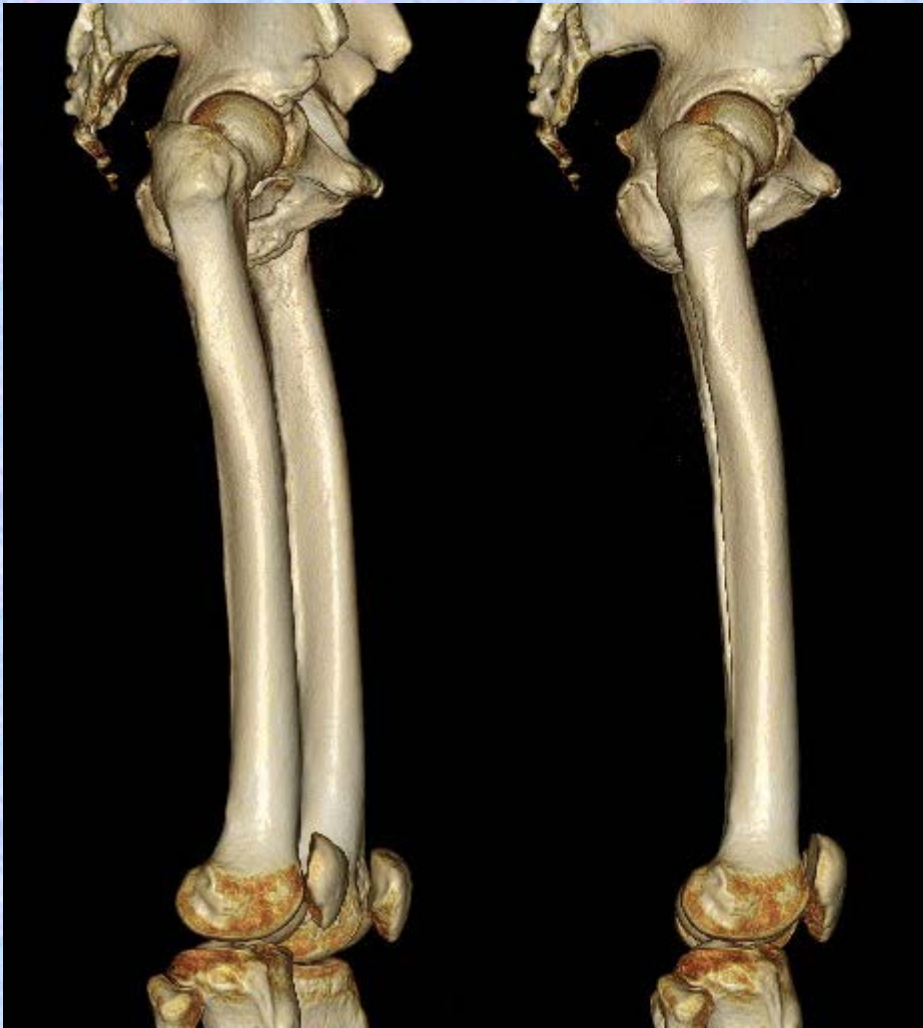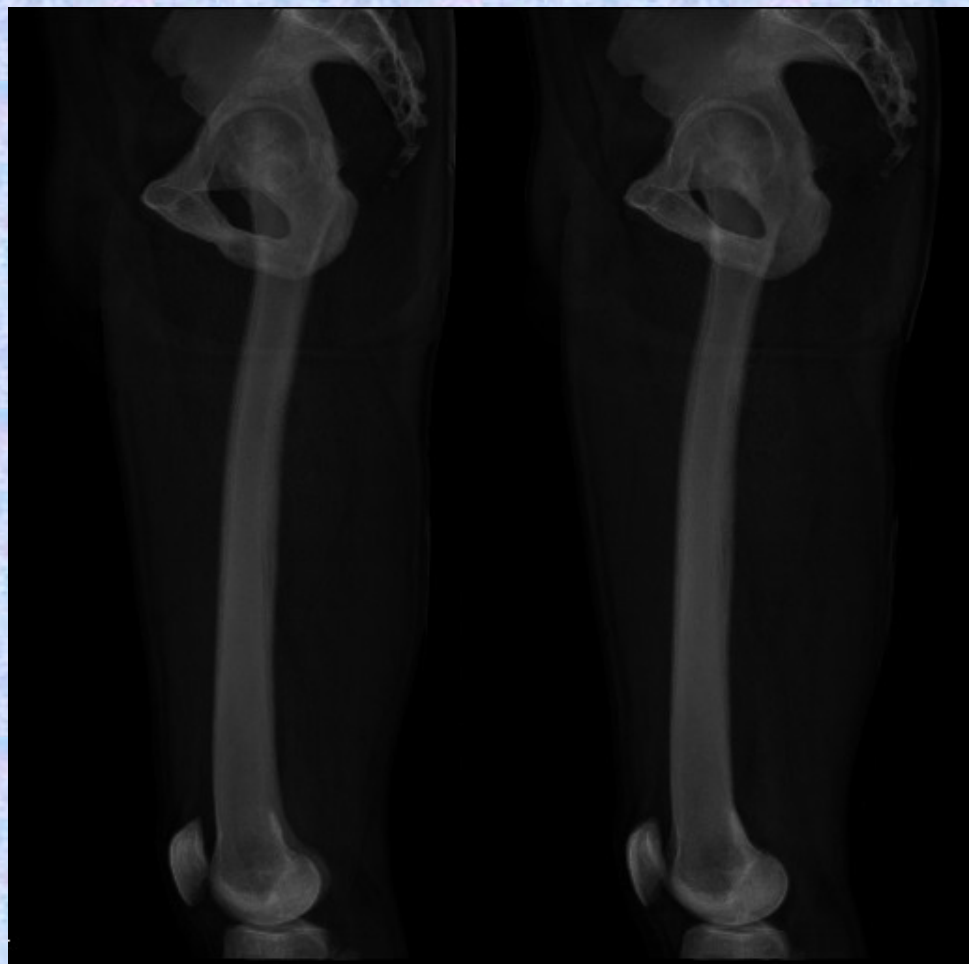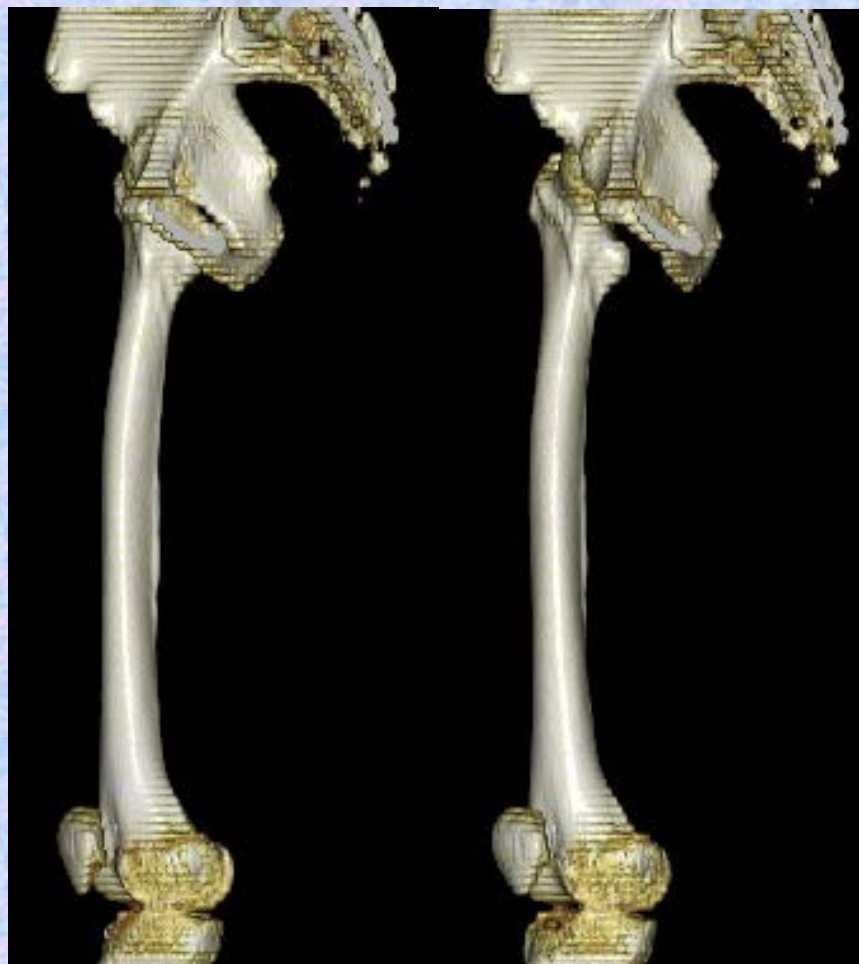- ①末節骨(母趾) distal phalanx of great toe
- ②末節骨(第2~5趾) distal phalanx(2~5)
- ③中節骨(第2~5趾) middle phalanx(2~5)
- ④基節骨(母趾) proximal phalanx of great toe
- ⑤基節骨(第2~5趾) proximal phalanx of toe(2~5:second,third,fourth,fifth)
- ⑥第1中足骨の体 shaft of first metatarsal
- ⑦第2~5中足骨の体 shaft of second metatarsal~shaft of fifth metatarsal

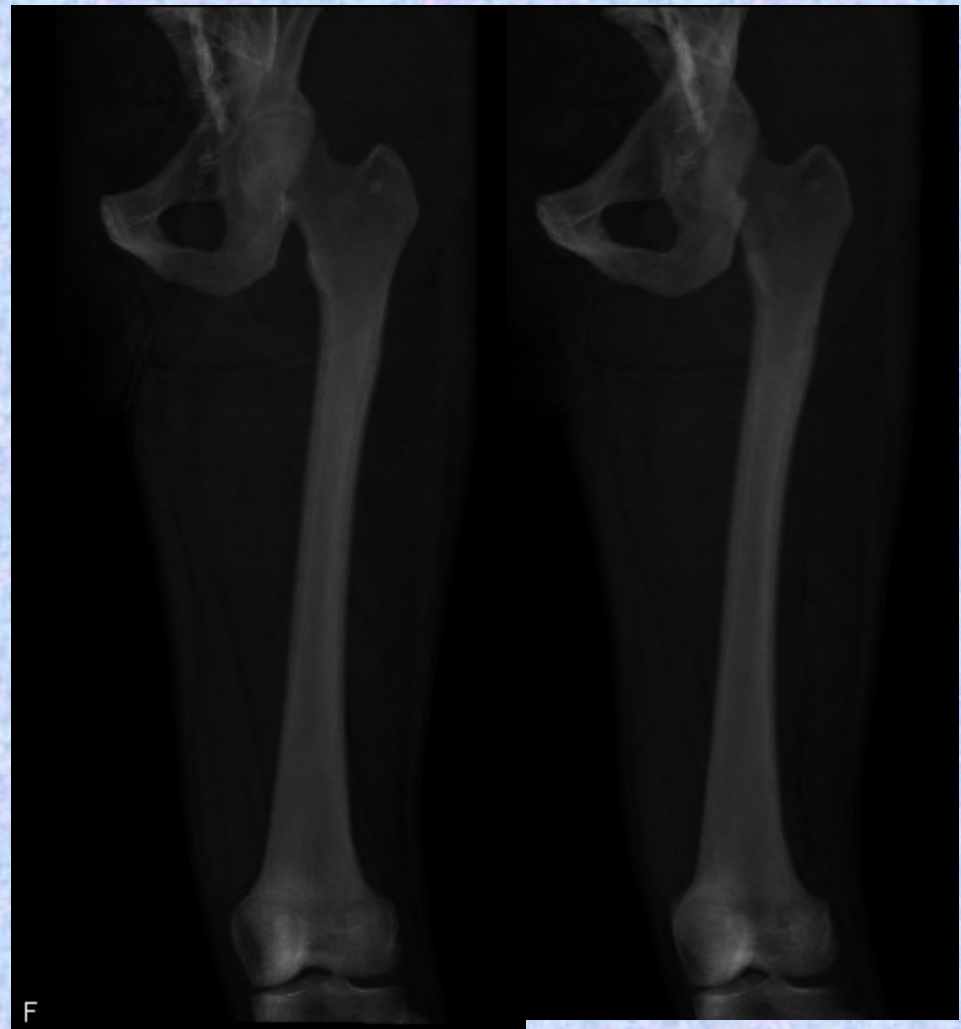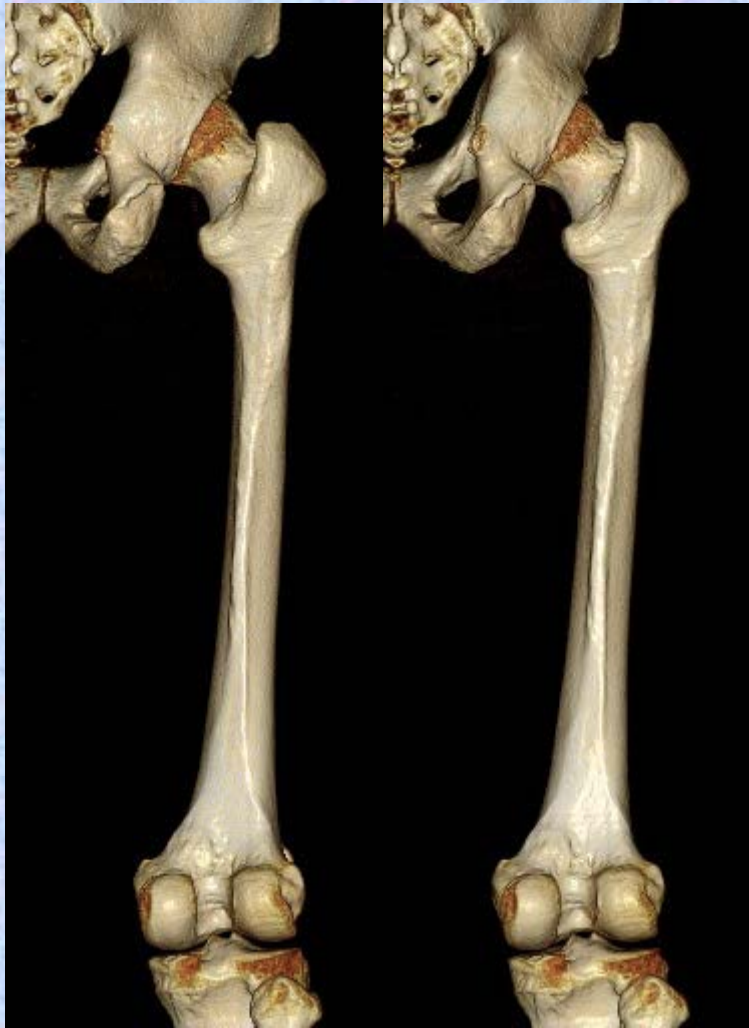- ⑧ 内側楔(せつ)状骨 medial cuneiform
- ⑨ 中間楔状骨 intermediate cuneiform
- ⑩ 外側楔状骨 lateral cuneiform
- ⑪ 立方骨 cuboid
- ⑫ 舟状骨 navicular
- ⑬ 距骨 talus
- ⑭ 距骨滑車 trochlear surface of body of talus
- ⑮ 踵骨 calcaneus
- ⑯ 舟状骨粗面 tuberosity of navicular
- ⑰ 踵骨隆起内側突起 medial process of navicular
- ⑱ 踵骨の載距突起 sustentaculum tali of calcaneus

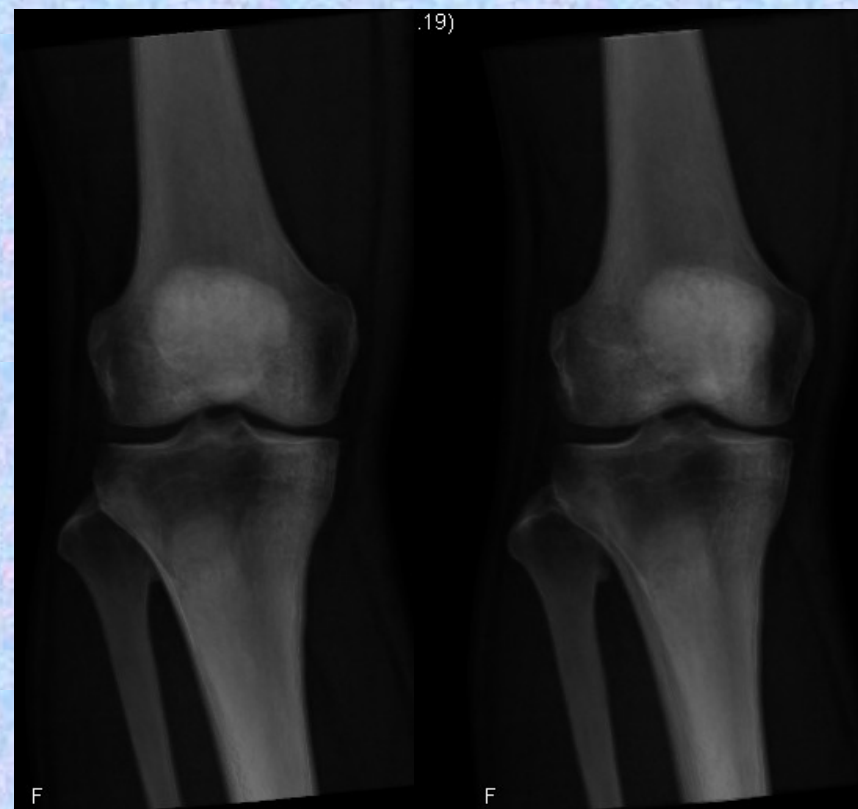

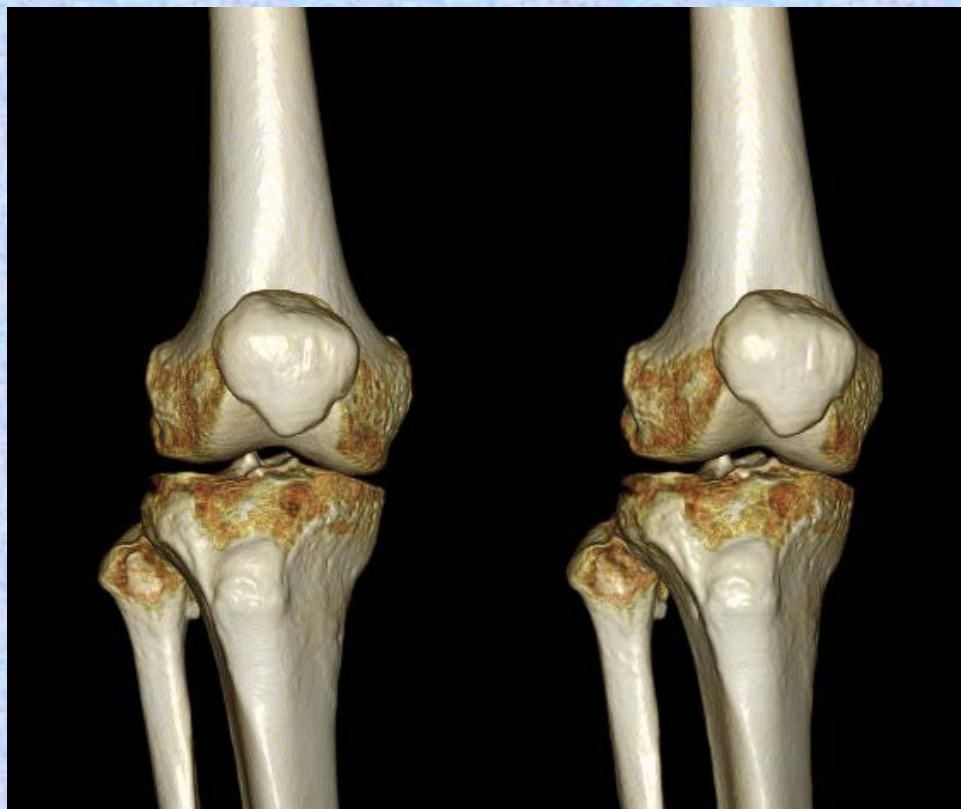


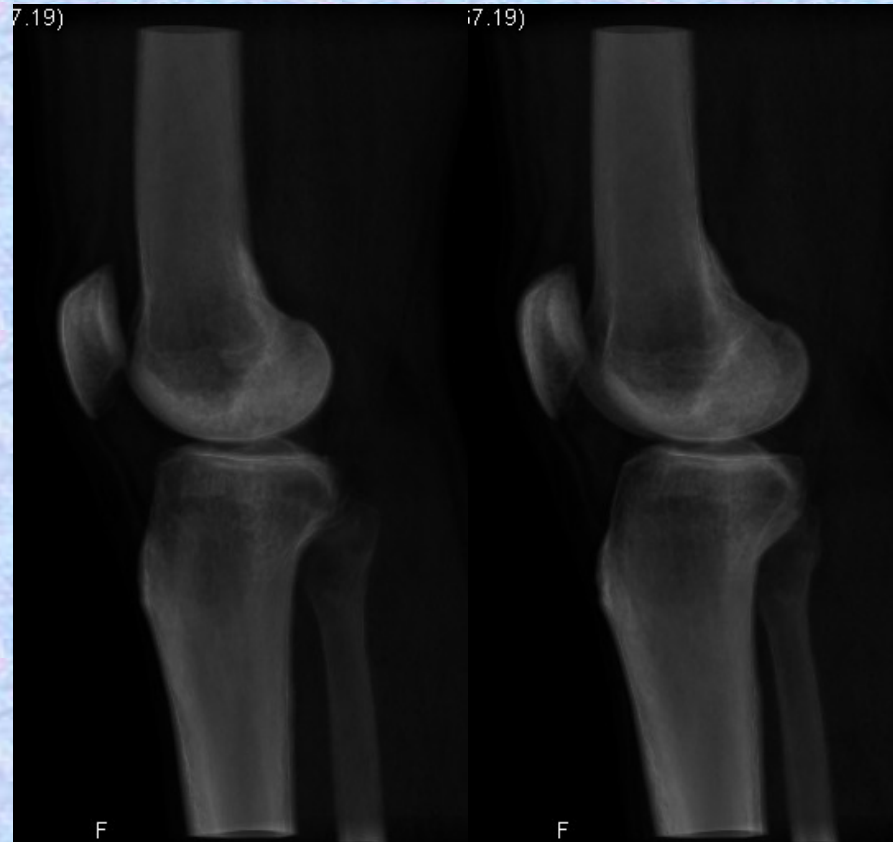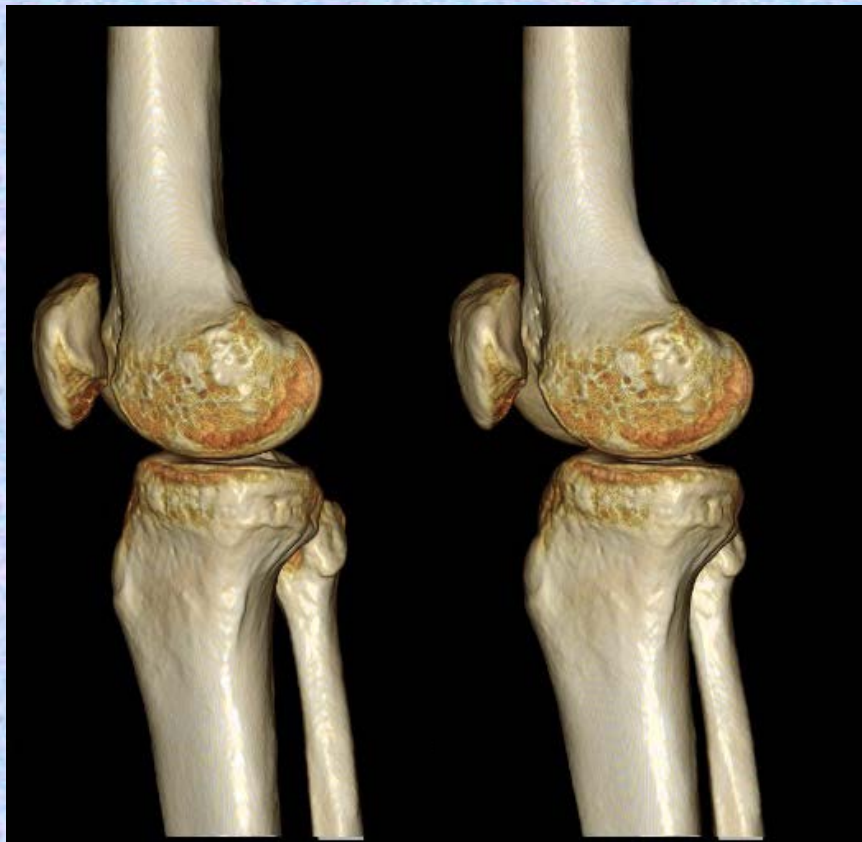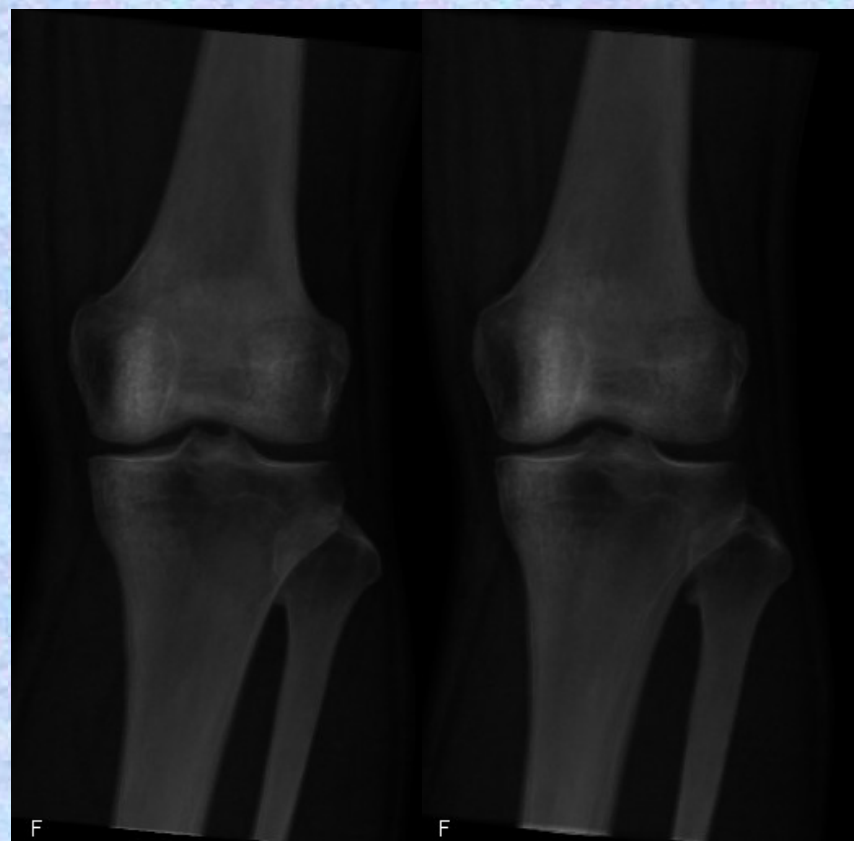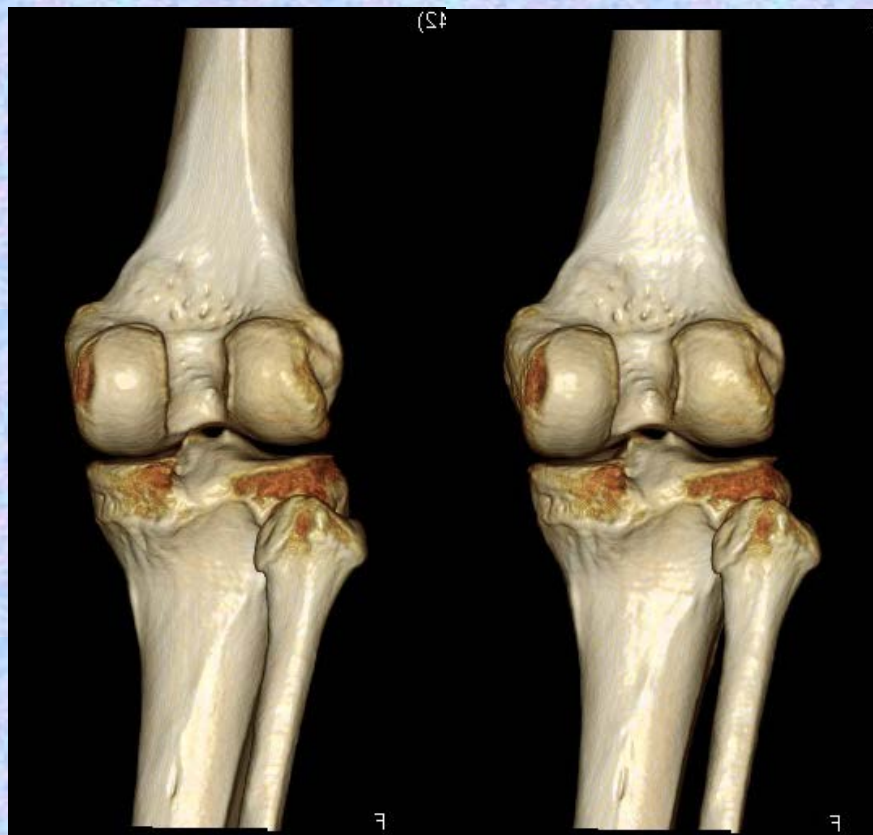


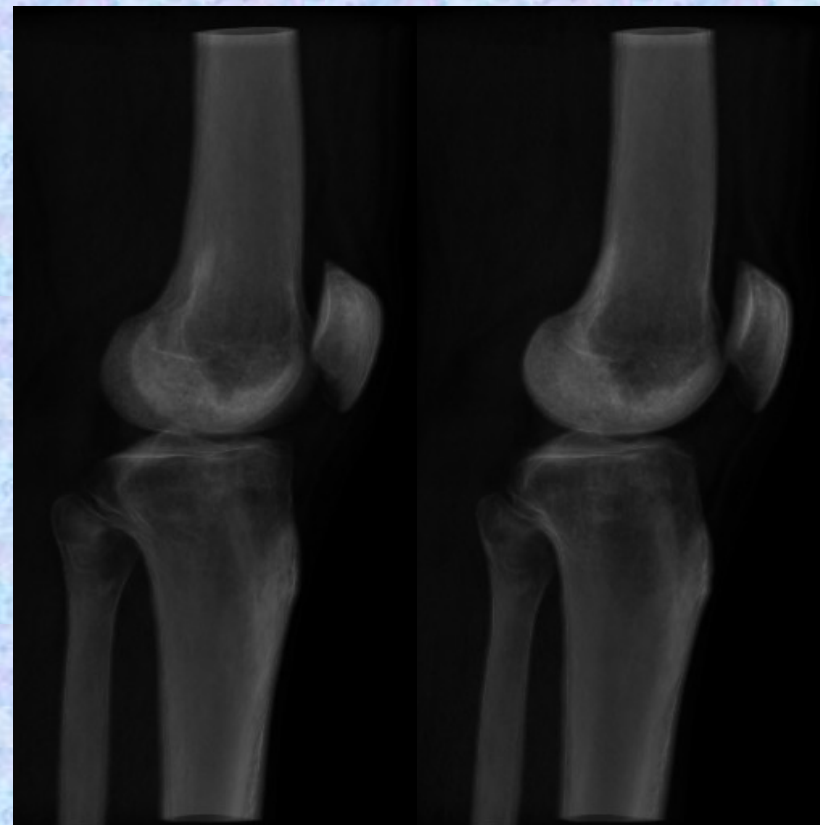
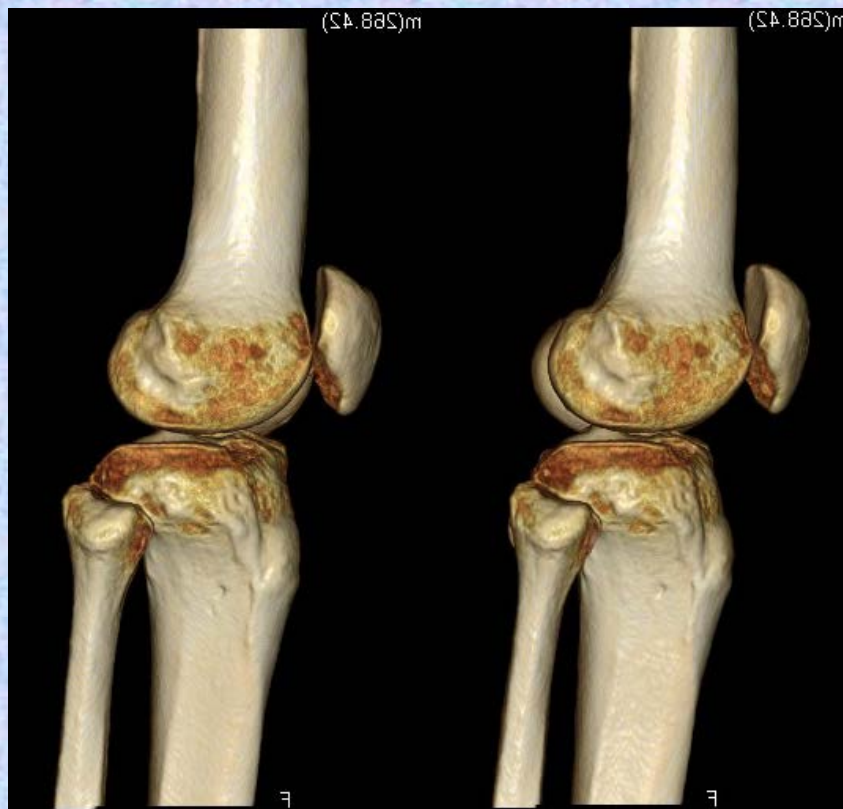






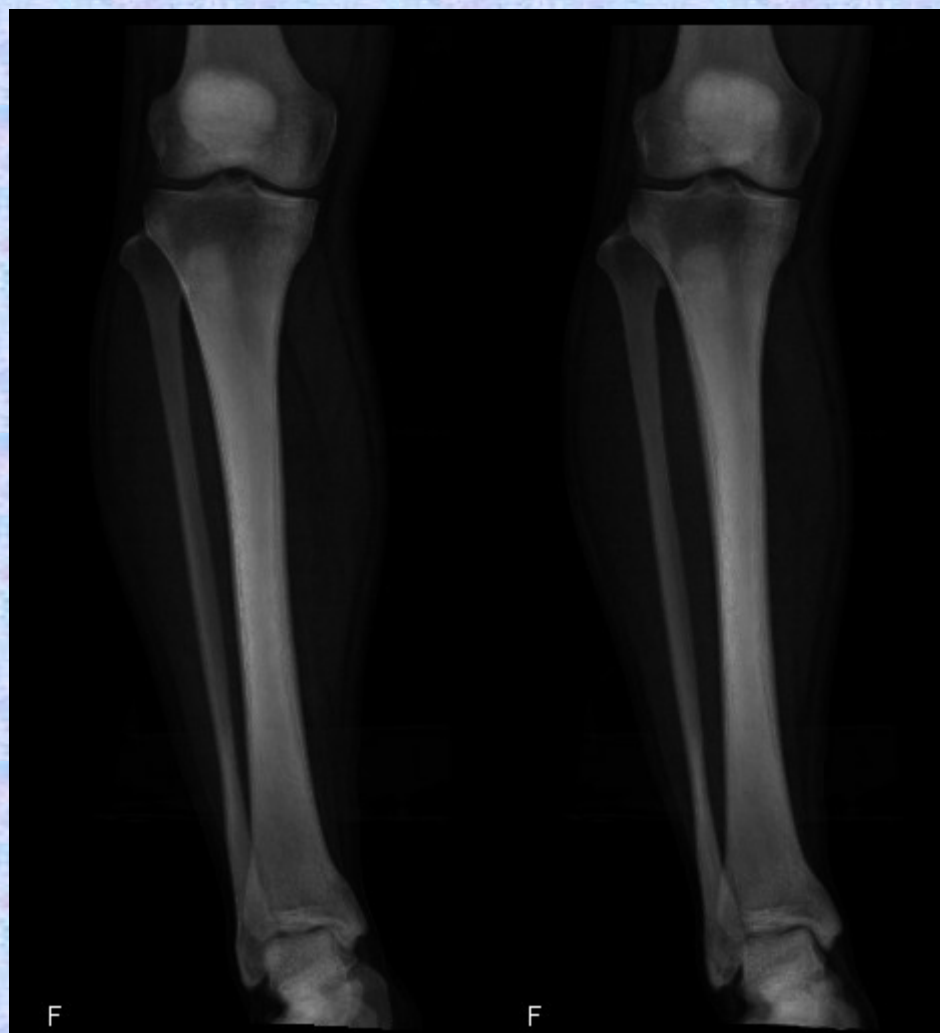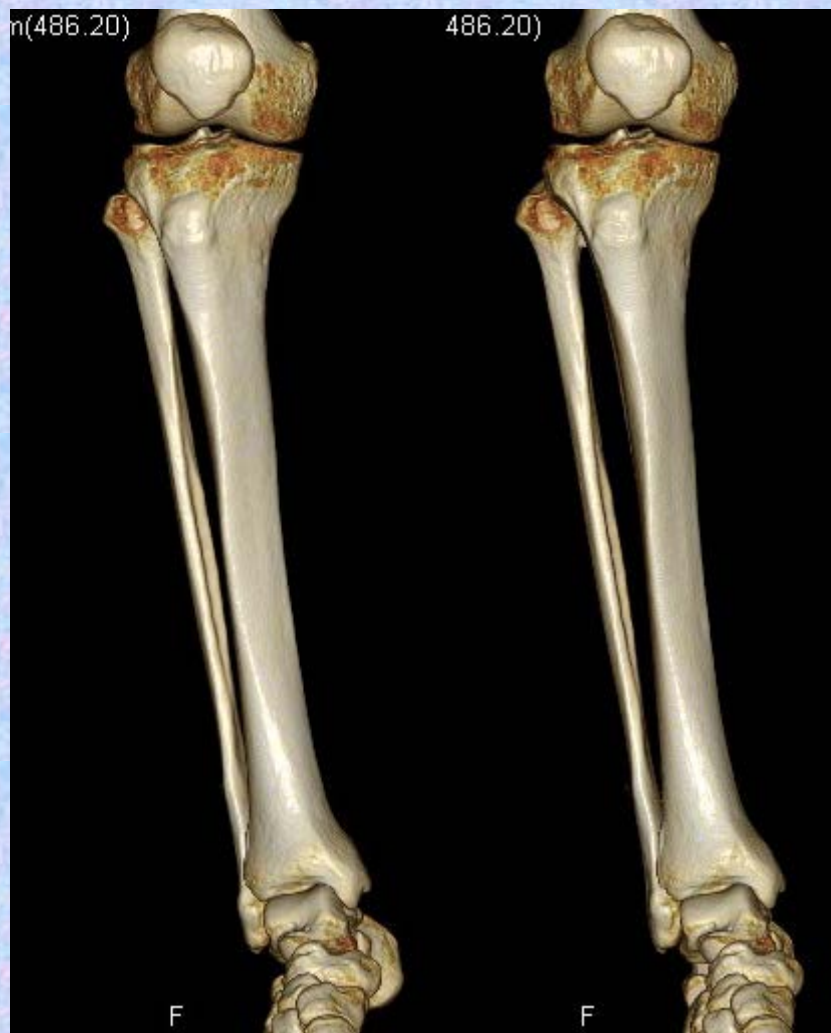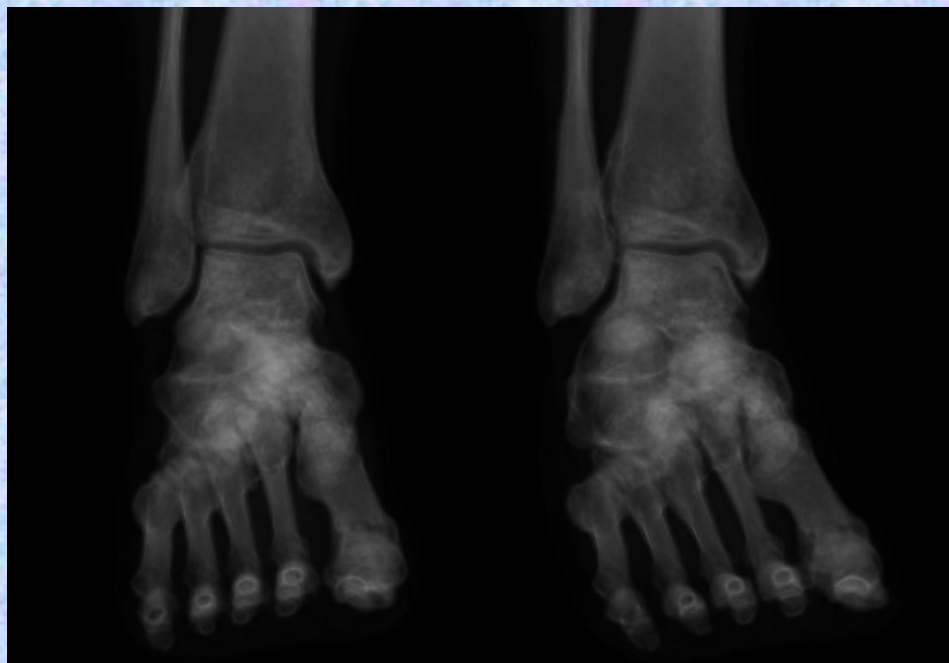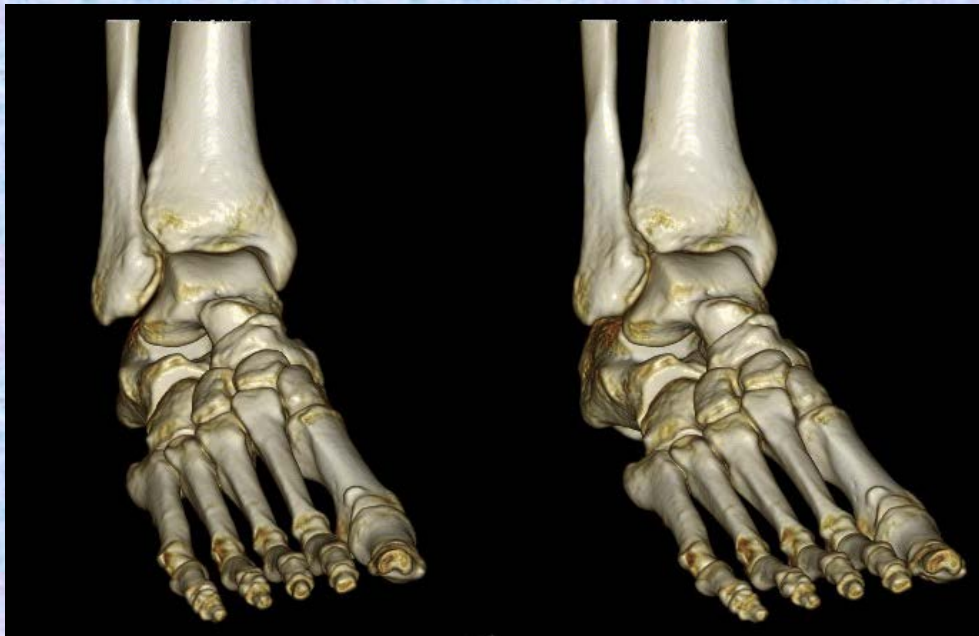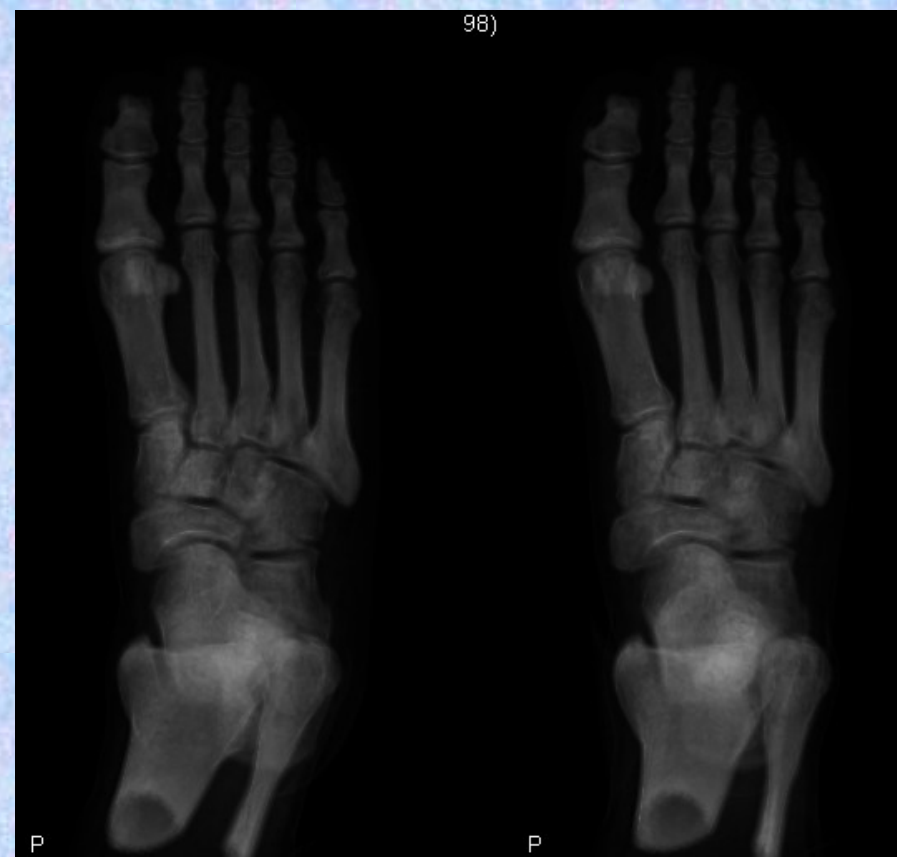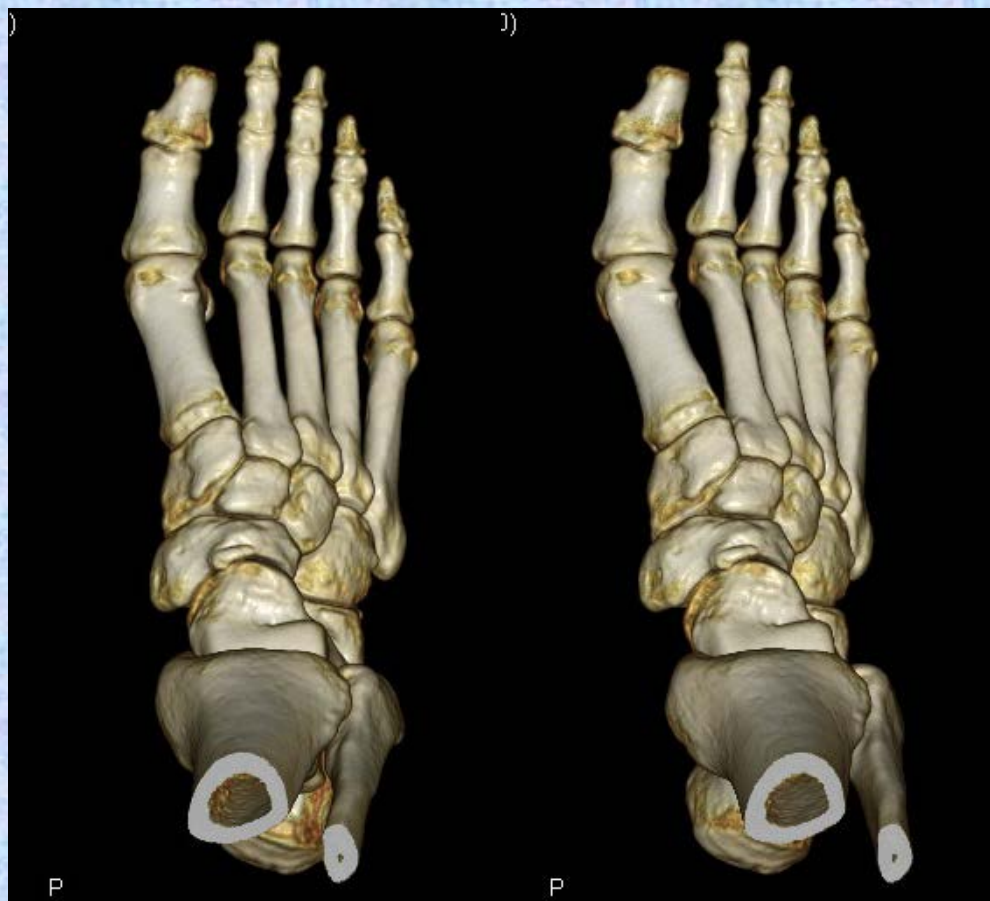












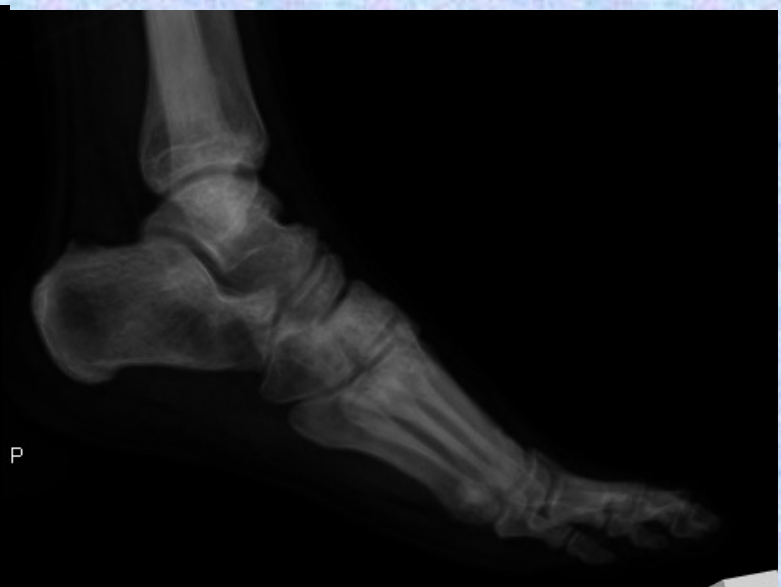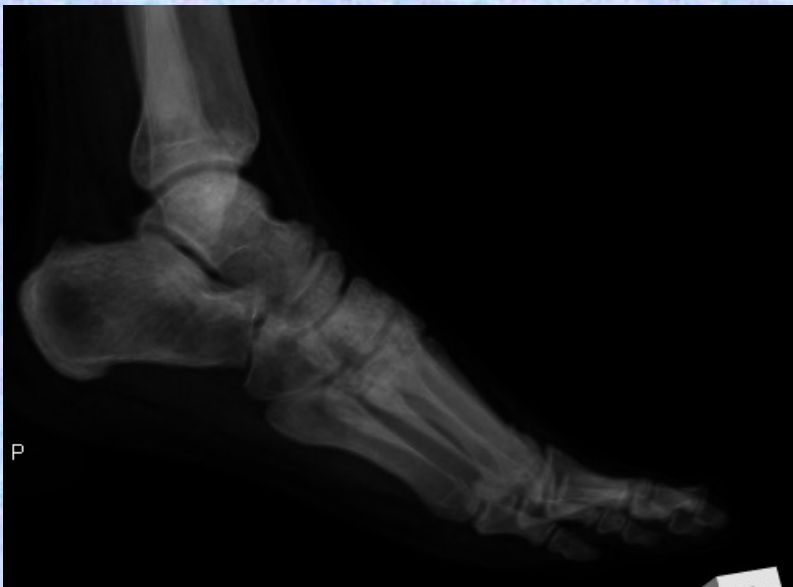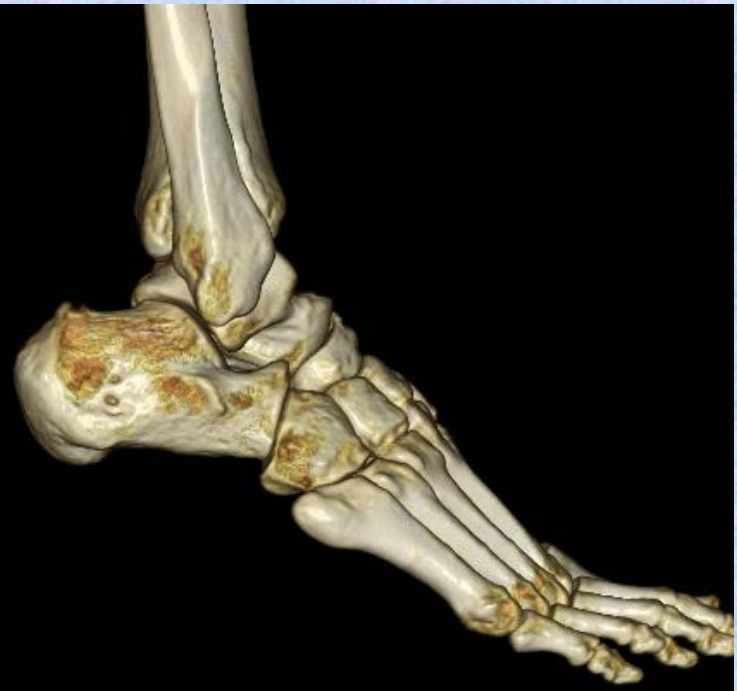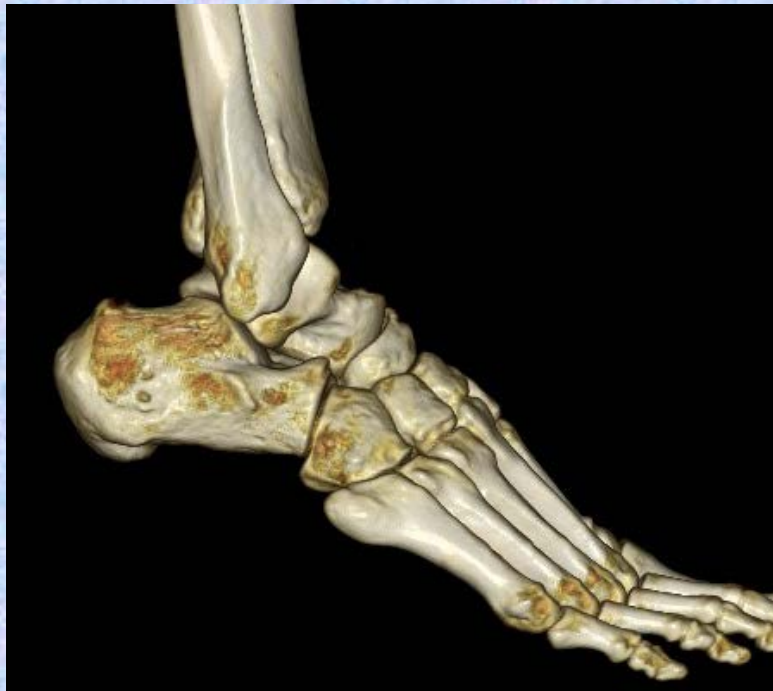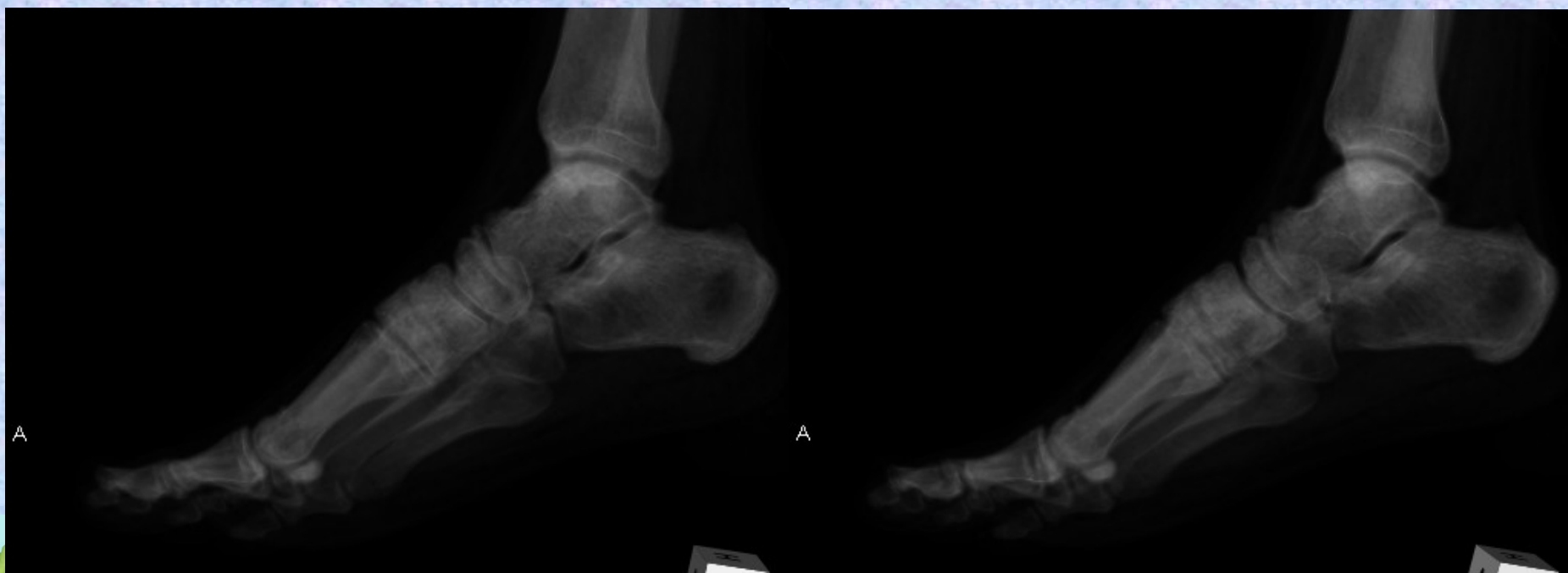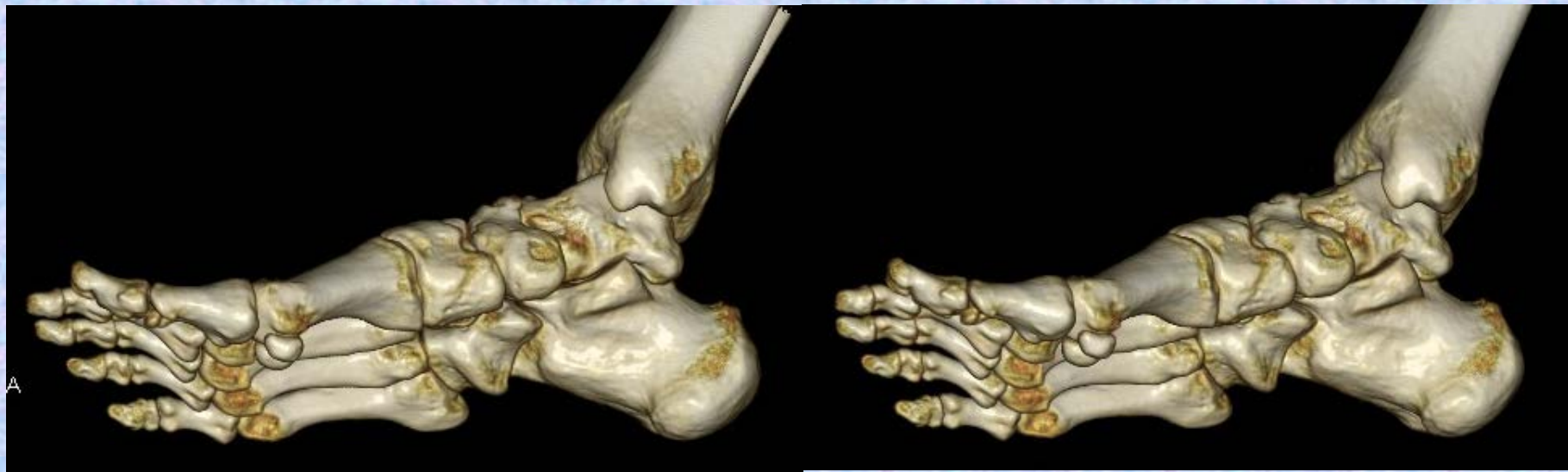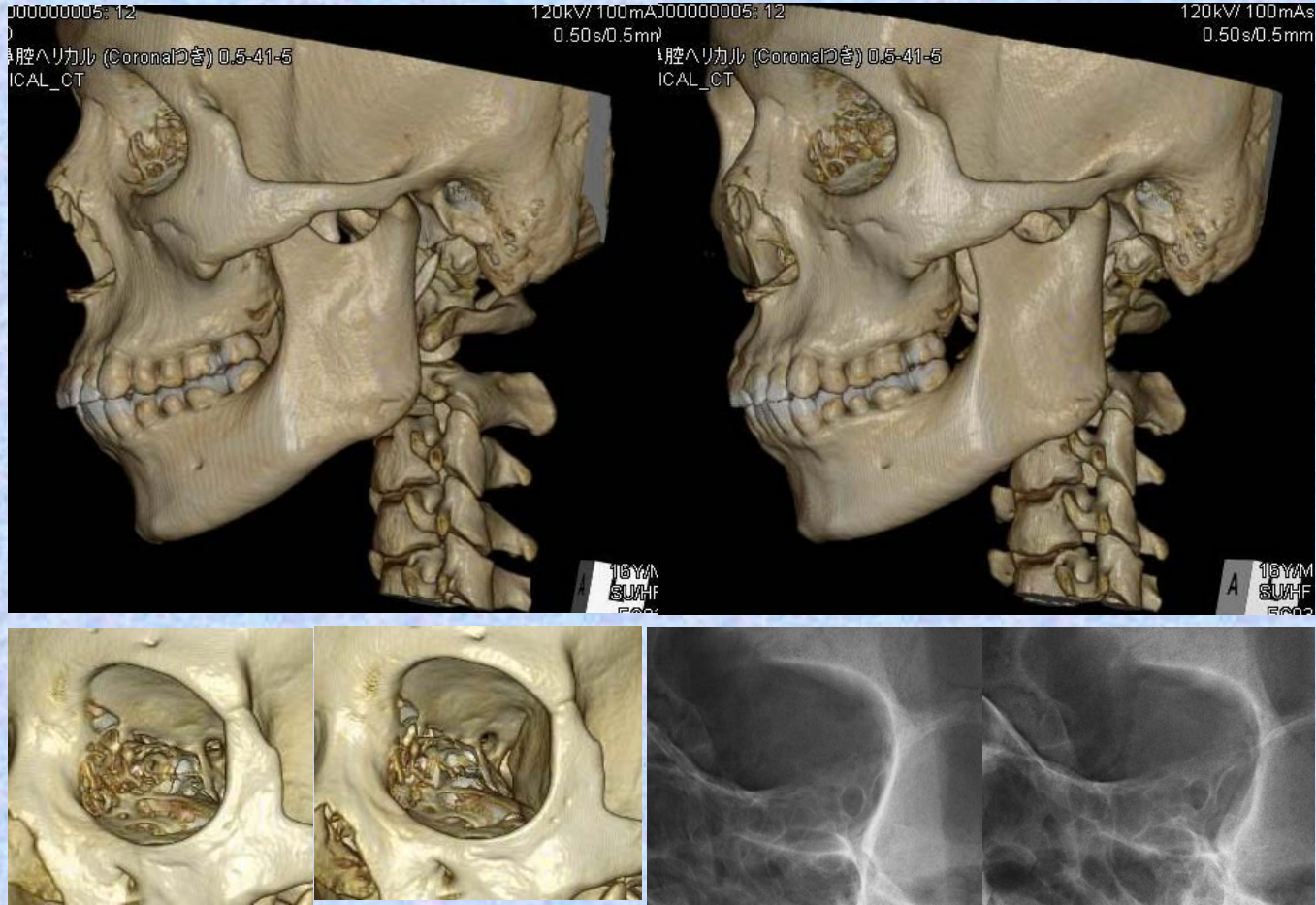




骨標本X線ステレオ解剖図

頭部

頭部



監修 香川大学医学部 組織細胞生物学 教授 荒木 伸一
作成 香川大学医学部附属病院 放射線部 勢川 博雄 2014.9



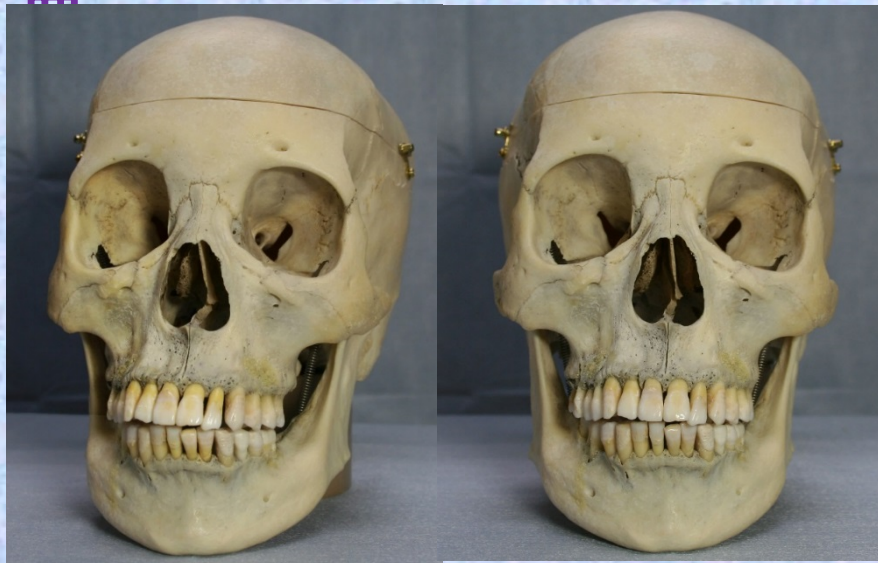頭蓋骨

Cranial bones

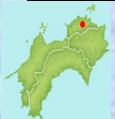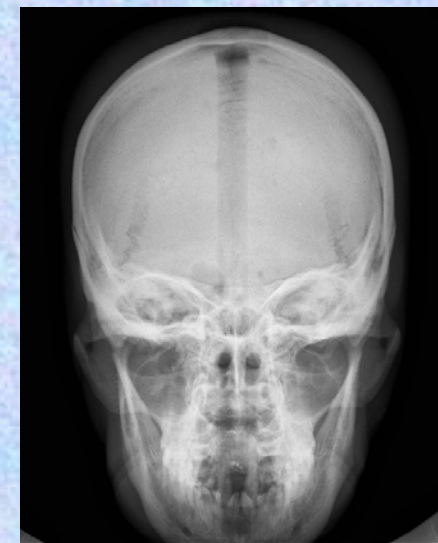
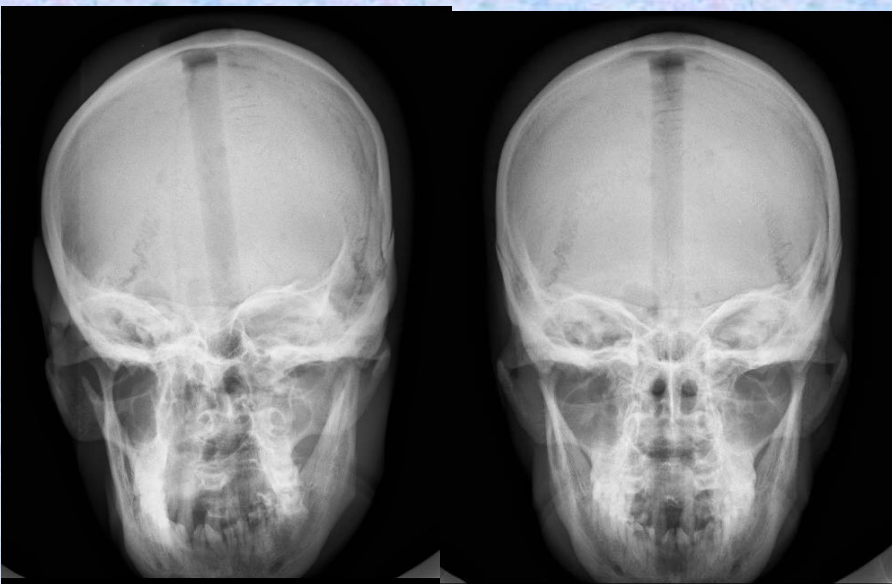
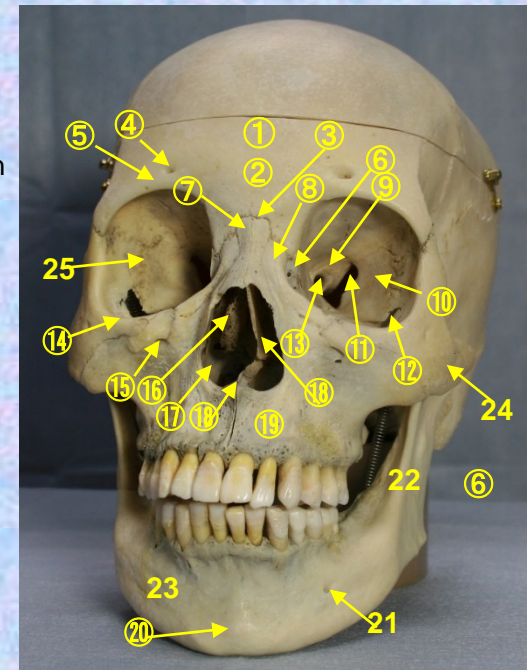


頭蓋骨 Cranial bones 前

前面 (Cranial bones anterior view)

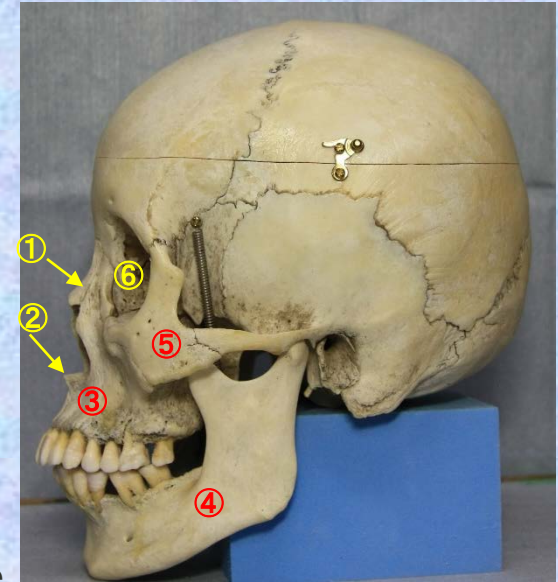
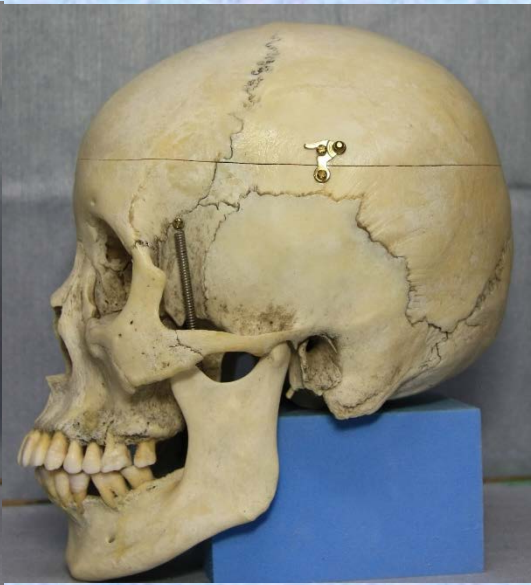
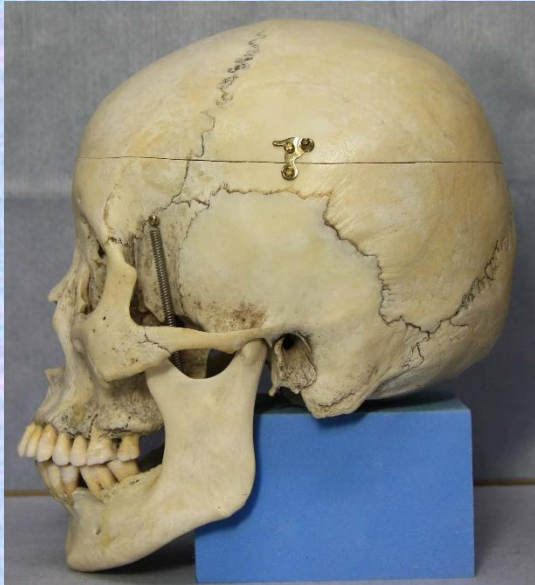
- ①前頭骨 frontal bone
- ②眉間 glabella
- ③ナジオン nasion
- ④眼窩上孔 supra-orbital foramen
- ⑤眼窩上縁 supra-orbital margin
- ⑥涙骨 Lacrimal bone
- ⑦鼻骨 nasal bone
- ⑧上顎骨前頭突起
frontal process of maxilla
- ⑨蝶形骨の小翼
Lesser wing of sphenoid bone
- ⑩蝶形骨の大翼
greater wing of sphenoid bone
- ⑪上眼窩裂 superior orbital fissure
- ⑫下眼窩裂
inferior orbital fissure
- ⑬視神経管 optic canal
- ⑭眼窩下縁 infra-orbital margin
- ⑮眼窩下孔 infra-orbital foramen
- ⑯中鼻甲介 middle nasal concha
- ⑰下鼻甲介 Inferior nasal concha
- ⑱前鼻棘 Anterior nasal spine
- ⑲上顎骨 maxilla
- ⑳オトガイ隆起 mental protuberance
- ㉑オトガイ孔 mental foramen
- ㉒下顎枝 ramus of mandible
- ㉓下顎体 body of mandible
- ㉔頬骨 zygomatic bone
- ㉕眼窩 orbit



頭蓋骨 Cranial bones 側面

側面 (Cranial bones lateral view)



①鼻骨

nasal bone

②前鼻棘

anterior nasal spine

③上顎骨

maxilla

④下顎体

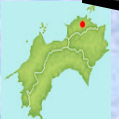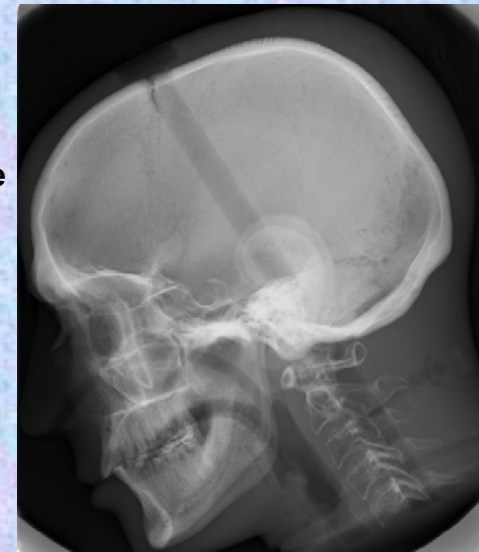
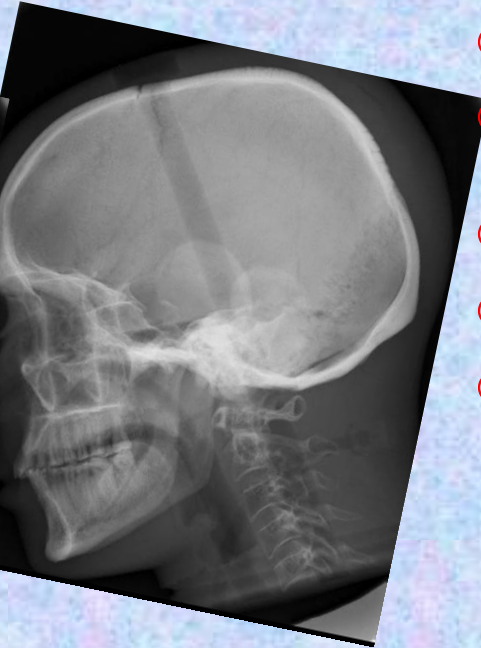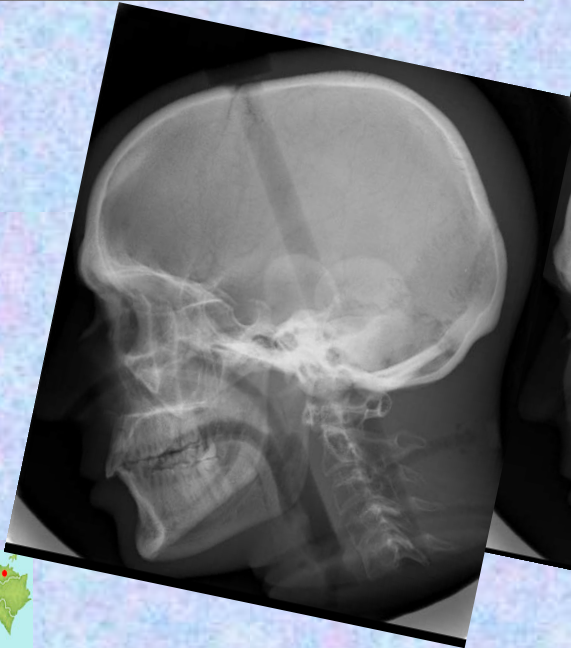
body of mandible

⑤頬骨

zygomatic bone

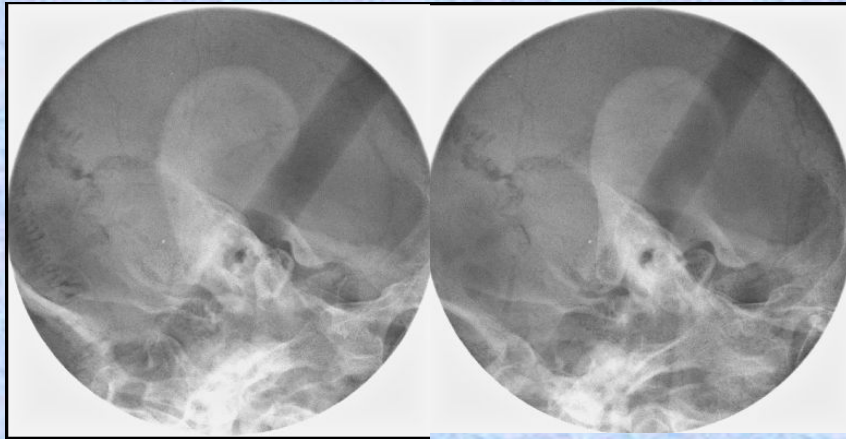
⑥眼窩

orbit

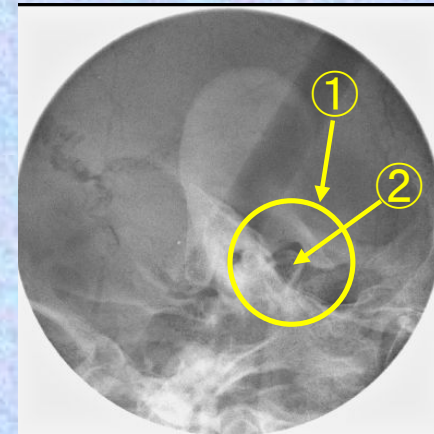


顎関節 tempero-mandibular joints

(Temporo-mandibular joint lateral view)

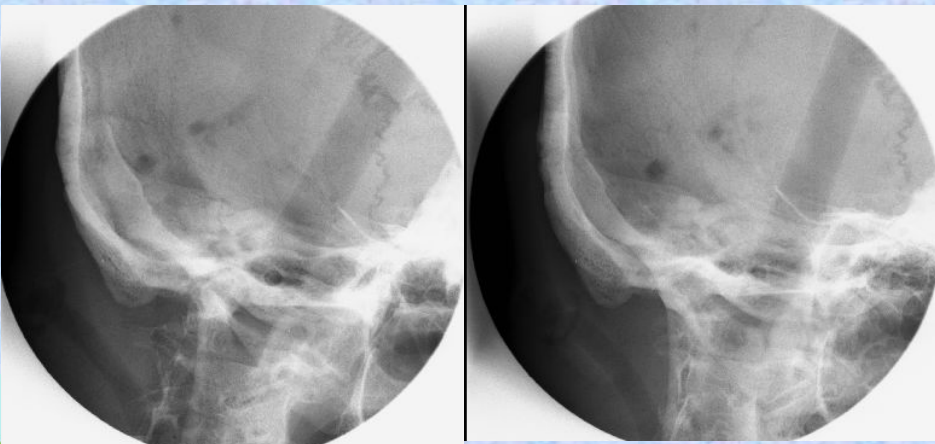
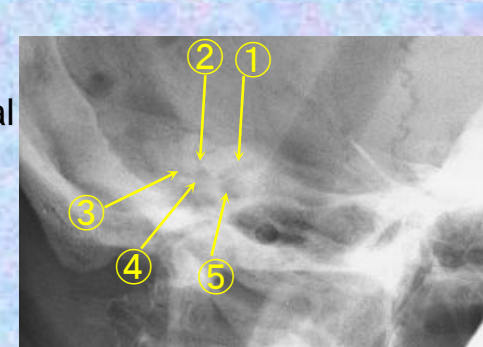


- ① 顎関節骨
temporo-mandibular joint
- ② 下顎頭
head of the mandible

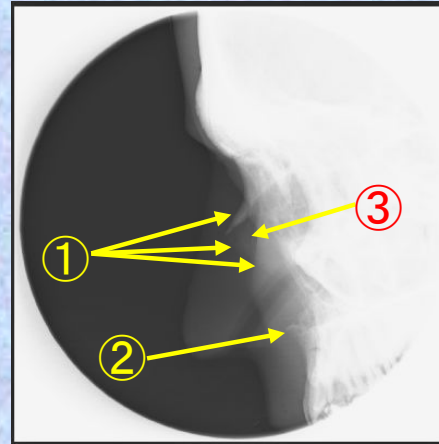
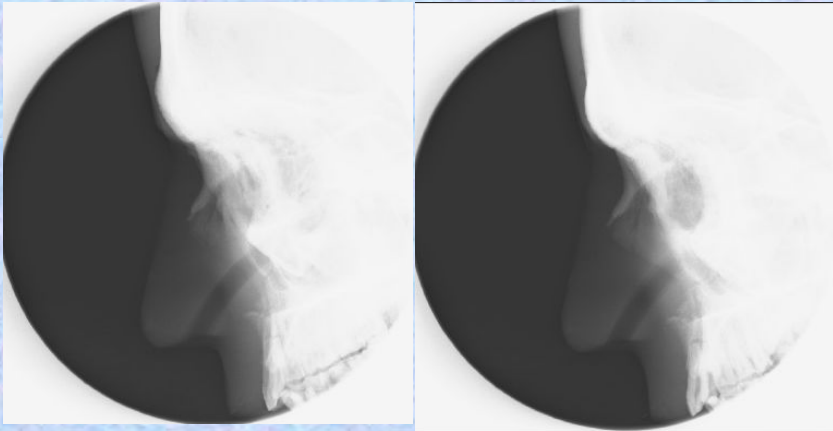


内耳道 internal auditory meatus (Stenvers 法)

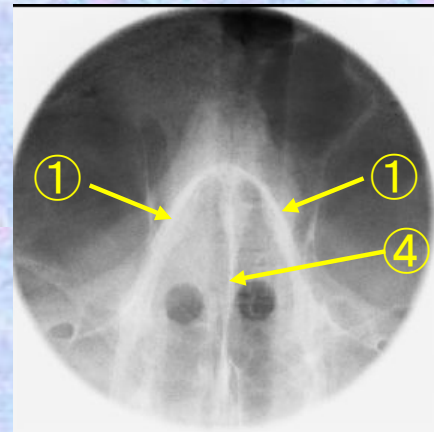
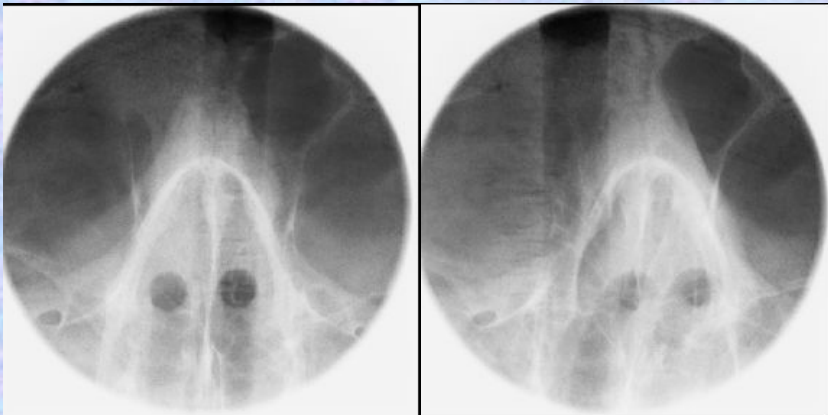
- ① 内耳道
internal auditory canal
- ② 前半規管
anterior semicircular canal
- ③ 外側半規管
lateral semicircular canal
- ④ 前庭
vestibule
- ⑤ 蝸牛
tympnic cavity



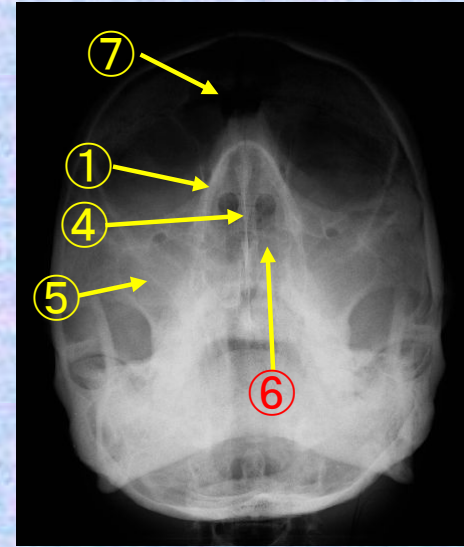
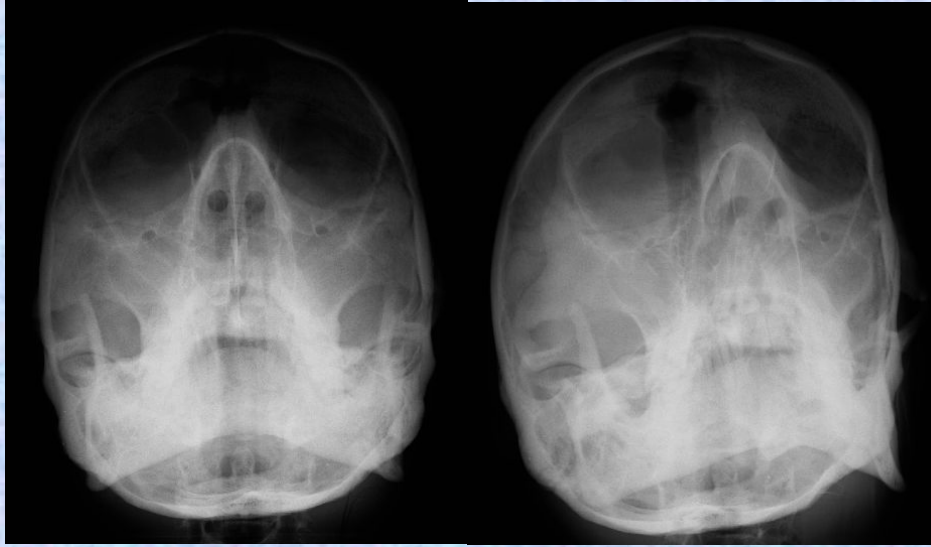
鼻骨 (nasal bone)



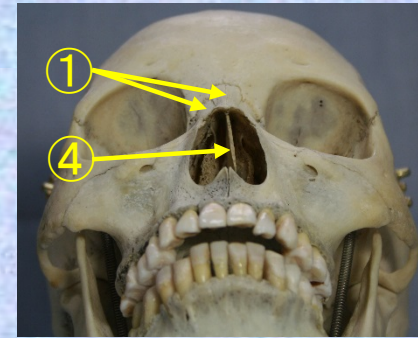
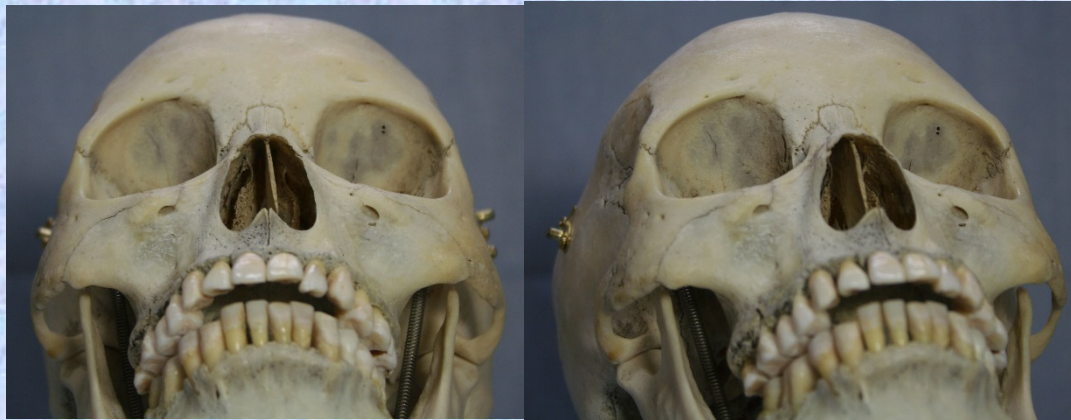- ①鼻骨
nasal bone
- ②前鼻棘
anterior nasal spine
- ③鼻骨上顎縫合
nasomaxillary suture
- ④鼻中隔
nasal septum



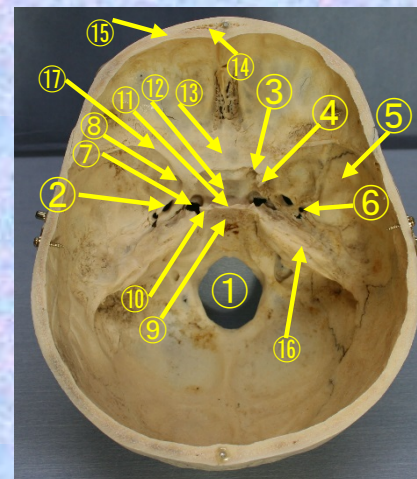
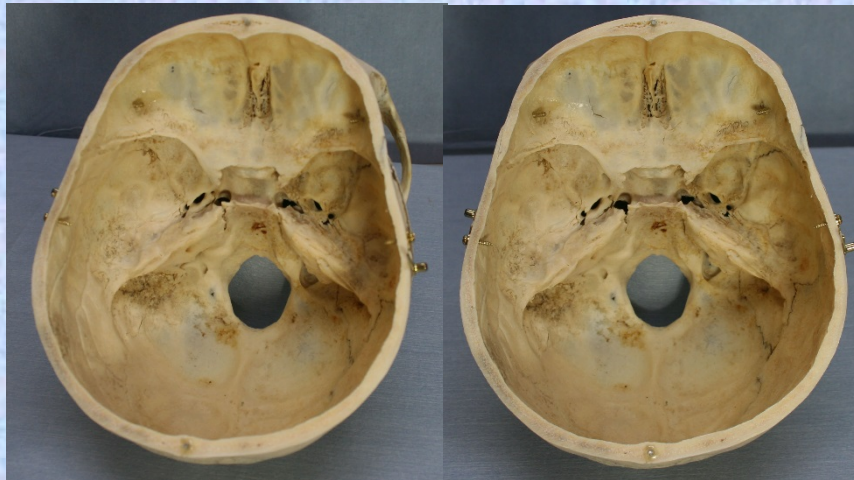
Water's 法 (Water's view)



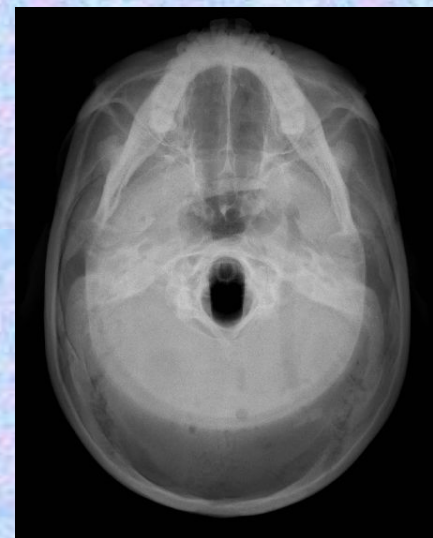
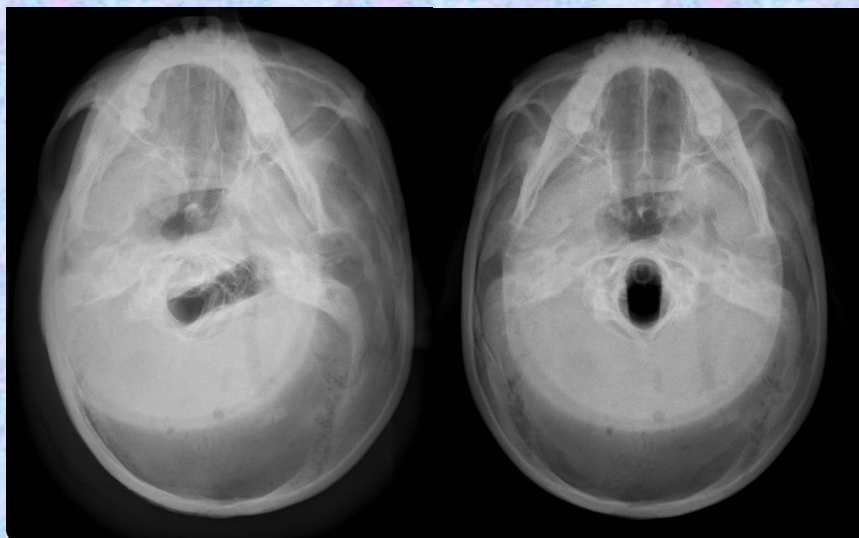
- ①鼻骨
nasal bone
- ②前鼻棘
anterior nasal spine
- ③鼻骨上顎縫合
nasomaxillary suture
- ④鼻中隔
nasal septum
- ⑤上顎洞
maxillary sinus
- ⑥蝶形骨洞
sphenoid sinus
- ⑦前頭洞
frontal sinus



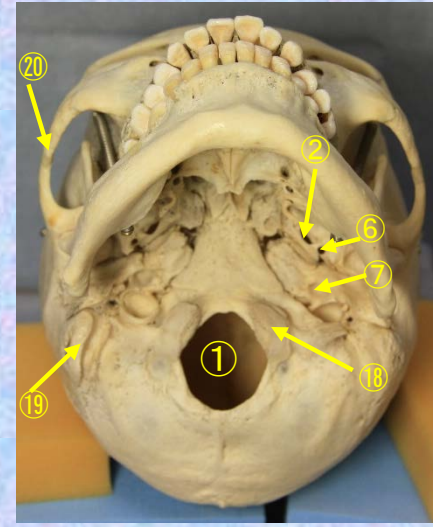
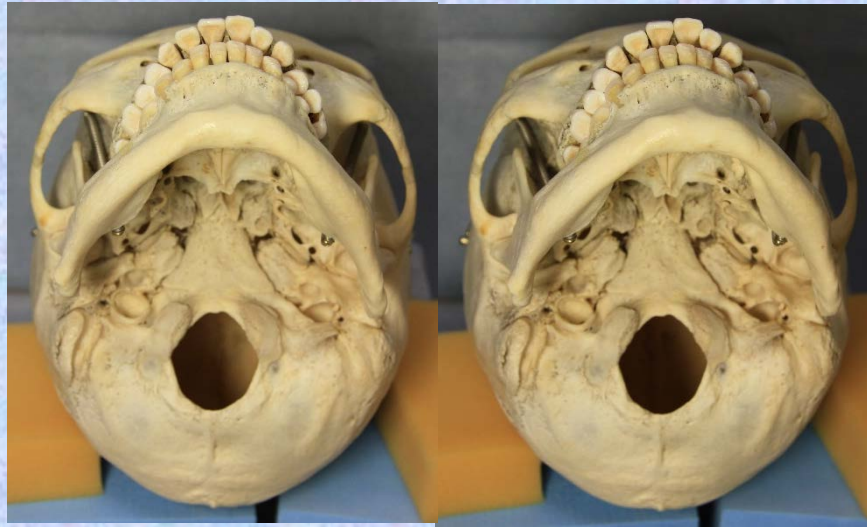頭蓋底 (Axial of head view)



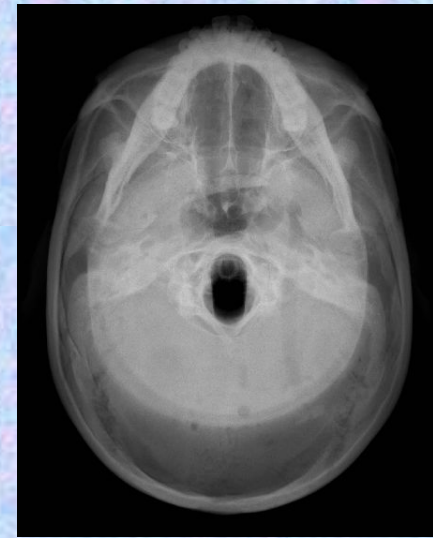
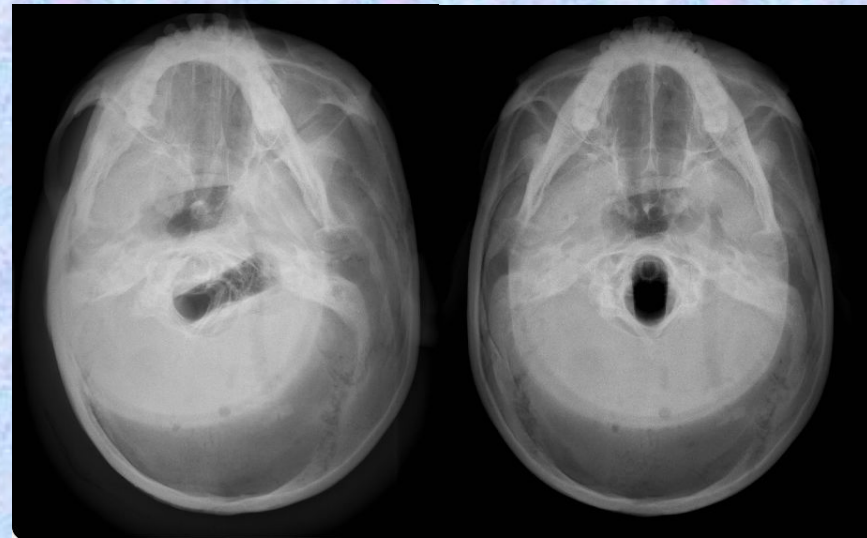
- ①大後頭孔
foramen magnum
- ②卵円孔
foramen ovale
- ③視神経管
optic canal
- ④前床突起
anterior clinoid process
- ⑤側頭骨の鱗部
squamous part of temporal
- ⑥棘孔
foramen spinosum
- ⑦頸動脈孔
carotid groove
- ⑧正円孔
foramen rotundum
- ⑨斜台
clivus
- ⑩後床突起
posterior clinoid process
- ⑪鞍背
dorsum sellae
- ⑫トルコ鞍
sella turcica
- ⑬蝶形骨隆起
jugum of sphenoid
- ⑭前頭洞
frontal sinus
- ⑮板間層
diploe
- ⑯側頭骨の岩様部
petrous part of temporal
- ⑰蝶形骨の小翼
lesser wing of sphenoid



頭蓋底 (Axial of head view)

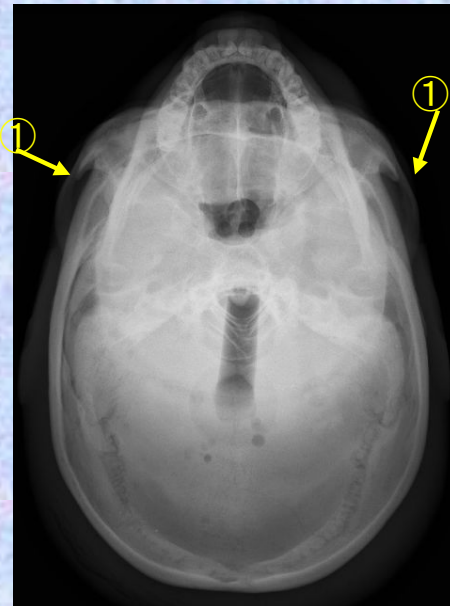
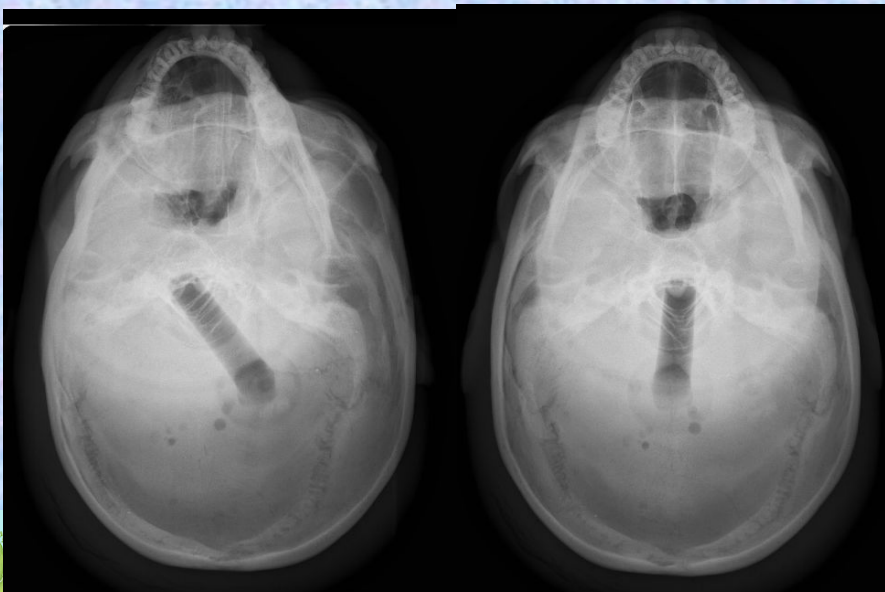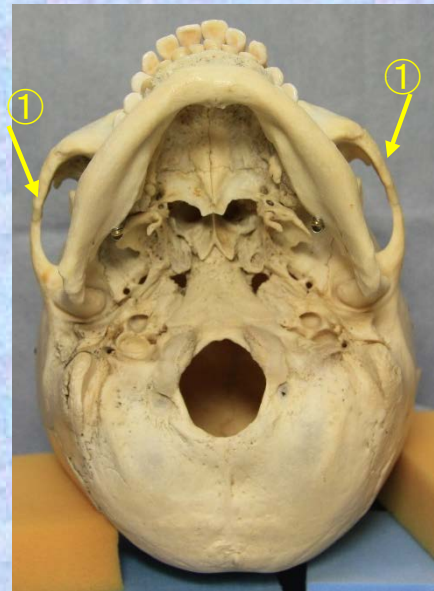
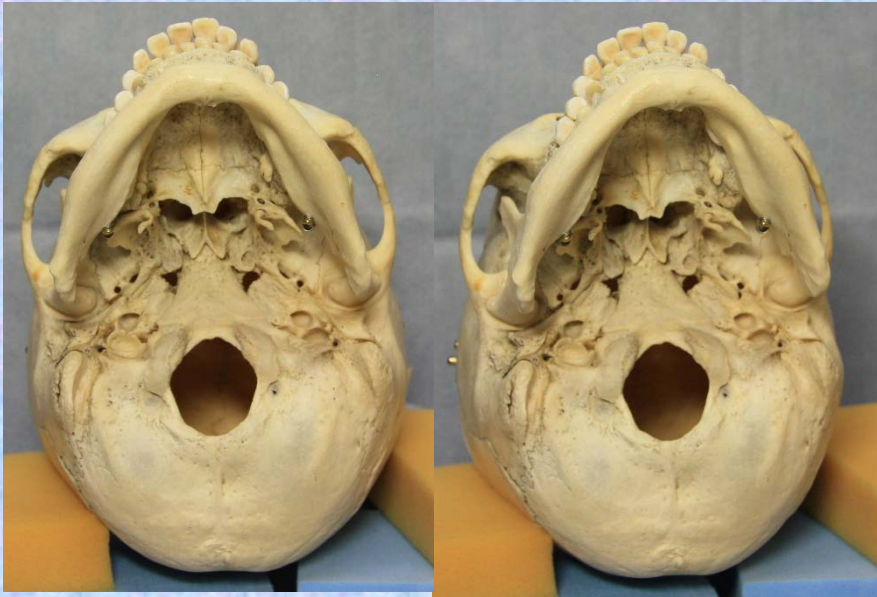


- ①大後頭孔
foramen magnum
- ②卵円孔
foramen ovale
- ⑥棘孔
foramen spinosum
- ⑦頸動脈孔
carotid groove
- ⑧後頭顆 occipital condyle
- ⑨乳様突起 mastoid process
- ⑩頬骨弓 Zygomatic arch



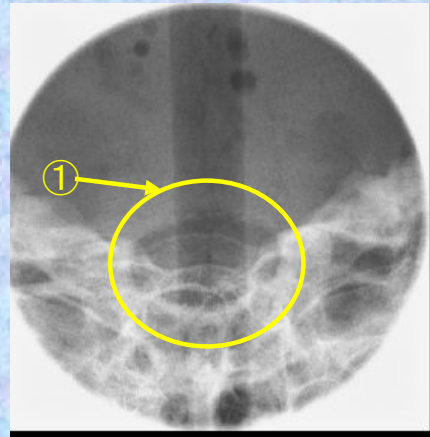
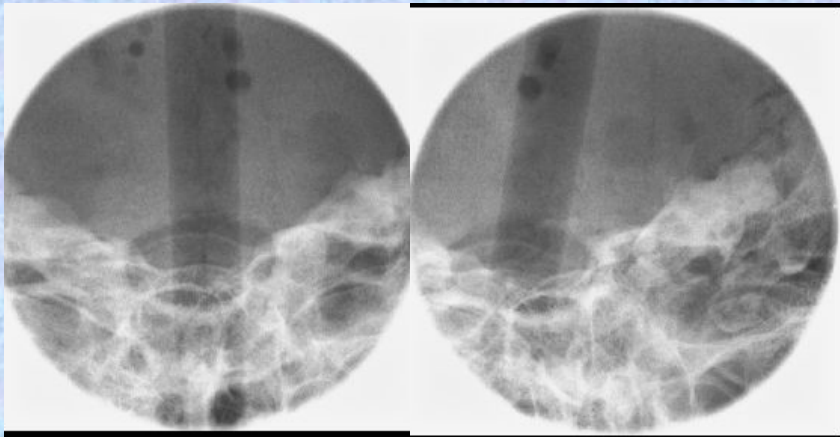
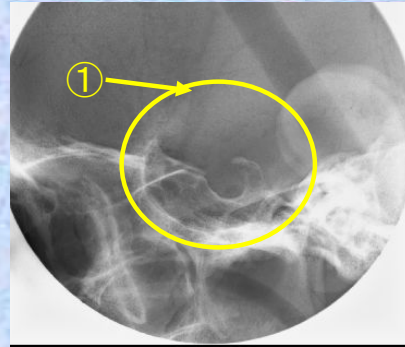
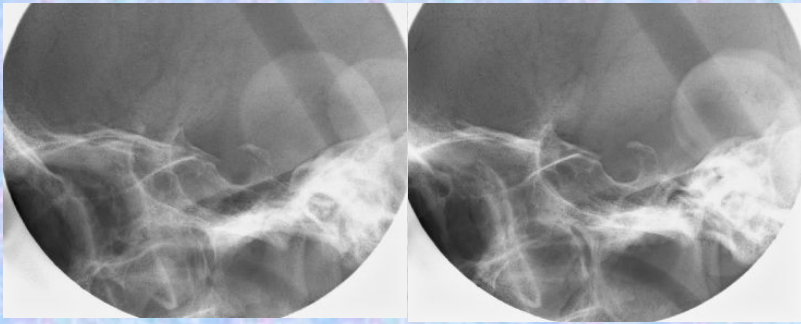
頬骨弓 (Zygomatic arch)

① 頬骨弓 Zygomatic arch



トルコ鞍 (Sella turcica)

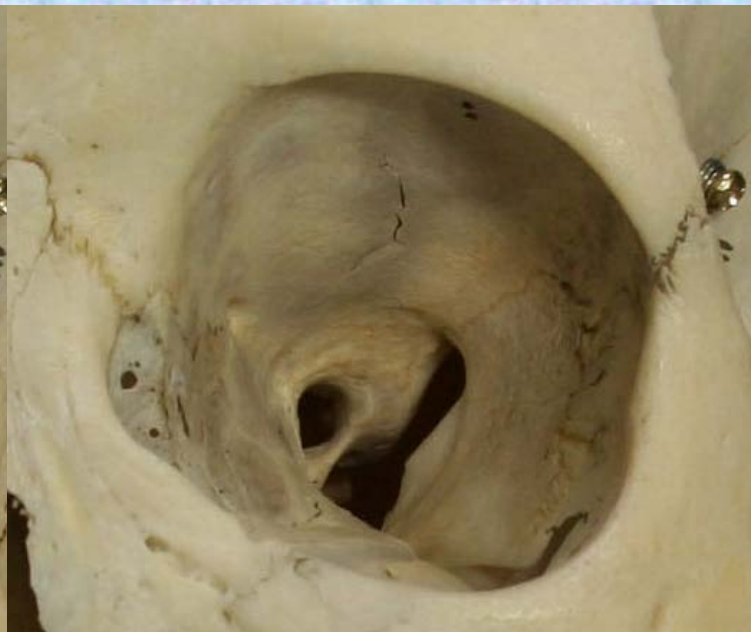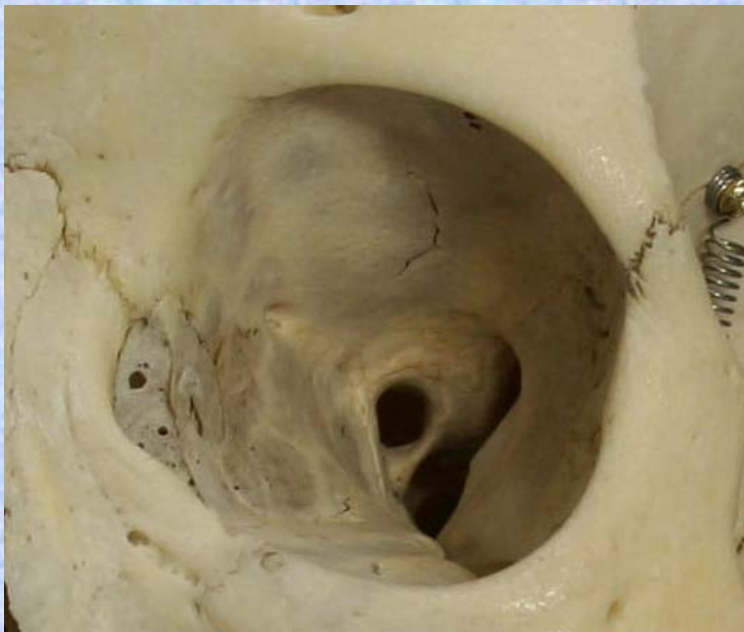
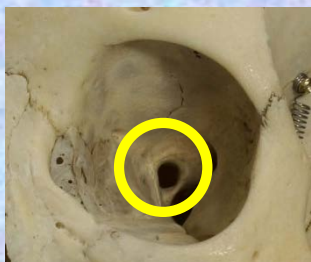①トルコ鞍 Sella turcica



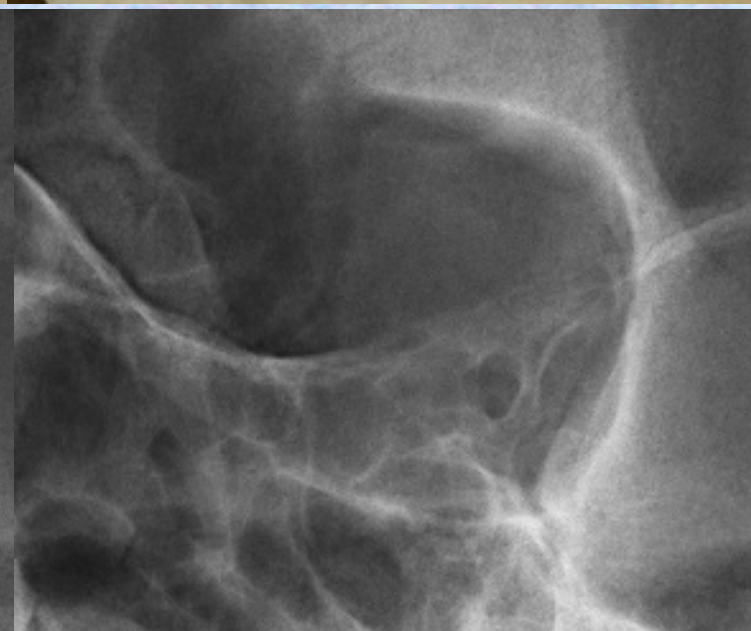
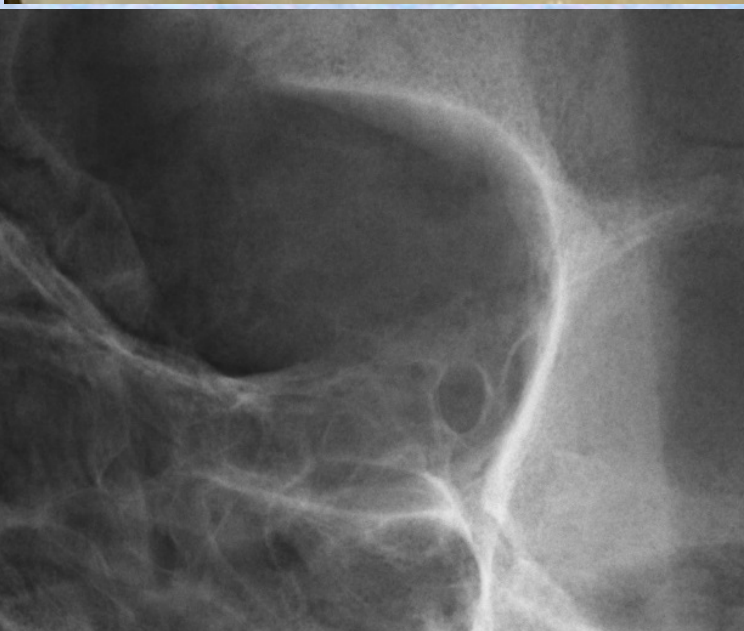
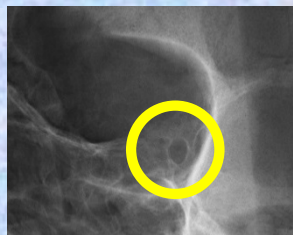
視神経管 (Optic canal)

視束管X線画像

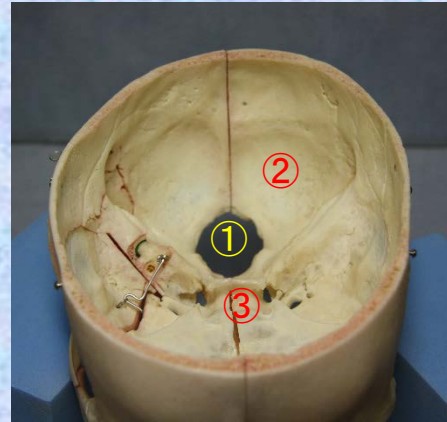
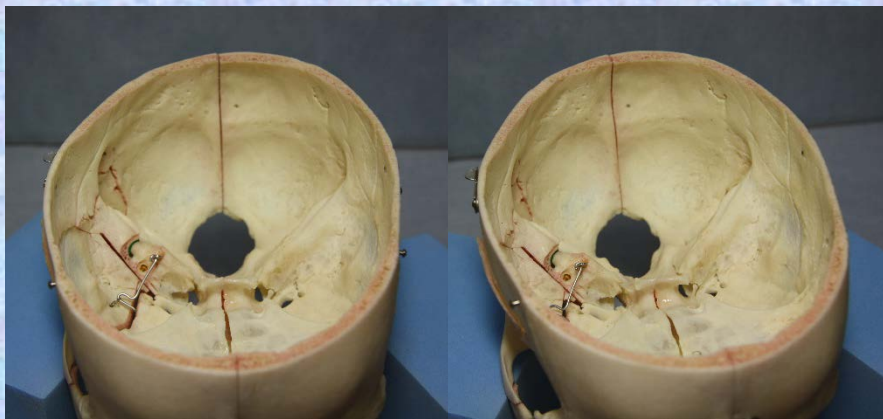
骨標本



X線画像



Towne 法



- ①大後頭孔
foramen magnum
- ②後頭骨
occipital bone
- ③トルコ鞍
sella turcica

